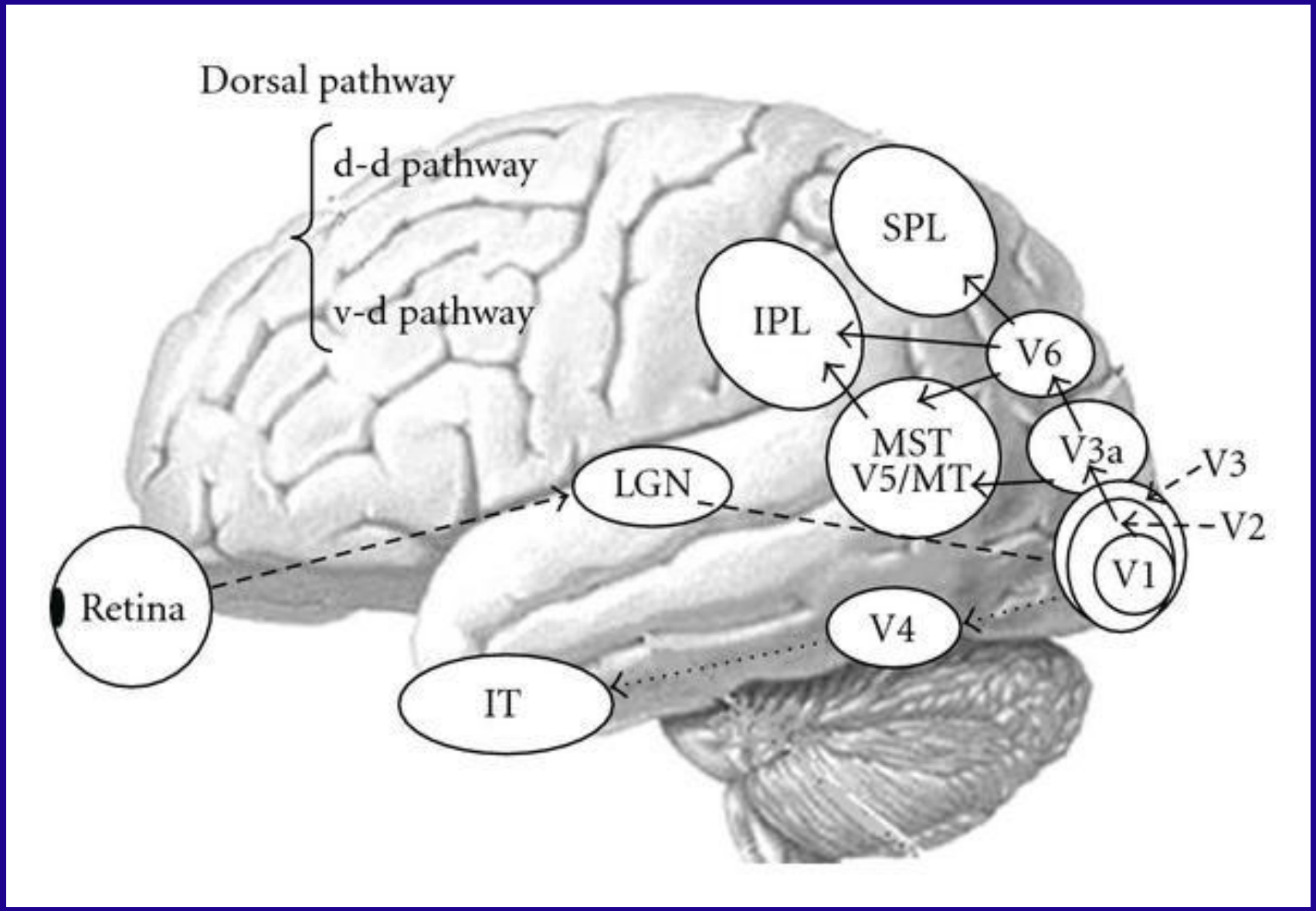
Dorsal pathway
d-d pathway
v-d pathway
SPL
IPL
V6
MST
V5/MT
V3a
V3
V2
V1
LGN
Retina
V4
IT

Damage to “where” pathway

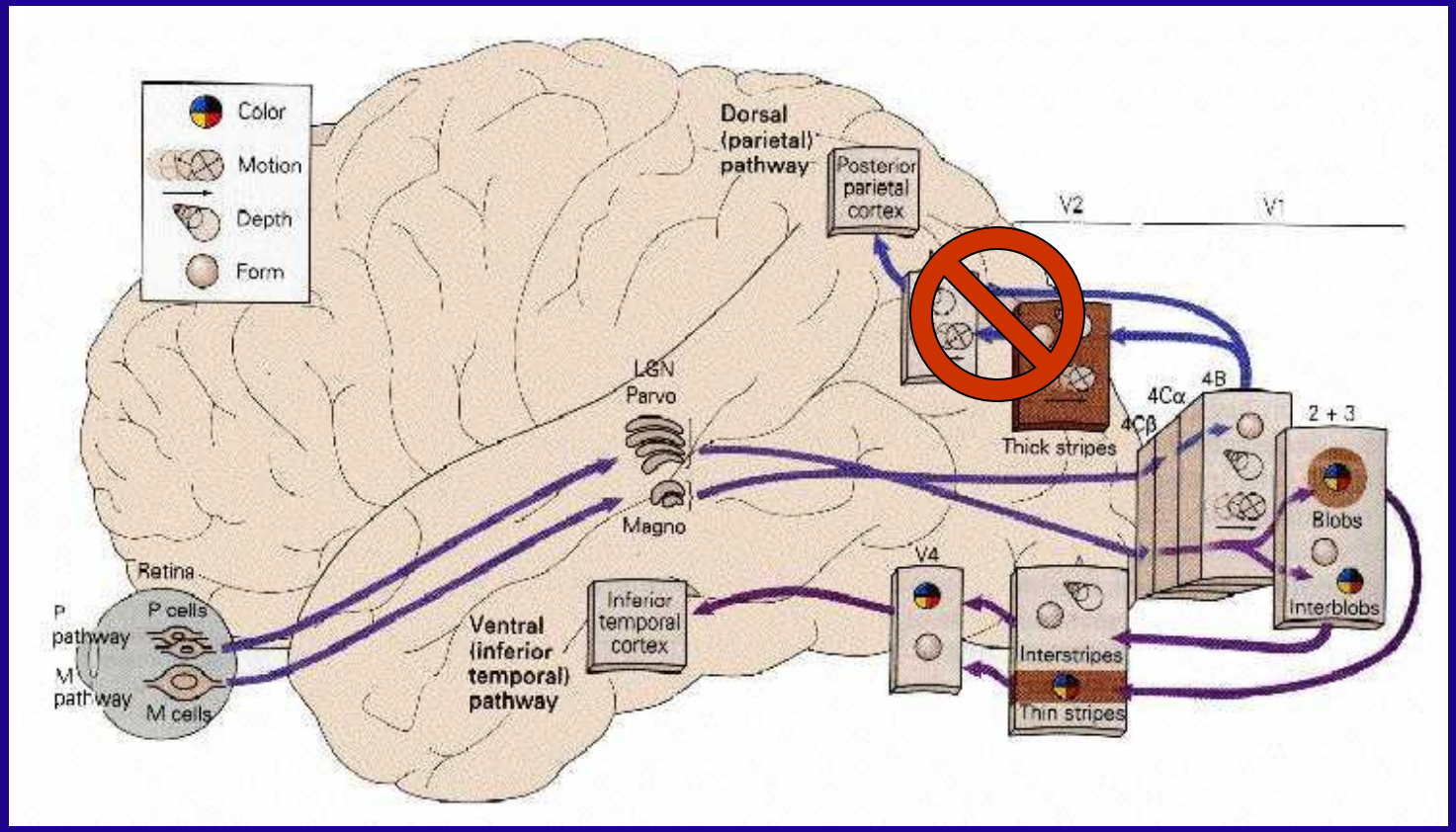

Abnormal motion processing & Visuspatial neglect

Akinetopsia

- Clinical features
  - Can't see moving objects (as if under strobe lights); can see still objects
  - People appear suddenly
- Neuropathology
  - **BL lesion** to area MT (V5; T-O-P junction)
  - UL lesions cause subtle defects

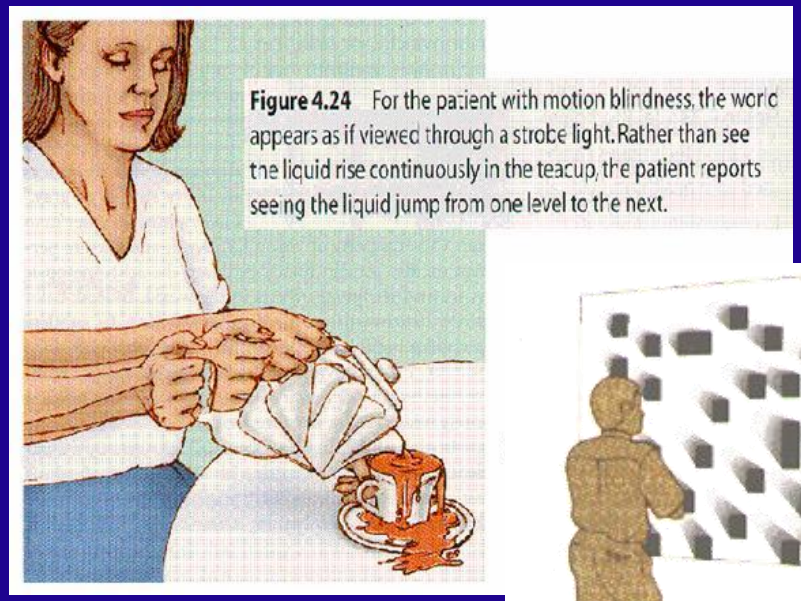

Figure 4.24 For the patient with motion blindness, the world appears as if viewed through a strobe light. Rather than see the liquid rise continuously in the teacup, the patient reports seeing the liquid jump from one level to the next.

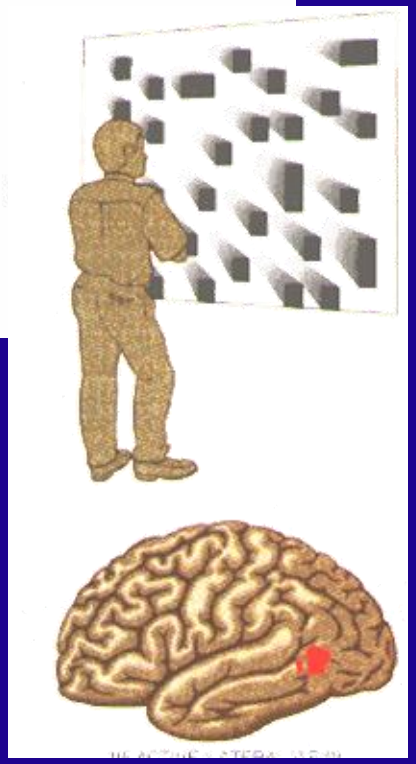

Akinetopsia

- Clinical features
  - Can't see moving objects (as if under strobe lights); can see still objects
  - People appear suddenly
- Neuropathology
  - **BL lesion** to area MT (V5; T-O-P junction)
  - UL lesions cause subtle defects

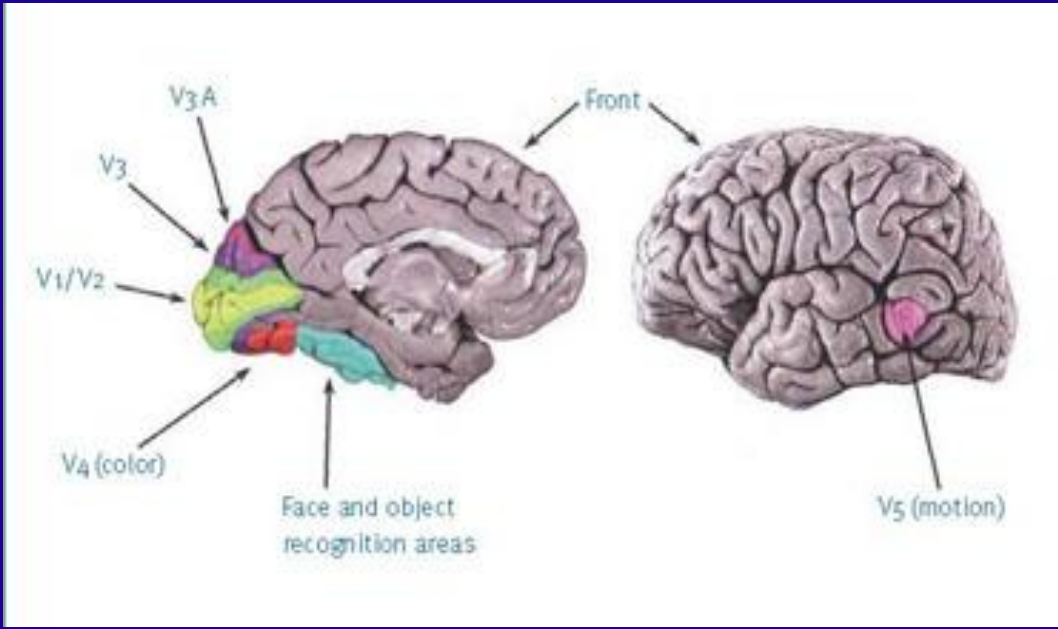

Topographagnosia

- Inability to navigate routes using familiar landmarks - deficit in familiar scene perception
- right ventral temporo-occipital lesions like **Right lingual gyrus**

VS

- right parietotemporal lesions

Spatial relationships distorted

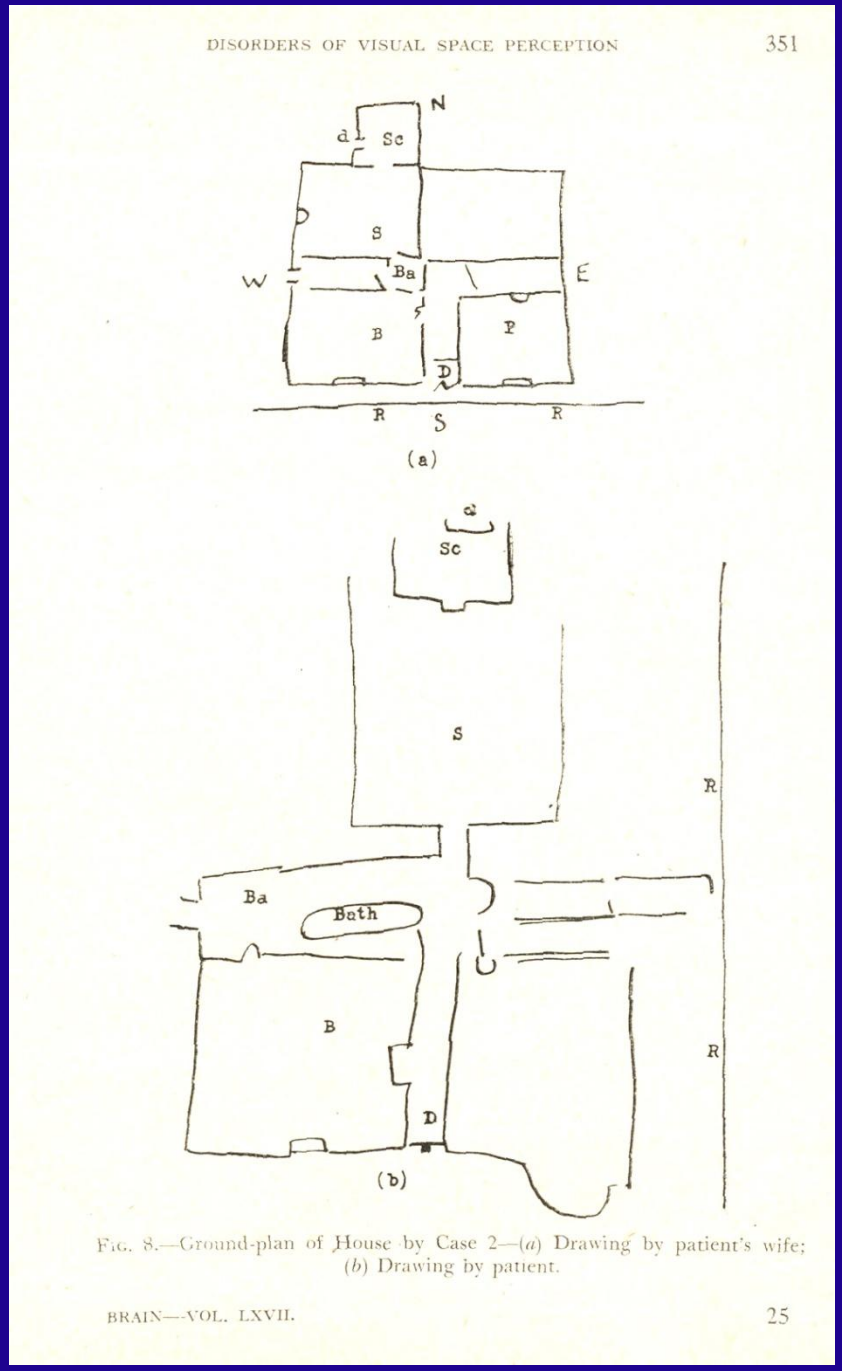

Spatial relationships distorted

Time, sequence, attention and space

Parietal lobe

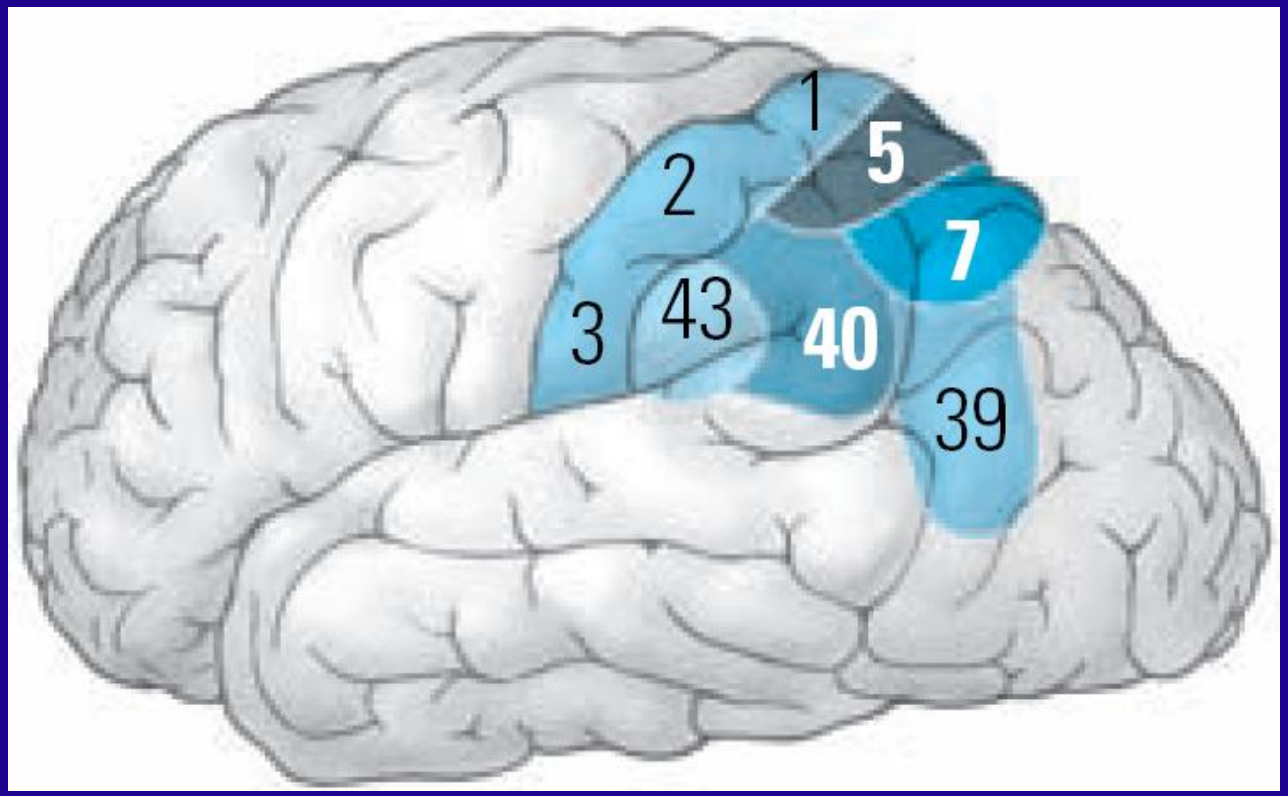

Parietal lobe

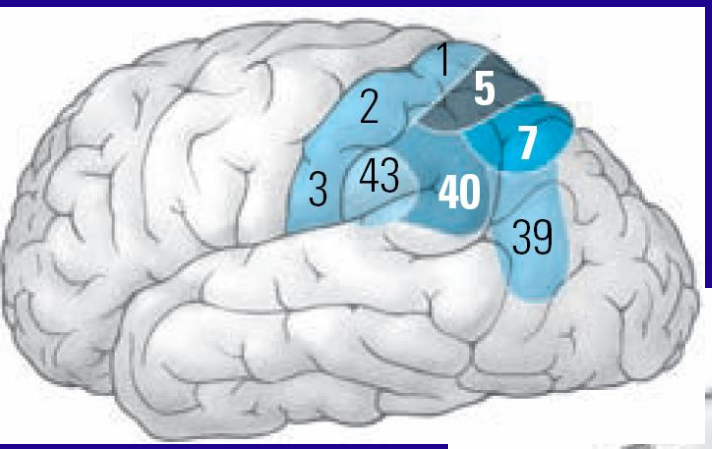

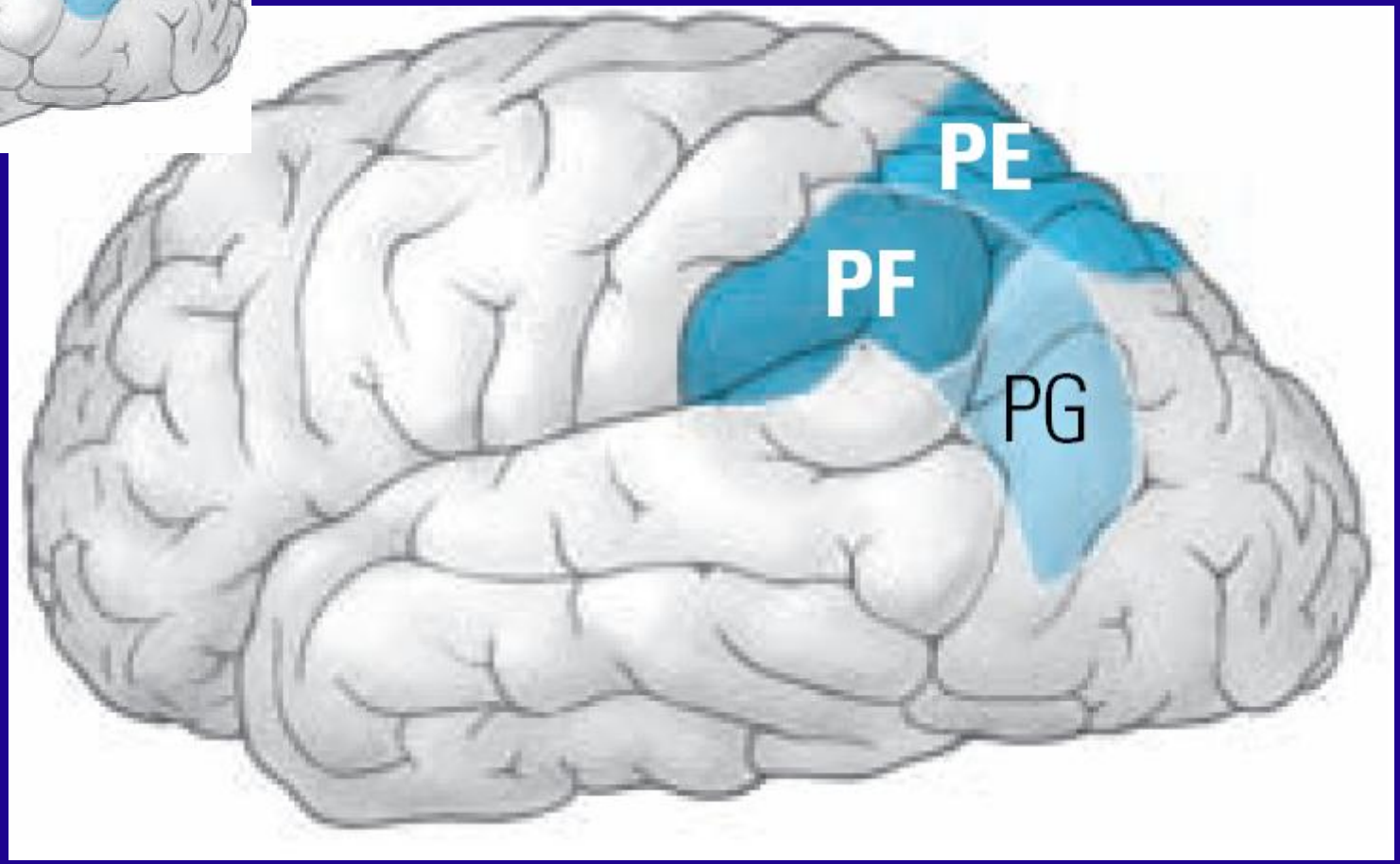

Spatial Information

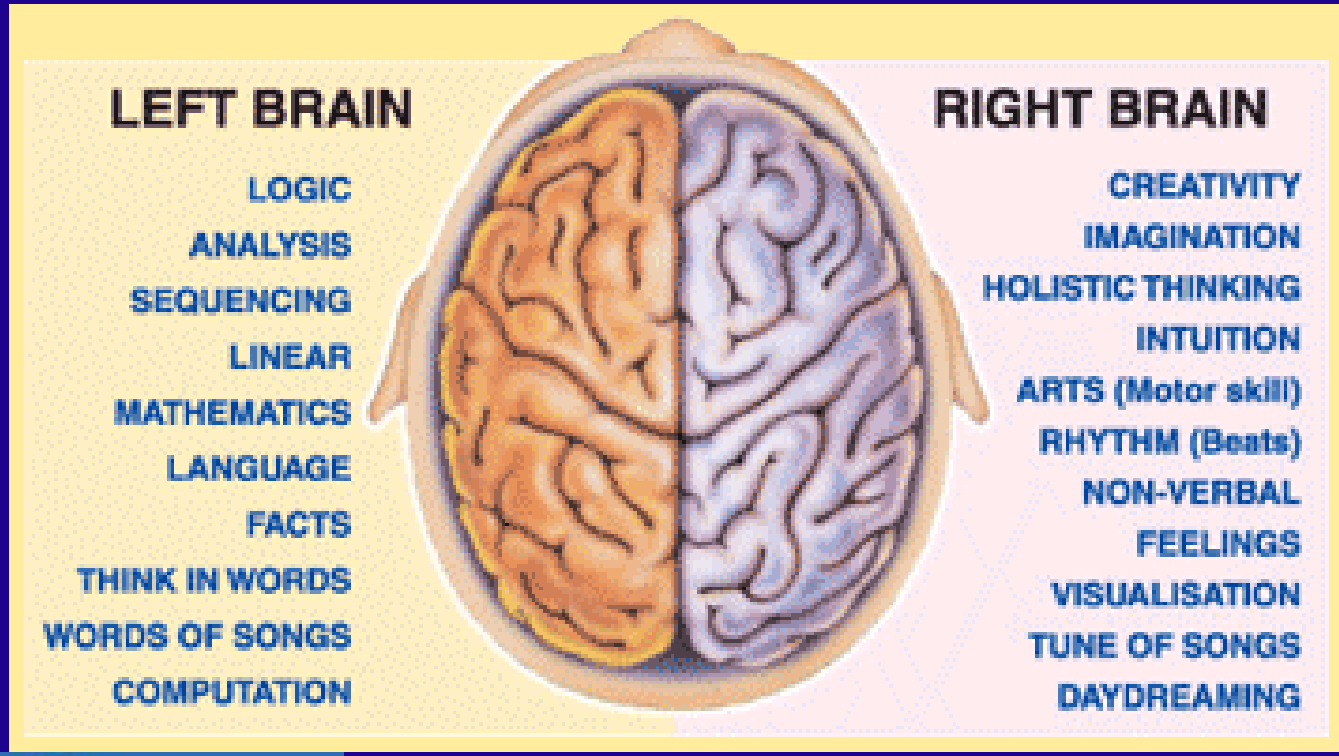
LEFT BRAIN
LOGIC
ANALYSIS
SEQUENCING
LINEAR
MATHEMATICS
LANGUAGE
FACTS
THINK IN WORDS
WORDS OF SONGS
COMPUTATION
RIGHT BRAIN
CREATIVITY
IMAGINATION
HOLISTIC THINKING
INTUITION
ARTS (Motor skill)
RHYTHM (Beats)
NON-VERBAL
FEELINGS
VISUALISATION
TUNE OF SONGS
DAYDREAMING



Object Recognition

Visual Attention Center

In humans, functional brain imaging shows that the *right parietal lobe* of normal subjects is highly active during tasks requiring attention.

(A) Attending to the left visual field

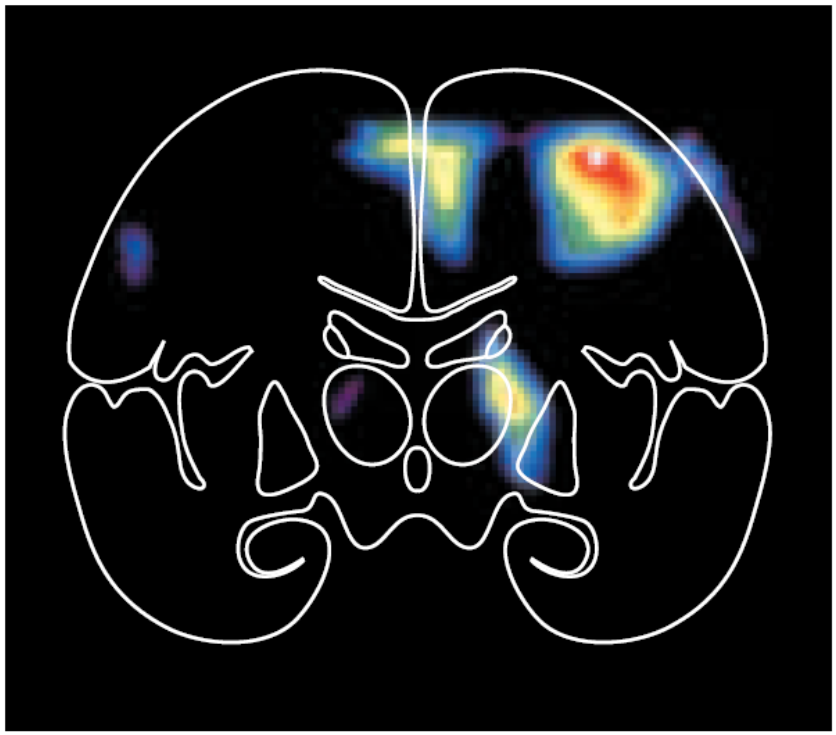

(B) Attending to the right visual field

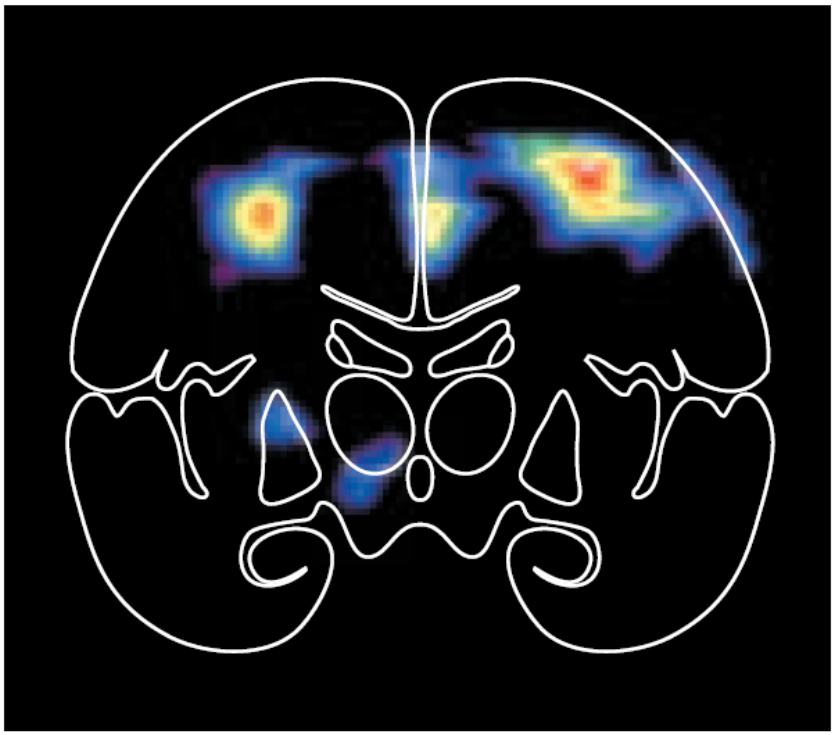

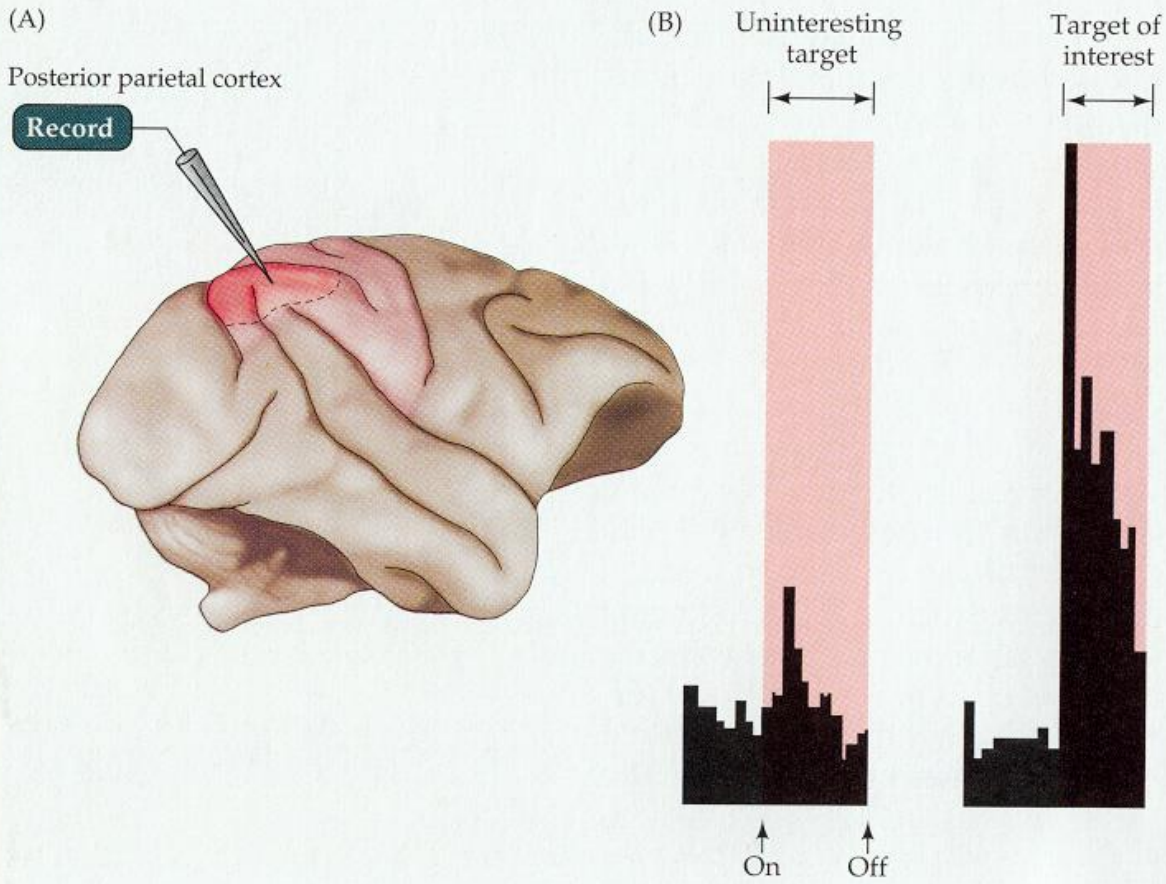

Figure 26.10 Selective activation of neurons in the parietal cortex of a rhesus monkey during the fixation of a significant visual target (in this case, a spot of light associated with a food reward). (A) Region of recording. (B) Although the baseline level of activity of the neuron being studied here changes little in response to an uninteresting target (left), it increases its firing rate tenfold during eye fixation on a target of interest (right). The histograms indicate action potential frequency per unit time. (After Lynch et al., 1977.)

(from Lynch, Mountcastle, Talbot, and Yin, *Journal of Physiology*, 1977)

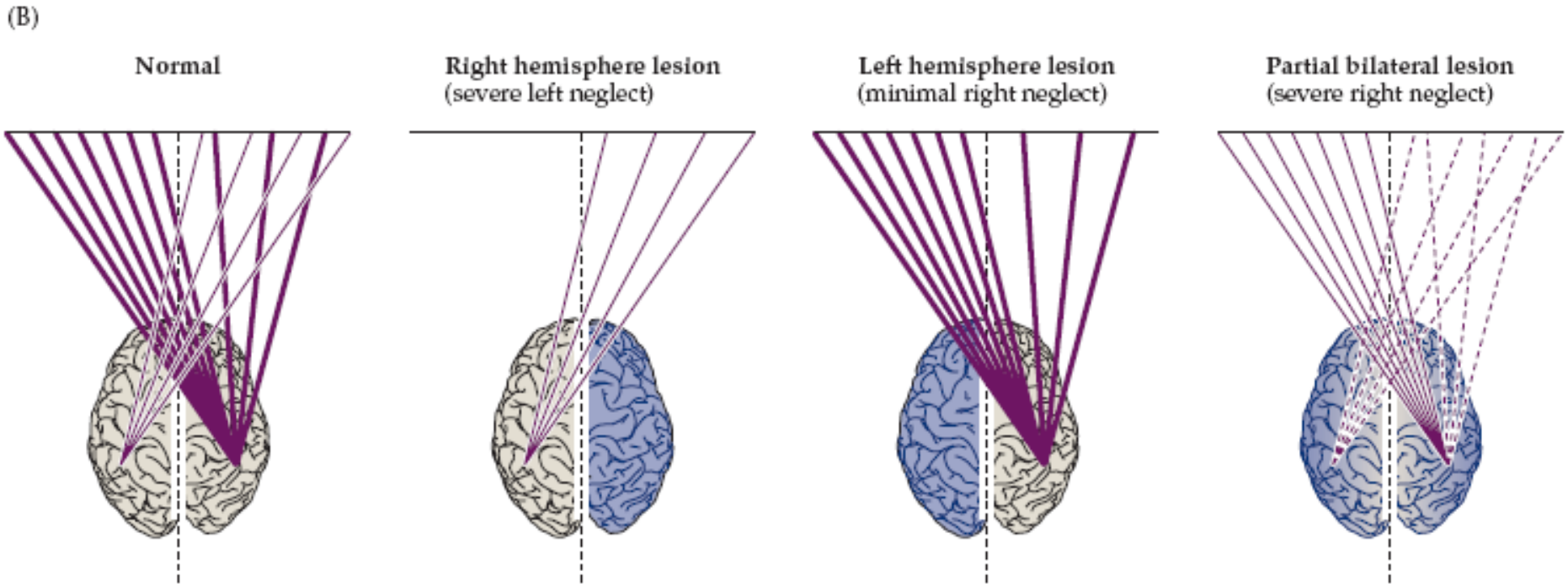
(B)
Normal
Right hemisphere lesion
(severe left neglect)
Left hemisphere lesion
(minimal right neglect)
Partial bilateral lesion
(severe right neglect)

Neglect syndrome

(right parietal association cortex)

The cat ran up the tree to catch a squirrel for his lunch. The squirrel was smart and ran out to the end of a thin branch. The branch broke, but the cat landed on his feet. No fat squirrel for lunch today, No sir!

A

B



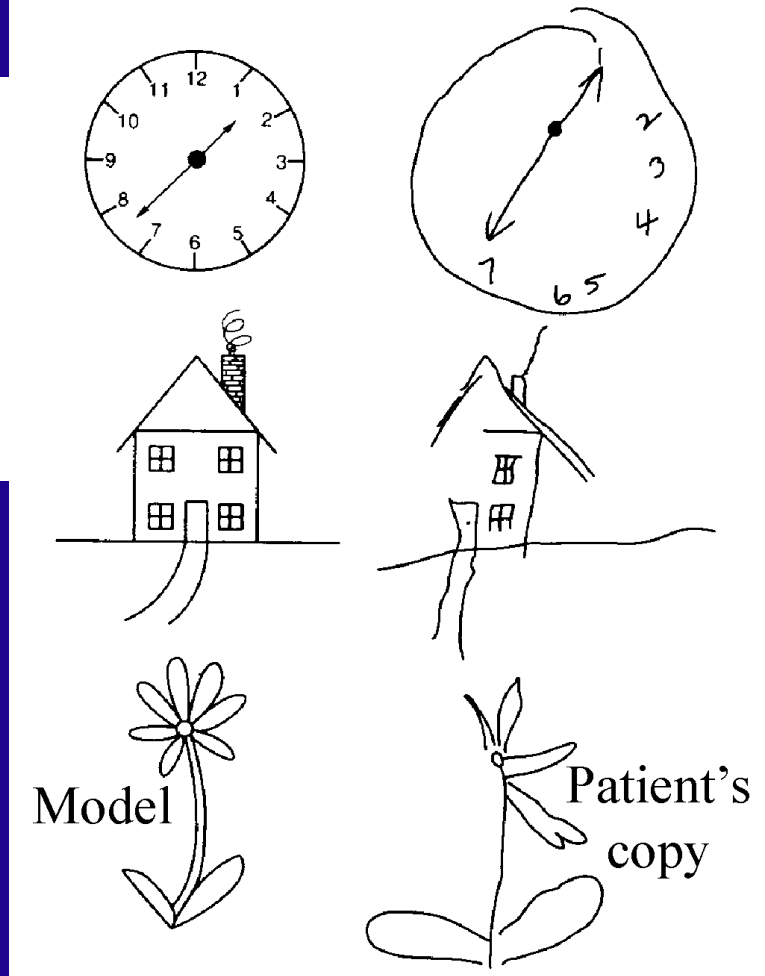

Assembly of "Manikin" Figure by Case 2. A. Correct Assembly. B. Assembly by Patient.


AR-
AR

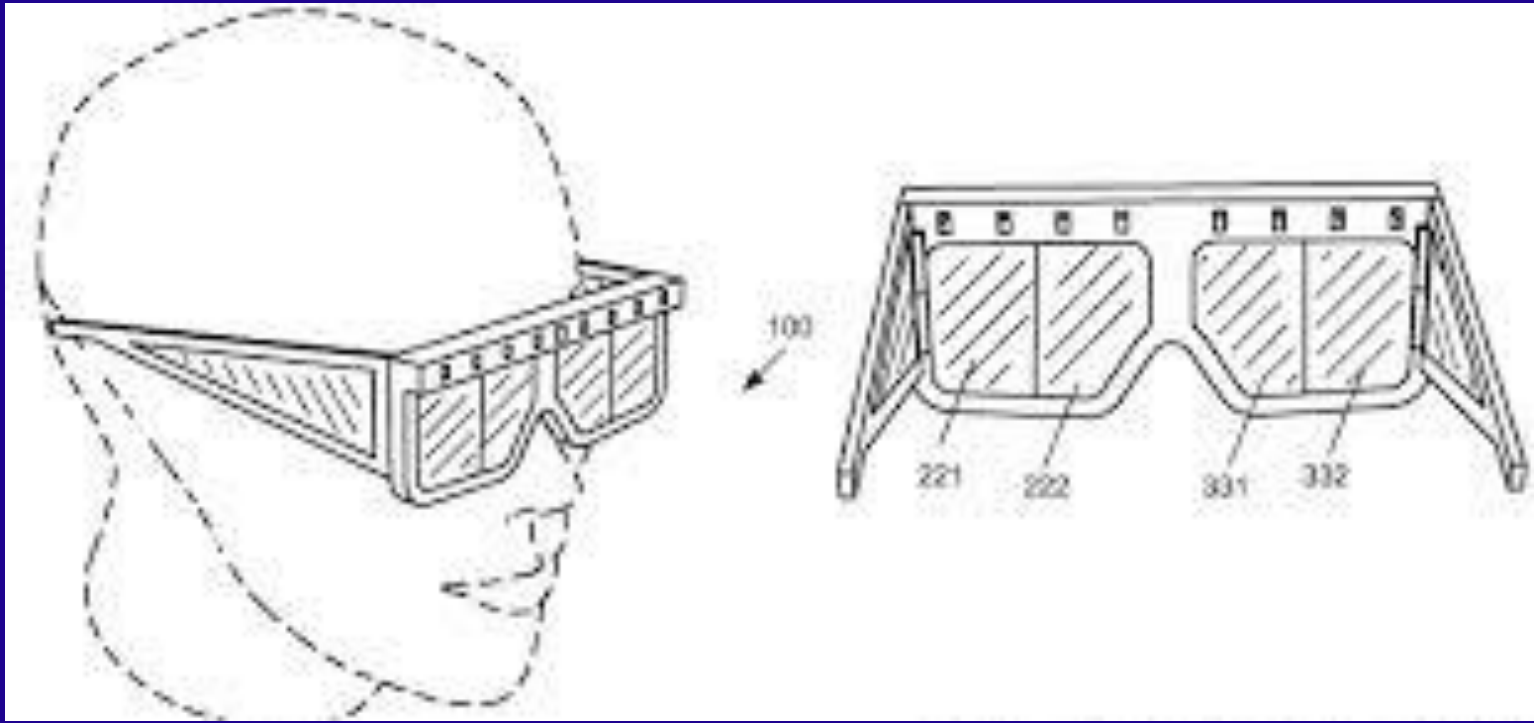
100
221
222
331
332

- Anosognosia
  - Unawareness or denial of illness

Left parietal

Parietal lobe

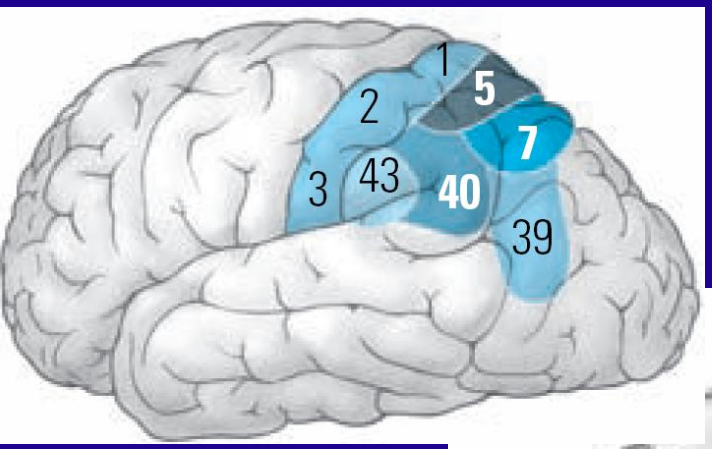

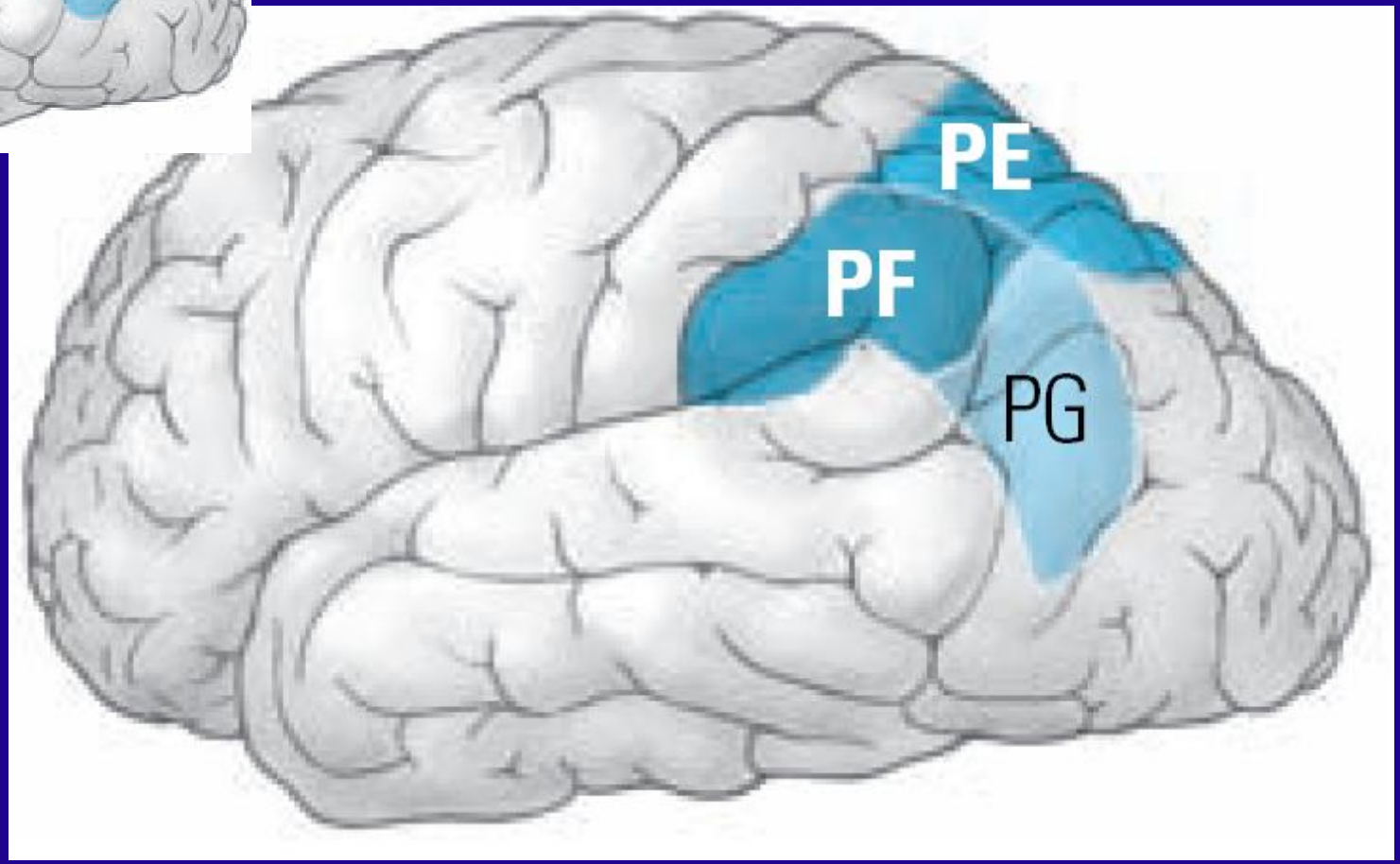

- Acalculia
- Language
- Agraphia
- Apraxia

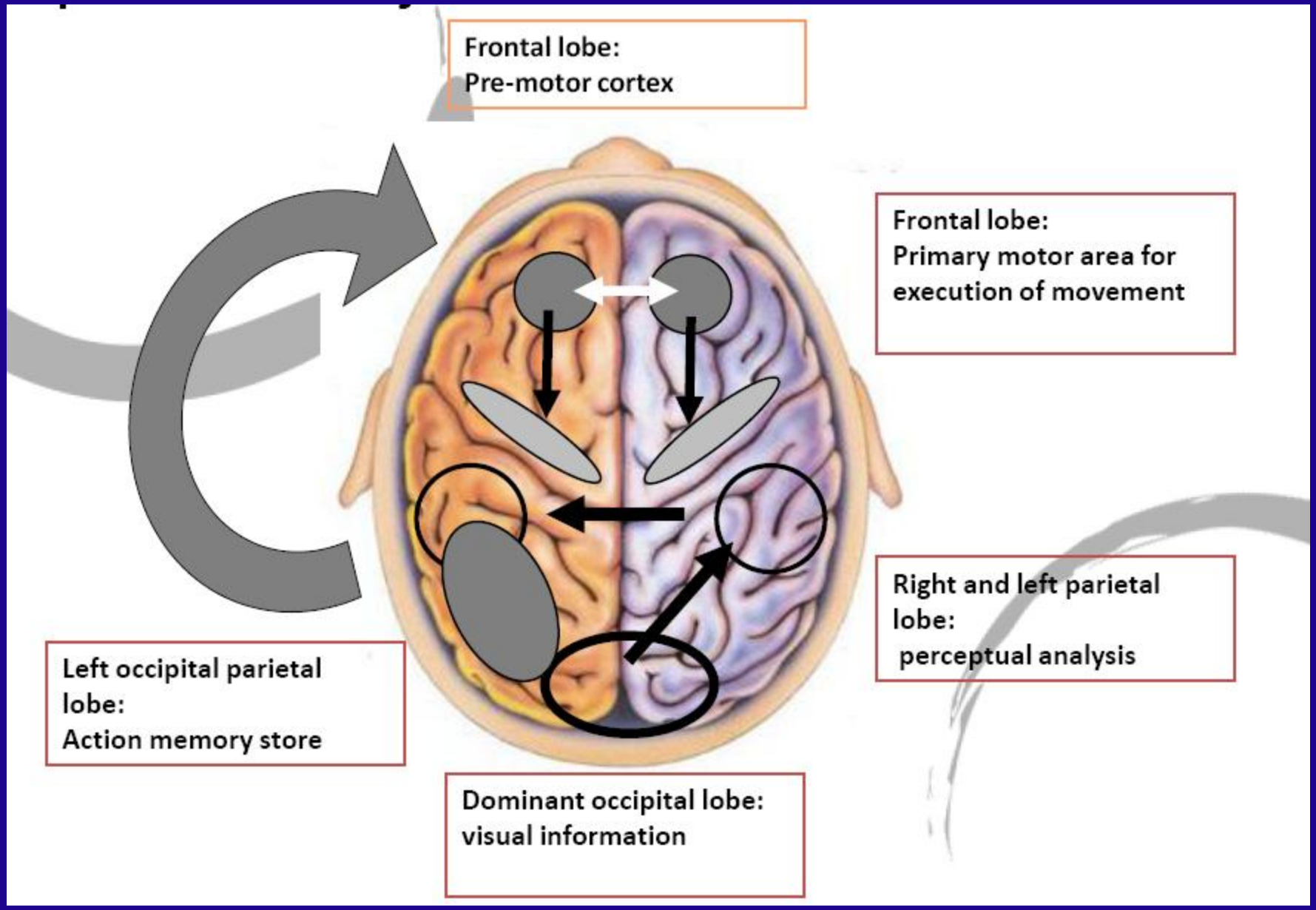
Frontal lobe:
Pre-motor cortex
Frontal lobe:
Primary motor area for execution of movement
Right and left parietal lobe:
perceptual analysis
Left occipital parietal lobe:
Action memory store
Dominant occipital lobe:
visual information

Bilateral Parietal Damage (Balint's Syndrome)

- Impaired control over the focus of visual attention due to inattentional amnesia
- Complex defects in perception of visual object structure, motion and depth.
- Neglect (hemifield)

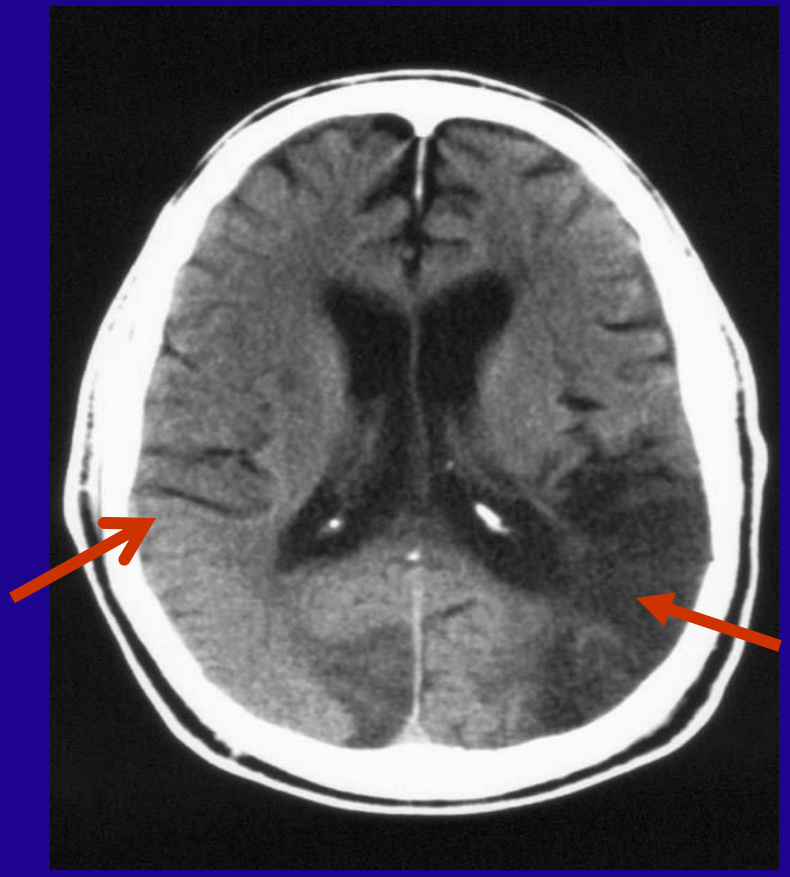

Bilateral Parietal Damage (Balint's Syndrome)

- **SIMULTANAGNOSIA :** Inability to interpret the totality of a picture scene (can identify individual portions of the whole picture)

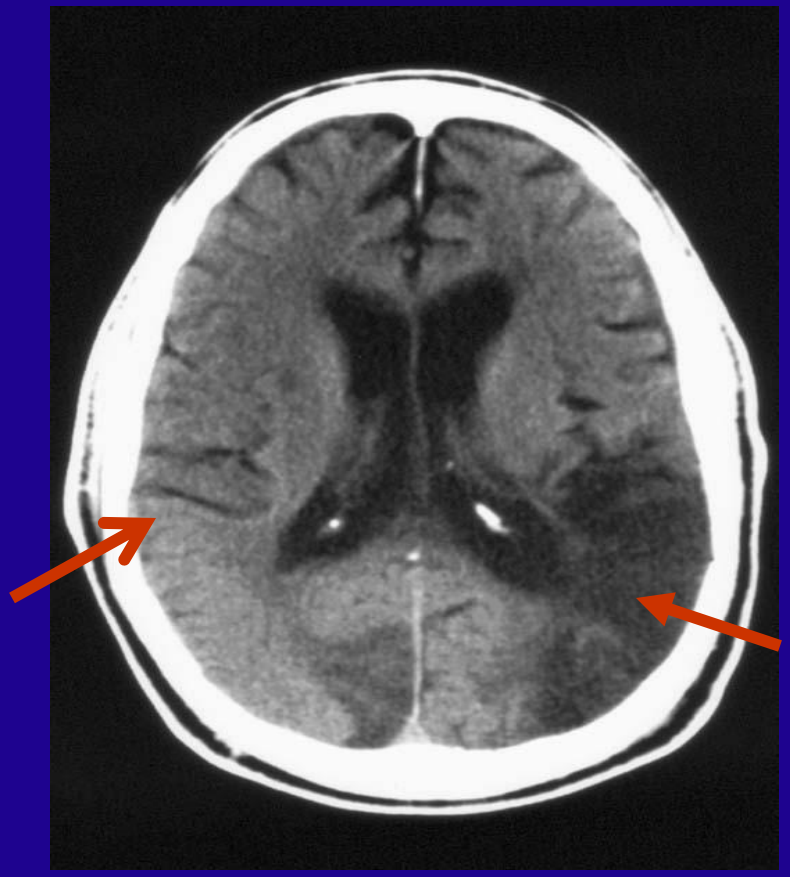

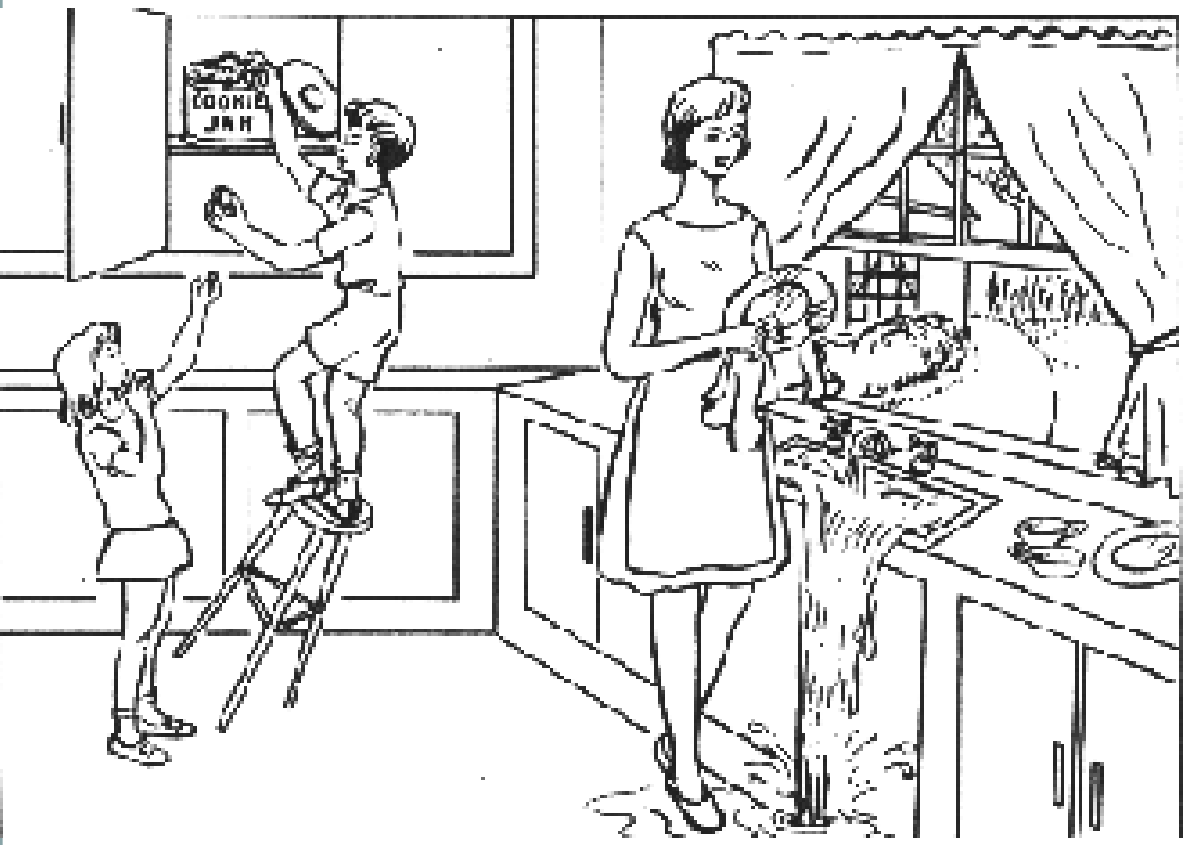


```
T T T       T T T
T T T       T T T
T T T       T T T
T T T T T   T T T
T T T T T   T T T
T T T T T   T T T
T T T       T T T
T T T       T T T
T T T       T T T
T T T       T T T
```

Bilateral Parietal Damage (Balint's Syndrome)

- **Simultanagnosia:** Inability to interpret the totality of a picture scene (can identify individual portions of the whole picture)
- **Optic ataxia:** Defects of visually guided hand movement

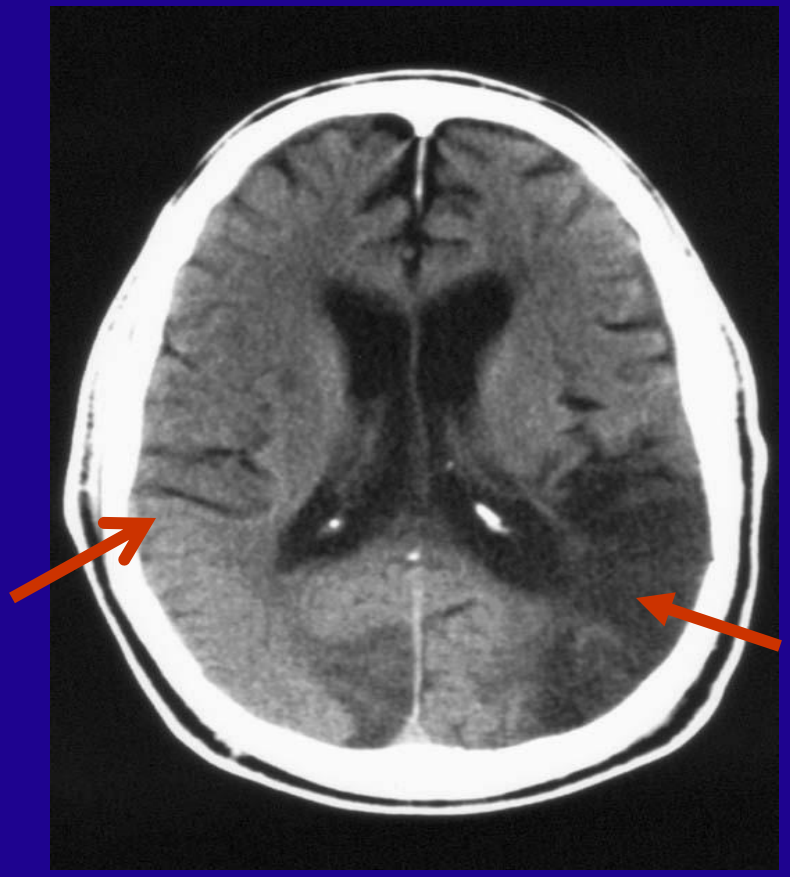

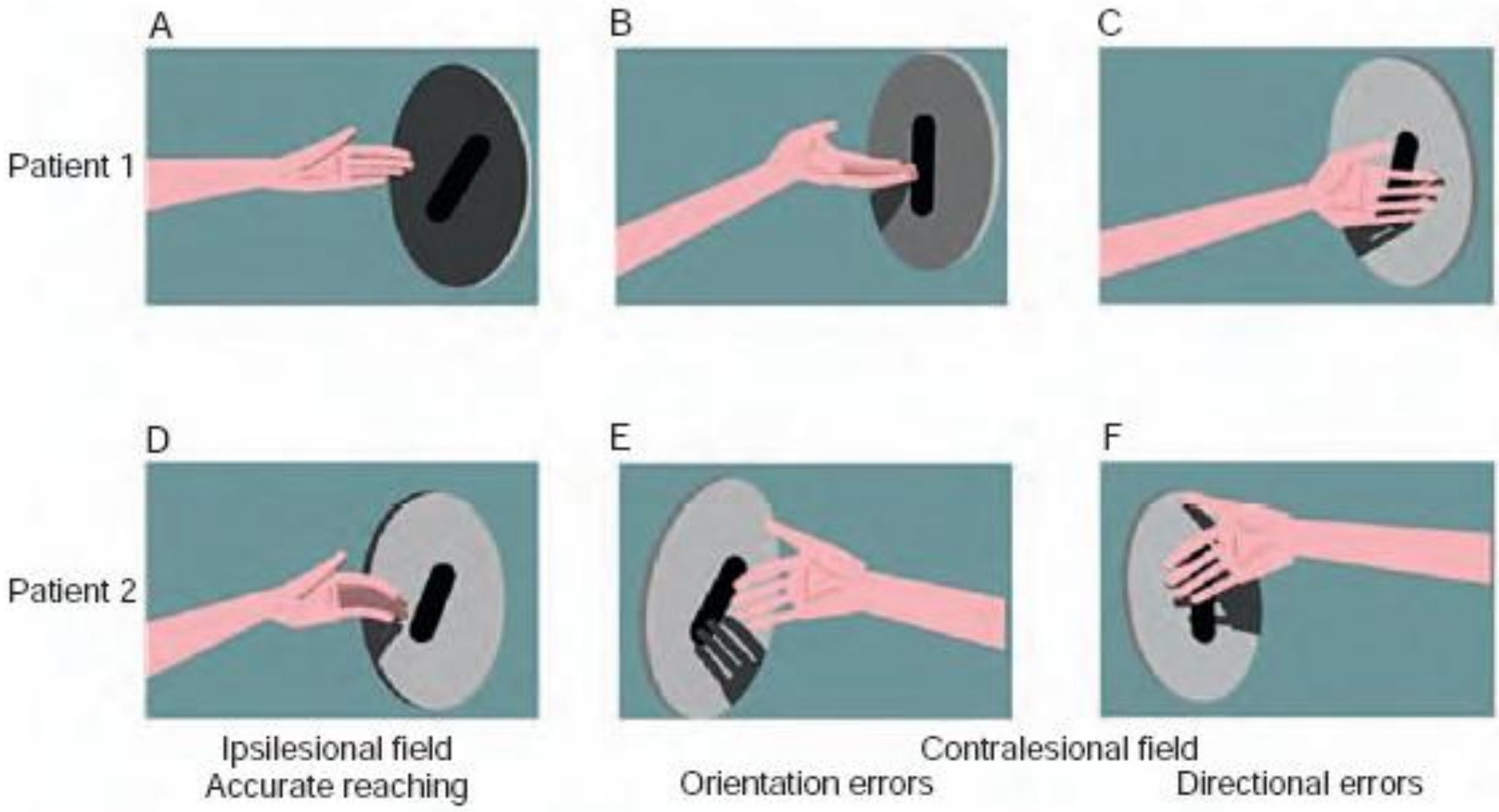
A
B
C
Patient 1
D
E
F
Patient 2
Ipsilesional field
Accurate reaching
Contralesional field
Orientation errors
Directional errors

Parietal Cortex Damage (1)

Damage to the parietal cortex often results in low performance in spatial tasks, most often poor visuo-motor control. Some patients with *optic ataxia* have no difficulty identifying an object, but their visually guided behavior is so impaired that they cannot grasp it properly!

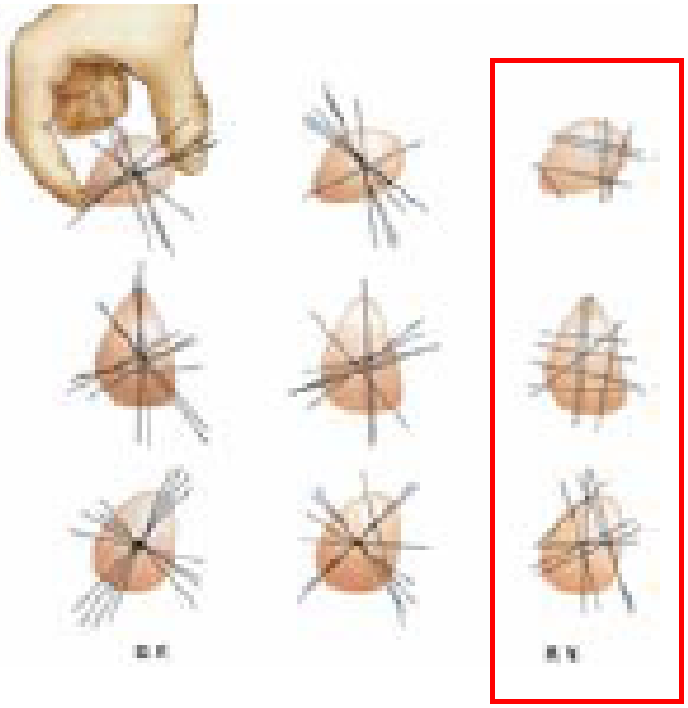

Temporal Cortex Damage

Nevertheless, the visually guided behavior of patients with *agnosia* is preserved. Thus, agnosic patients have difficulty identifying an object, but they can grasp and manipulate it.

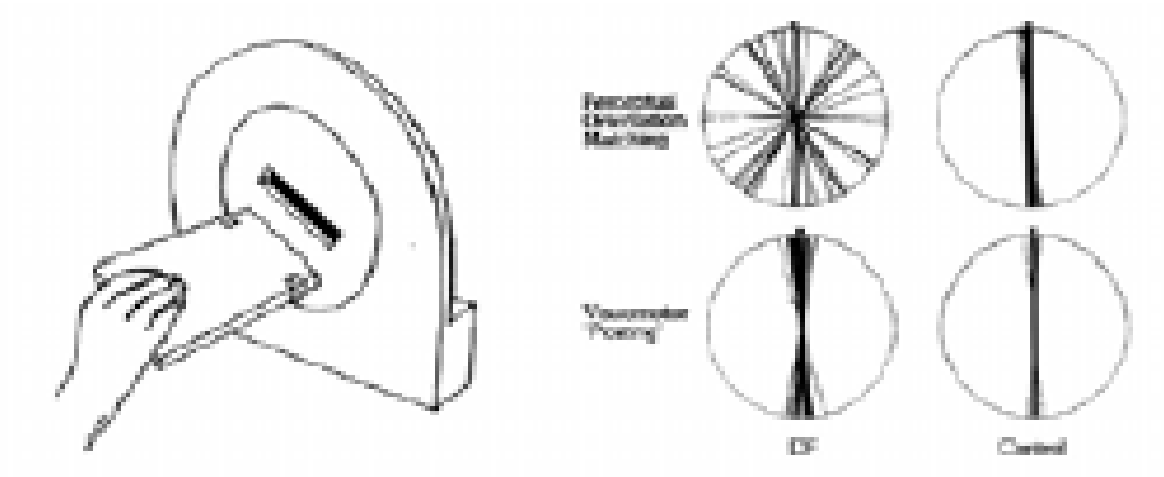

Bilateral Parietal Damage (Balint's Syndrome)

- **Simultanagnosia:** Inability to interpret the totality of a picture scene (can identify individual portions of the whole picture)
- **Optic ataxia:** Defects of visually guided hand movement
- **Ocular apraxia:** Inability to voluntarily move eyes to objects of interest (difficulty volitionally redirecting gaze

language

Passively viewing words

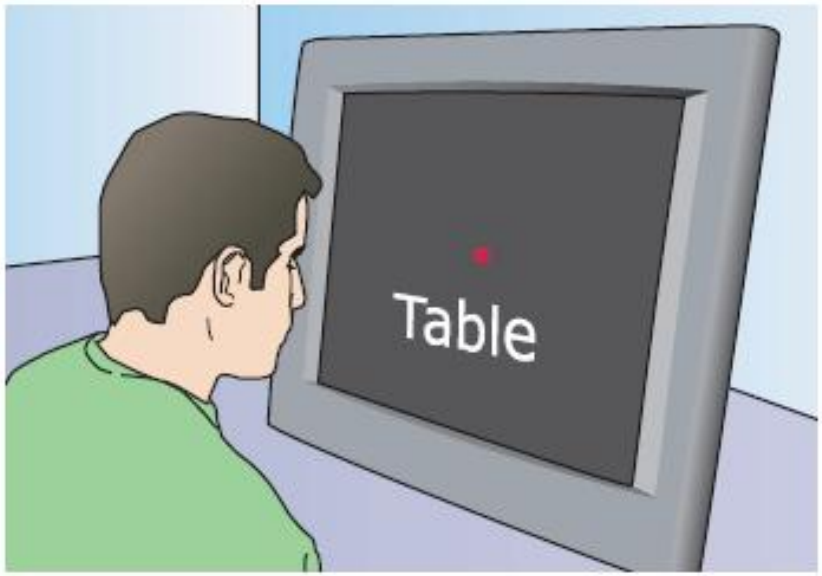

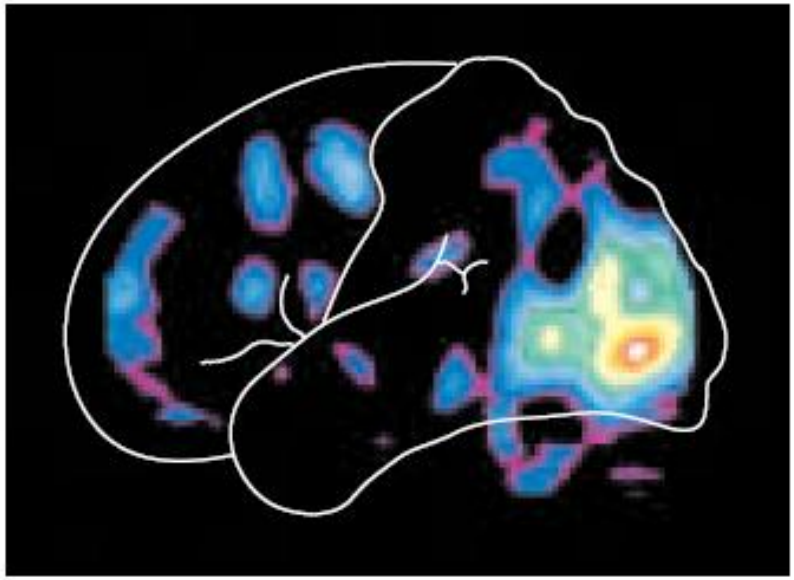

Listening to words

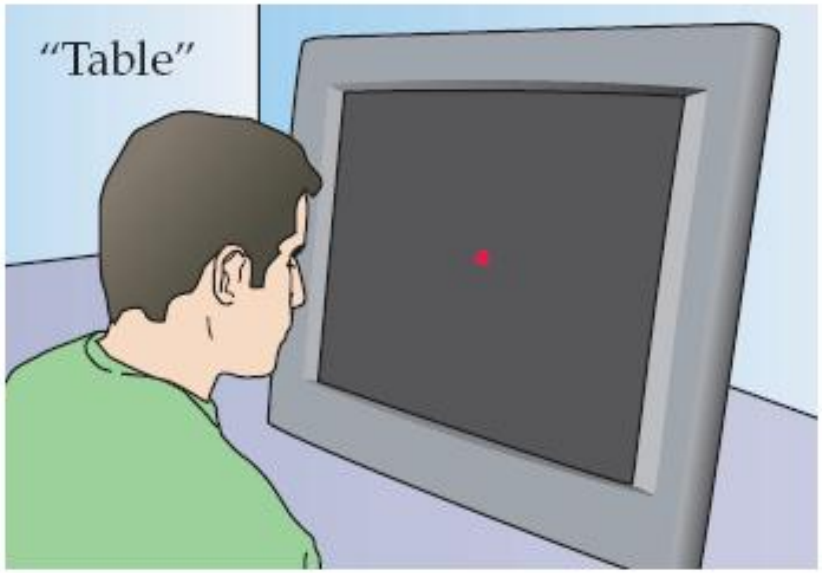

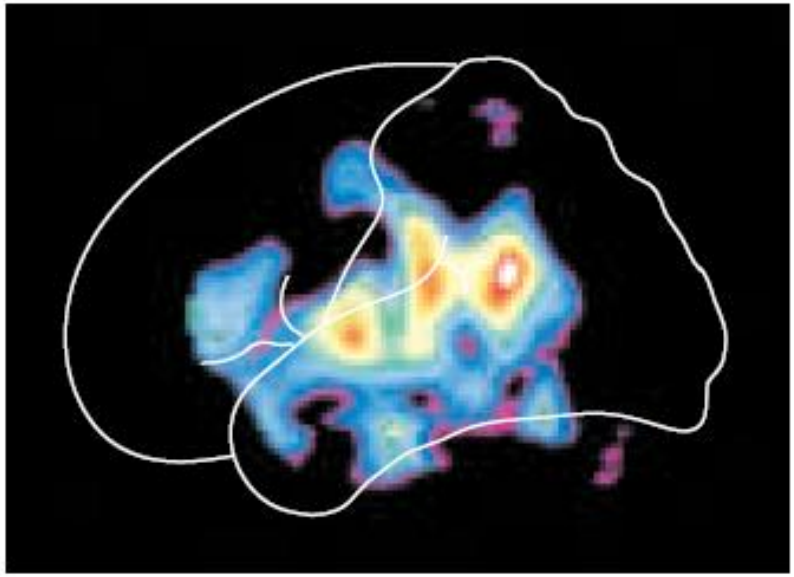

Speaking words

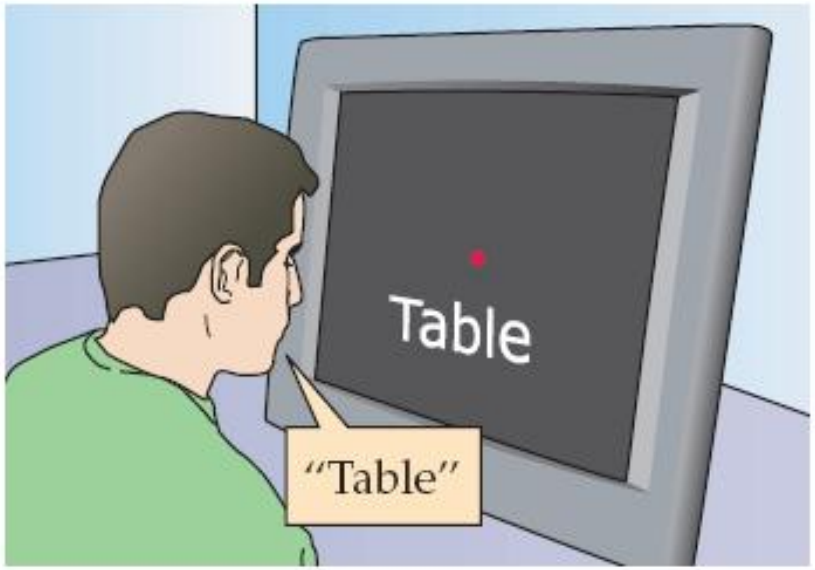

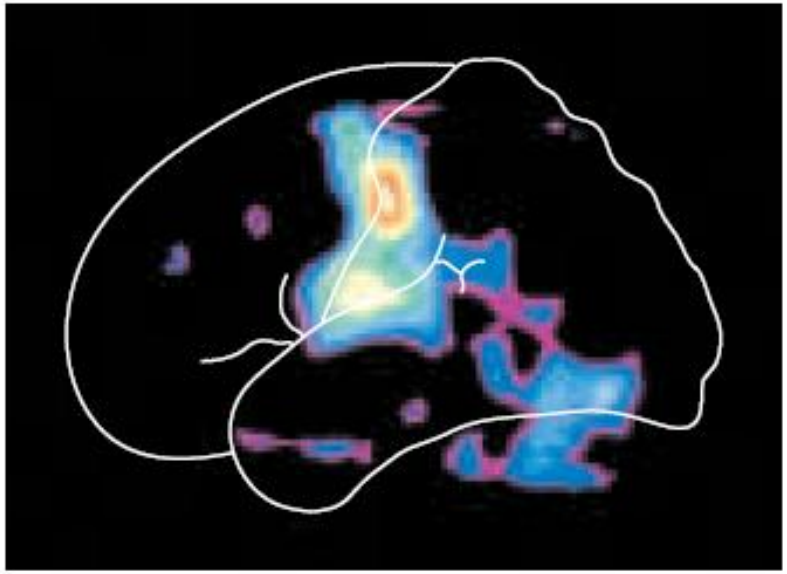

Generating word associations

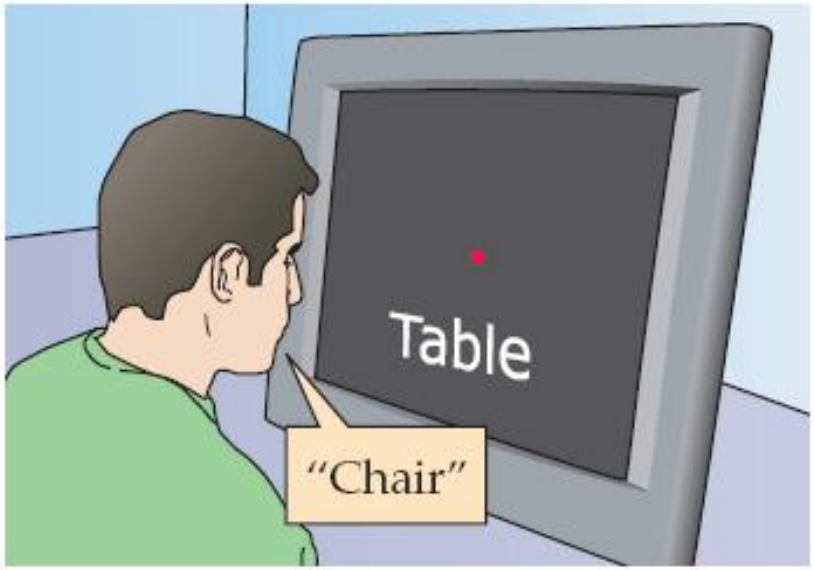

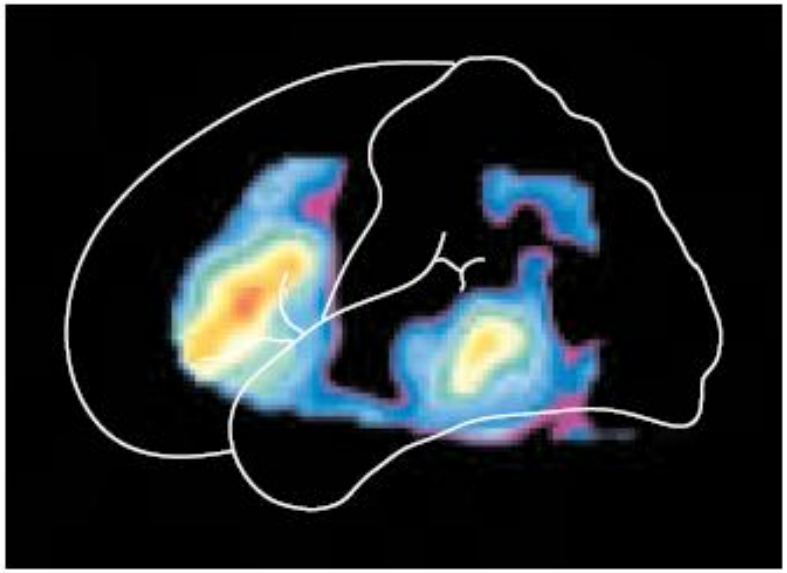

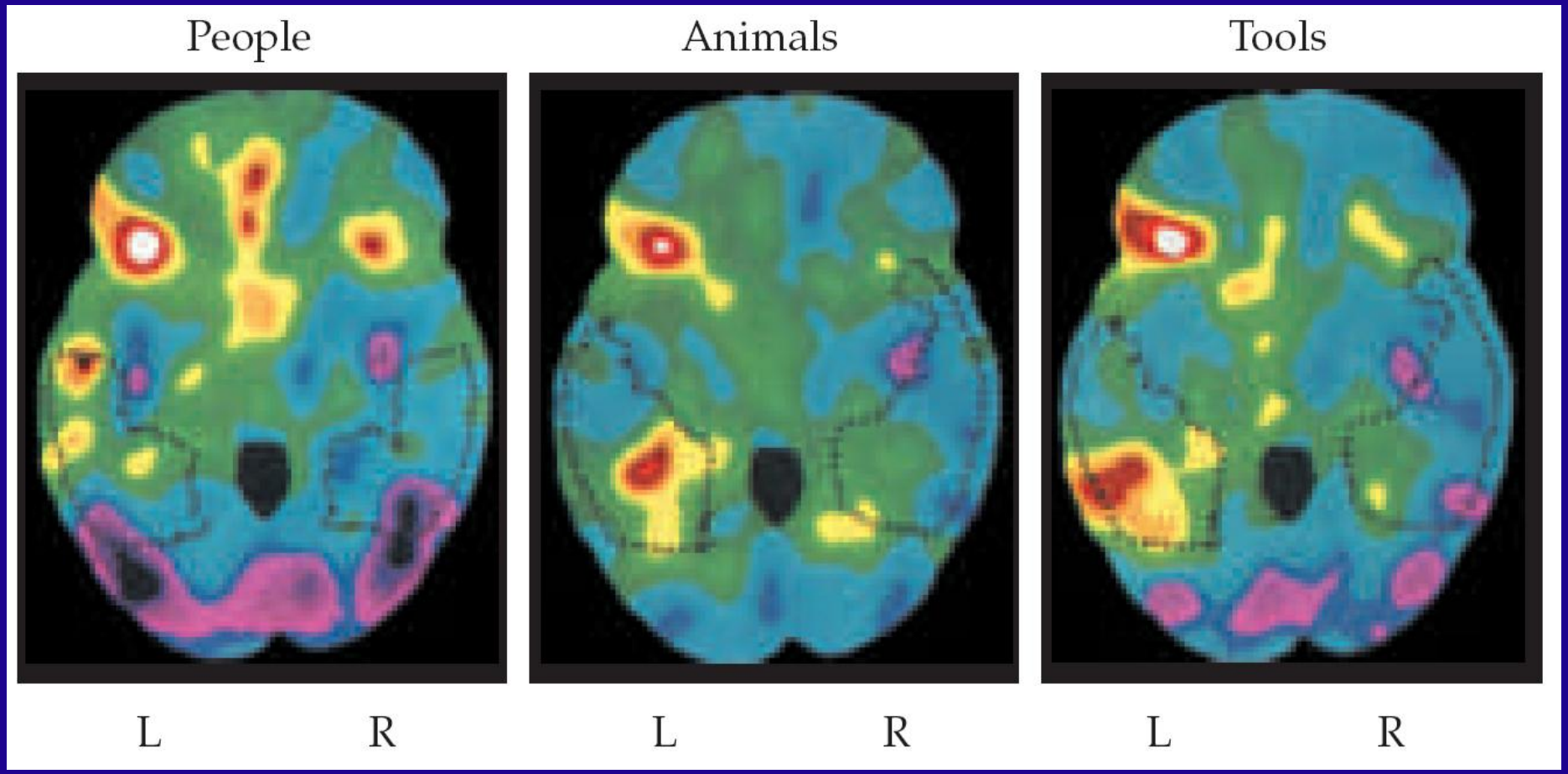
People
Animals
Tools
L
R
L
R
L
R


High
Level of activity
Low

language

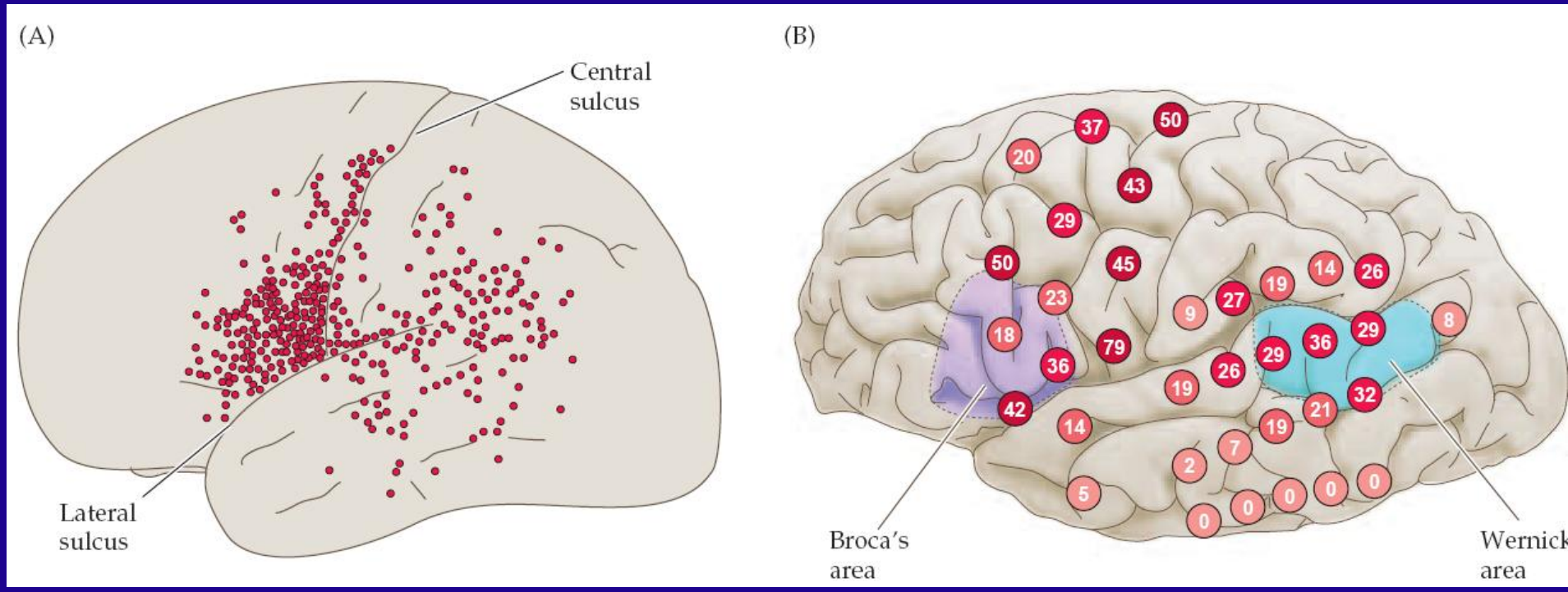

117

the implementation system

the mediation system

the conceptual system

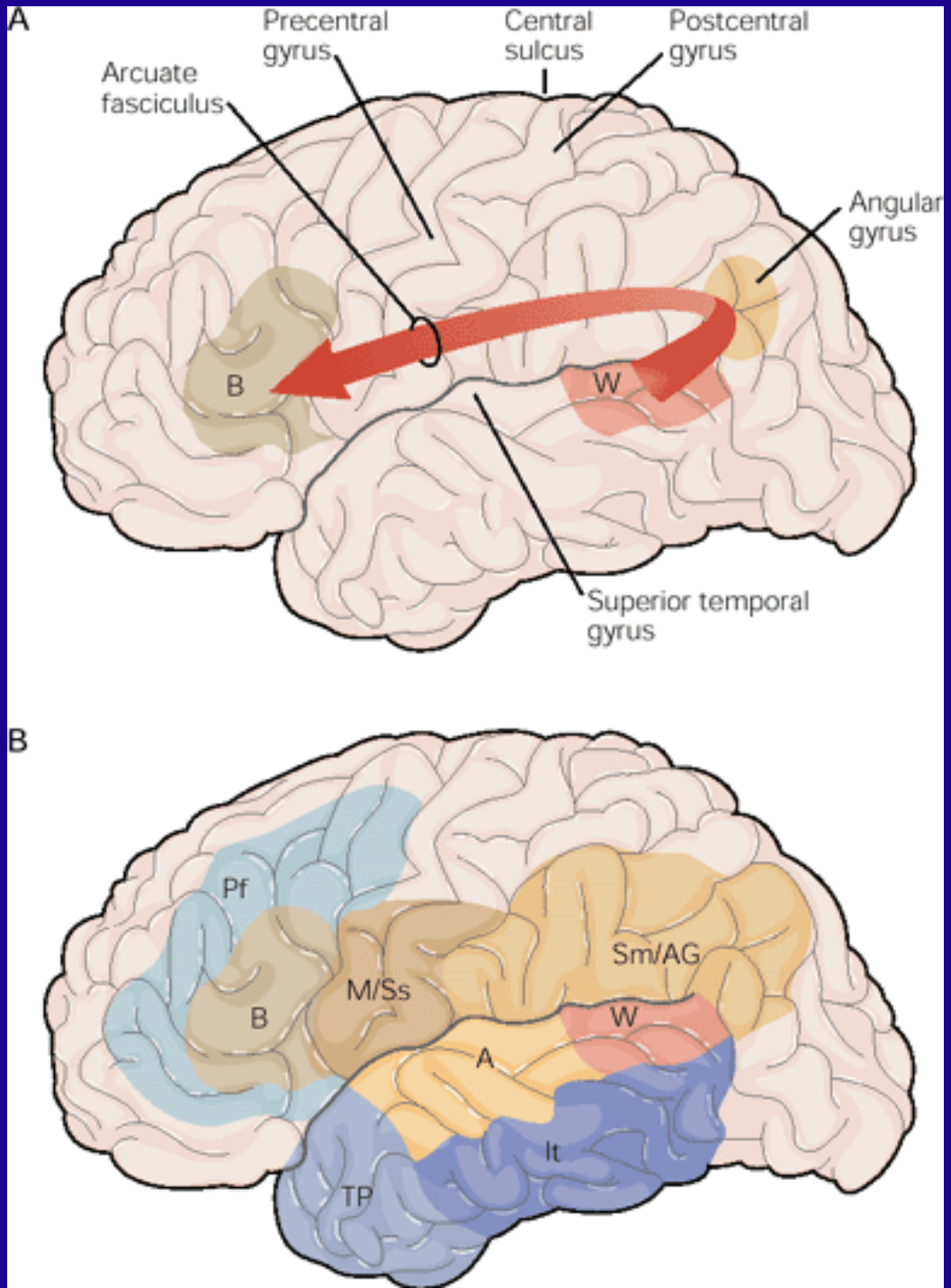

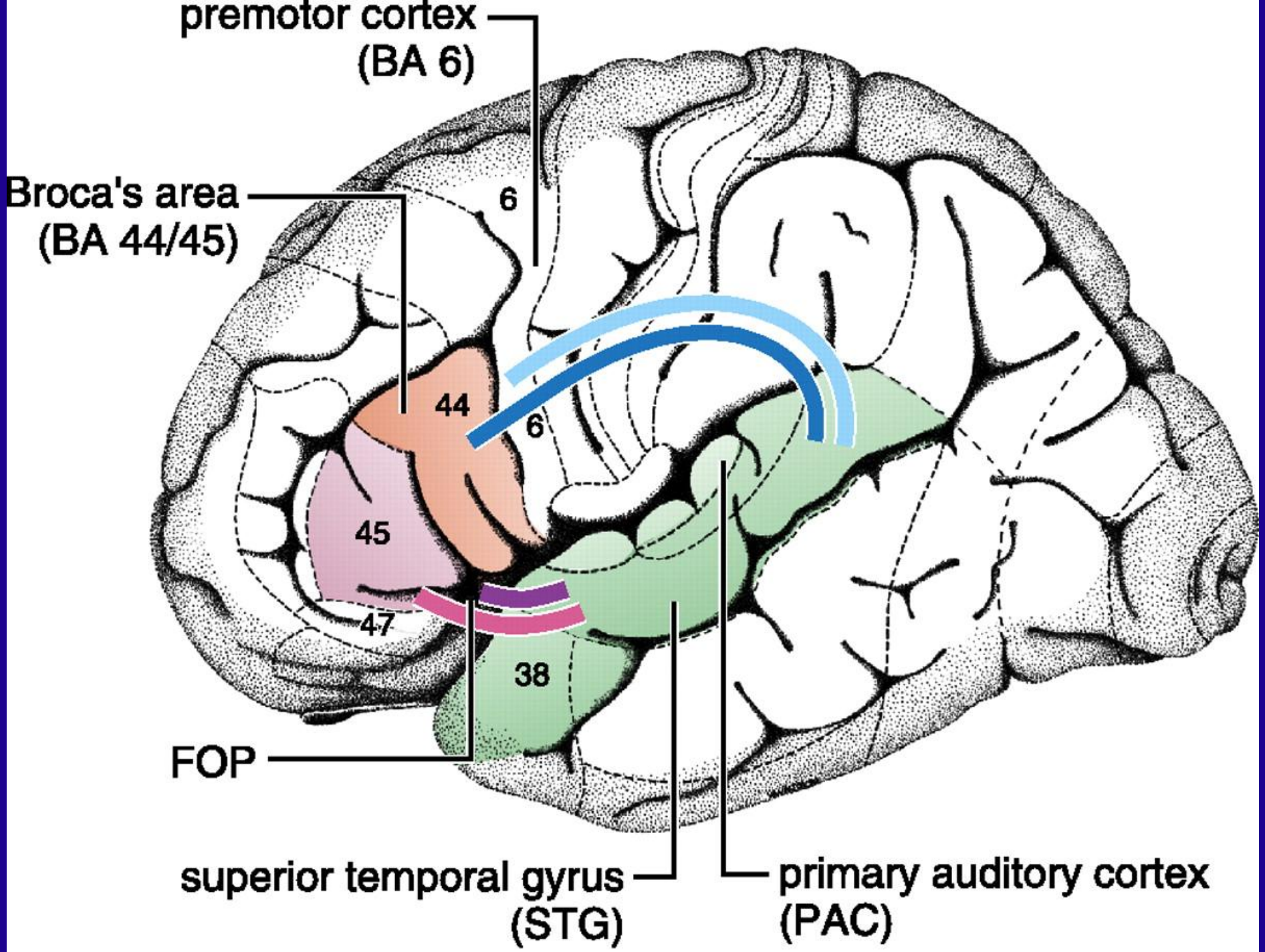
premotor cortex
(BA 6)
Broca's area
(BA 44/45)
6
44
6
45
47
38
FOP
superior temporal gyrus
(STG)
primary auditory cortex
(PAC)

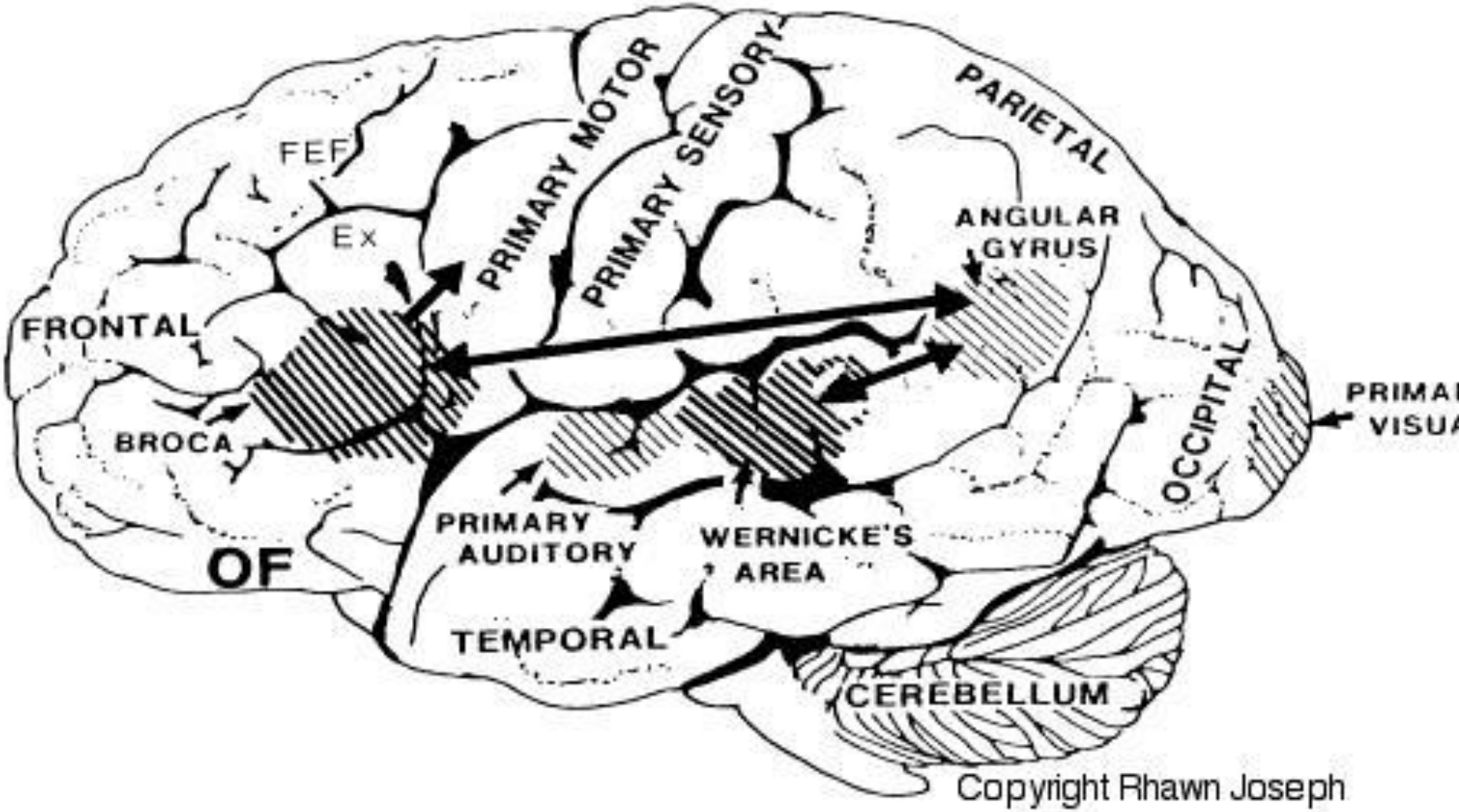
FEF
Ex
PRIMARY MOTOR
PRIMARY SENSORY
PARIETAL
ANGULAR GYRUS
FRONTAL
BROCA
OF
PRIMARY AUDITORY
WERNICKE'S AREA
TEMPORAL
OCCIPITAL
CEREBELLUM
Copyright Rhawn Joseph



Paul Broca
physician, anatomist, anthropologist
1824-1880

L'Hopital Royal de Bicestre
Paris
about 1750

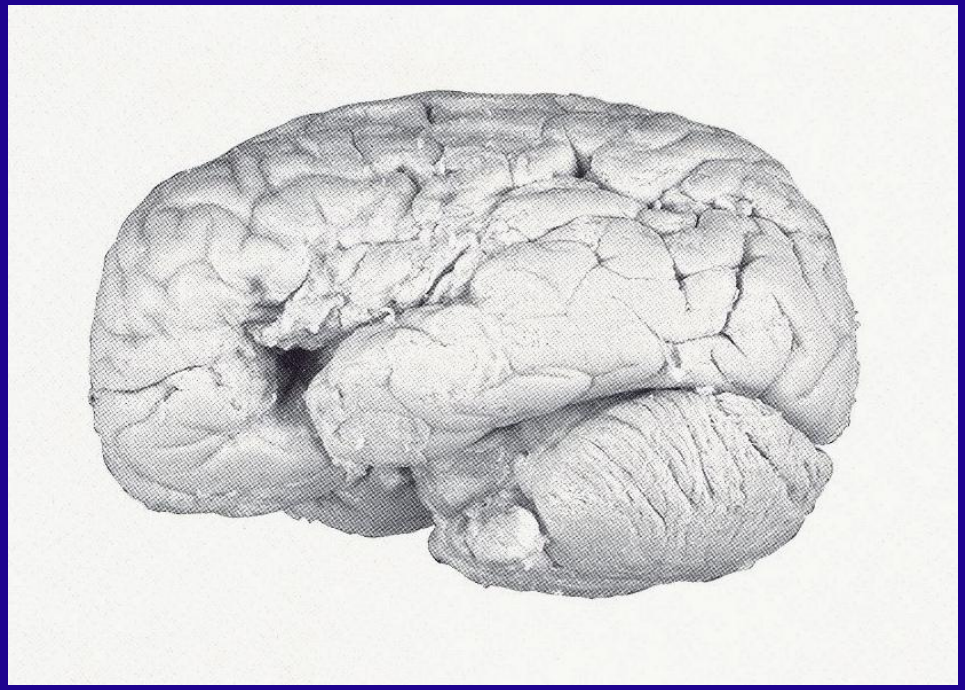

Brain of “Tan” Leborgne
(for the last 20 years of his life,
the only word M. Leborgne could say was “tan”)

Broca Aphasia (Expressive aphasia)

Left hemisphere

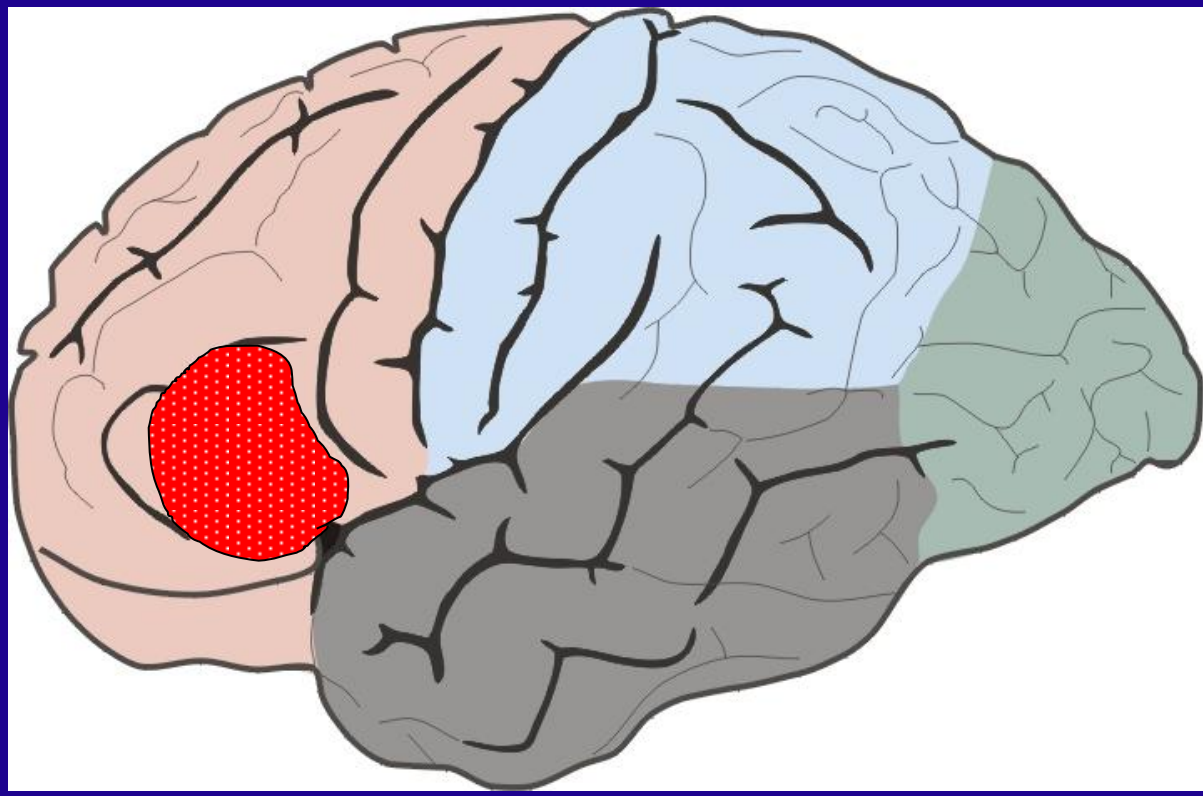

Broca's aphasia - Sarah Scott - teenage stroke

http://www.youtube.com/watch?v=1aplTvEQ6ew

Wernicke Aphasia (Receptive aphasia)

Left hemisphere

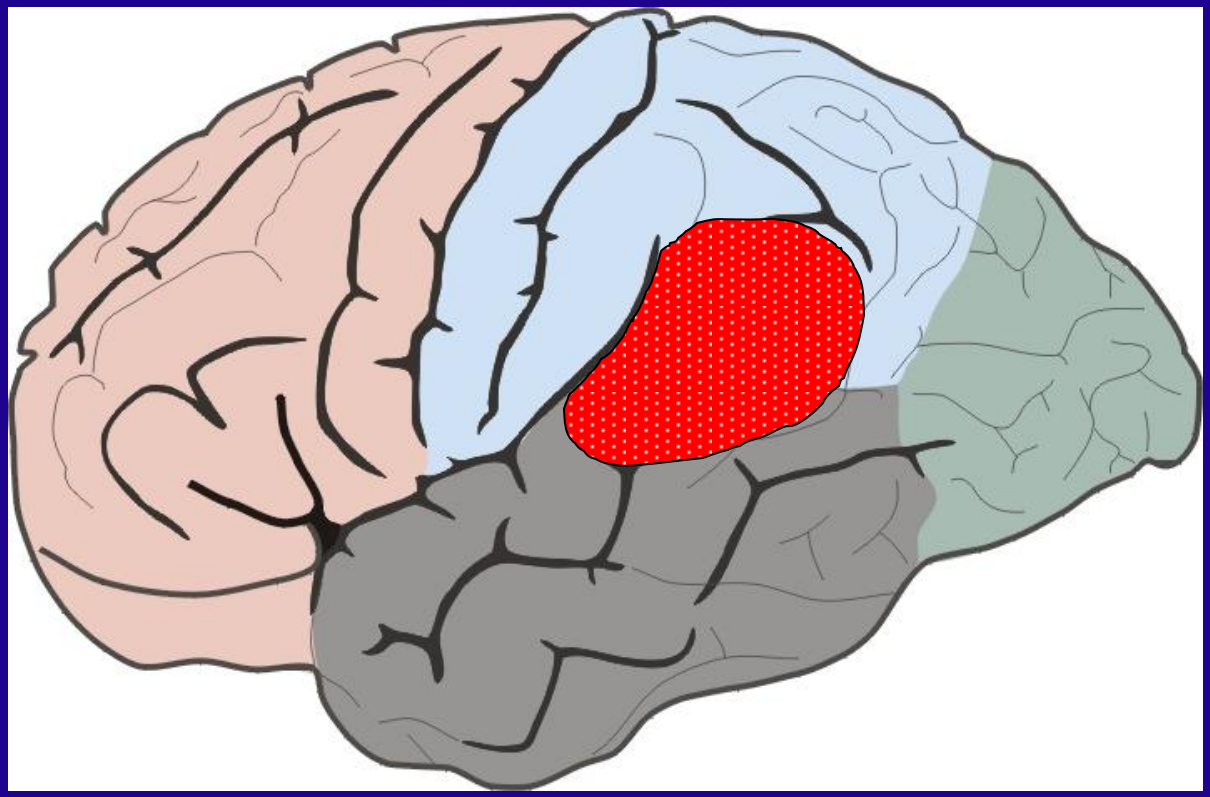

Wernicke's Aphasia Interview with Amelia Carter

http://www.youtube.com/watch?v=UtadyCc_ybo

(right hemisphere)

Prosody of speech

(right hemisphere)

Broca Aphasia (Expressive aphasia)

Left hemisphere

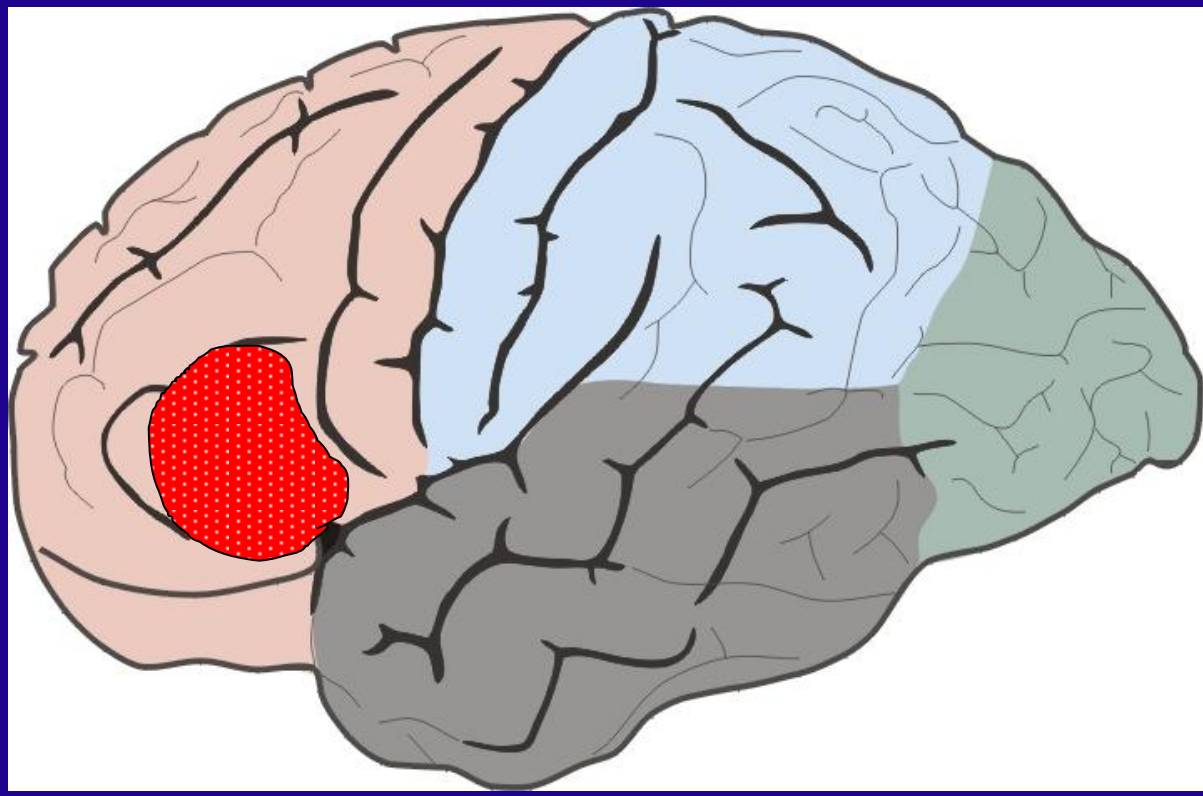

Broca's aphasia - Sarah Scott - teenage stroke

http://www.youtube.com/watch?v=1aplTvEQ6ew

Wernicke Aphasia (Receptive aphasia)

Left hemisphere

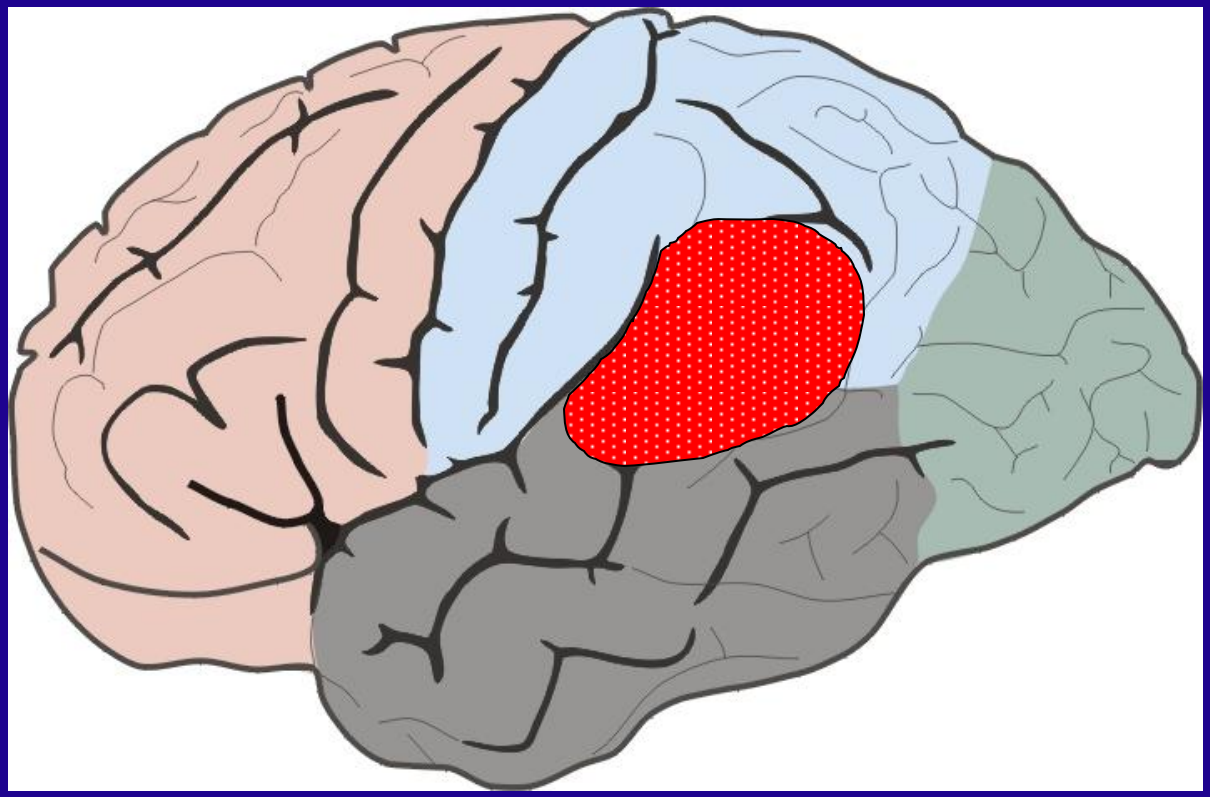

Wernicke's Aphasia Interview with Amelia Carter

http://www.youtube.com/watch?v=UtadyCc_ybo

Pay attention to

- Drugs
- Transient problems (CO)
- Chronic problems (alcohol)
- MS
- Degeneration (Alzheimer)