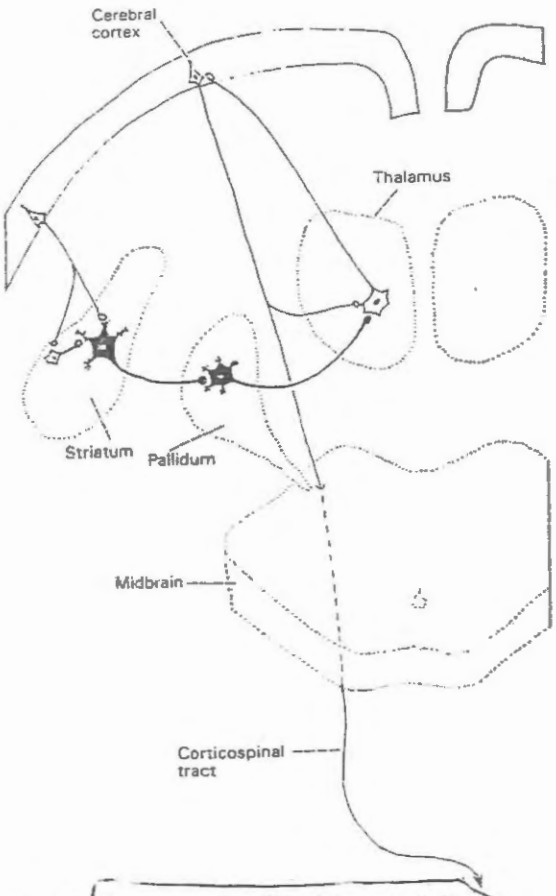


Fig. 18-4 The cortico-strio-pallido-thalamo-cortical loop.

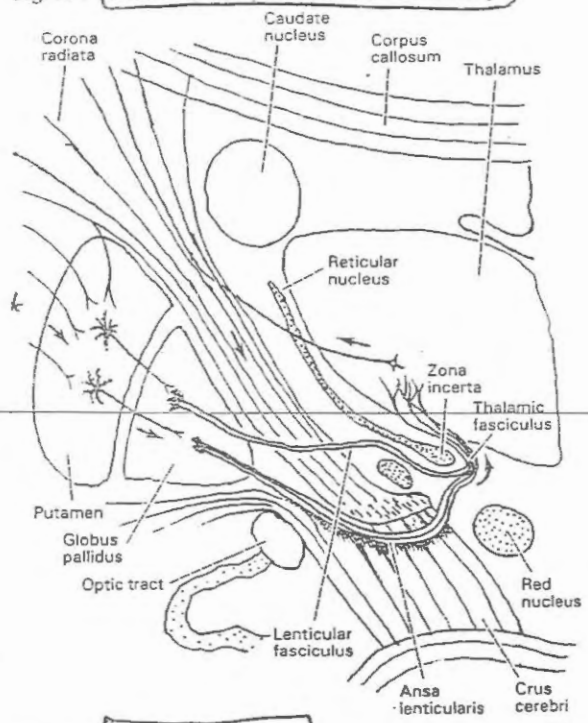


Fig. 18-5 Pallidothalamic fibers.

## Basic circuits

24

1) From all parts of the cerebral cortex axons run into the Striatum (caudate putamen)

Substrate

↓

contains { excitatory cholinergic neurons / inhibitory GABAergic neurons

↓

② The largest projection from the striatum is from inhibitory GABAergic to all parts of the pallidum (and to substantia nigra)

↓

Axons of pallidum run to the thalamus in the pallido-thalamic tract

↓

formed of 2 parts:

→ Ansa lenticularis

→ lenticular fasciculus

⇩

③ Synapse on ventral anterior (VA) and ventral lateral (VL) nuclei of the thalamus (like the striopallidal fibres, the pallido-thalamic fibres are inhibitory and GABAergic

↓ !!! ↕ ??

From VA & VL EXCITATORY fibres run to premotor, supplementary motor & primary motor areas of the cerebral cortex

↙

The motor cortex gives rise to the bulk of the pyramidal tract which generates contralateral movement in response to thalamocortical stimulation

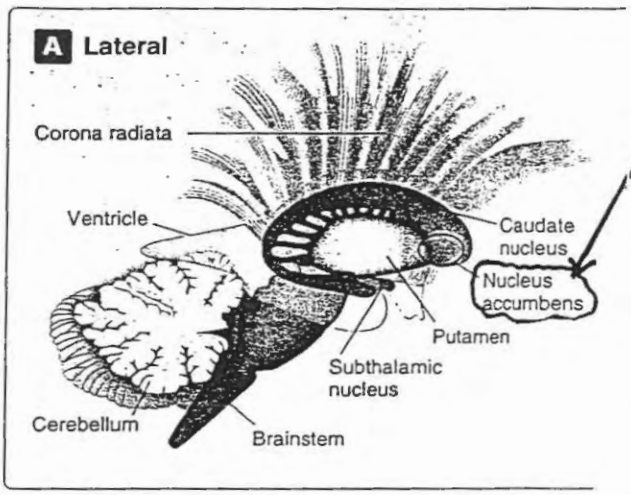


The nucleus accumbens is the anterior & ventral of the Striatum where the head of the caudate & the Putamen are continuous with each other. It receives extensive dopaminergic input and is an integral part of the limbic system.

* Putamen and caudate → together form the Striatum
→ separated by the anterior limb of the internal capsule

* INPUT NUCLEI form to the basal ganglia and receive mainly EXCITATORY input from wide areas of the cerebral cortex

* globus pallidus → medial to the Putamen and lateral to the thalamus
→ subdivided into an external part (GPe) and an internal part (GPi) → The two parts are functionally different & have different connections within the basal ganglia
→ is the OUTPUT NUCLEUS of the basal ganglia SENDING INHIBITORY PROJECTION TO THE THALAMUS

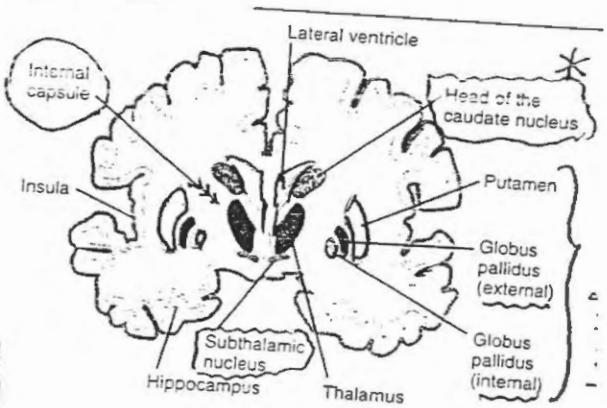


Subthalamic nucleus - inferior to the thalamus
receive input from basal ganglia ??
→ its output is Excitatory - through glutamatergic fibres to the globus pallidus as well as substantia nigra

# Functional organization of the Basal ganglia



- The basal ganglia exert their motor actions largely via RECIPROCAL connections with the cerebral cortex.
  - → Nearly all areas of the cerebral cortex PROJECT to the STRIATUM (caudate + putamen). The cortical inputs to the striatum are EXCITATORY and mediated by GLUTAMATE
  - → The output from the basal ganglia is via INHIBITORY (gamma-aminobutyric acid, GABA) neurons from the INTERNAL SEGMENT of the GLOBUS PALLIDUS to the THALAMUS AND THEN → via Excitatory pathways to the motor + premotor cortices

The flow and processing of cortical signals within the basal ganglia involve 2 major pathways < direct / indirect

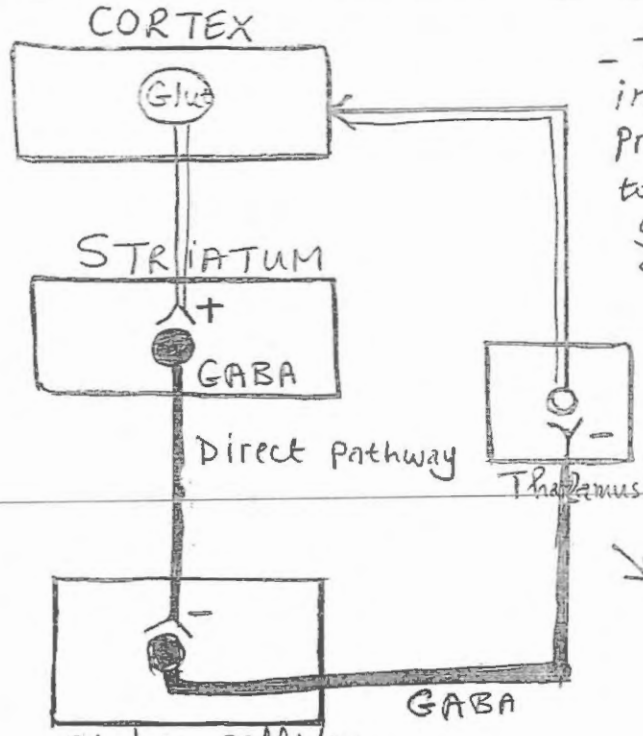


- The DIRECT pathway involves inhibitory GABAergic projection from the Striatum to the internal segment of globus pallidus → Activation of this pathway results in inhibition of inhibitory pallidal output neurons + hence DISINHIBITION of the thalamic neurons

This is thought to FACILITATE movement by exciting premotor + supplementary motor cortical areas

- globus pallidus internal segment (GPi)
- Substantia nigra reticulata (SNR)

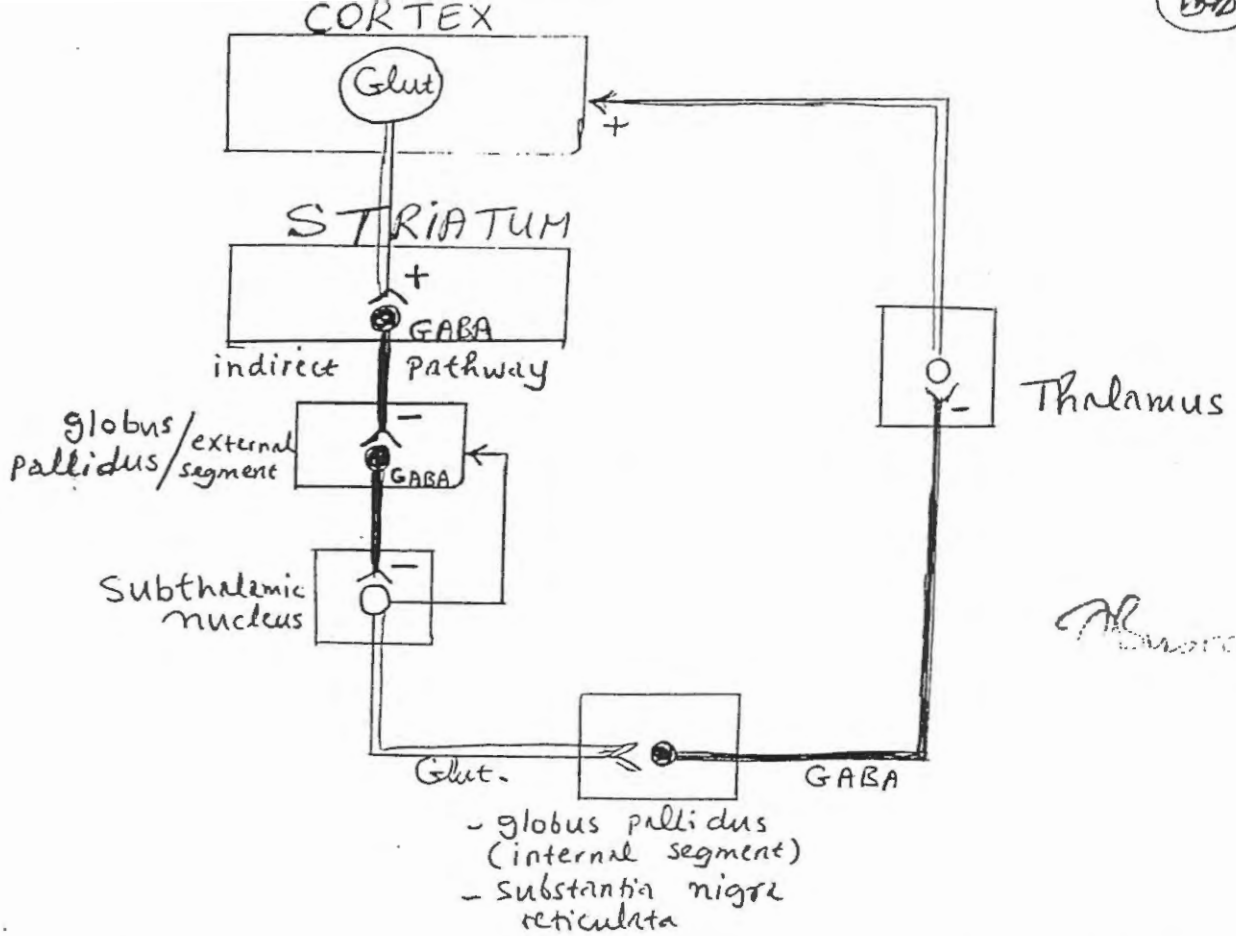


The INDIRECT pathway involves a distinct group of striatal GABAergic neurons that project to the EXTERNAL SEGMENT of the globus pallidus and inhibit an inhibitory GABAergic projection to the subthalamic nucleus, from which excitatory (glutamatergic) neurons project to the internal segment of globus pallidus PROVIDING EXCITATORY effect to the inhibitory GABAergic pallidothalamic output neurons

↓

The neteffect of activation of this pathway is the SUPPRESSION of thalamic neurons activity → DISFACILITATION of the motor cortical neurons →

INHIBITION OF MOVEMENT

Dopamine has excitatory action on the striatal neurons that control the DIRECT pathway

inhibitory action on the striatal neurons that control the INDIRECT pathway

In Parkinsonism → Loss of Striatal dopamine

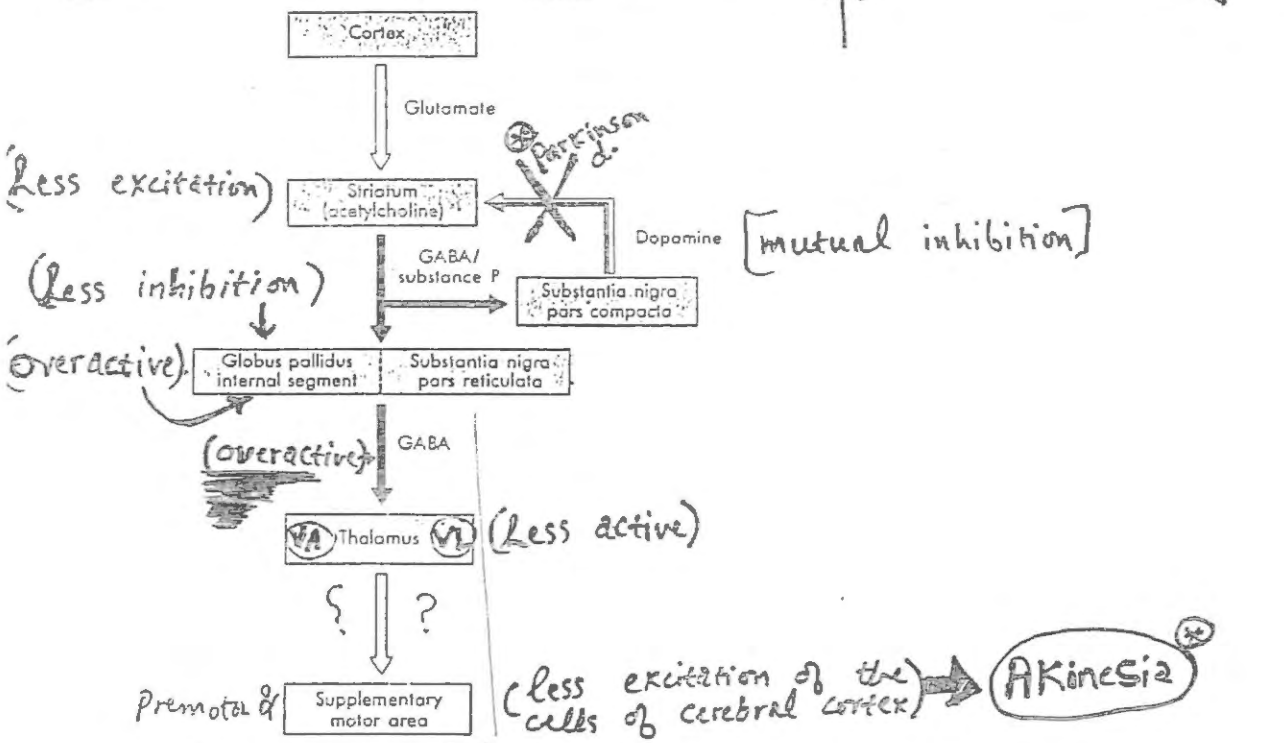


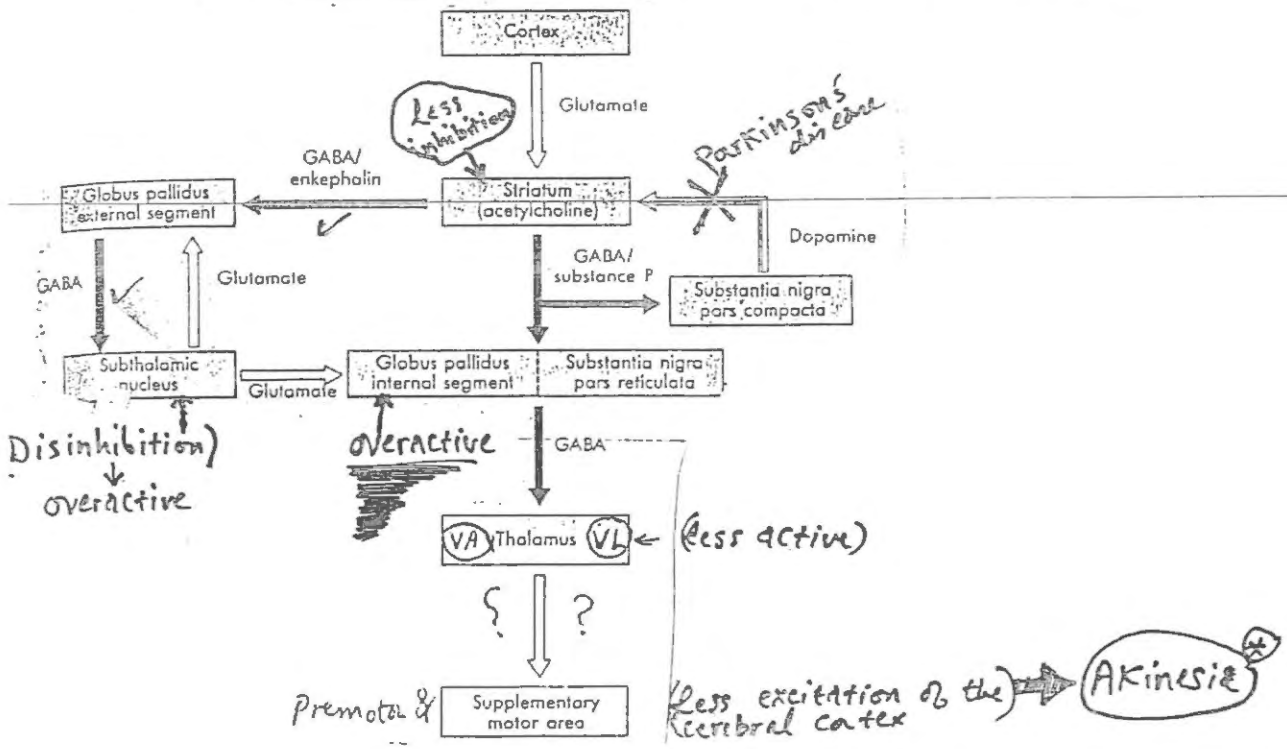

Chorea: rapid (dancelike) involuntary movements (diskinesia) largely restricted to muscles of distal extremities

Lesion → loss of Striatal GABAergic neurons that project to the external segment of the globus pallidus (indirect pathway) → This releases the inhibition of the external pallidal segment → suppression of the subthalamic activity → Reduced inhibition of thalamic neurons → greater facilitation of cortical areas → spontaneous movements

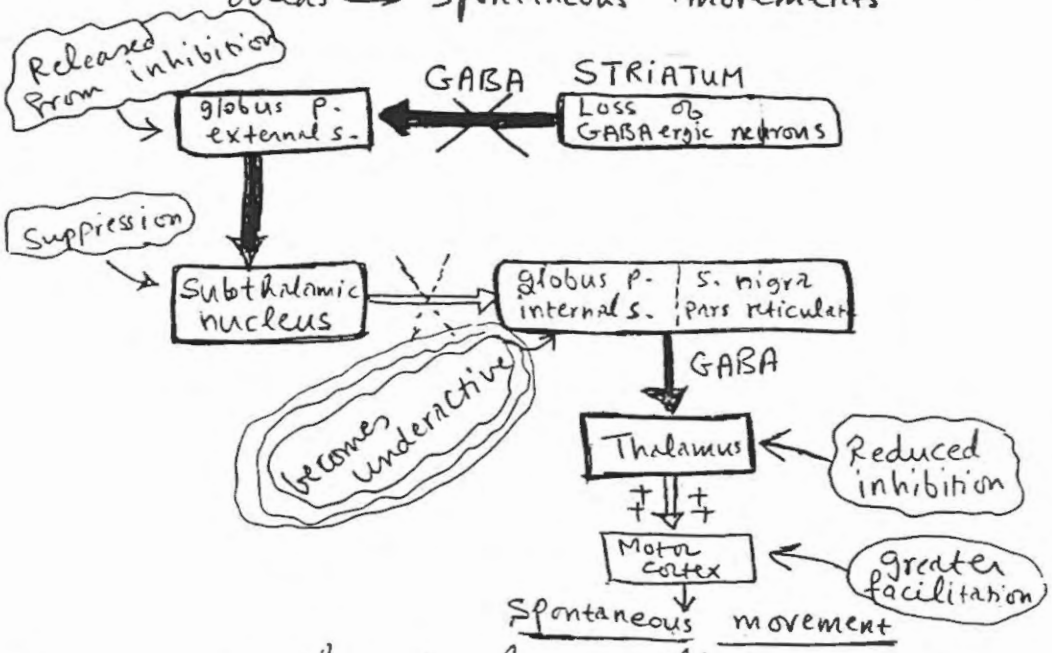


Functions of the basal ganglia

1. The Corpus striatum (caudate, putamen, globus pallidus) ⊕ Substantia nigra ⊕ Subthalamic nucleus

⇒ are FUNCTIONALLY INTERDEPENDANT

* Disease in any part of this complex of extrapyramidal nuclei

⇒ UPSETS TOTAL FUNCTION and the symptoms reflect general derangement

* Dysfunction of one component may result in over-activity in another part of the complex ⇒ RELEASE PHENOMENON.

2. The exact role of the basal ganglia in movement is far from clear. One speculation is that the Striatum contains LEARNED MOTOR PROGRAMS imprinted there by the multiplicity of cortical inputs. In Parkinson's disease patients find it hard to initiate movements learned in early life (such as standing and turning around) and in carrying them through.

3. Inhibit muscle tone throughout the body ???

In Parkinson disease

↓

**Overactive GPi** (internal segment of globus pallidus which is INHIBITORY)

↓

Suppression of thalamus

↓

Disfacilitation of cortex

↓

**HYPOKINESIA**

**Inhibition** of Midbrain extrapyramidal area

↓

**Inhibition** of Pontine reticulospinal tract

↓

**Disinhibition** of α and γ motoneurons

↓

Hyperactive

↓

Hyperactive stretch reflex

↓

**Hypertonia** — Extensors, flexors

in Axial & Proximal muscles

Inhibition of rubrospinal tract

↓

**Disinhibition** of α and γ motoneurons

↓

To flexor muscles **Proximal** & distal

↓

↑ tone in flexor muscles of limbs

---

**Tremor** → overactive globus pallidus ??

Programming of eye movements appears to occur Not only in the frontal eye feild but also in basal ganglia

↓

INPUT: reaches the basal ganglia via corticostriate fibres from the frontal eye feild and Posterior Parietal cortex

Output: from the globus pallidus(i) and substantia nigra (Pars reticulata) to VA thalamic nucleus

↓

directly influence the frontal eye field

Bustami

In Parkinson disease: Normal spontaneous eye movements are lacking or seldom occur

↓ ⊕ infrequent blinking

Staring appearance

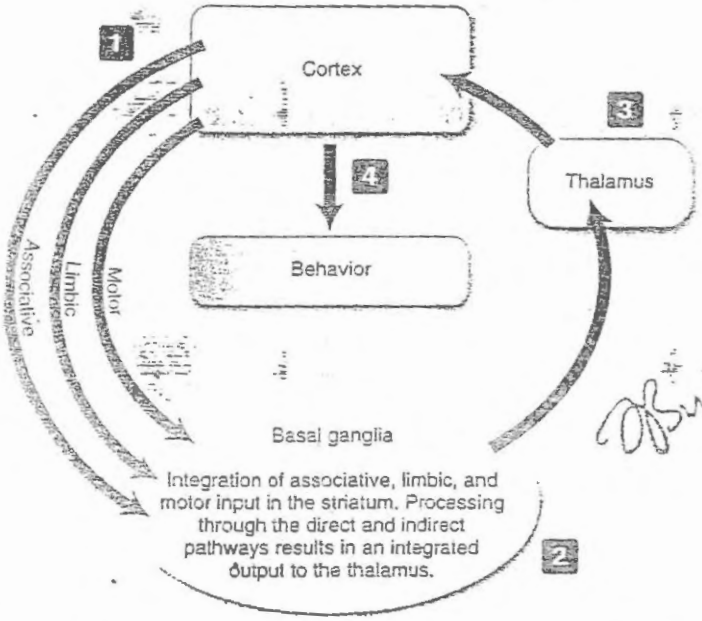


The input (1) to the basal ganglia can be described as three parallel streams of information from the cortex { Motor, associative, limbic }

Observant!

↓

The Striatum integrates these inputs (2)

↓

From the striatum the activity of the thalamus is determined via the direct & indirect pathways (3)

The thalamus then sends projections back to the cortex (4)

↓

The basal ganglia therefore INTEGRATE these { Sensory, motor, emotional, motivational } inputs that result in a final common pathway which determines the complex pattern of behaviour we display.

Observant!

## Motor circuit

Inputs related to motor performance come from widespread areas of the cortex including: primary motor area, premotor & supplementary motor areas as well as primary somatosensory & sensory association areas ⟹ ALL ARE INTEGRATED IN THE PUTAMEN → The motor circuit is mediated through both the direct and indirect pathways within the basal ganglia ⟹ the balance of these two pathways results in coordinated motor performance

↓

An imbalance in these pathways causes movement disorders characterized by TOO LITTLE MOVEMENT (without paralysis) or uncoordinated EXCESSIVE MOVEMENTS

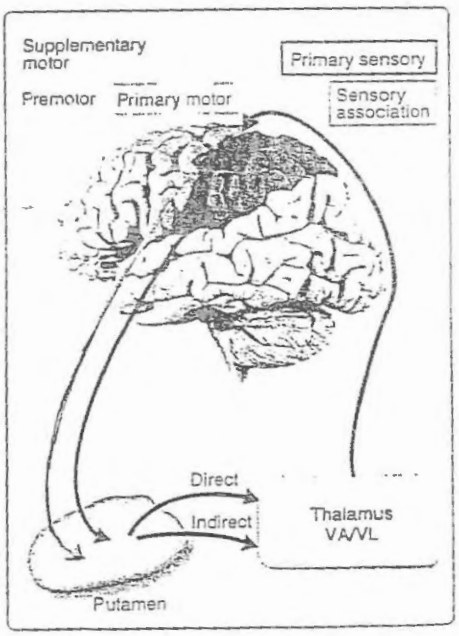


**Figure 16.13**
Schematic representation of the motor circuit. VA = ventral anterior nucleus; VL = ventral lateral nucleus.

| | Limbic circuit | Association circuit |
|---|---|---|
| Cortex | - frontal association areas<br>- limbic lobe<br>- hippocampus<br>- amygdala | Association areas → frontal, parietal, temporal |
| Striatum | nucleus accumbens<br>ventral striatum | - *caudate nucleus<br>- nucleus accumbens |
| Direct / indirect | ↓ | ↓ |
| GPi (globus pallidus internal segment) | ↓ | ↓ |
| Thalamus | VP (ventral posterior nucleus)<br>DM (dorsomedial) | VA (ventral anterior)<br>Centromedian |
| CORTEX | anterior cingulate<br>orbitofrontal (ventral part of frontal) | → motor cortex<br>- Prefrontal association area<br>→ wide cortical area (affect arousal) |

Function → Regulation of :- emotional, motivational & affective aspects of behaviour

↓

important in motor expression of emotions like posture gestures & facial expression related to emotion (disappear in Parkinson disease)

*Cognitive function

↓

planning of complex motor activity

* When a new task has been practiced and well learned → activity in the associative circuit decreases & the motor circuit becomes active instead

## THE NEUROLOGY OF THE BASAL GANGLIA

The basal ganglia have great neurological importance because several common diseases have been correlated with specific lesions to this area. Damage to the basal ganglia produces movement disorders, or dyskinesia [G. *dys*, bad, and *kinesis*, movement]. Dyskinesia, a motor disorder that entails some loss of voluntary control and regulation, falls into two classes: those that result in spontaneous movements, or hyperkinesia, and those that result in poverty of movement, or hypokinesia. Hyperkinesia is expressed as *involuntary spontaneous movements*. Hypokinesia causes the opposite effect, *the lack of spontaneous movements and a slowing of voluntary movement*. It is important to note that the motor system is otherwise intact, as are the knowledge and will to initiate and perform the motor act.

Dyskinesia differs from paralysis and paresis in two major respects. First, unlike paralysis or paresis, dyskinesia involves no dysfunction of the upper or lower motor neuron systems. Consequently, there is no weakness. Second, dyskinesia is not apraxia, the inability to plan or execute a complex motor act. Apraxia follows a lesion to the cerebral cortex and affects one's ability to conceptualize the task.

Parkinson's disease (paralysis agitans)

33

- widespread destruction of Substantia nigra → (loss of dopamine at Striatum)*
- Clinical signs → hypokinesia (or akinesia) ①, rigidity ②, Rest tremor ③
- Hypokinesia : difficulty in initiating movements, in carrying them through (freezing) or in terminating them
- Rigidity : increase muscle tone affecting both flexors & extensors (i.e bidirectional)
- Rest tremors → not always present
  - affect muscles of fingers (pill-rolling)
  - disappear during movement (unlike the intention tremors of cerebellar disease

- Chemical changes in Parkinson's disease
  - ↓ DA/Ach ratio (decrease dopamine/Acetyl choline ratio
- Treatment :
  - L-dopa → crosses the blood brain barrier and changes into dopamine within the living dopaminergic neurons
  - Anticholinergic drugs
  - Surgical destruction of the overactive pallidum

# PARKINSON'S DISEASE

(Degenerative changes are present in substantia nigra & globus pallidus)



"rest-tremor"
often "pill-rolling tremor in thumb & fingers

Bustami
1985

# - Dyskinesias -

(Abnormal "movement")



## ATHETOSIS

(Greek = not fixed)

* lesion → Putamen
* features → Slow, writhing, snake-like involuntary movements of the extremities.
* The alternating adduction & abduction of the shoulder joint is accompanied by flexion & extension of the wrist & fingers.
* may follow trauma or a birth injury.



## HEMIBALLISM

Ballisa = throwing

* Lesion → Subthalamic nucleus of Luys
* features → Violent abnormal movements originating mainly from the activity of the proximal muscles of the shoulder & pelvis.
* Hypotonia
* Symptoms are contralaterally.
* Symptoms are relieved by surgical lesion in VL nucleus.

محاضرات د. فرج البسطاي
25/2/2014 لطلبة الطب البشري
CNS II (الجزء الأول) (51)
تكملة المجموع الأول

## THE SPINAL CORD

— The spinal cord is a compressed cylindrical column (about 45 cm).

— It is 25 cm. shorter than the vertebral column.

— Above, it is continuous with the *medulla* at the level of the *foramen magnum*. Below, it tapers forming the *conus medullaris* and *ends at the level of the intervertebral disc between the first and second lumbar vertebrae.*

— A fine thread of neuroglia surrounded by pia mater called the *filum terminale*, descends from the *conus medullaris* to be attached to the back of the coccyx.

— The spinal cord is attached to the dura mater by lateral septa called the *denticulate ligaments* (which are folds of pia mater found between the ant. and the post. roots).

— The spinal cord is supported in the vertebral canal by 3 mechanisms :

a) the *filum terminale* : which is attached to the back of the coccyx.

b) the *denticulate ligaments* : which are attached to the dura mater.

c) the *dura mater* : which is attached above to the margins of the foramen magnum and on either side to the margins of the intervertebral foramena.

The *dura mater ends at the lower border of the second sacral vertebra.* $S_2$

## THE SPINAL NERVES

— 31 pairs of spinal nerves (*8 cervical, 12 thoracic, 5 lumbar, 5 sacral* and *1 coccygeal*) are attached to the spinal cord.

— Each spinal nerve is attached to the spinal cord by means of 2 roots (a *dorsal "sensory"* root and a *ventral "motor"* root).

— Each root is attached by a series of filaments along the length of a segment of the spinal cord.

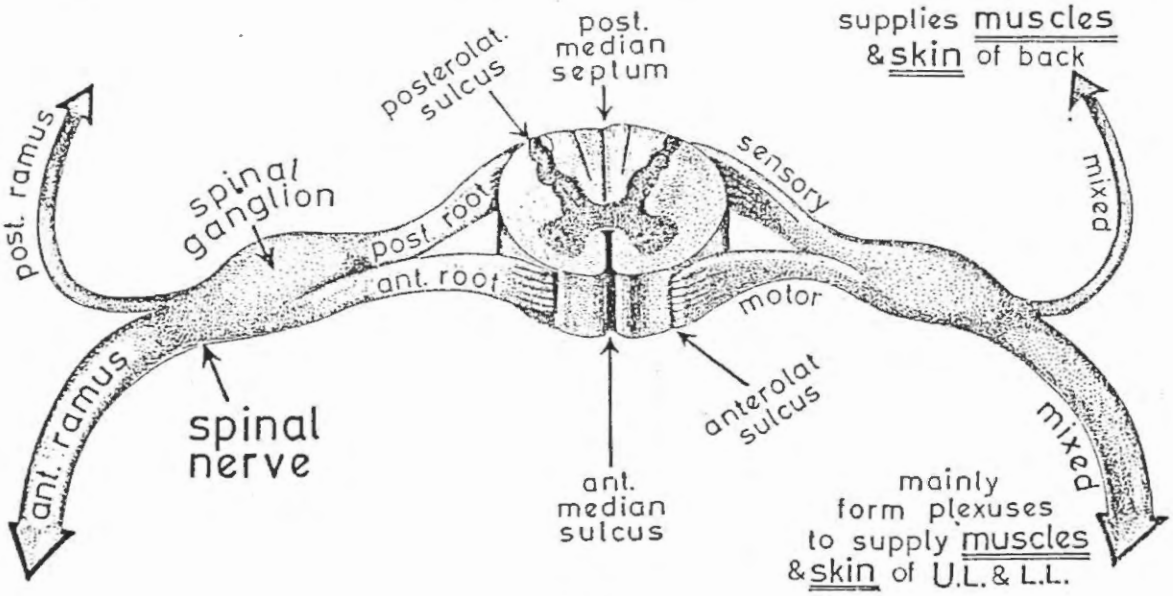


Fig. 66

A segment of the spinal cord with its sensory and motor roots.

— When the foetus, is 3 *months* old the length of his spinal cord is equal to the length of his vertebral column, and the spinal cord fills the whole length of the vertebral canal.

— After 3 months, the *vertebral column grows faster* than the spinal cord.

— *At birth*, the spinal cord ends at the level of the *3rd lumbar* vertebra.

— The *adult* spinal cord ends at the level of the intervertebral disc *between L1 and L2*.

*Notice the following :*

1 — *The segments of the spinal cord are not in line with the vertebrae which correspond to them in number and the difference increases as we go downwards :*

— the spinous process of C6 is opposite the spinal cord segment C7

— the spinous process of T3 is opposite the spinal cord segment T5

— the spinous process of T9 is opposite the spinal cord segment T10.

| Spinous process (vertebra) | Spinal cord segment |
|---|---|
| C6 | $C_7$ |
| T3 | $T_5$ |
| $T_8$ | $T_{10}$ |
| $T_{10} - T_{12}$<br>$L_1 - L_2$ | $L_1 - L_5$<br>$S_1$ - end |

2 — The spinal nerves leave the vertebral canal at the *intervertebral foramena* which *are lower down than the level of origin of the spinal nerves;* therefore, the ant. and post. *roots have to descend in the subarachnoid space some distances; "the lower the segment of the spinal cord the longer the distance which the roots have to descend before they reach their intervertebral foramena."*

3 — The *lumbar* and *sacral* nerves have very long post. and ant. roots. Their roots form a bundle called "the *cauda equina*" (because it resembles the tail of a horse).

4 — The subarachnoid space below L2 (after the spinal cord ends) contains *only the cauda equina and filum terminale suspended in C.S.F.* If we puncture the subarachnoid space below L2 *(lumbar puncture)* there is no danger of injury to the spinal cord.

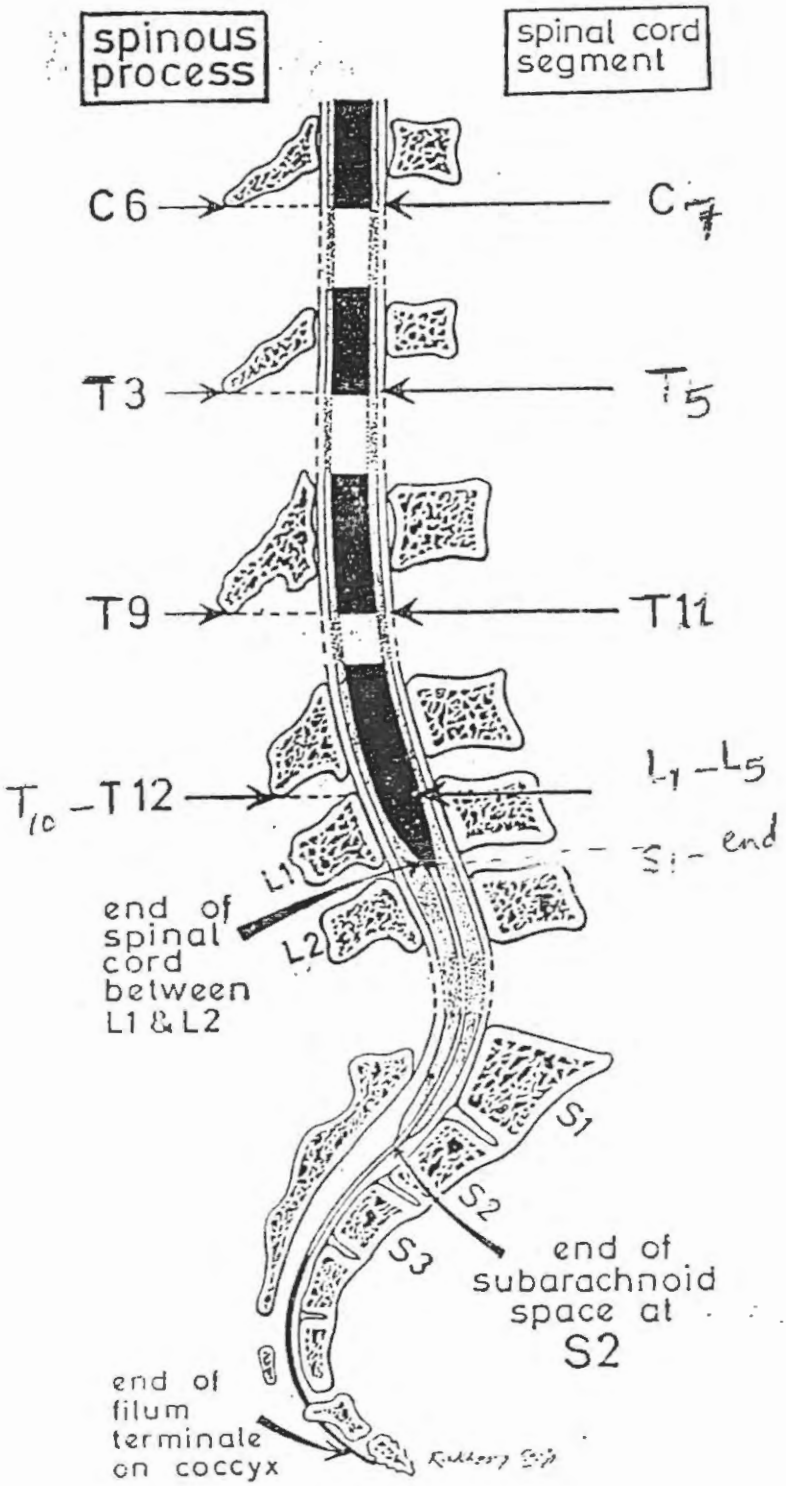


Fig. 83

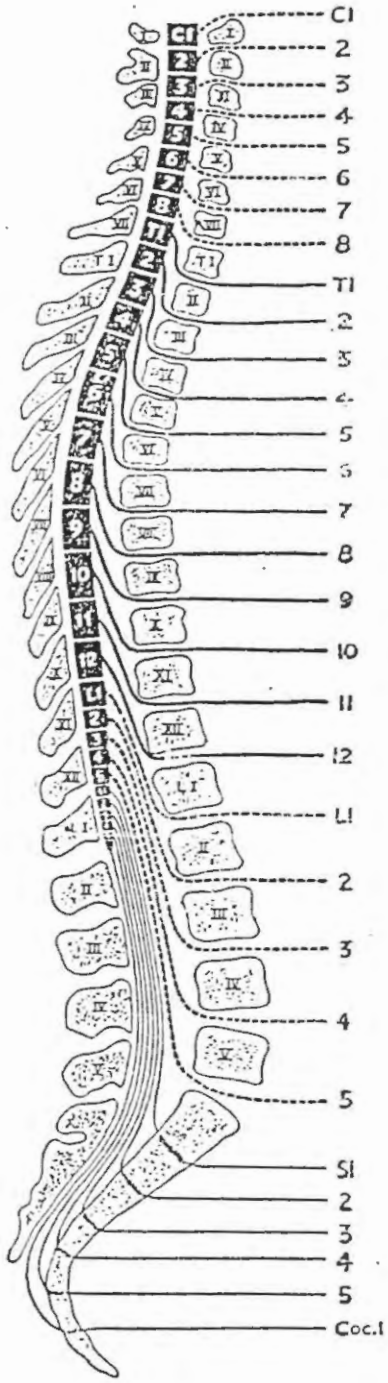


Fig. 84

Two diagrams to illustrate the relation between the spinal cord and the vertebral column

53 B

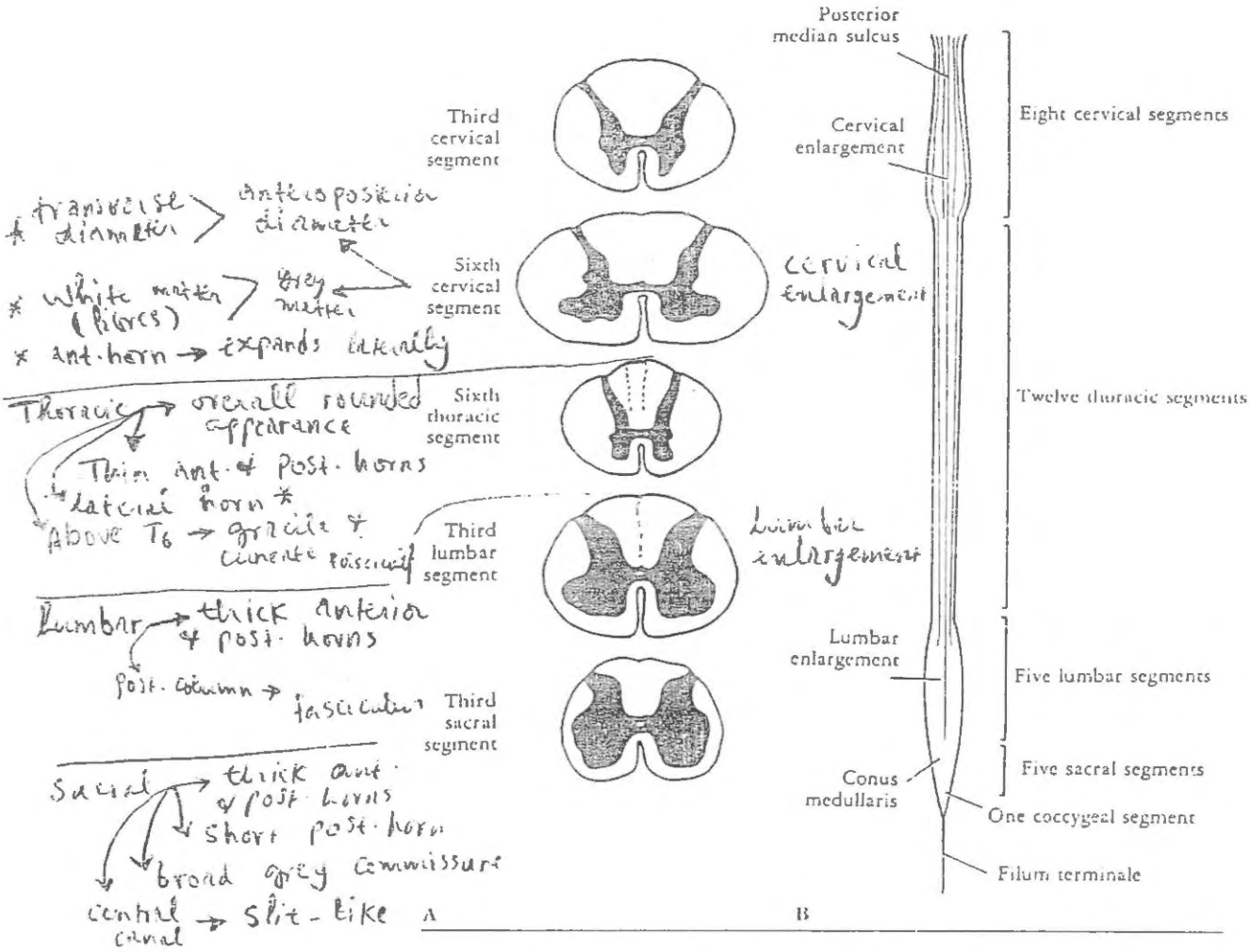
Posterior median sulcus
Third cervical segment
Cervical enlargement
Eight cervical segments
Sixth cervical segment
cervical enlargement
Twelve thoracic segments
Sixth thoracic segment
Third lumbar segment
lumbar enlargement
Lumbar enlargement
Five lumbar segments
Third sacral segment
Five sacral segments
Conus medullaris
One coccygeal segment
Filum terminale
A
B
* transverse diameter > anteroposterior diameter
* white matter (fibres) > grey matter
* ant. horn → expands laterally
Thoracic → overall rounded appearance
Thin ant. & post. horns
lateral horn *
Above T6 → gracile & cuneate fasciculi
Lumbar → thick anterior & post. horns
post. column → fasciculus
Sacral → thick ant. & post. horns
short post. horn
broad grey commissure
central canal → slit-like

8 (55)

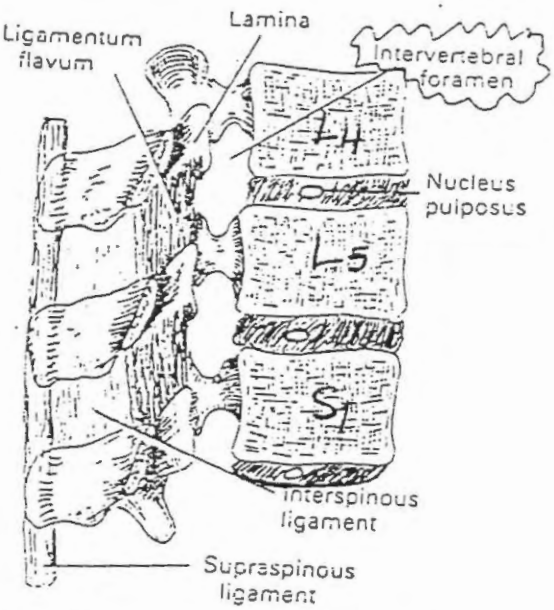


Fig. 5.68 Bisected vertebral column. The left half is seen from the right, so showing the inside of the vertebral canal, intervertebral discs in section, and the boundaries of two intervertebral foramina.

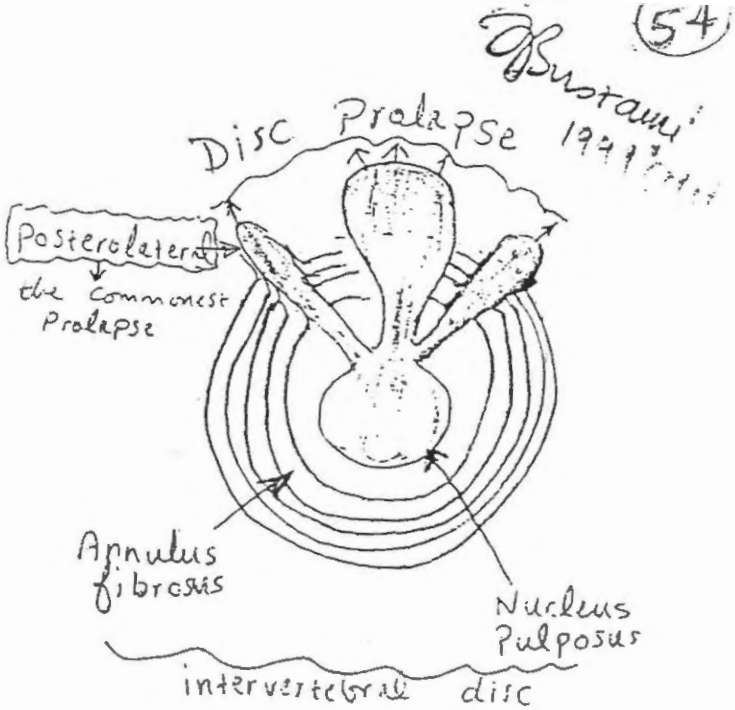


**Most Common Lumbar Disc Syndromes**

| Root | Disc Interspace | Reflex Affected | Motor Weakness | Sensory Changes (if any) |
|---|---|---|---|---|
| L4 | L3–L4 | Knee jerk | Knee extension | Anteromedial leg |
| L5 | L4–L5 | Hamstring jerk | Large toe dorsiflexion | Large toe, Anterolateral leg |
| S1 | L5–S1 | Ankle jerk | Foot, plantar flexion | Foot, lateral border |

Dermatomes of lower limb  Myotomes of lower limb

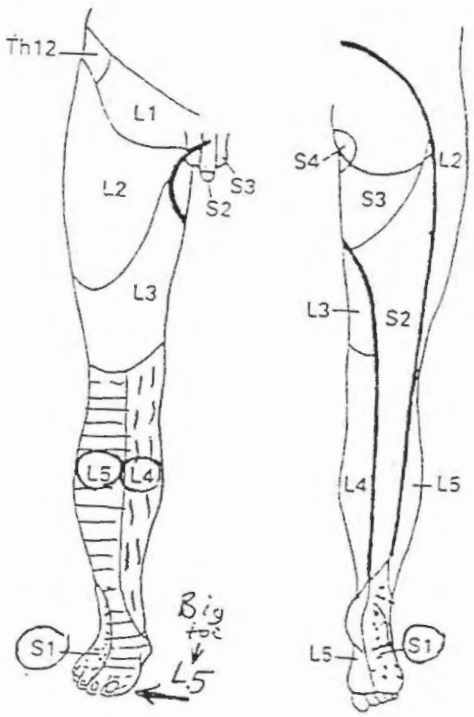


$\boxed{L2, L3, L4}$ → quadriceps → Knee extension; Iliopsoas → thigh on hip flexion; adductor group → thigh adduction

$\boxed{L5}$ → Tibialis anterior, Extensor hallucis longus } Ankle & big toe DORSIFLEXION

hamstring

[Check: have Patient walk on heels]

$\boxed{S1}$ → gastrocnemius → Ankle Plantar-flexion

[Check: have patient walk on tiptoes]

- An (L4/5) disc prolapse → produces pain over the [L5 dermatome], there may be weakness of Dorsiflexion of the ankle or great toe

- with an (L5/S1) prolapse (the commonest)
→ pain is felt at the back of the leg & sometimes in the Sole of foot
→ planterflexion & eversion are weak and the ankle jerk (S1 segment) is reduced or absent.


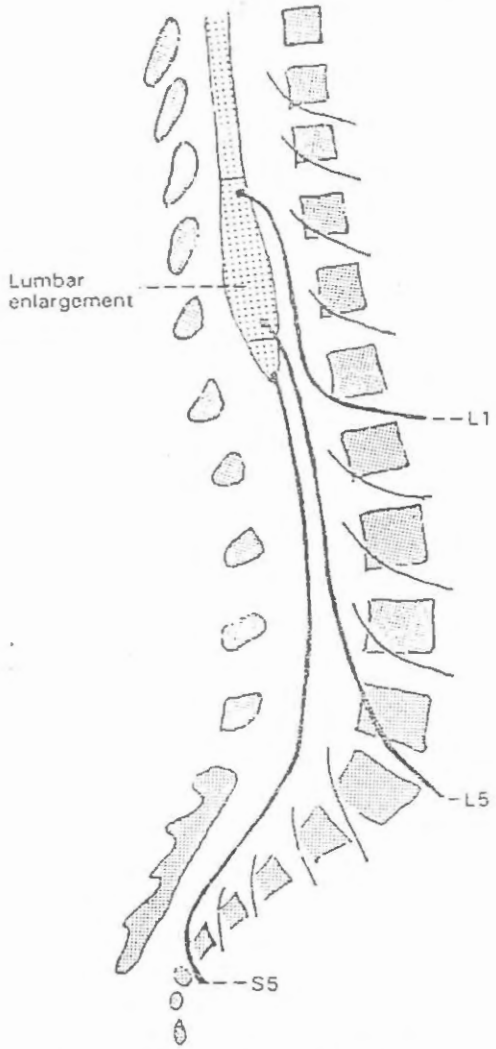


Fig. 8-8 Lumbar and sacral nerve roots. Only three are shown in continuity.

The root length increases progressively from rostral (superior) to caudal (inferior) levels

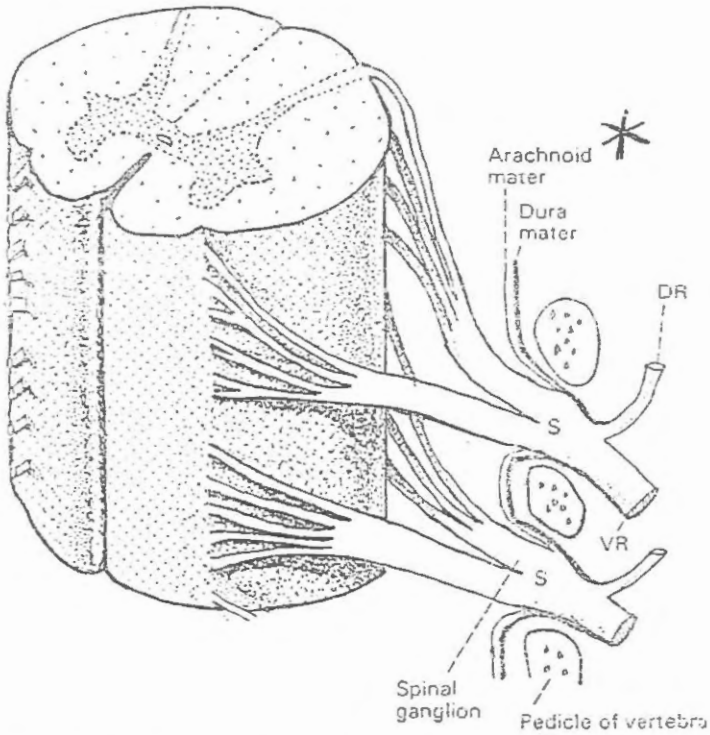


Fig. 8-9 Two thoracic spinal cord segments and spinal nerves. DR, dorsal ramus; S, spinal nerve; VR, ventral ramus.

**Thoracic roots**

These are rarely affected, because only rotary movements are permitted between the thoracic vertebrae. However, nerve roots may be compressed by vertebral collapse from trauma or metastatic cancer.

The *T1 syndrome* is a rare condition in which the first thoracic anterior root is torn from the spinal cord by violent traction, for instance when someone is pulled along the ground by one hand. The two presenting features are (a) wasting of the intrinsic muscles of the hand, and (b) Horner's syndrome (pupillary constriction, drooping of the upper eyelid (Chapter 31).

- Remember T1 (trunk) may be involved in CA apex of lung

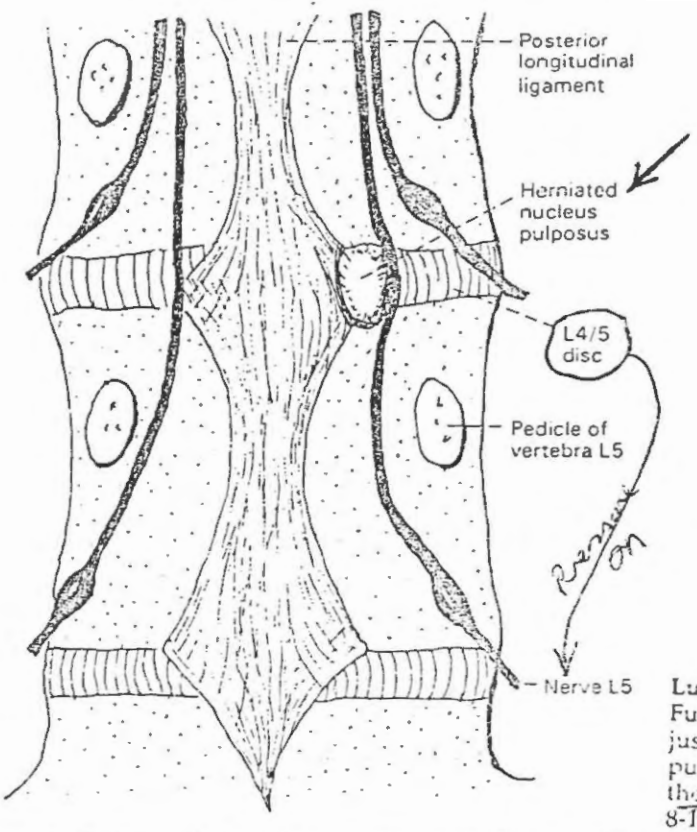


Fig. 8-17 Prolapse of L4/5 disc usually presses on L5 nerve roots. (Only posterior roots are shown.)

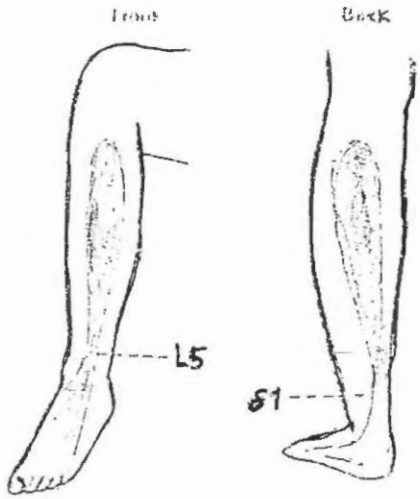


**Lumbar roots**

Fully 95% of all cases of prolapsed intervertebral disc occur just above or below the fifth lumbar vertebra. The nucleus pulposus herniates posterolaterally as a rule and compresses the pair of roots traveling to the *next* foramen of exit (Fig. 8-17).

- Lumbar disc Prolapse is characterized by < backache / Sciatic pain (Sciatica)
- Backache is caused by < tearing of annulus fibrosus / pressure on dura mater

**Innervation of dura mater and vertebral ligaments**

Each spinal nerve gives off a recurrent branch within the intervertebral foramen. The recurrent branch supplies the dura mater, the posterior longitudinal ligament of the vertebral column, and the outermost 8–10 lamellae of the annulus fibrosus of the intervertebral disc. The dura mater is exquisitely sensitive to* stretching, and clinical evidence indicates extensive overlap of innervation. Stretching of the dural sheath of a single spinal nerve gives rise to pain over five or more dermatomes on the back (see later).

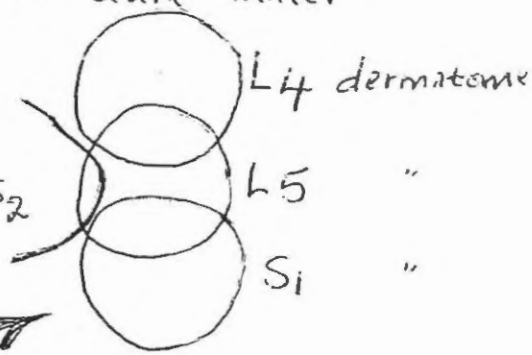


- Sciatica
  - → caused by pressure on posterior root fibres
  - → it is felt in the buttock, back of thigh & leg
  - → it is increased by pressure within the lumbar cistern (subarachnoid space) e.g by coughing or sneezing
  - → also increased by stretching the affected root
    → straight leg raising test

## Limbic circuit

- frontal association areas
- limbic lobe
- hippocampus
- amygdala

## Association circuit

Association areas → frontal, parietal, temporal

Cortex → Striatum

Direct / indirect

- nucleus accumbens
- ventral striatum

- *caudate nucleus
- nucleus accumbens

→ GPi (globus pallidus internal segment)

→ Thalamus → VP (ventral posterior nucleus), DM (dorsomedial)

VA (ventral anterior)

Centromedian

→ CORTEX → anterior cingulate, orbitofrontal (ventral part of frontal)

→ motor cortex
- Prefrontal association area

→ wide cortical area (affect arousal)

Function → Regulation of :- emotional, motivational & affective aspects of behaviour

→ important in motor expression of emotions like posture gestures & facial expression related to emotion (disappear in Parkinson disease)

Cognitive function → planning of complex motor activity

* When a new task has been practiced and well learned → activity in the associative circuit decreases & the motor circuit becomes active instead

# المسارات الحسية
# Sensory Pathways

Bustami

## Anterolateral system
المسار الأمامي الوحشي

Carry mainly (Pain) ألم
& (temperature) حرارة — cold, hot
sensations
(+) crude touch لمس غير دقيق
(+) itch sensation الحكة

## Dorsal column system
المسار العصبي الحسي الخلفي

Carry :
① Discriminative touch اللمس الدقيق
↓
To know exact location of touch & to make two-point discrimination
② proprioception (sense of position) & Kinesthesia
القدرة على الاحساس بمواقع أجزاء الجسم المختلفة واتجاه الحركات المختلفة
③ stereognosis (to know objects by feeling without looking
التعرف على الأجسام بالاحساس دون الاستعانة بالبصر

Any sensory pathway from body wall is formed of :-

- First order neuron الخلية الحسية الأولى → within dorsal root ganglion
- ↓
- Second order neuron الخلية الحسية الثانية → either in spinal cord or medulla oblongata
  → CROSS Midline either in spinal cord or medulla
- ↓
- third order neuron الخلية الحسية الثالثة → within the (thalamus) مهاد
- ↓
- area 3, 1, 2 المساحة الحسية الرئيسية في قشرة المخ
  → Primary sensory cortex ← (*) تفهم طبيعة الاحساس

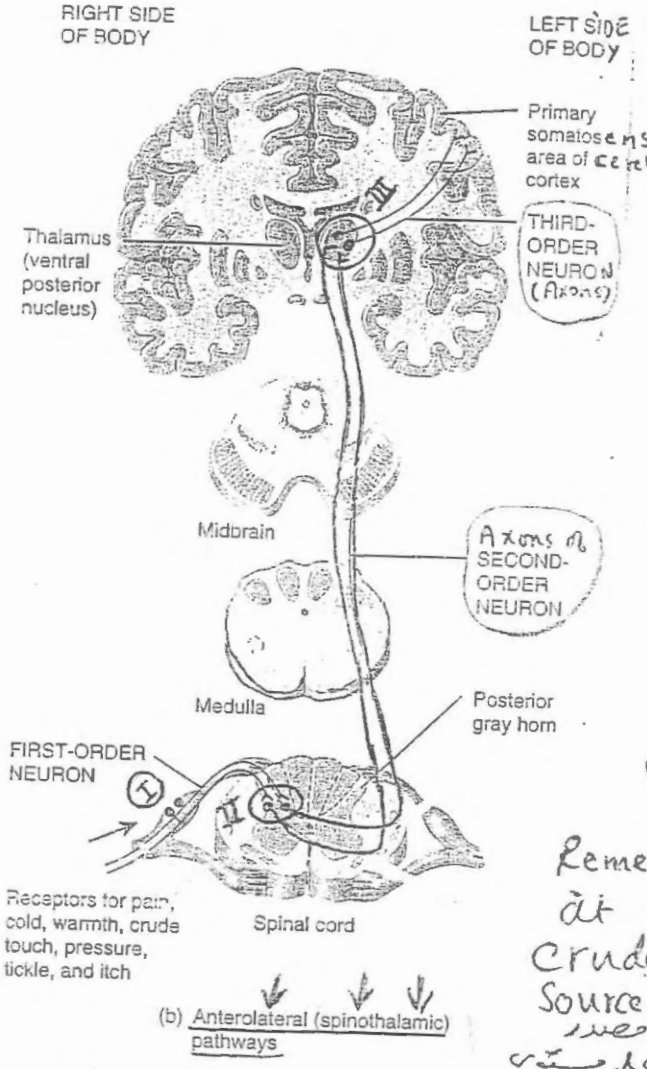


## Anterolateral (spinothalamic) System

↓

Notice the Crossing of the axons of second order neuron at the level of the spinal cord

لاحظ تقاطع محاور الخلايا الحسية من الدرجة الثانية على مستوى النخاع الشوكي

↓ النتيجة

Sensations from Right side of body will reach left half of brain

الإحساس من النصف الأيمن من الجسم يصل الى النصف الأيسر من الدماغ

Remember → Pain can be felt at the level of thalamus but crudely i.e we cannot tell the Source of pain or its severity شدة الألم

نستطيع أن ندرك الإحساس بالألم على مستوى المهاد ولكن بشكل غير دقيق حيث لا نستطيع أن نميز بدقة مصدر الألم أو شدة المنبه وهذه الصفات تحتاج الساحة الحسية في مشرة (3,1,2) الخ

---

## Dorsal (Posterior) Column System

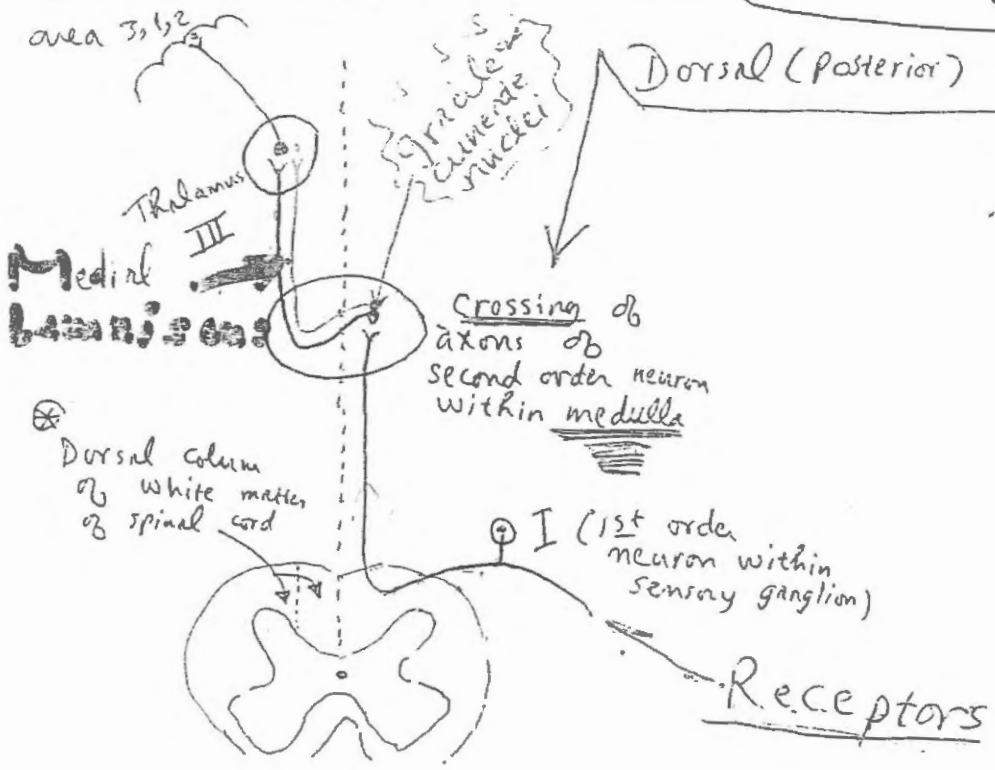


Bustami

② The mother cells for the dorsal root of a spinal nerve are present Outside the spinal cord ?!! → Within dorsal root ganglia or spinal ganglia ⇒ Sensory ganglion

↓

NO Synapse

توجد الخلايا للجذر الخلفي الحسي للعصب الشوكي خارج النخاع الشوكي ← [داخل عقدة عصبية حسية] مرتبطة بالجذر الخلفي

↓

لا يوجد تشابك عصبي في هذه العقدة (كما هو الحال في العقد العصبية السمبثاوية .....)




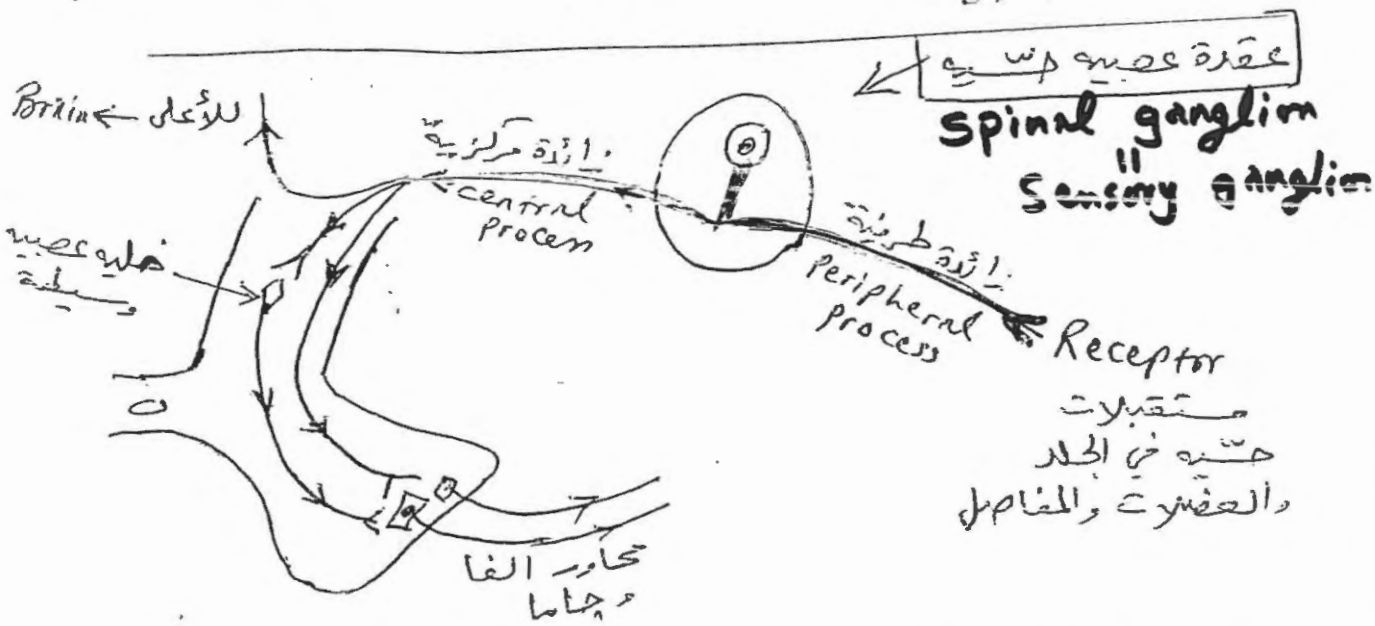


① الزائدة الطرفية للخلية العصبية تصل الى المستقبلات الحسية وتنقل السيالة العصبية Nerve impulse من هذه المستقبلات باتجاه النخاع الشوكي

② الزائدة المركزية تدخل النخاع الشوكي :

أ) تكمل للأعلى في المادة البيضاء مكونة مسار عصبي حسي يعرف بالجهاز العصبي الحسي الخلفي Dorsal column system

ب) تعمل تشابك عصبي synapse مع خلية عصبية وسيطة interneuron

ج) تصل مباشرة وتتشابك مع خلايا الفا وجاما

# Hemisection of the spinal cord
## Brown-Sequard syndrome

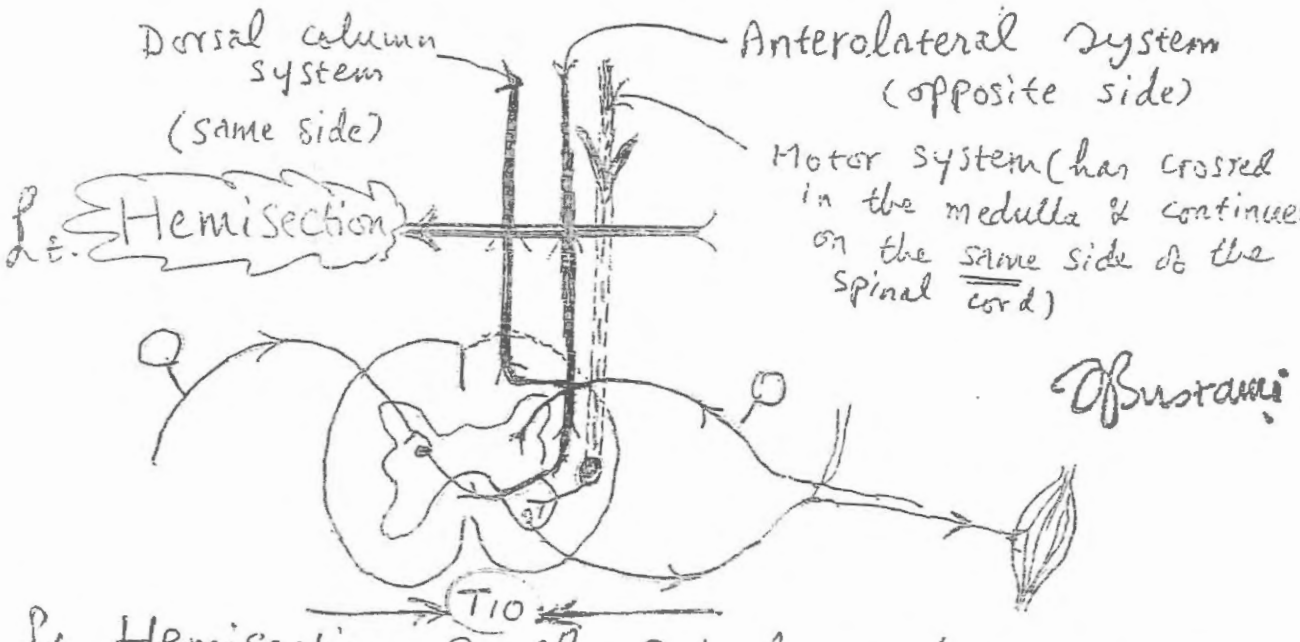


**Lt. Hemisection of the Spinal cord** (e.g occlusion of the anterior spinal artery)

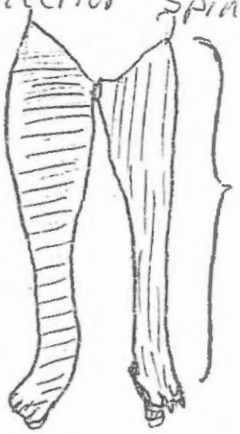

**Contralateral signs**

Below level of lesion:

↓

Loss of pain, temperature & crude touch in Rt. lower limb

**Ipsilateral signs**

Below level of lesion:

1. Spastic paralysis ⊕ hyperreflexia of Lt. lower limb
2. Loss of discriminative touch, sense of position & stereognosis in Lt. lower limb