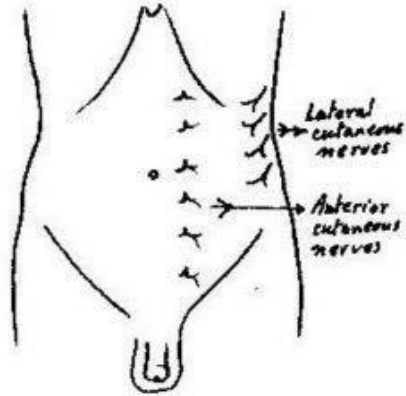
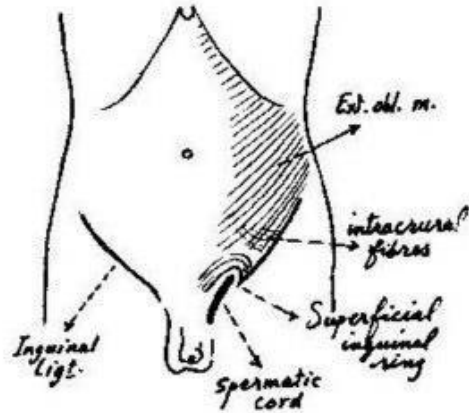


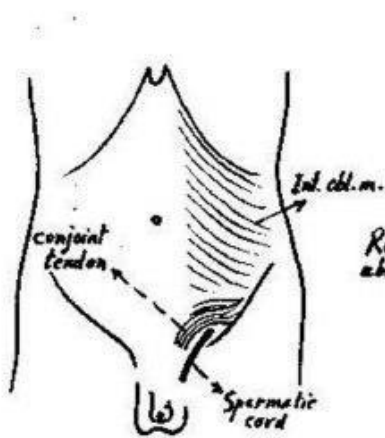
ANTERIOR ABDOMINAL WALL



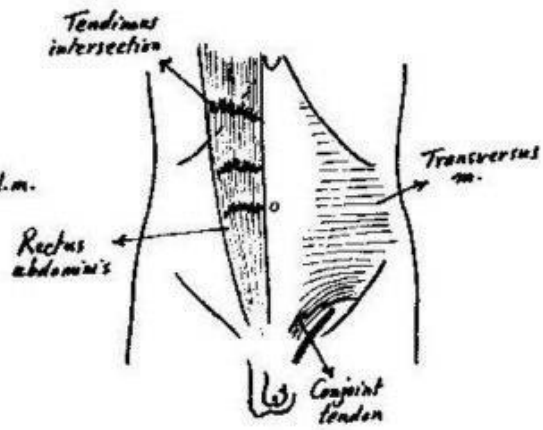
Ant. & Lateral cutaneous nerves (ant. abd. wall).



External oblique muscle

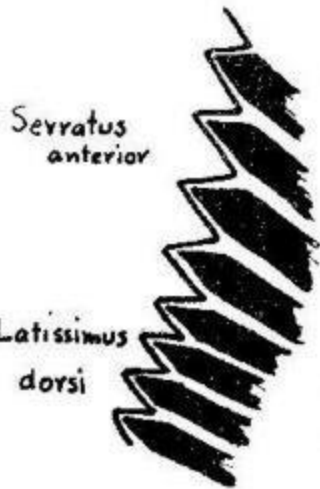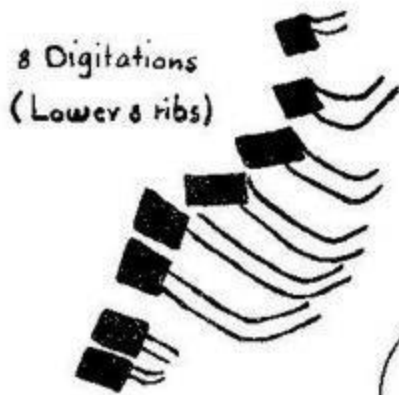


Internal oblique muscle

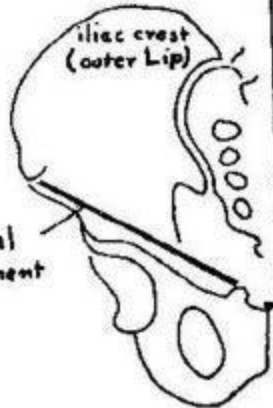


Transversus abdominis & Rectus abd. muscles.

Origin of external oblique M.



Inguinal ligament



xiphoid process

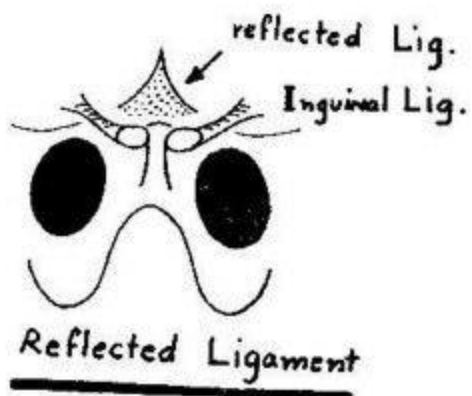
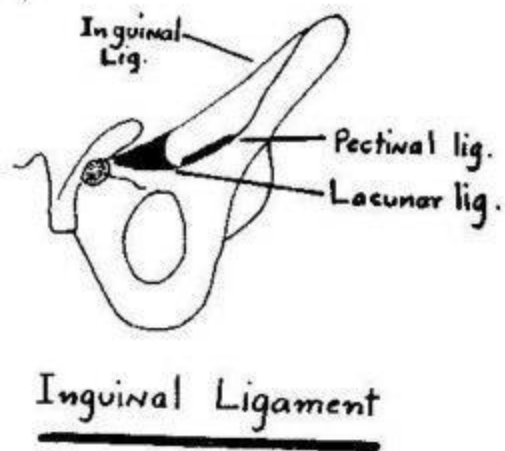
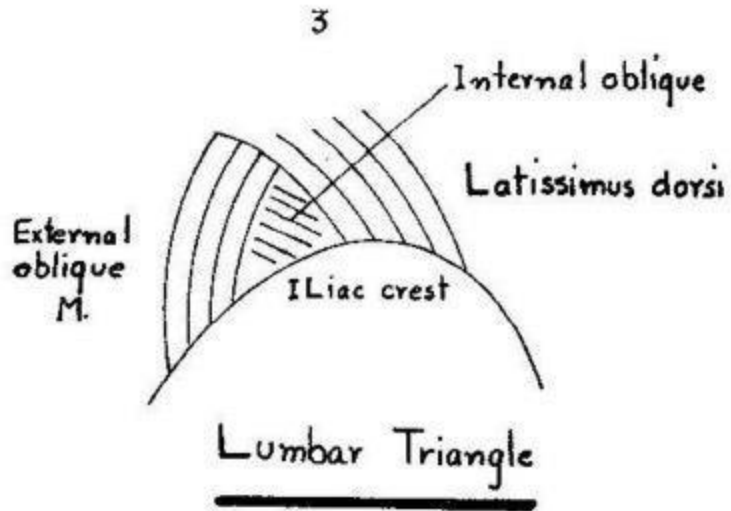
Linea alba

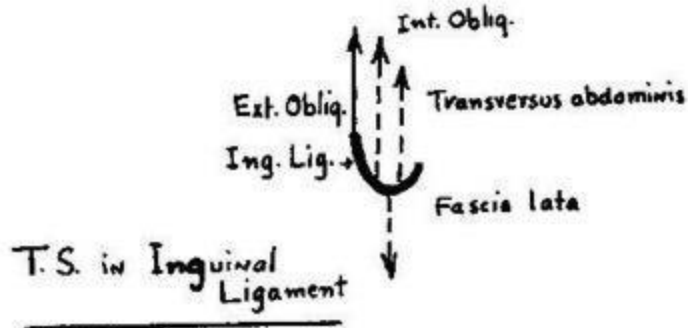
pubic crest

Insertion of external oblique M.


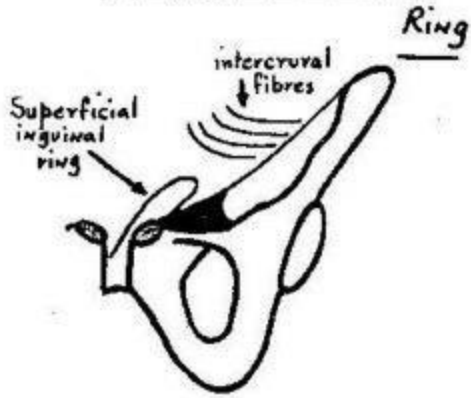
digitations of external oblique M.

Interdigitation





Superficial Inguinal

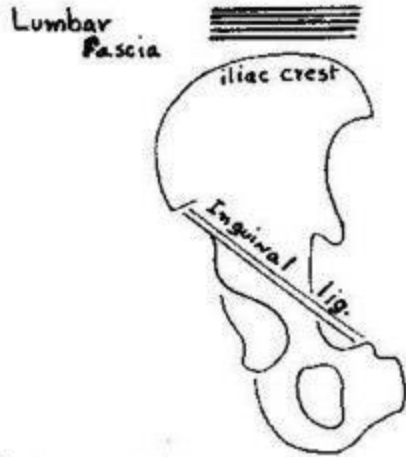


Lt. Superficial Inguinal Ring

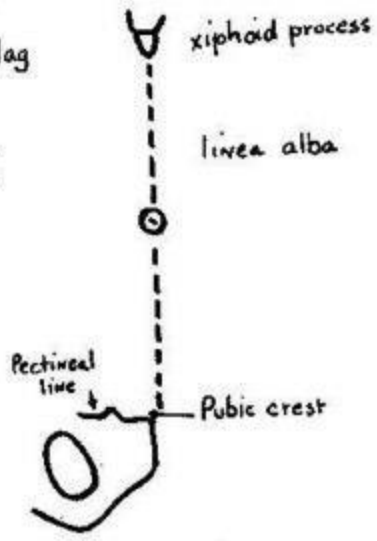


Lower 6
Costal cartilages

Insertion



Origin of Internal Oblique M.



Insertion



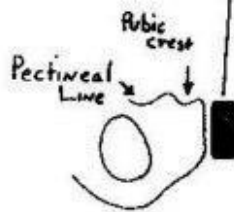
Lower 6 costal cartilages



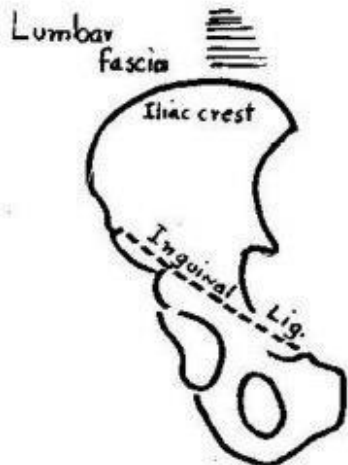
xiphoid process



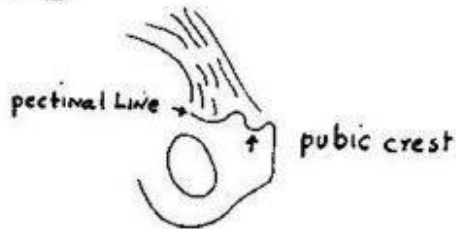
Linea alba



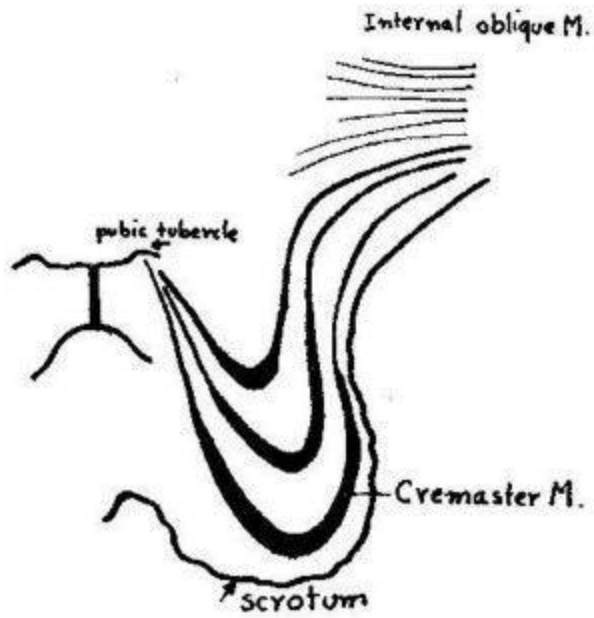
Insertion of transversus abdominis



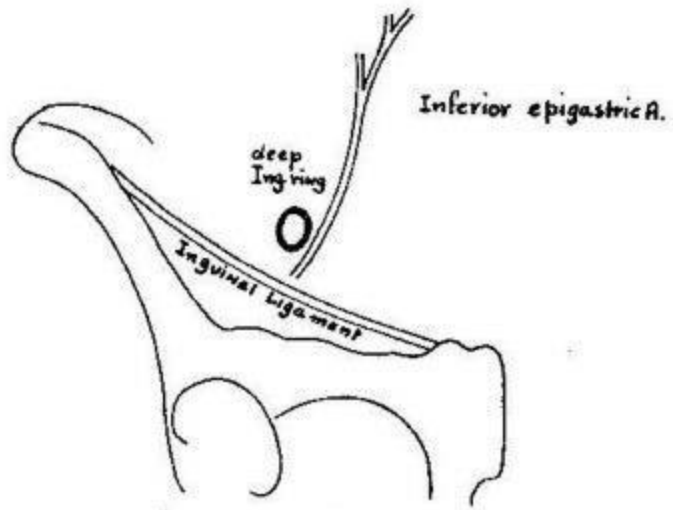
Origin of transversus abdominis



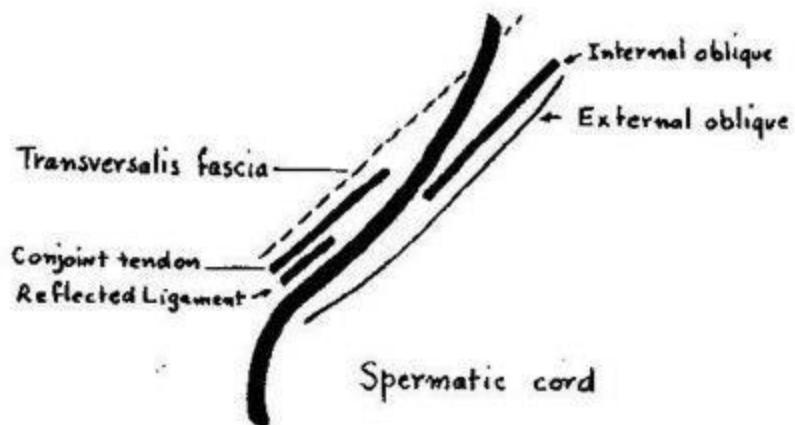
Conjoint Tendon



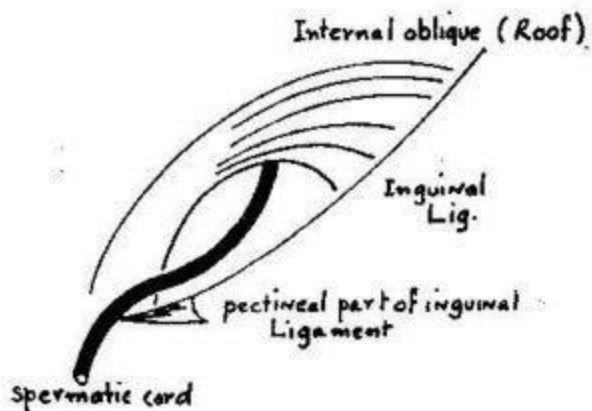
Cremaster Muscle



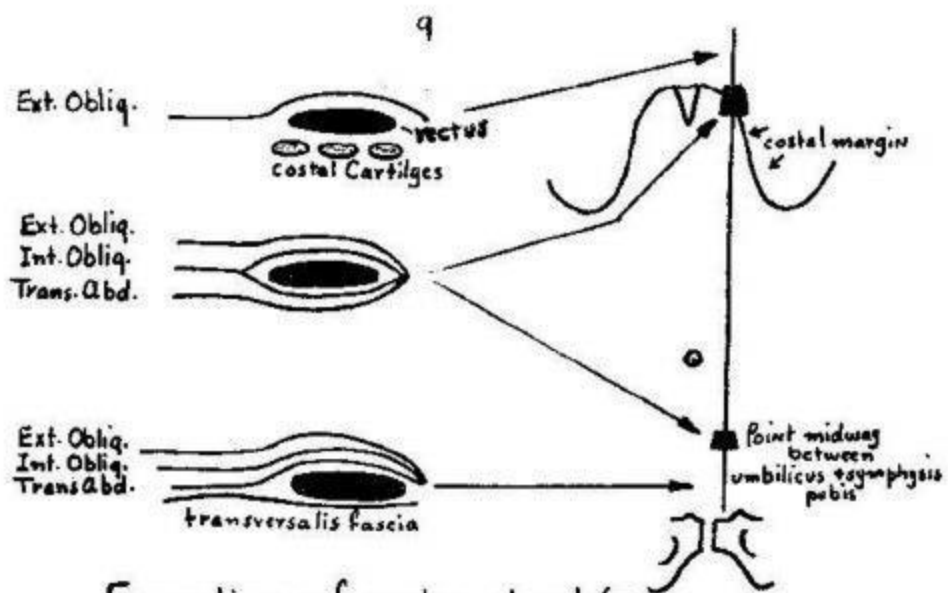
Deep Inguinal Ring



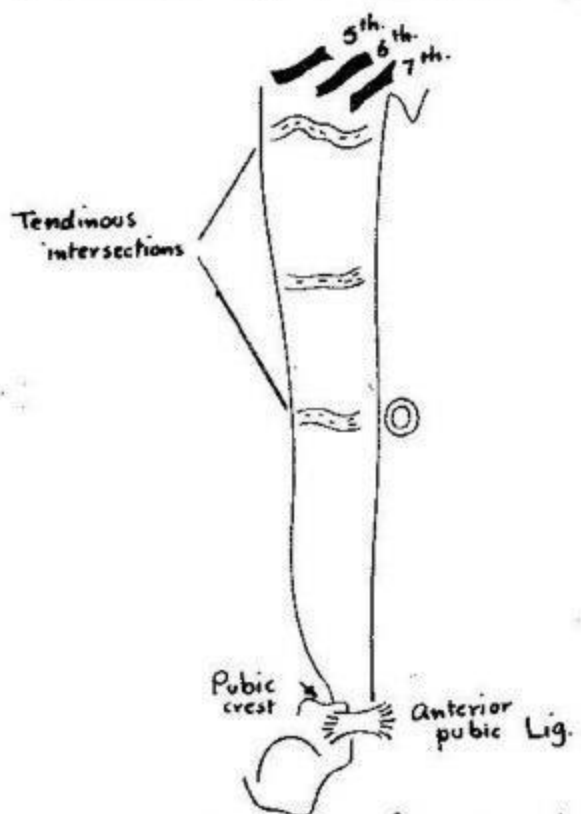
Boundaries of Lt. Inguinal Canal



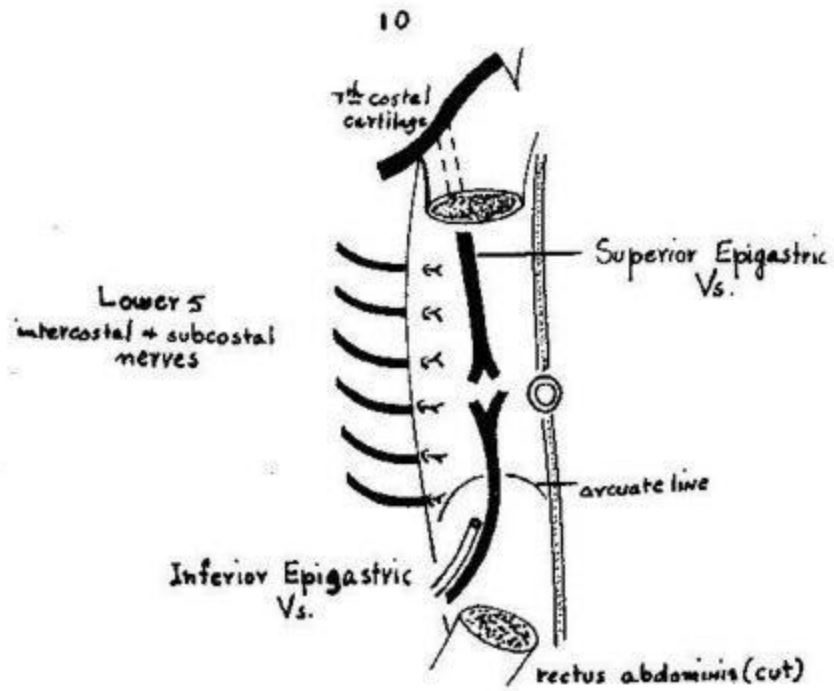
Roof + Floor of Inguinal Canal .



Formation of rectus sheath (T.S)

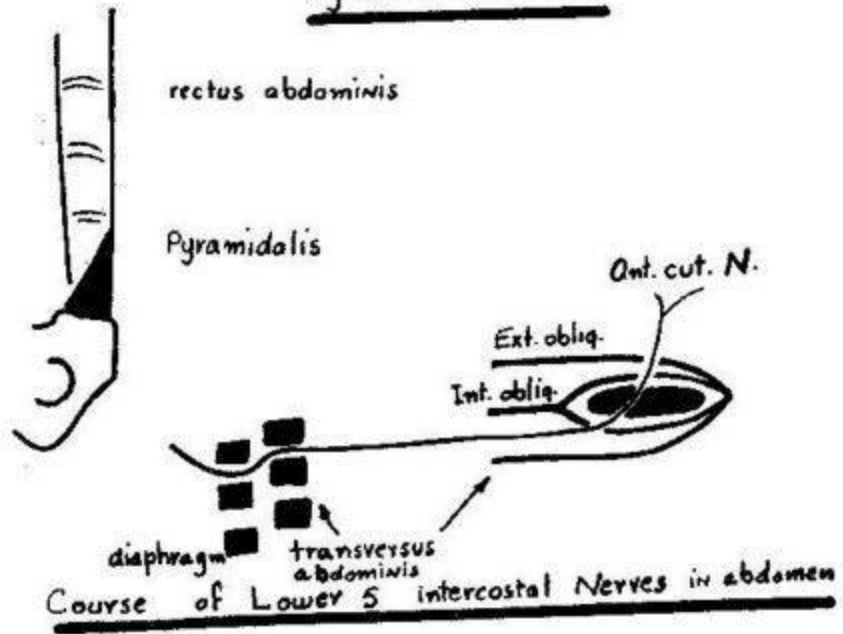


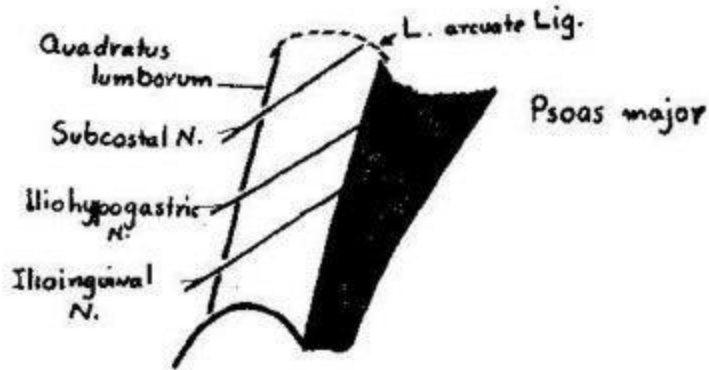
Origin + Insertion of rectus abdominis




Contents of rectus sheath

Pyramidalis Muscle

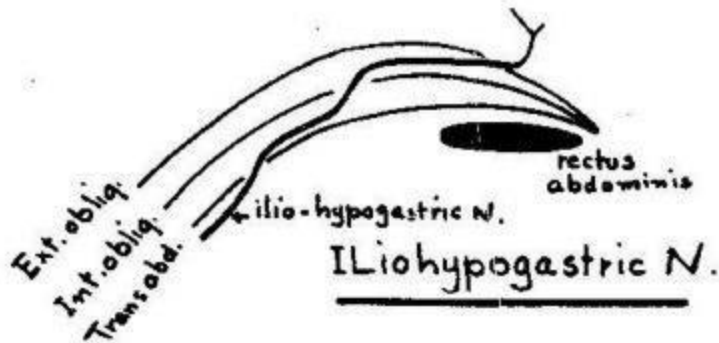


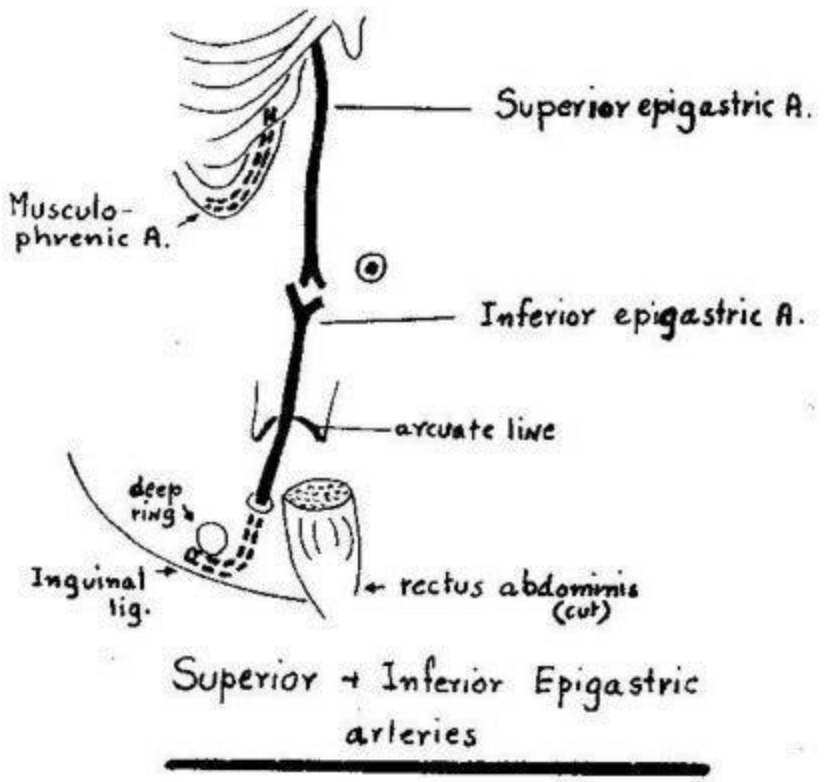
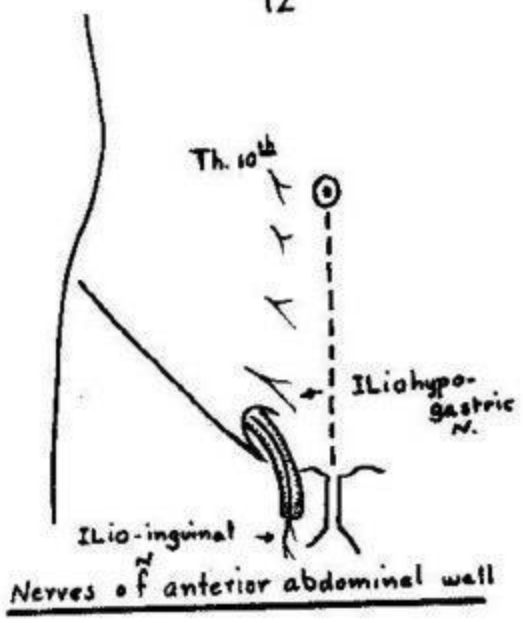


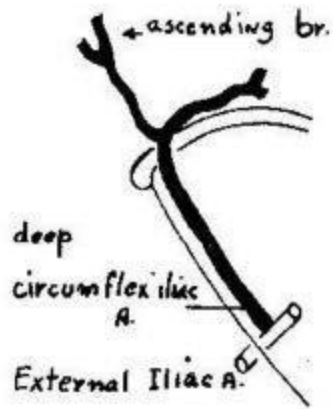
Course of subcostal + iliohypogastric Nerves



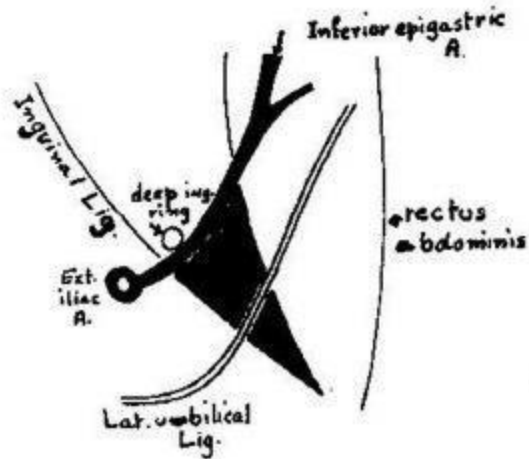
Subcostal Nerve



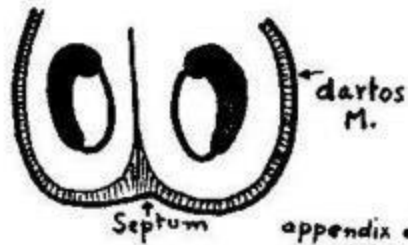




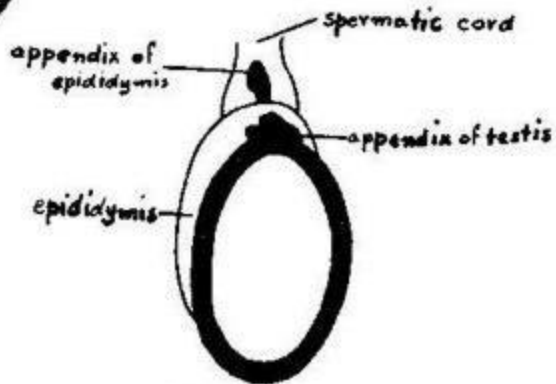
Deep Circumflex Iliac Artery



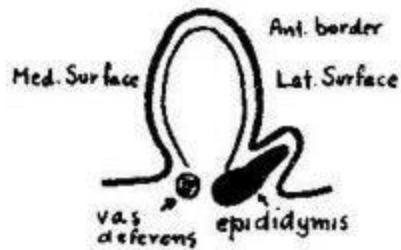
Left Inguinal Triangle (post. view)



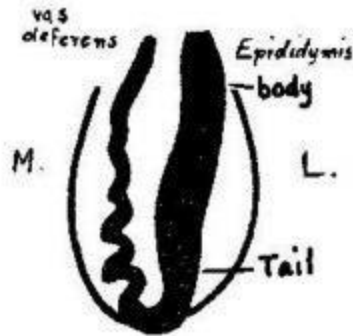
Scrotum



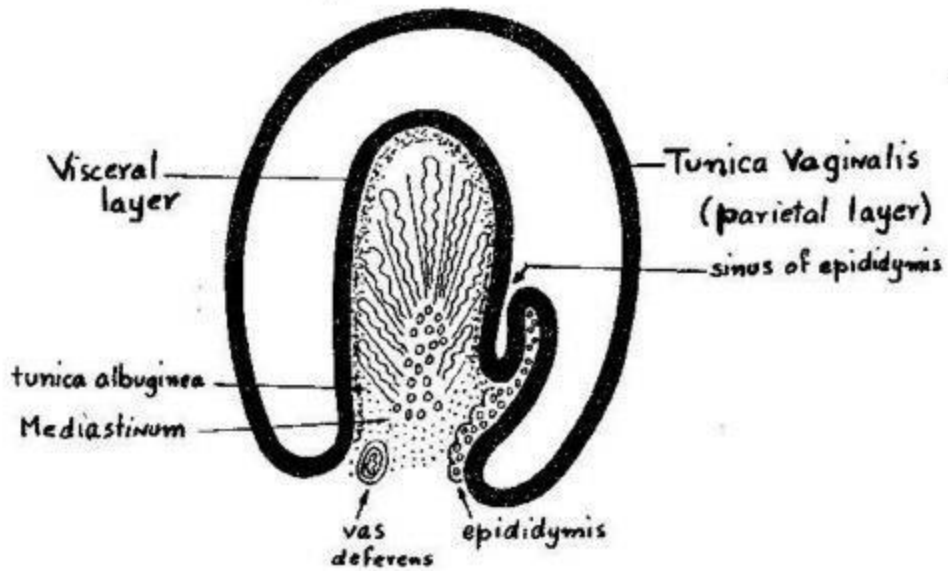
Right testis (ant. view)



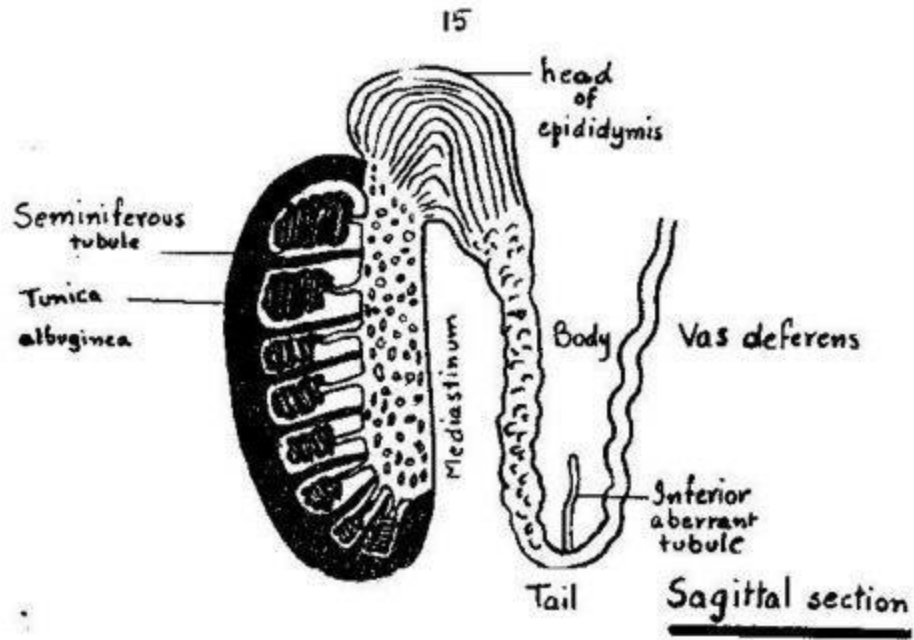
T.S. in R. testis



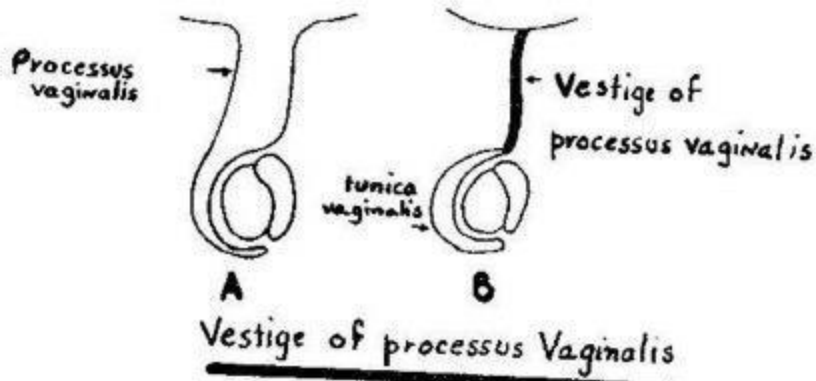
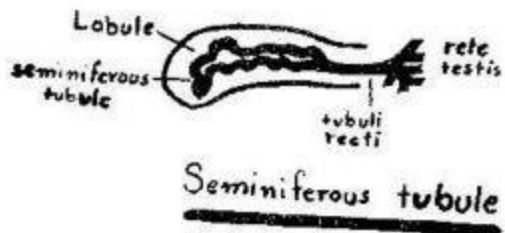
Right testis (Rst. View)



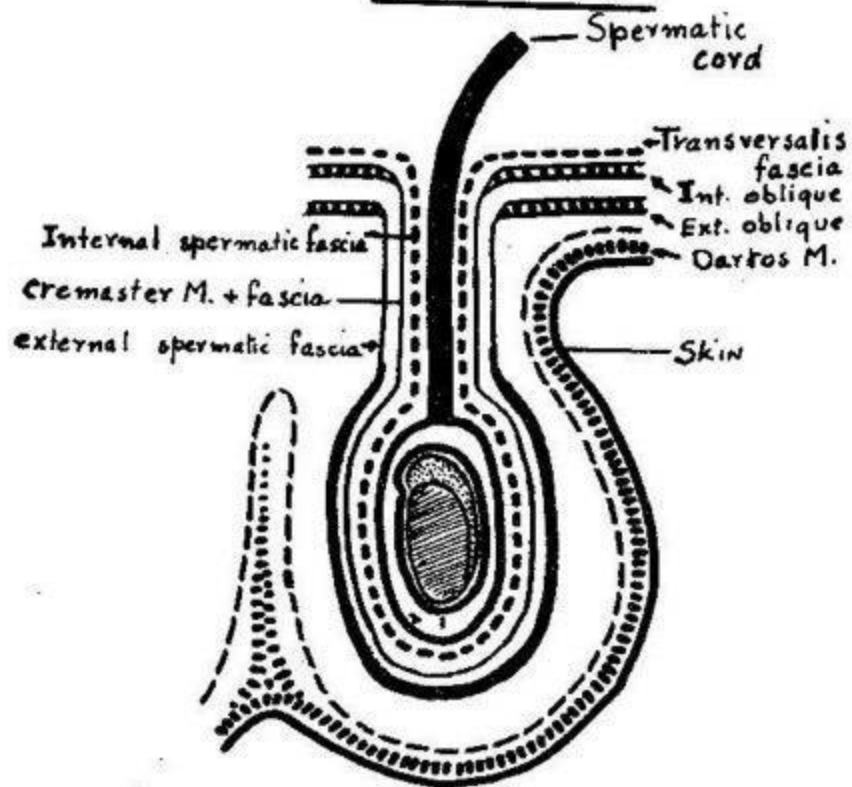
Tunica Vaginalis (T.S. in testis)



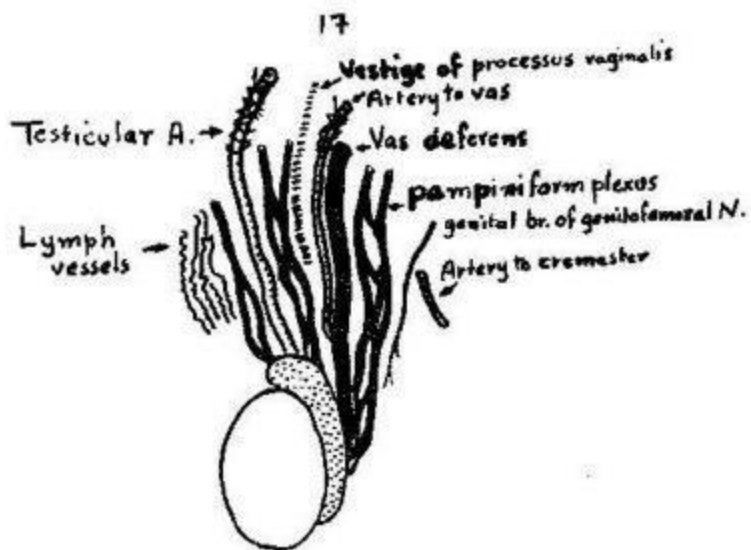
in testis



Coverings of testis and Spermatic cord

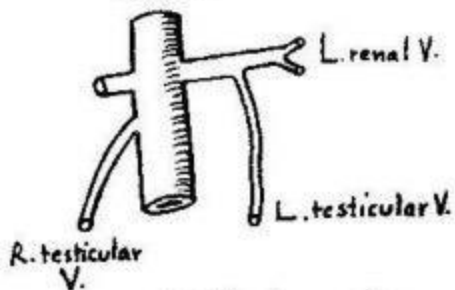


1. Tunica vaginalis (Visceral layer)
2. Tunica vaginalis (Parietal layer)

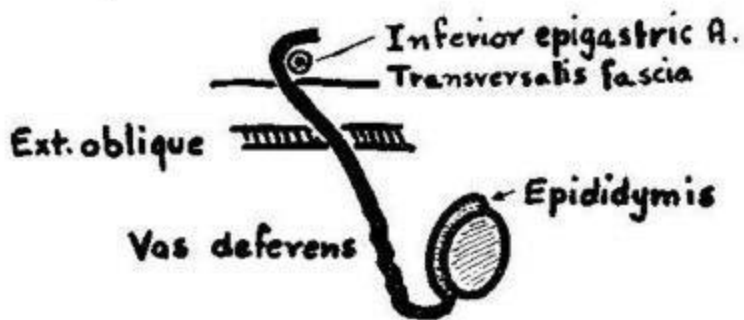


Contents of spermatic cord

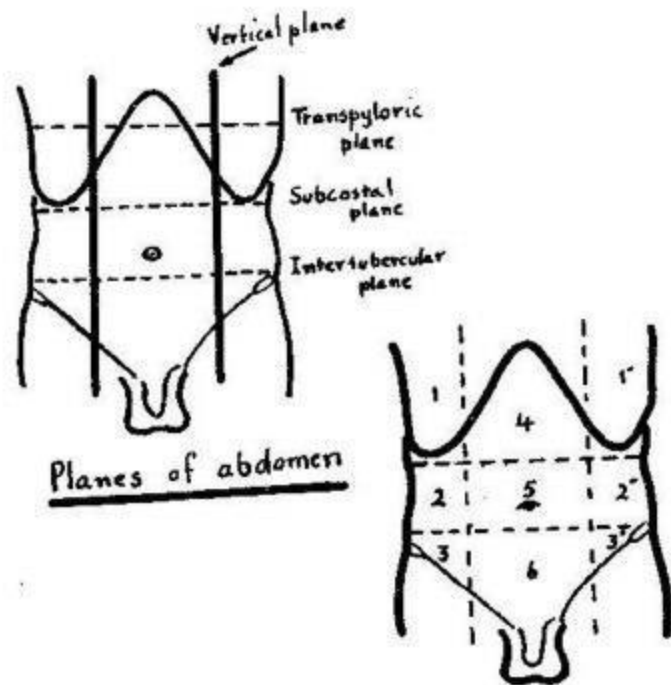
I.V.C.



Testicular veins

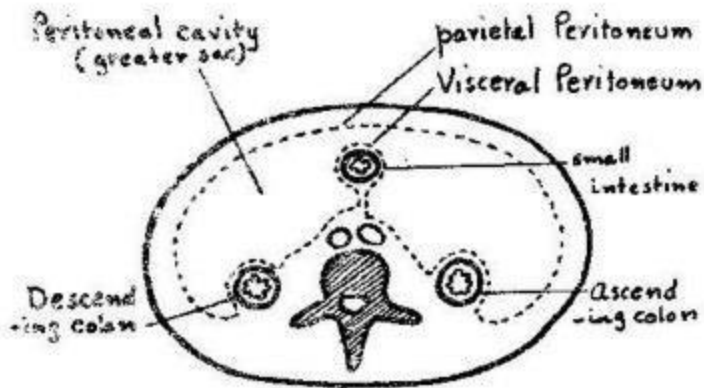


R. Vas Deferens

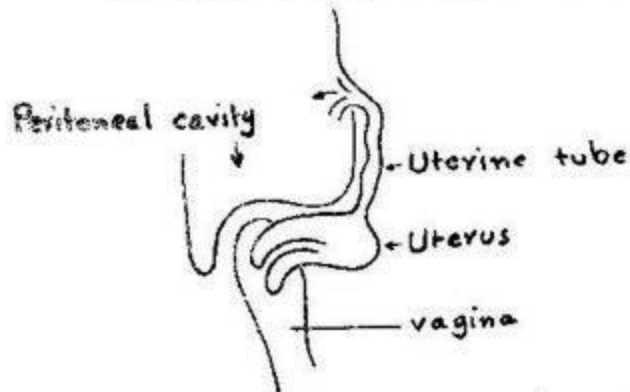


- 1,1' R. + L. hypochondrium
 2,2' R. + L. Lumbar
 3,3' R. + L. inguinal
 4. Epigastrum
 5. Umbilical
 6. Hypogastrum

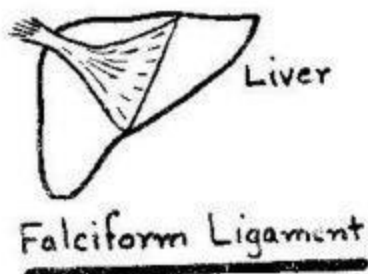
Regions of abdomen

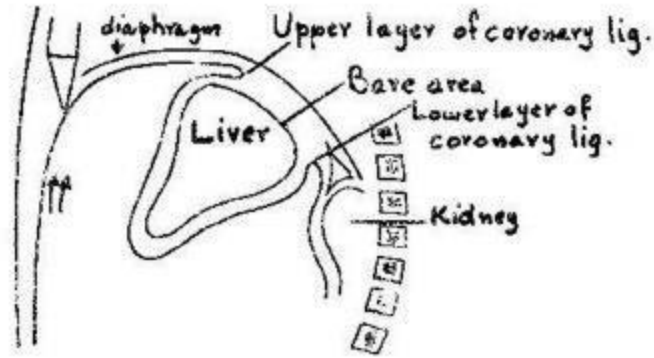


T. S. in abdominal cavity showing Visceral + Parietal Peritoneum

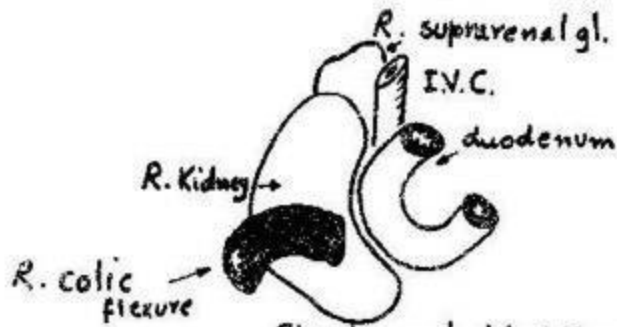


Uterine tube opens in peritoneal cavity (side view)

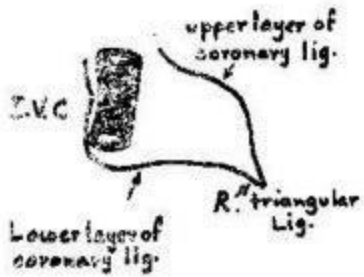




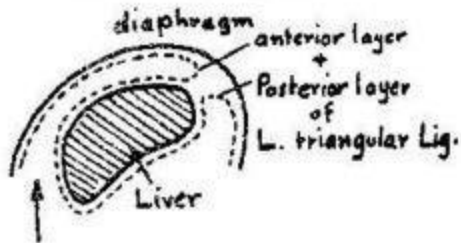
Tracing Peritoneum on right side of falciform ligament



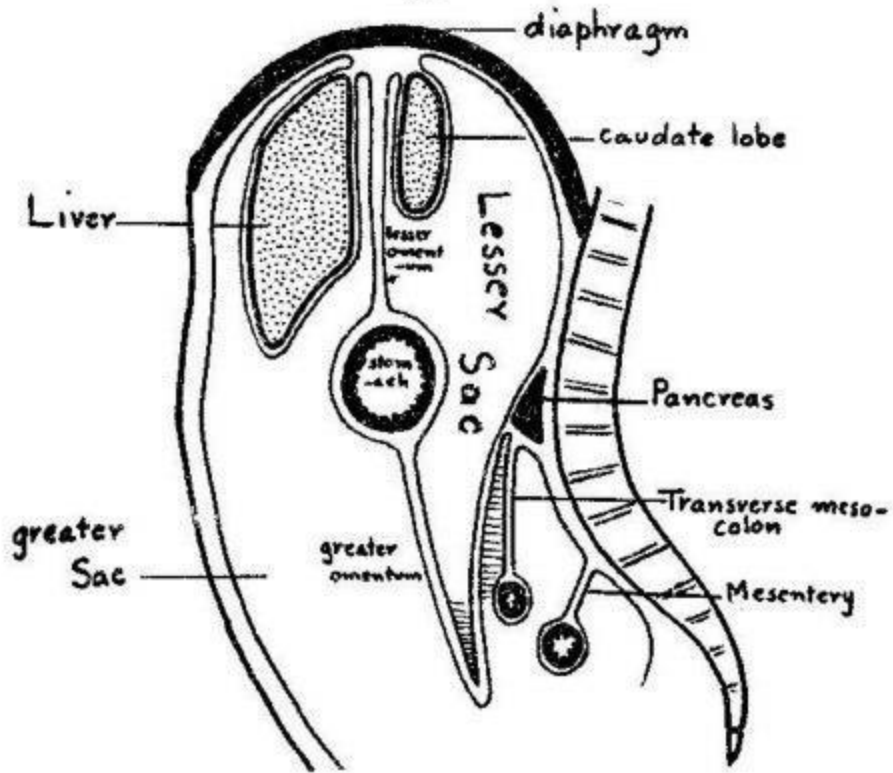
Structures behind liver



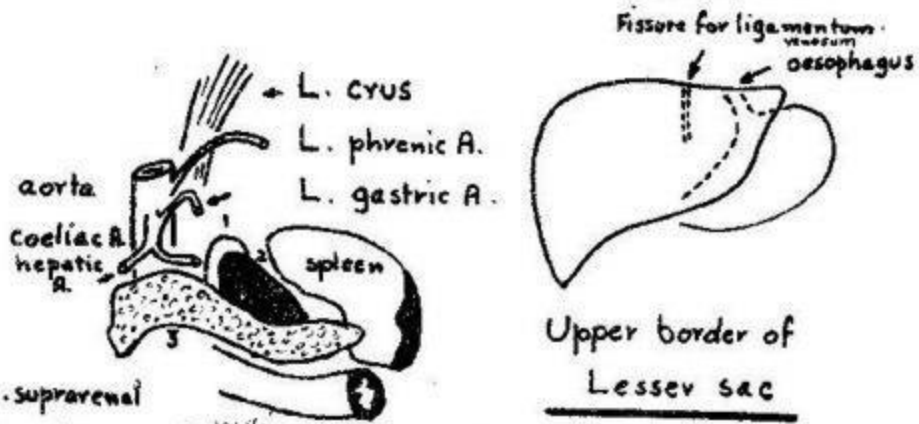
Bare area of liver



Tracing peritoneum on the left side of falciform ligament

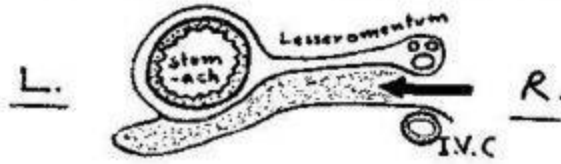


Greater and Lesser Sacs
(Sagittal section)

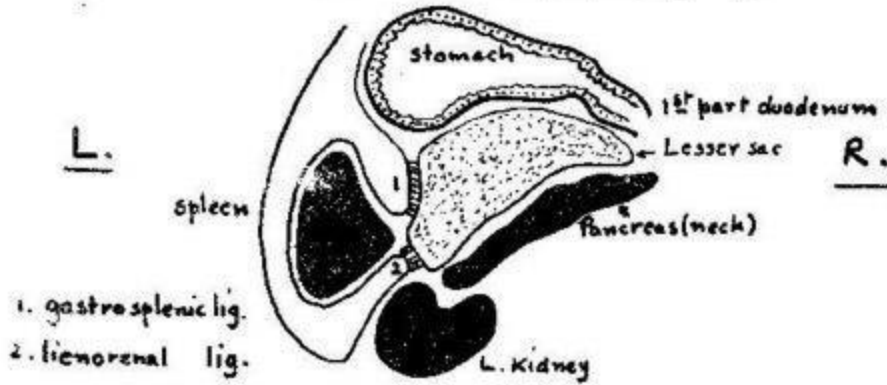


- 1. L. suprarenal
 - 2. L. Kidney
 - 3. Pancreas
- Posterior wall of Lesser Sac


Right + Left border of lesser sac




T.S. at opening into lesser sac



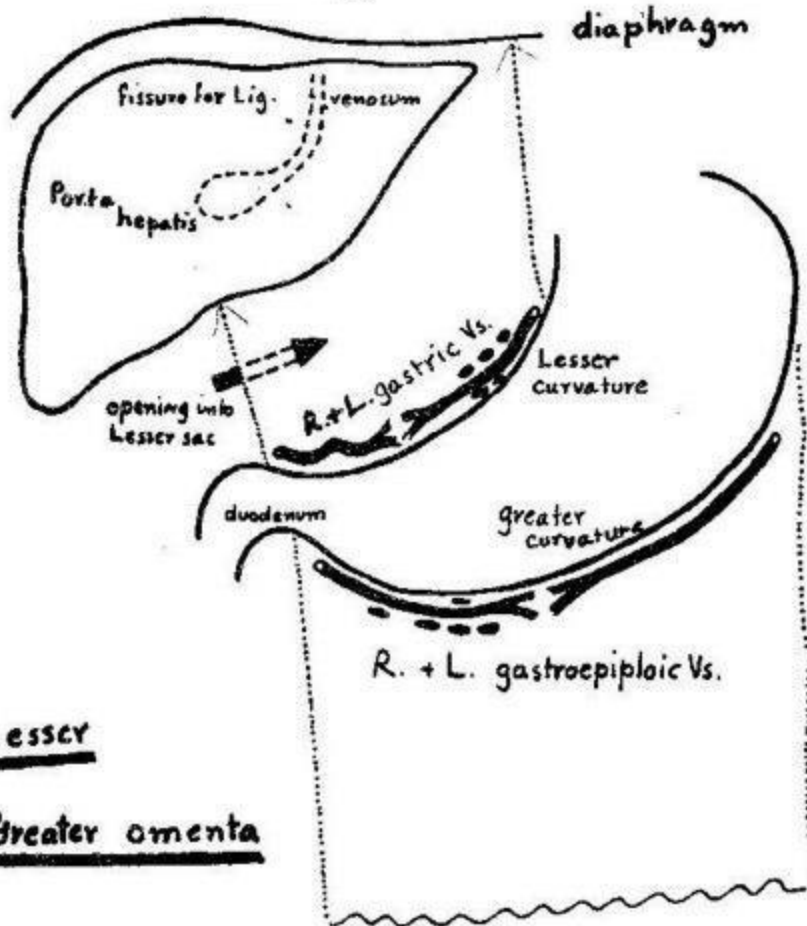
T.S. below opening into lesser sac



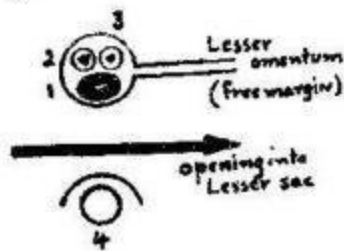
T.S. below stomach



Divisions of Lesser Sac

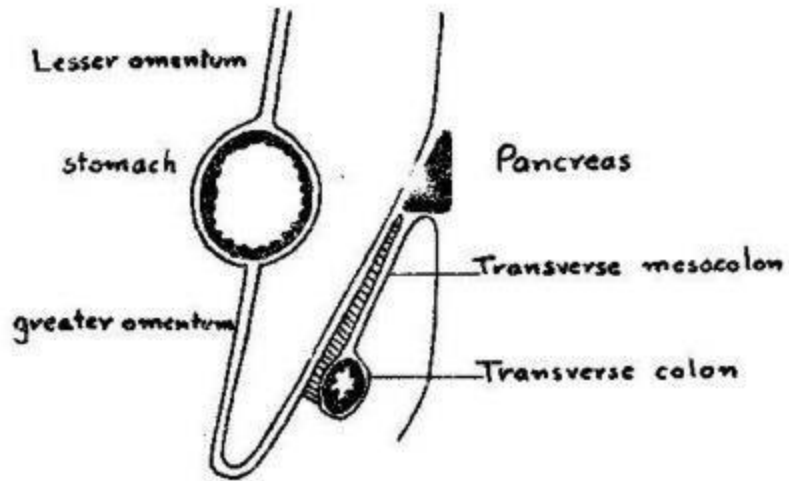


Lesser
and Greater omenta

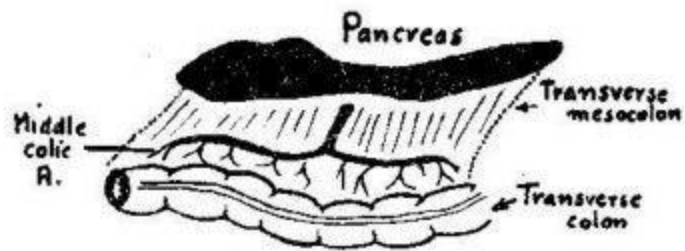


- 1. Portal V.
- 2. Bile duct
- 3. Hepatic A.
- 4. I. V.C.

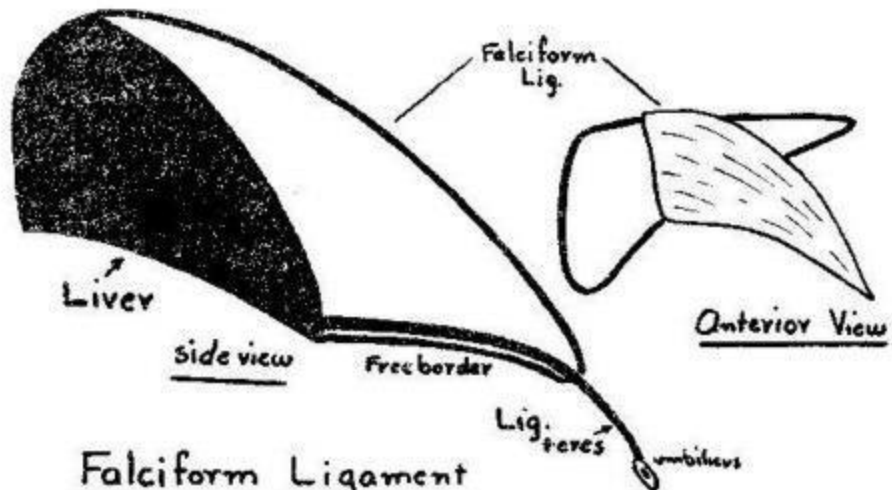
Opening into
Lesser sac (T.S.)



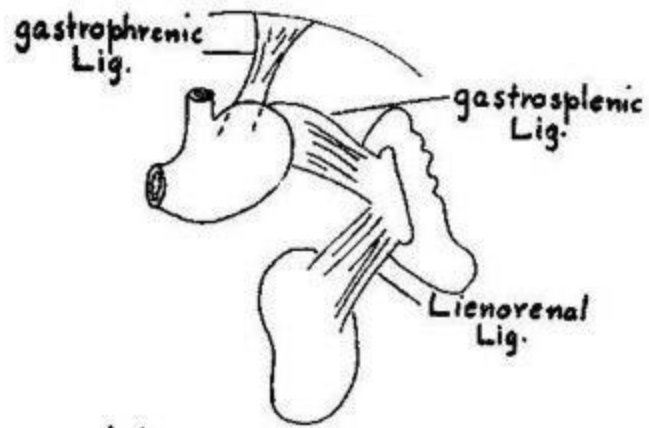
Greater omentum (side view)



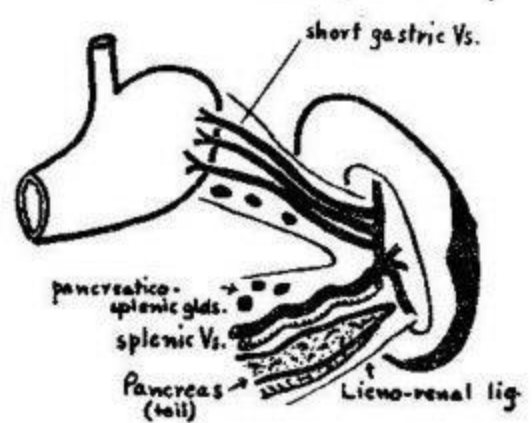
Transverse Mesocolon



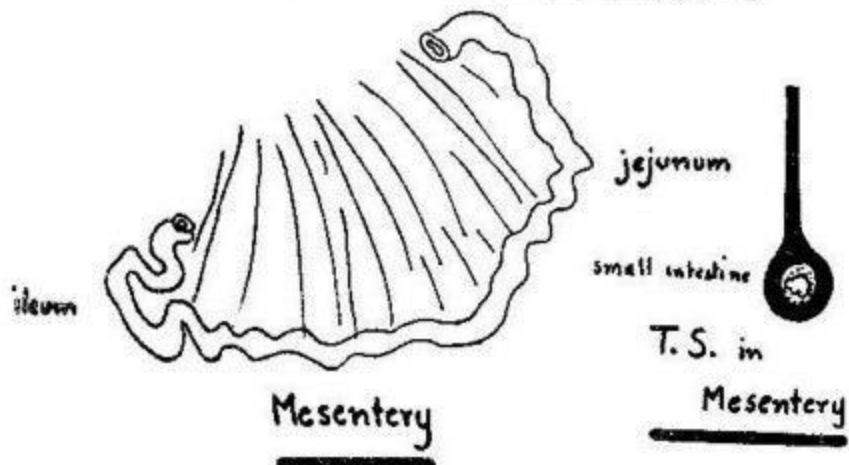
Falciform Ligament



Ligaments of spleen



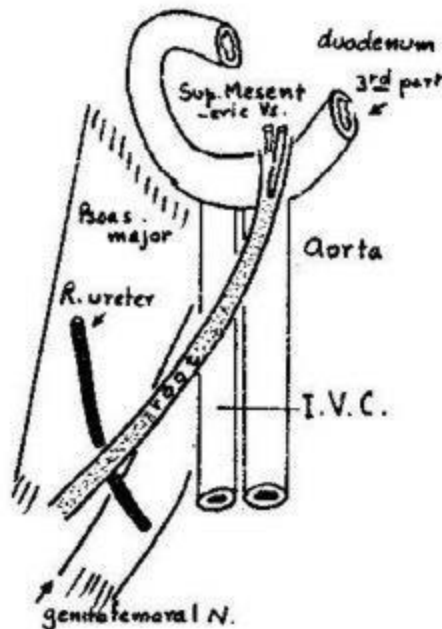
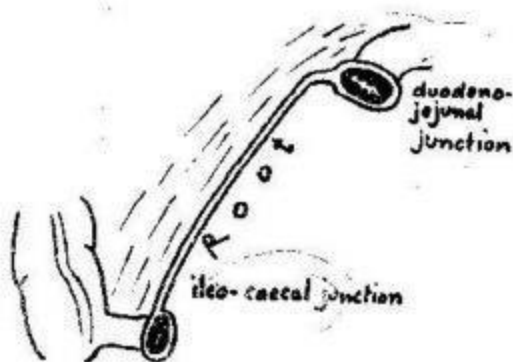
Contents of gastrosplenic + lienorenal ligaments



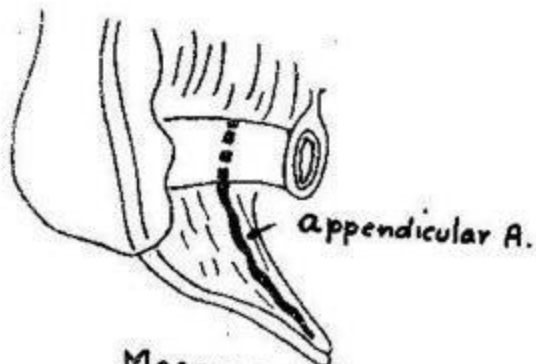
Mesentery

T.S. in Mesentery

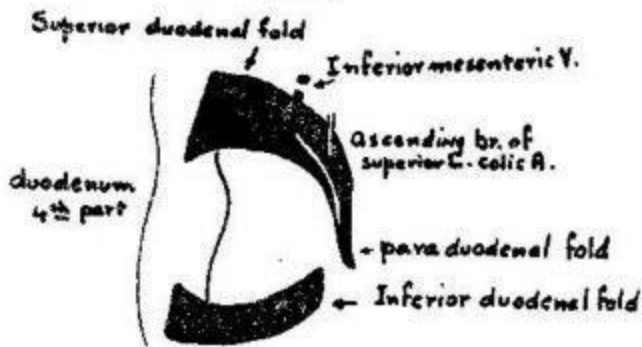
Root of Mesentery



Relations of root of Mesentery




Mesoappendix

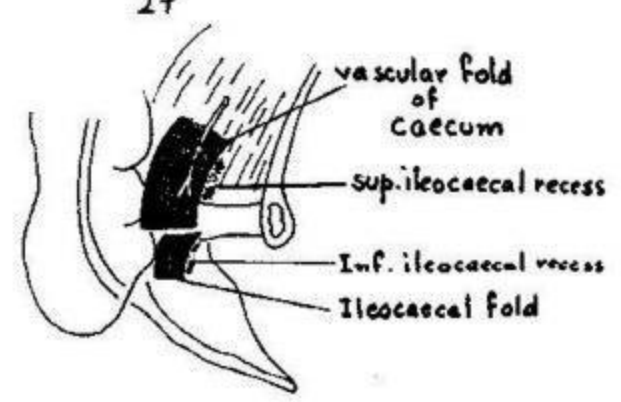


Folds of duodenum

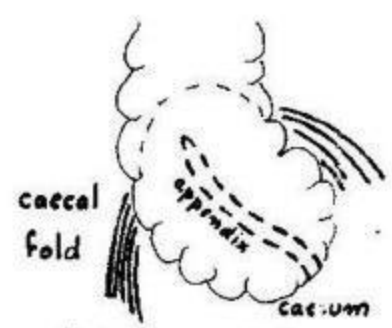




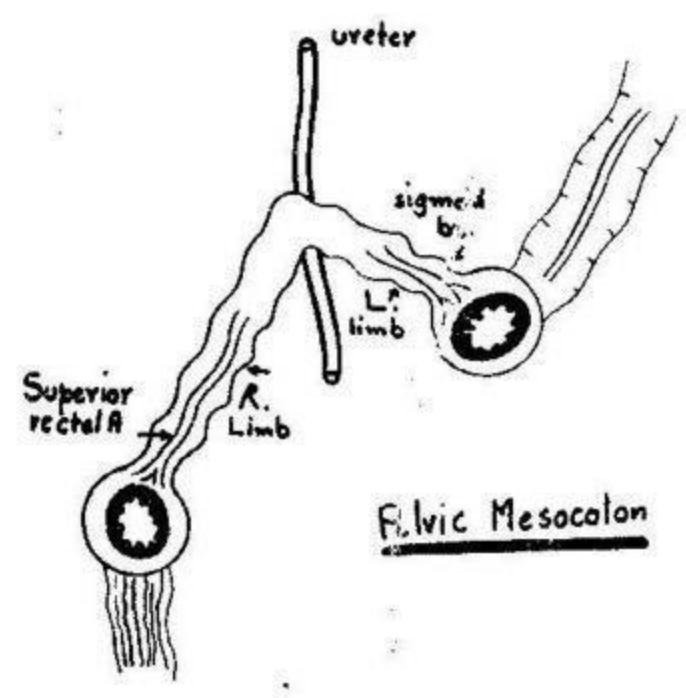
Retroduodenal Recess



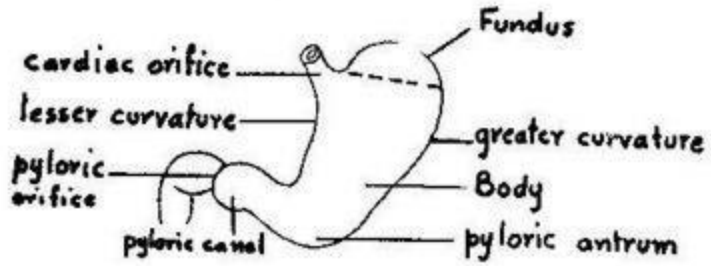
Folds of caecum



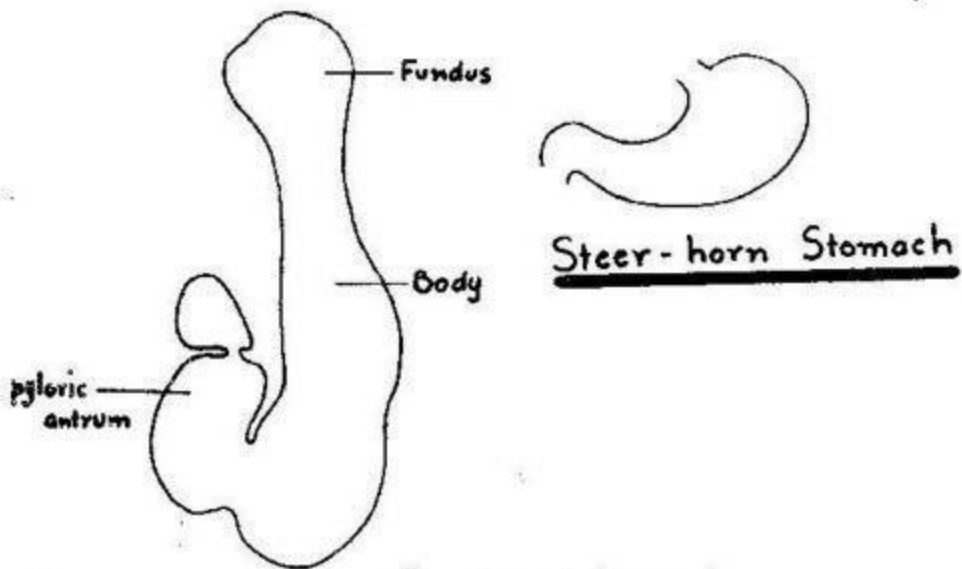
Retrocaecal Recess



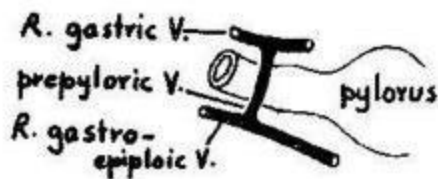
Pelvic Mesocolon



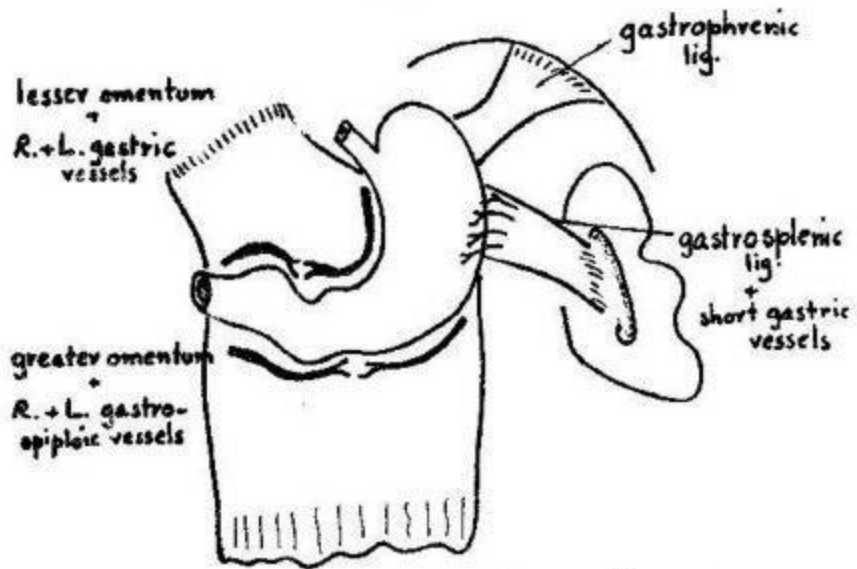
Divisions of Stomach



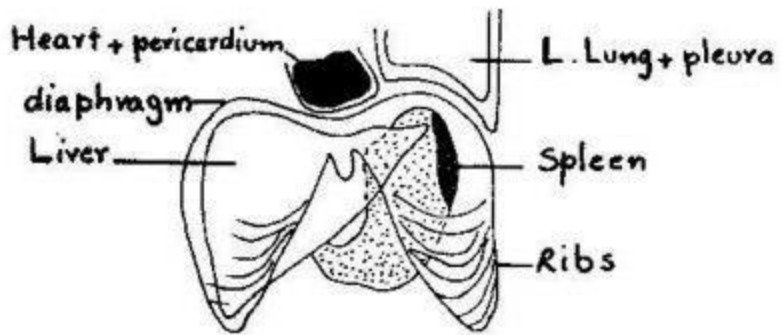
J. shaped Stomach



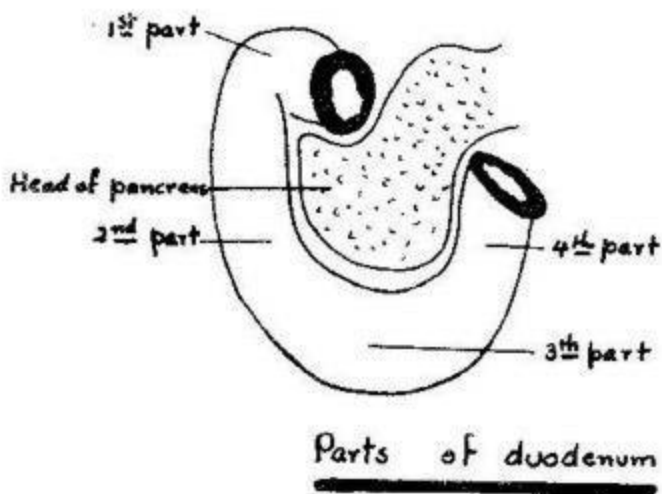
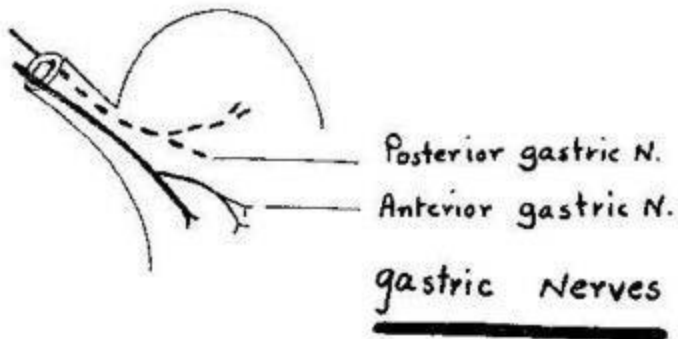
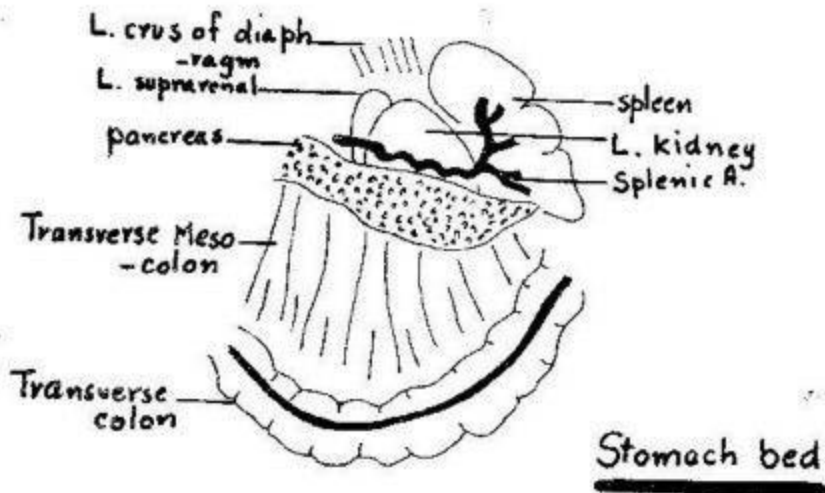
Prepyloric Vein

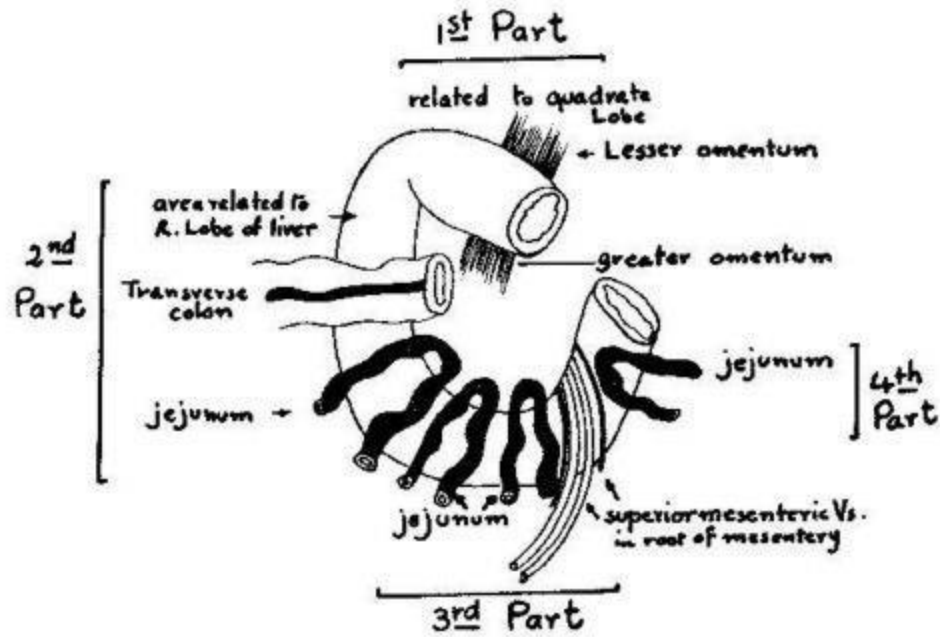


Lesser and Greater Curvatures

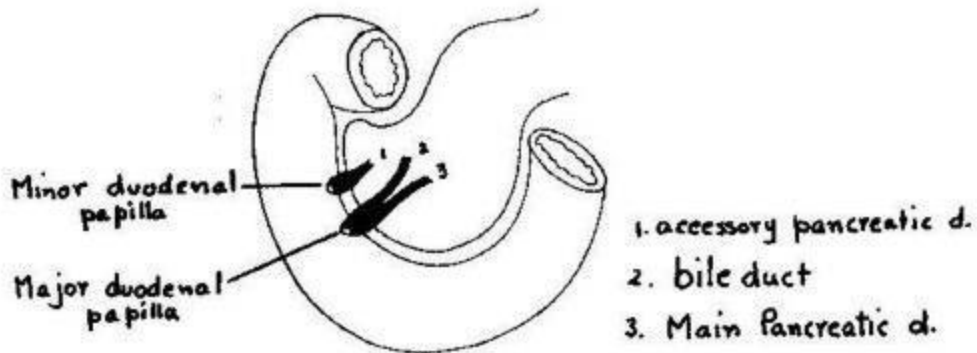


Antero-superior surface





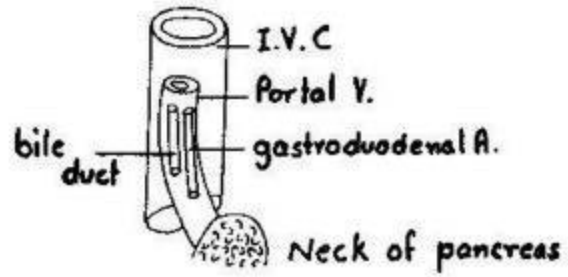
Anterior relations of duodenum



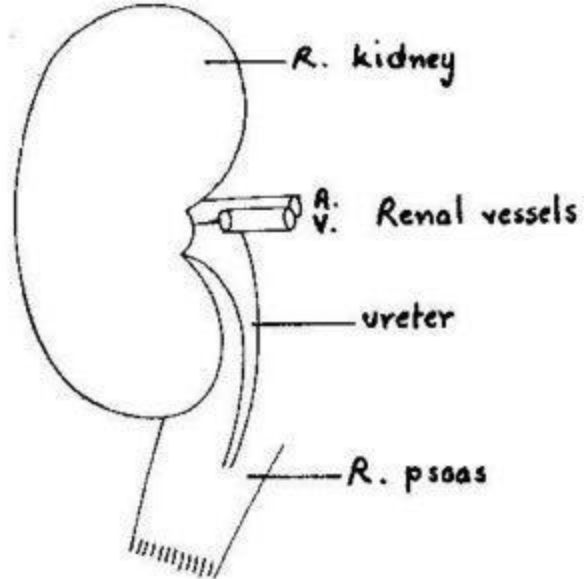
Duodenal Papillae

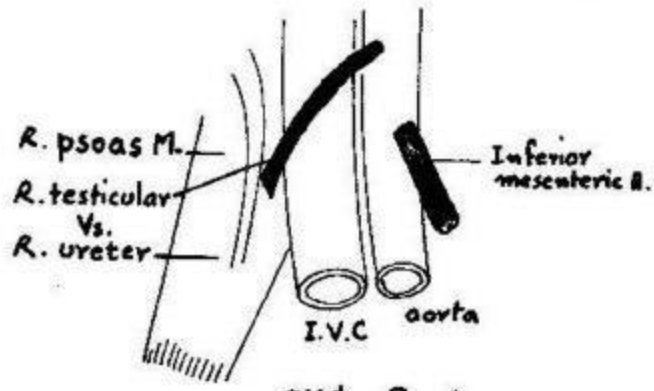
Posterior relations of duodenum

First Part

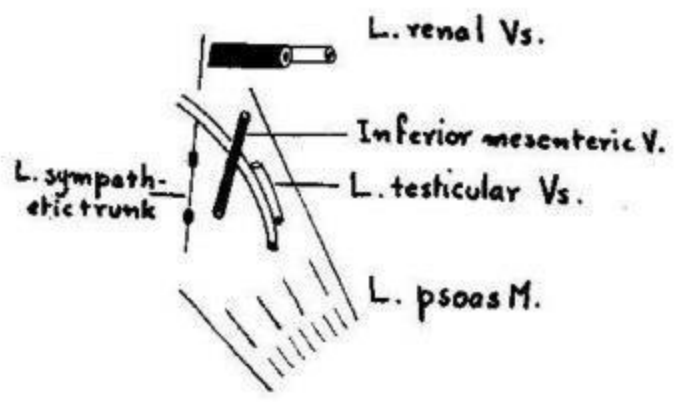


Second Part





3rd Part

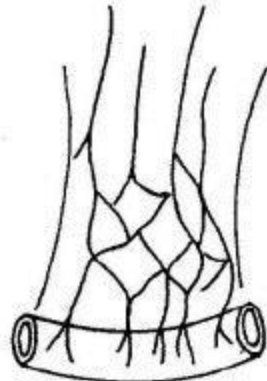
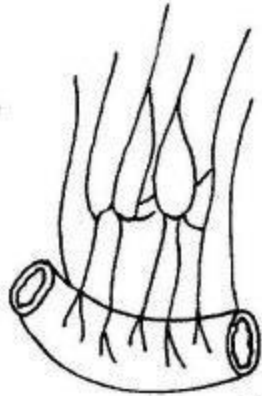


4th Part

Jejunum

34

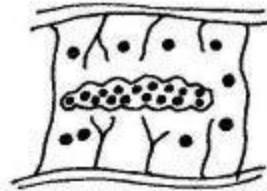
Ileum



Arterial Arcades



Circular folds



Peyer's patch



Villi (jejunum)

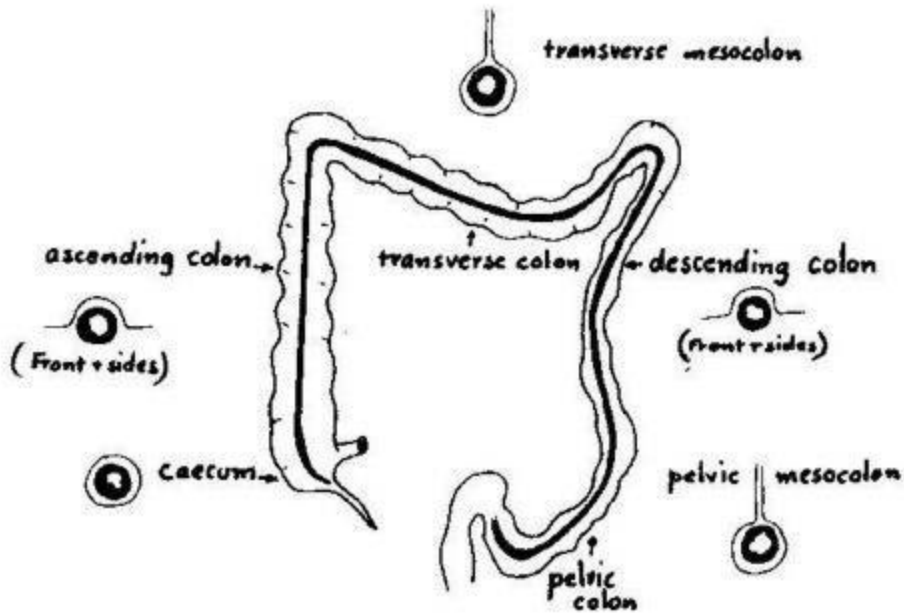
taeniae coli



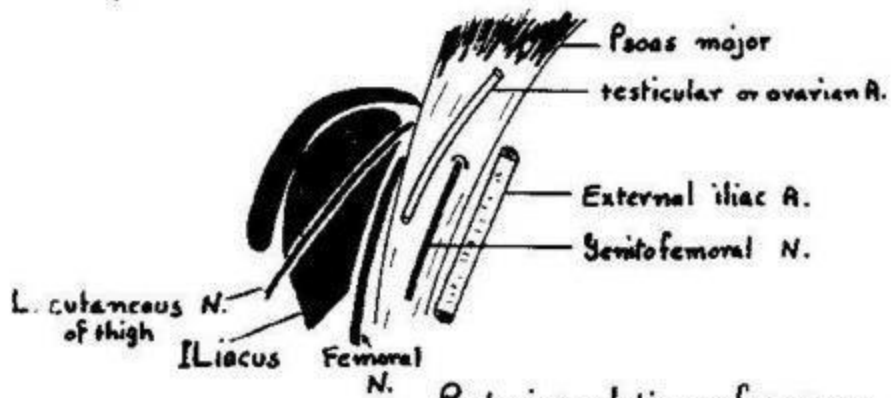
sacculatation

appendices vermiformes

characters of large intestine

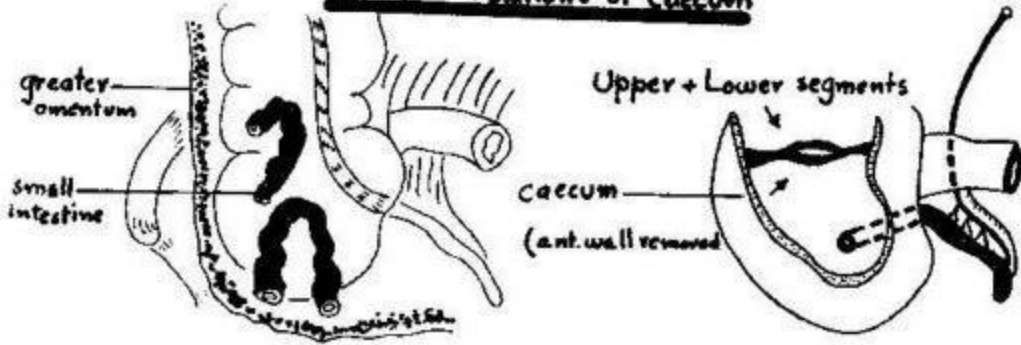


Peritoneum of large intestine

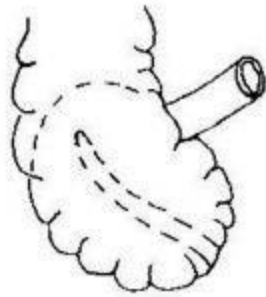


Posterior relations of caecum

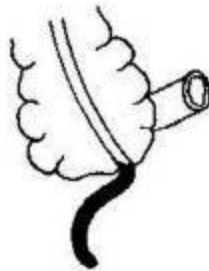
Anterior relations of caecum



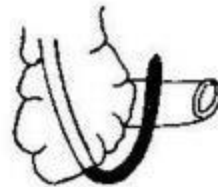
Ileocaecal valve
Appendicular Artery



retrocaecal appendix



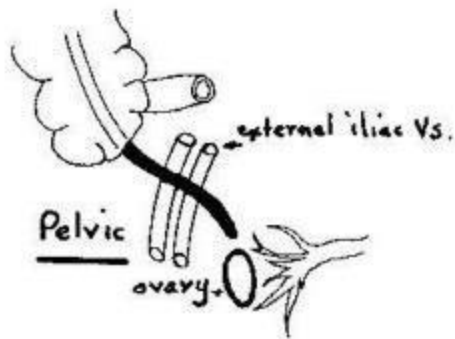
subcaecal appendix



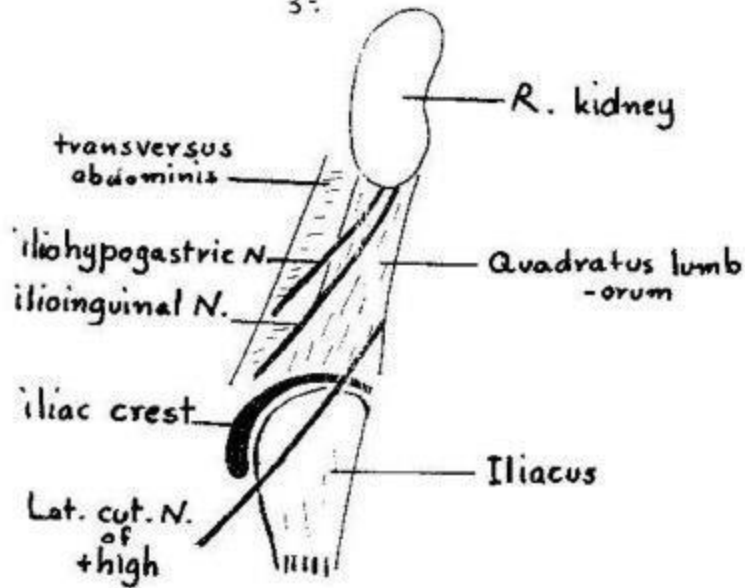
anteileal



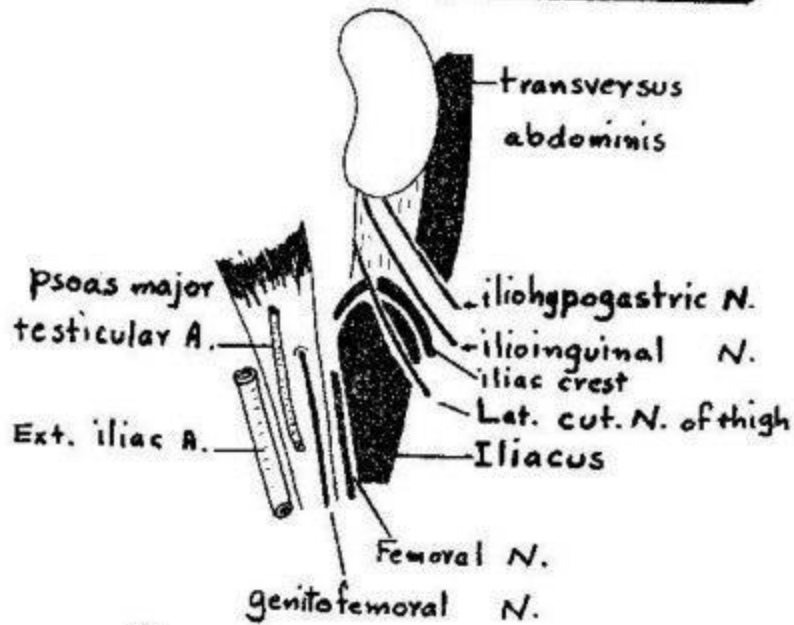
retroileal



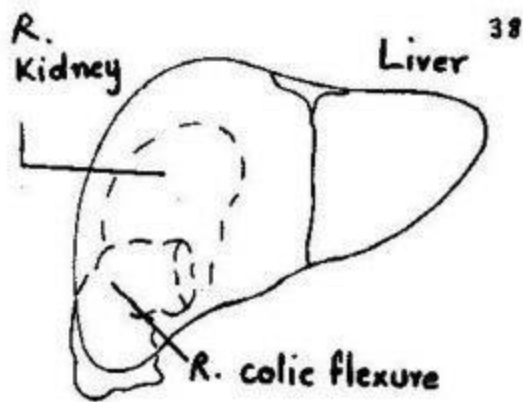
Positions of the vermiform appendix



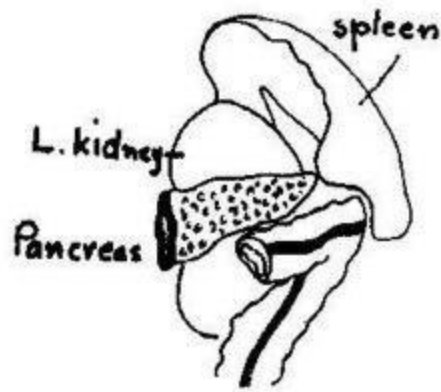Posterior relations of ascending colon



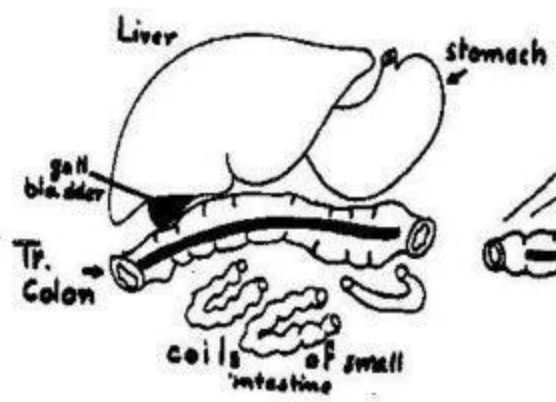
Posterior relations of descending colon



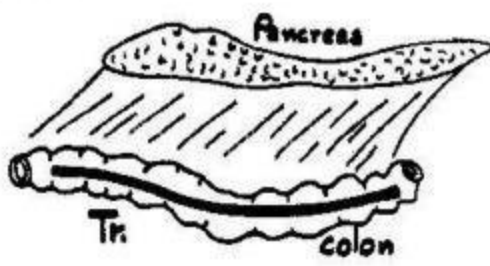
Right colic flexure



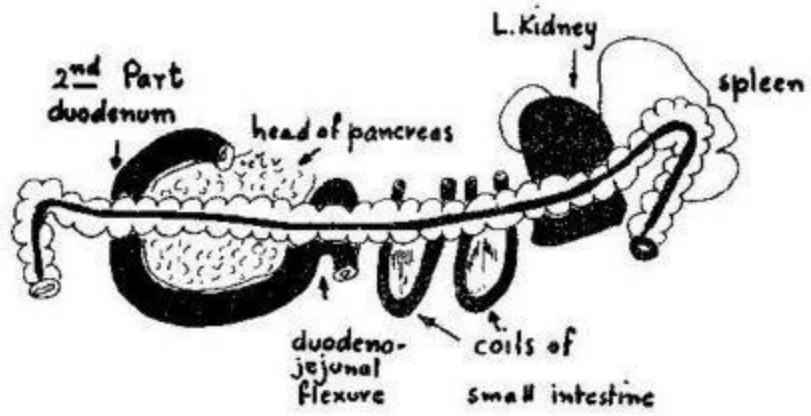
Left colic flexure



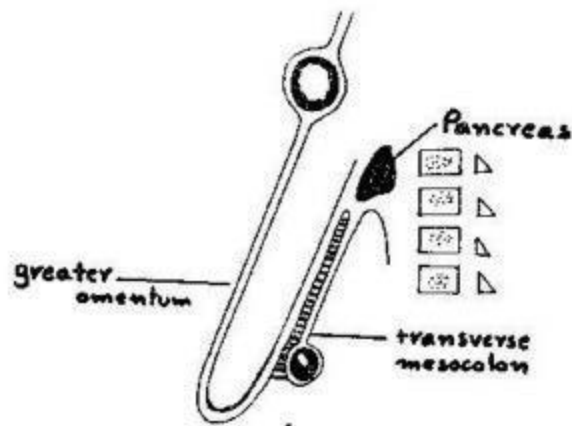
Superior + Inferior relations of Transverse Colon



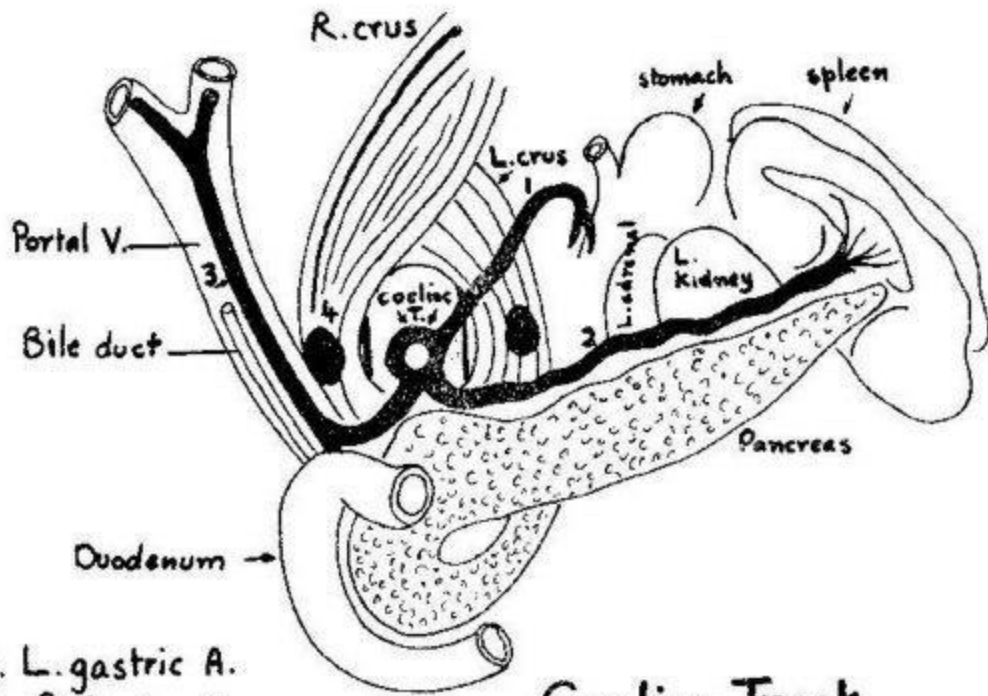
Transverse Mesocolon



Posterior relations of transverse colon

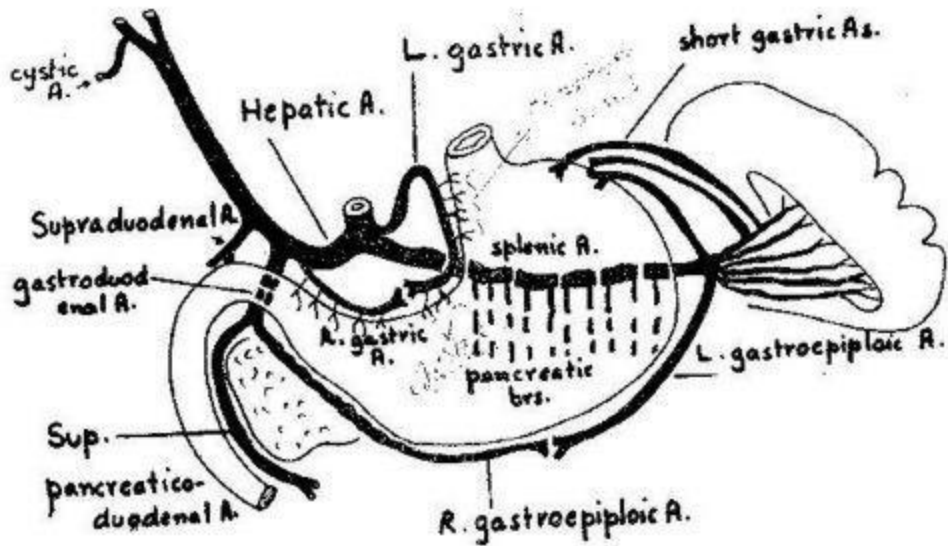


Attachment of transverse mesocolon

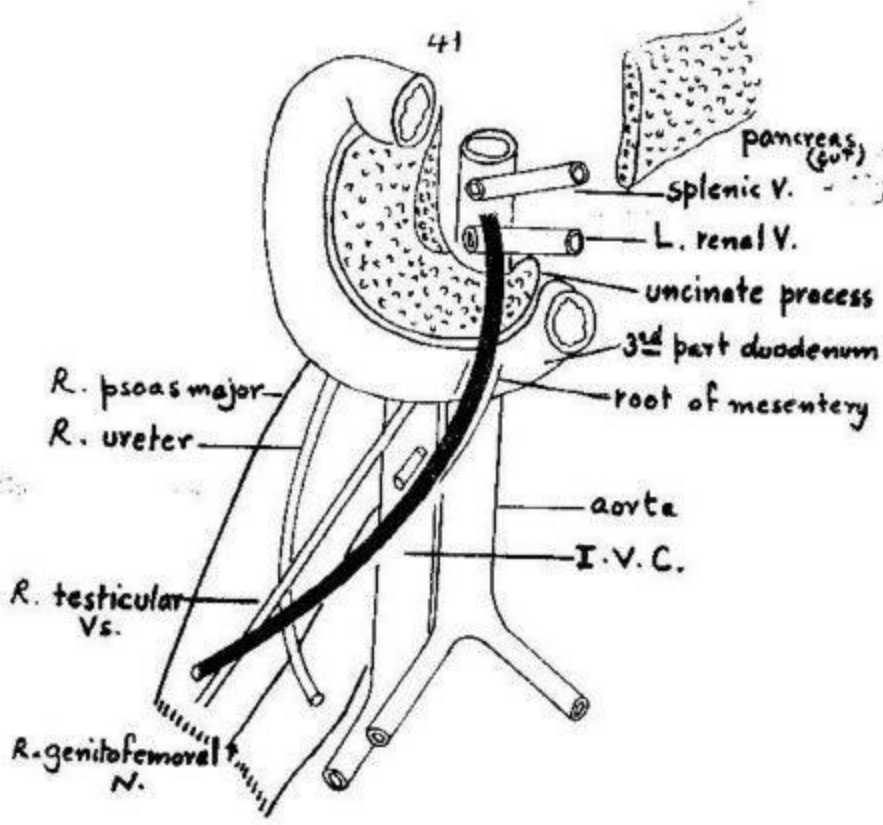


1. L. gastric A.
2. Splenic A.
3. Hepatic A.
4. Coeliac ganglion

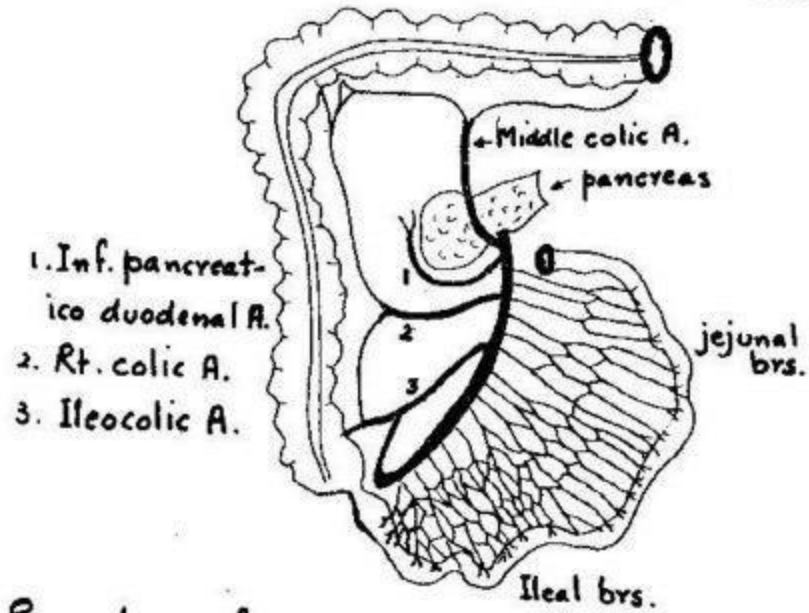
Coeliac Trunk



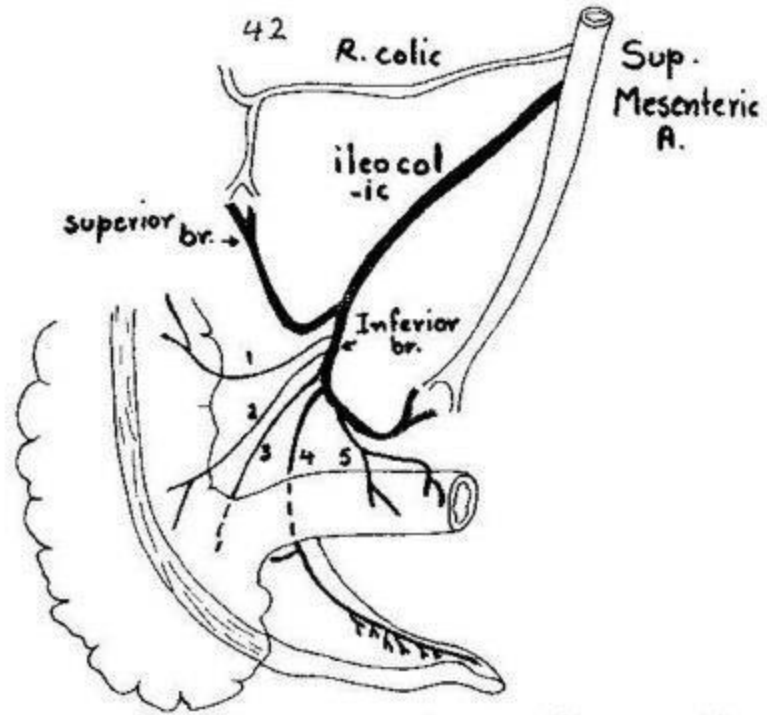
Branches of coeliac artery



Relations of superior mesenteric artery

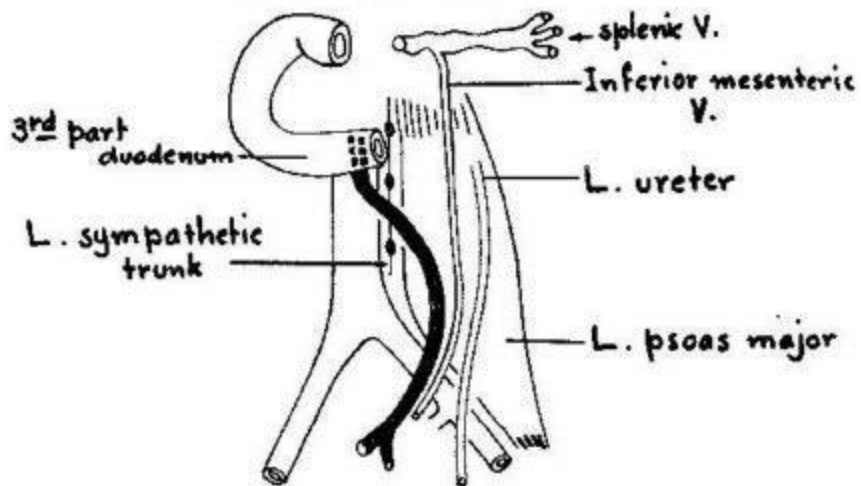


Branches of superior mesenteric artery



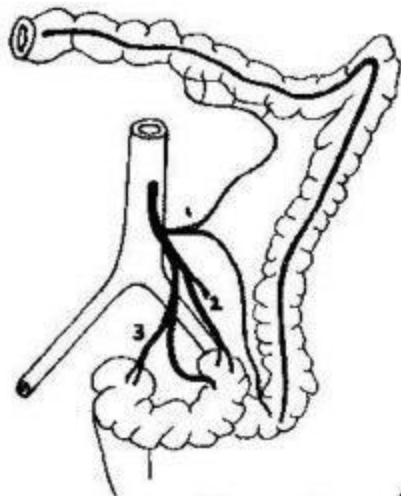
1. Ascending br. 2. Ant. caecal br. 3. Post. caecal br.
 4. Appendicular A. 5. Ileal br.

Branches of ileocolic artery



Relations of inferior mesenteric artery

43

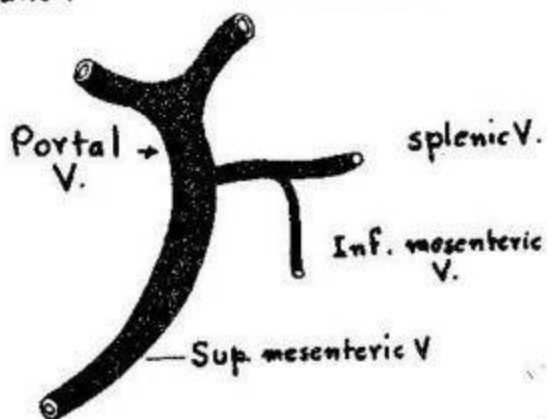


1. Sup. L. colic A.
2. Inf. L. colic As.
3. Sup. rectal A.

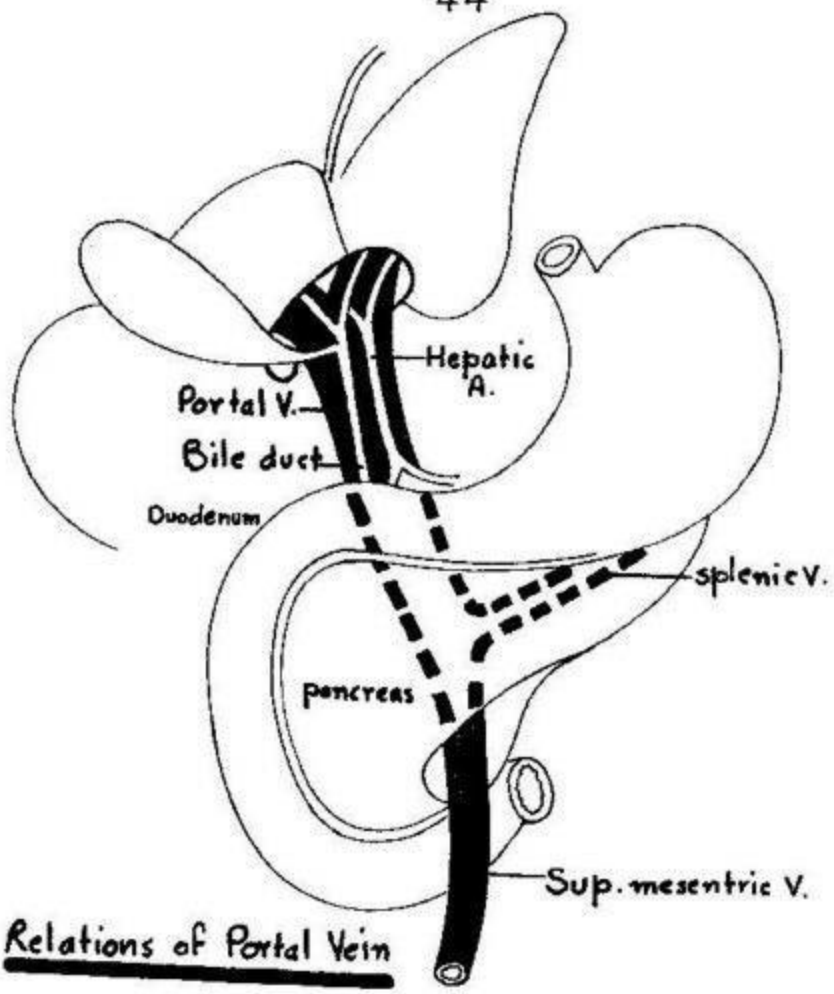
Branches of inferior mesenteric artery

R. branch

L. branch



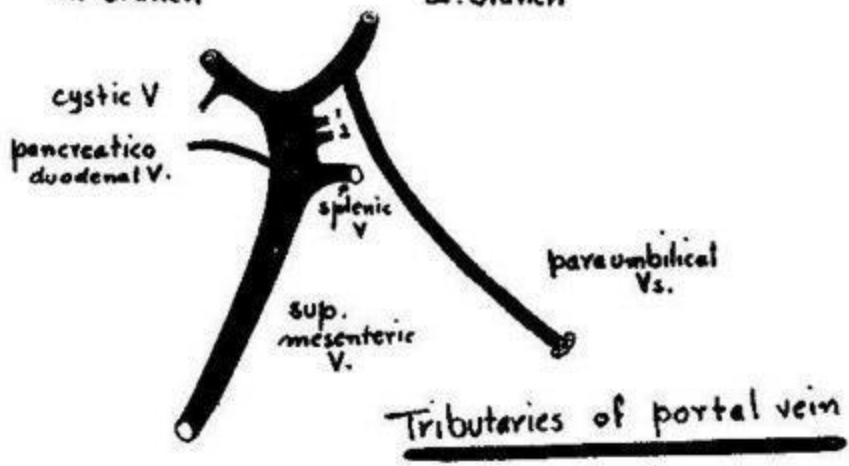
Formation of portal vein



Relations of Portal Vein

R. branch

L. branch




Tributaries of portal vein

1. R. gastric V.

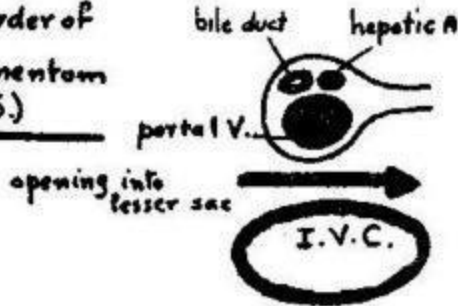
2. L. gastric V.

45
Relations of portal vein + bile duct

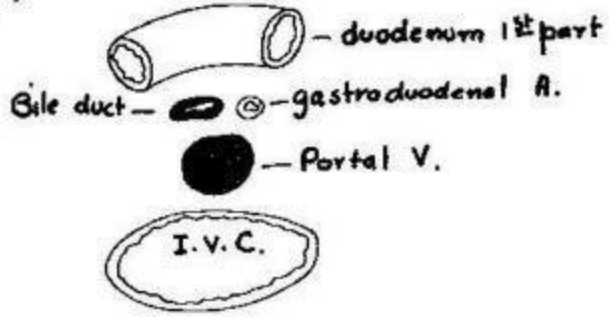
In porta hepatis (T.S.)



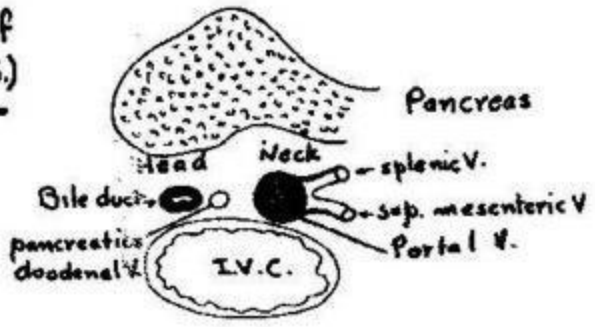
In free border of lesser omentum (T.S.)



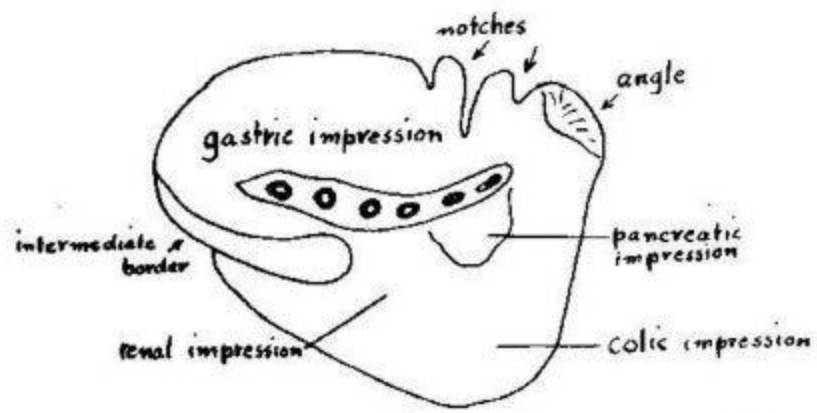
behind 1st part duodenum (T.S.)



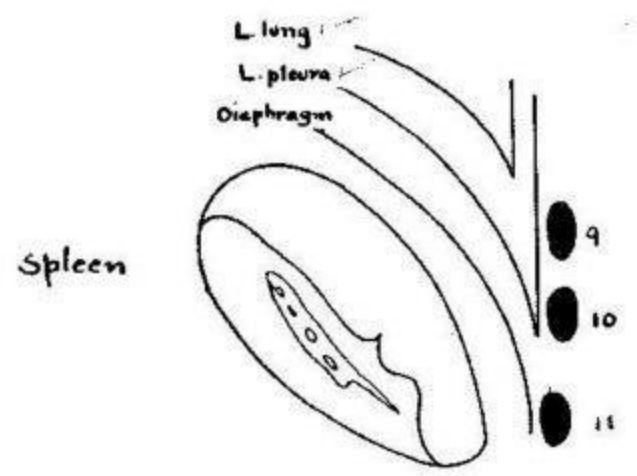
Behind neck of pancreas (T.S.)



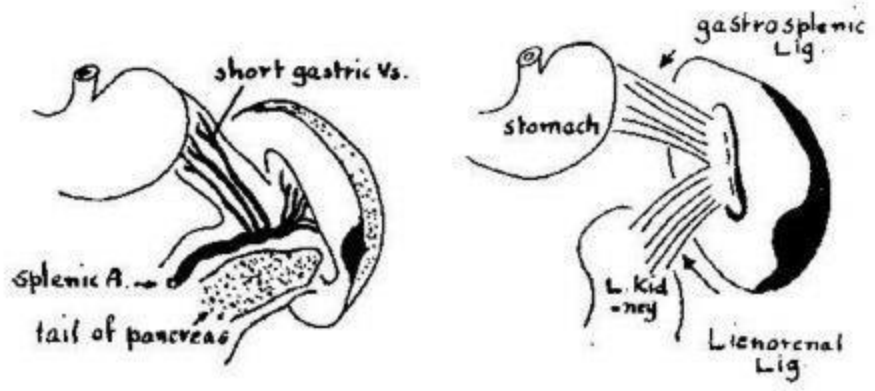
46




Spleen (Visceral surface)



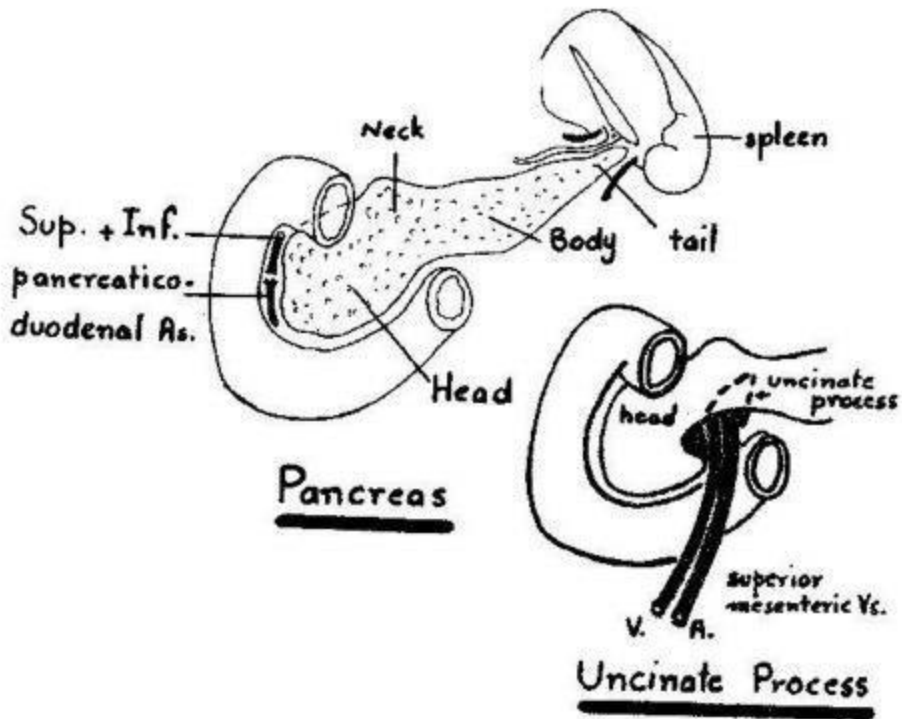
Diaphragmatic surface

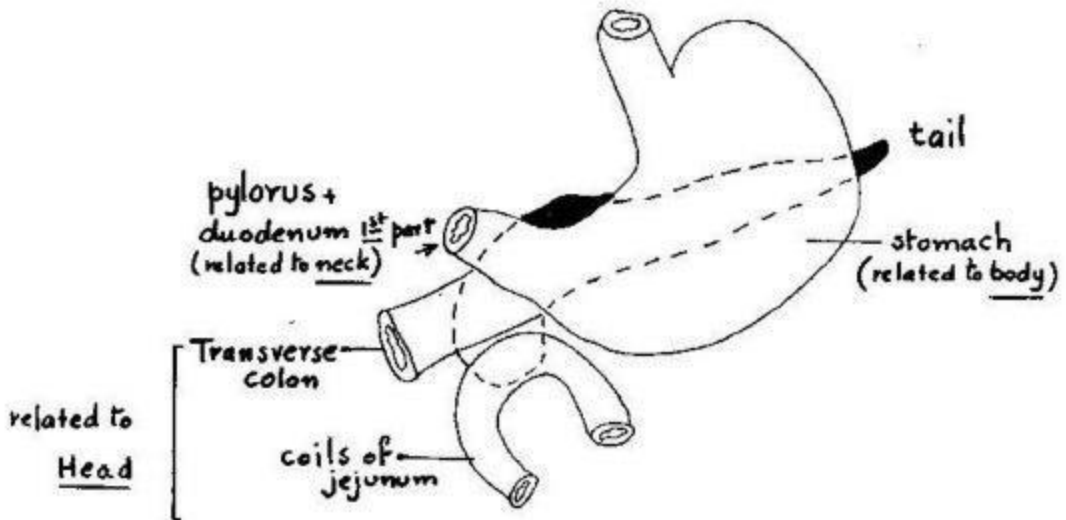


gastrosplenic + lienorenal ligaments

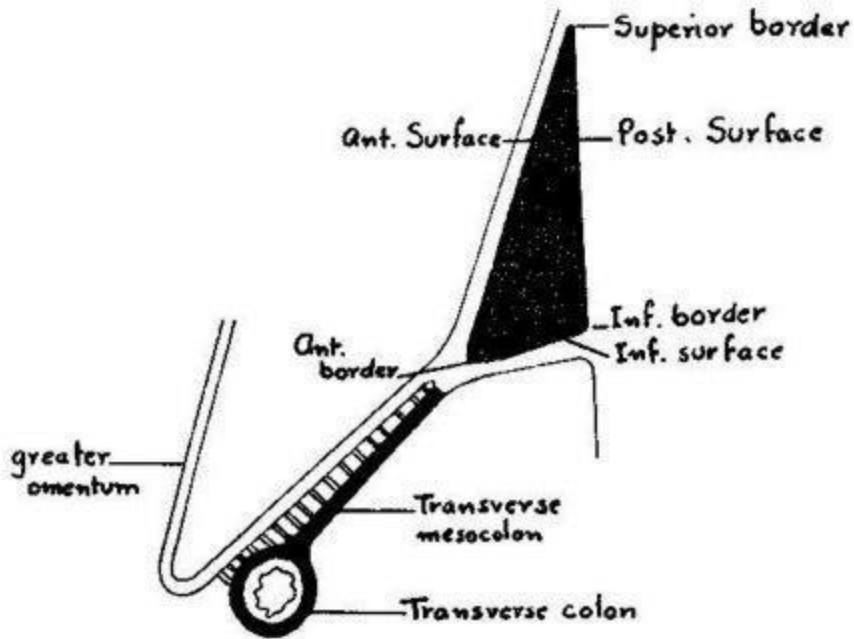


Relation of spleen to ribs

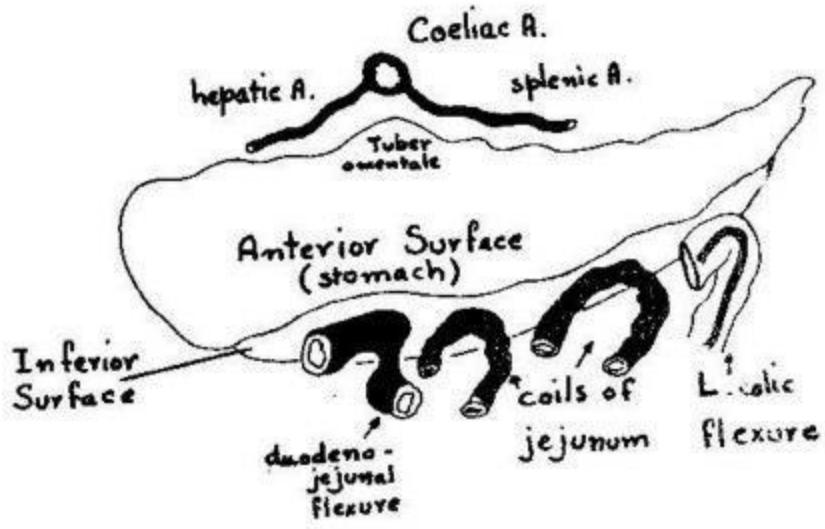




Anterior relations of Pancreas

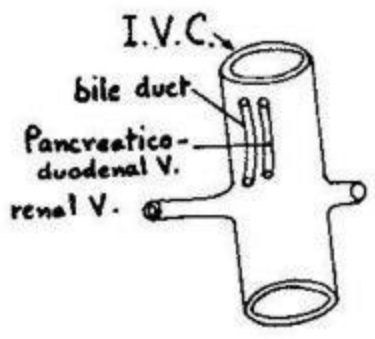


Surfaces and borders of Pancreas (T.S.)




Relations of anterior surface and inferior surface

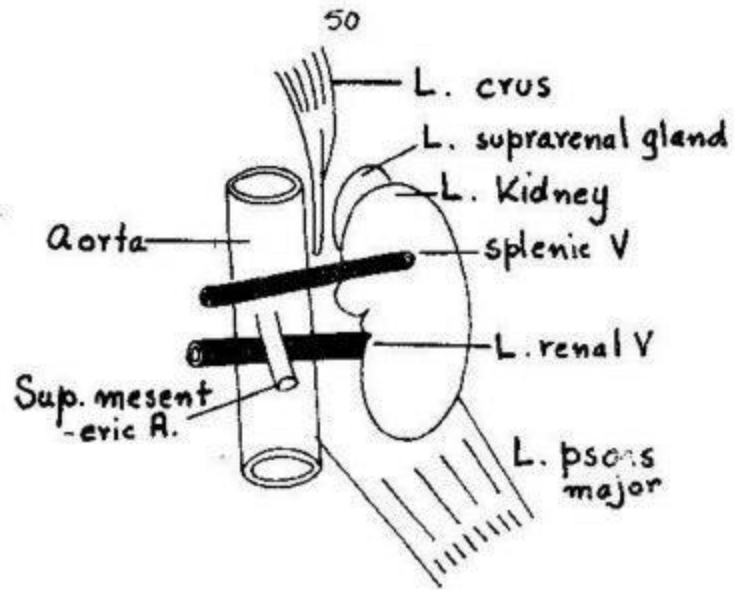
Posterior relations of Pancreas



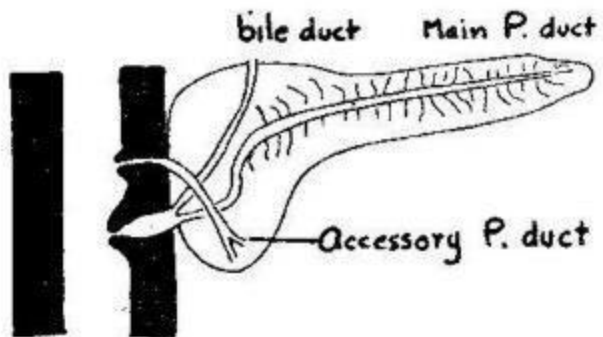
1. Head



2. Neck

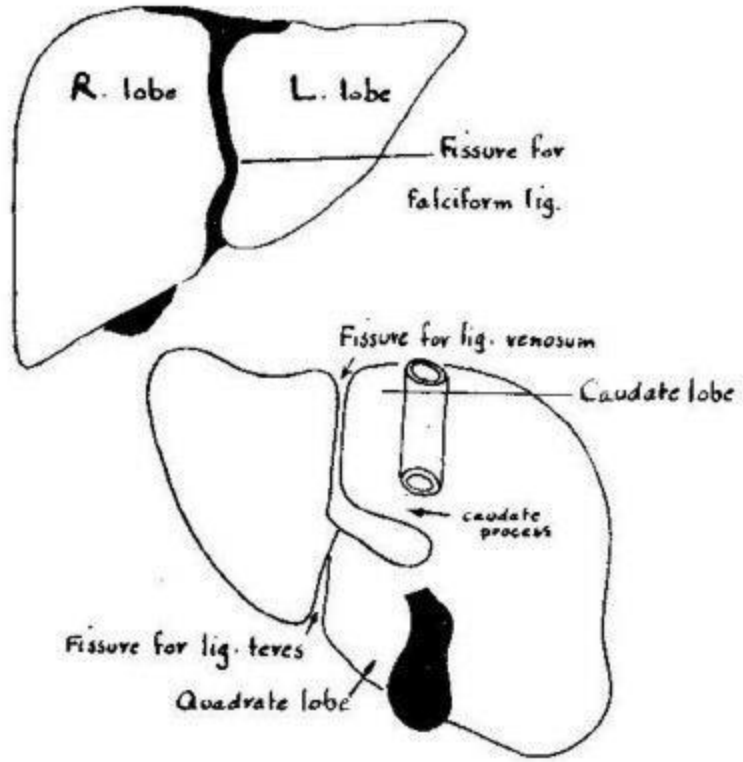


3. Body (Post. relations)

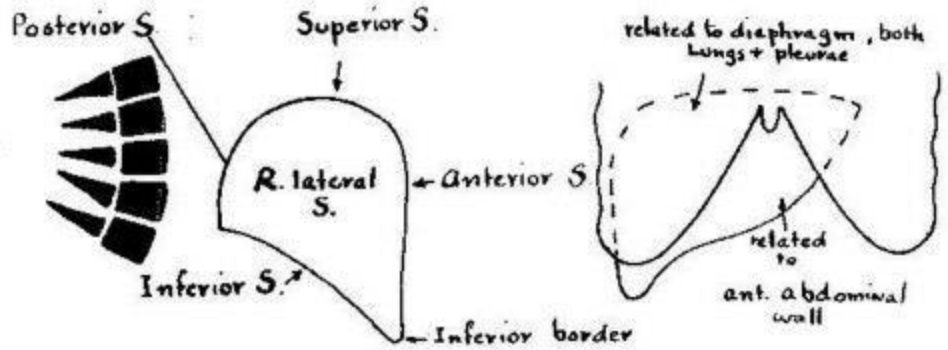


Pancreatic Ducts

51
Lobes of liver

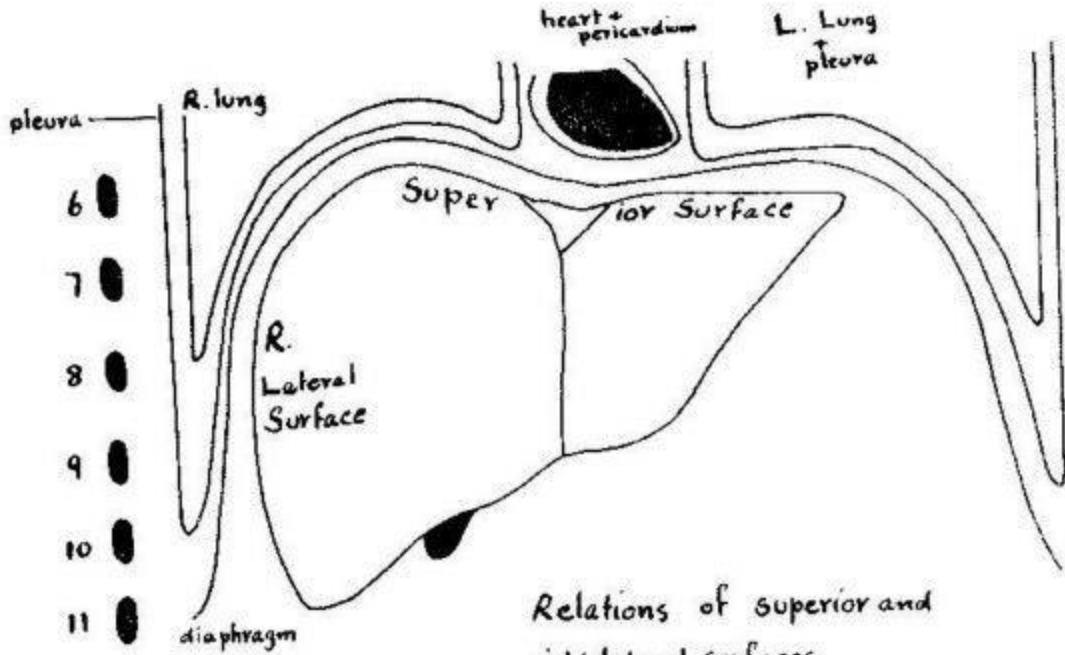


Lobes of liver (Post. view)

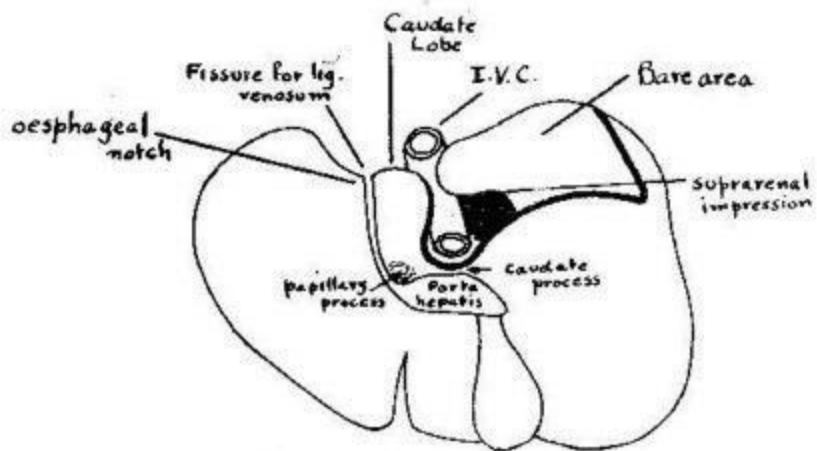


Surfaces of Liver (seen from right side)

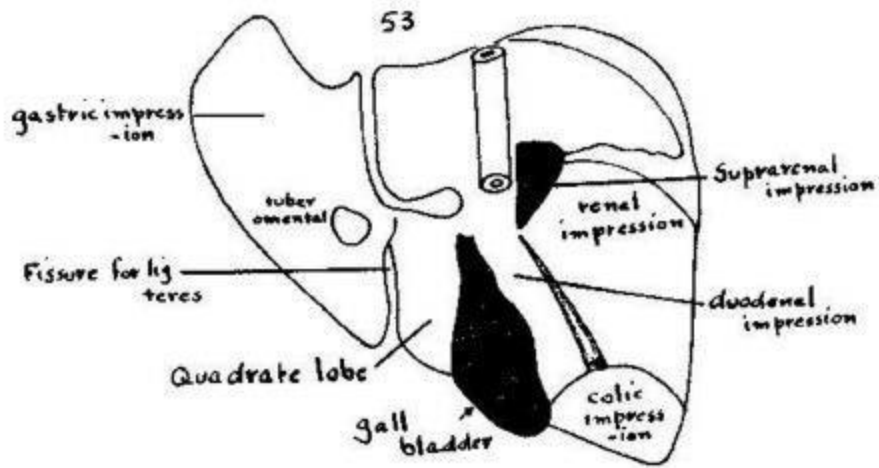
Relations of anterior surface



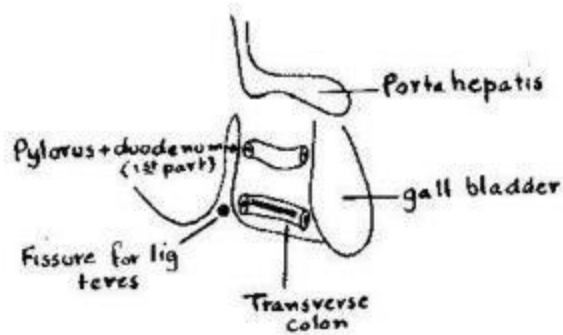
Relations of superior and right lateral surfaces



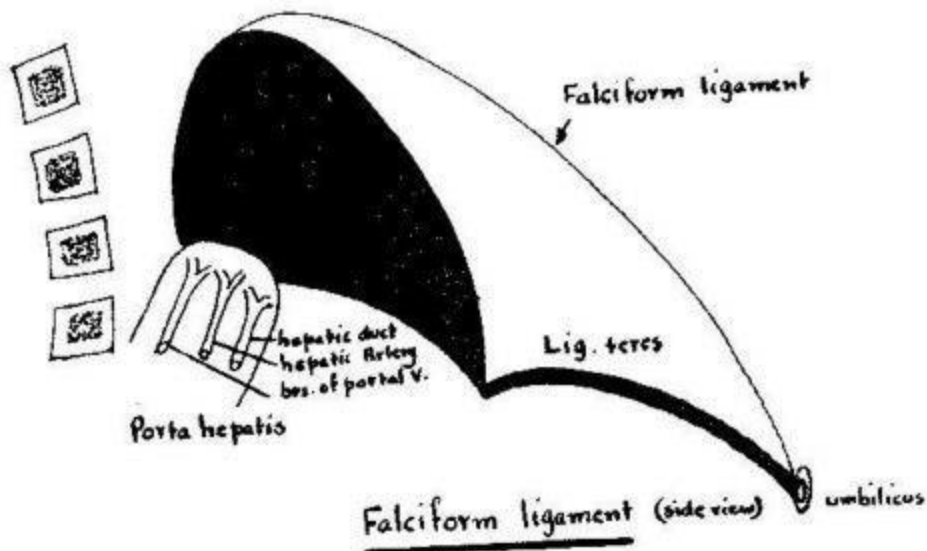
Relations of posterior surface

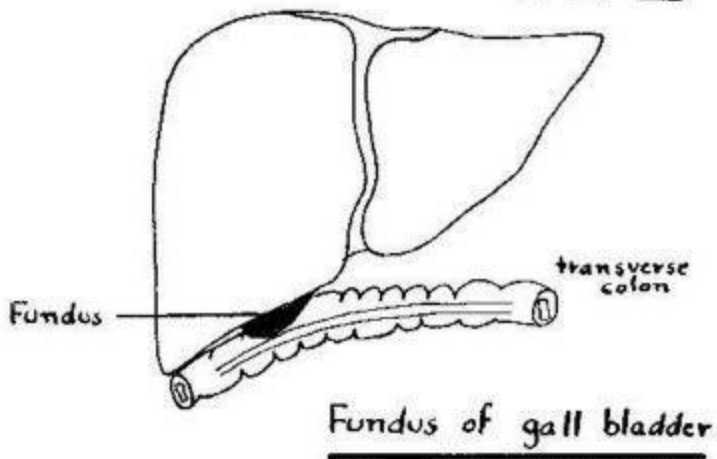
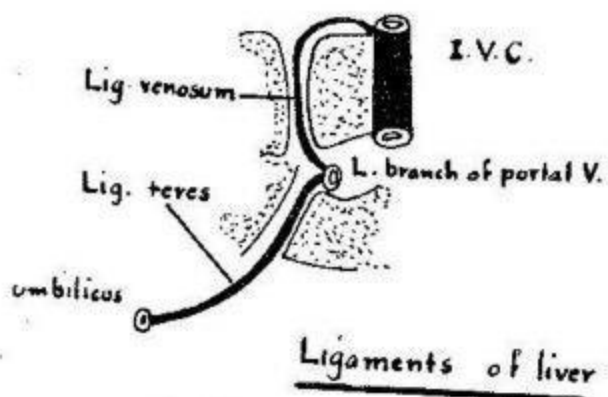
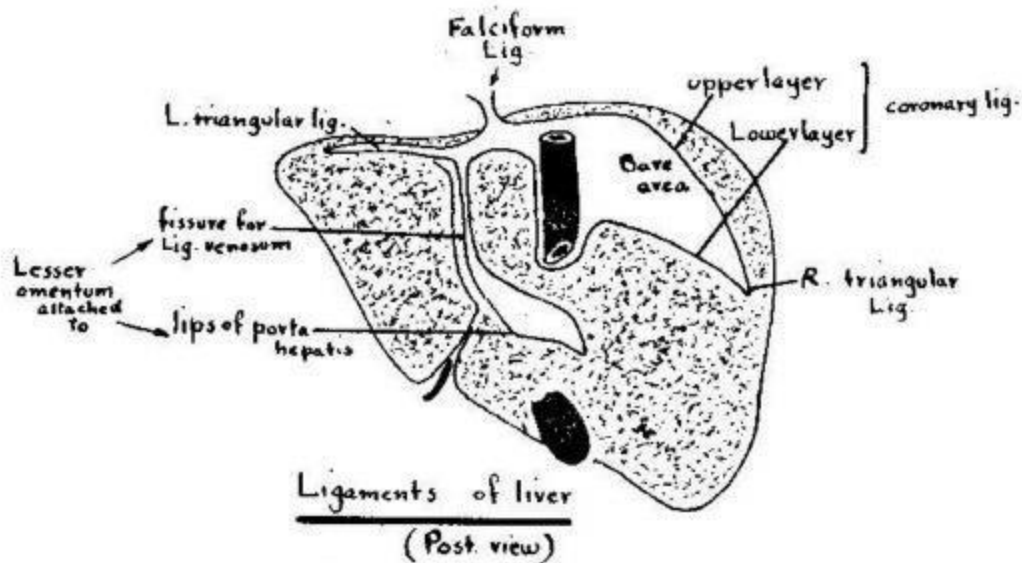


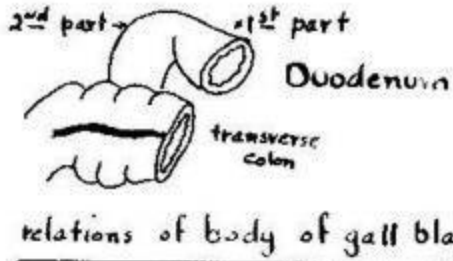
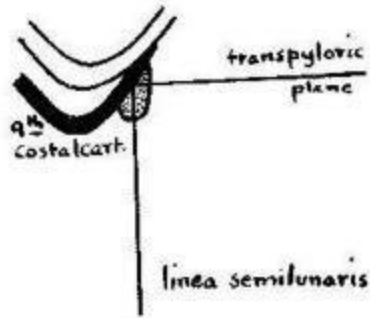
Relation of inferior surface



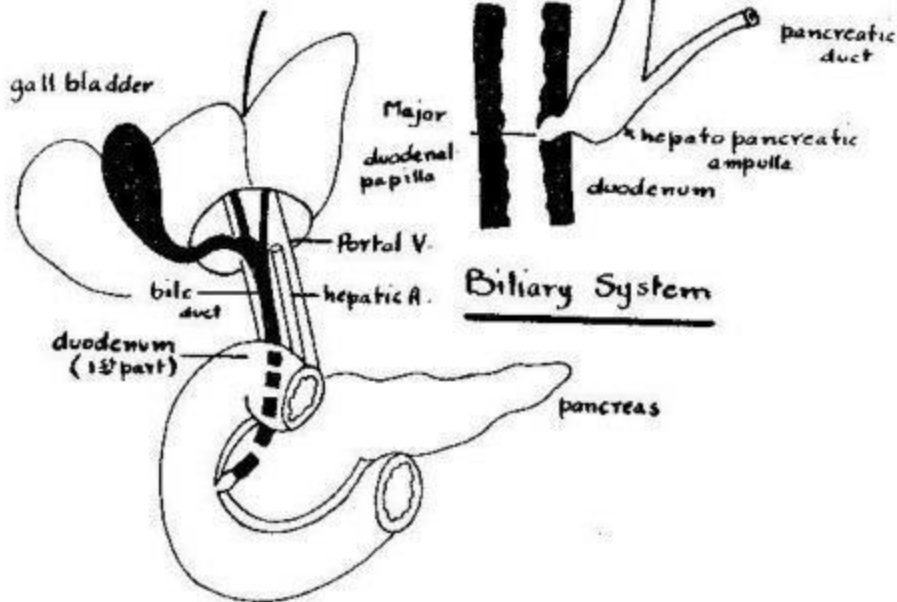
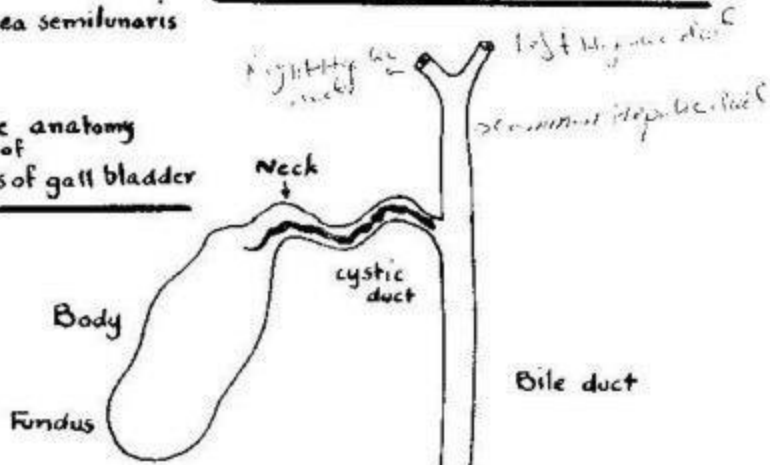
Relation of quadrate lobe



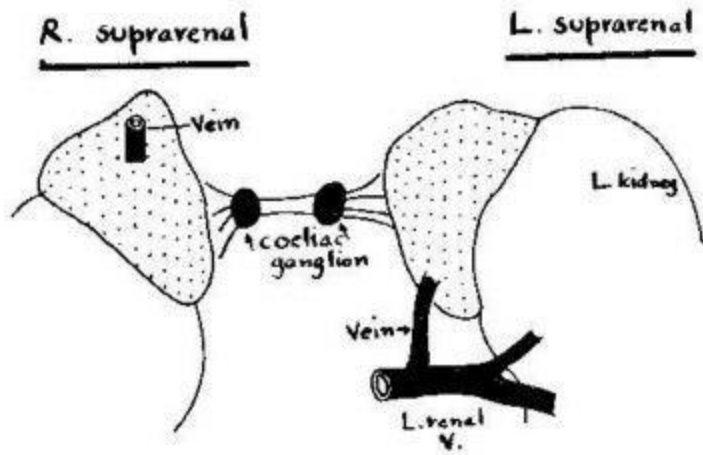
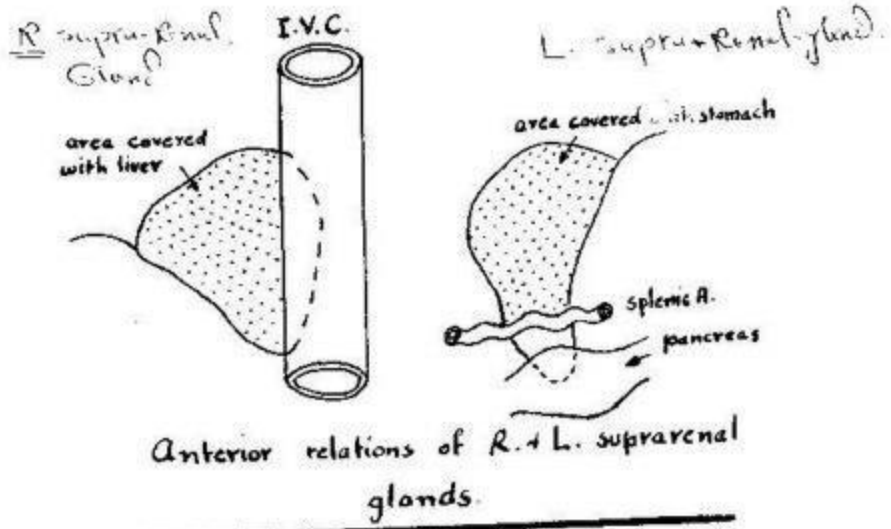


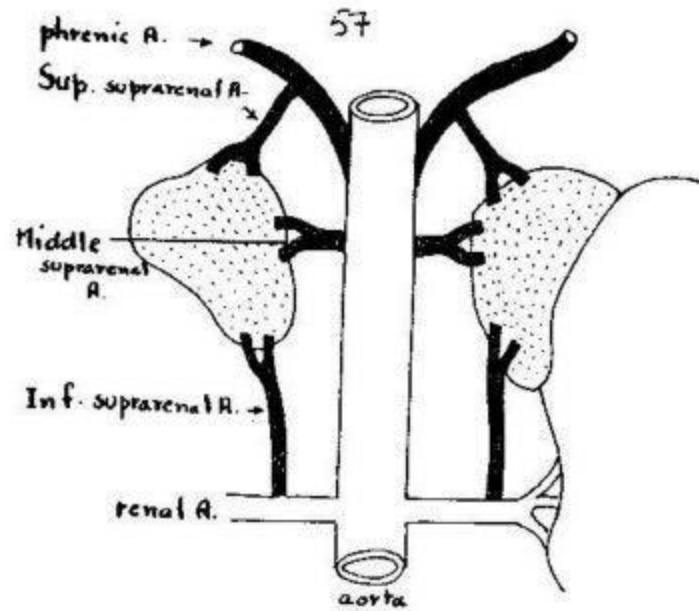


Surface anatomy of fundus of gall bladder

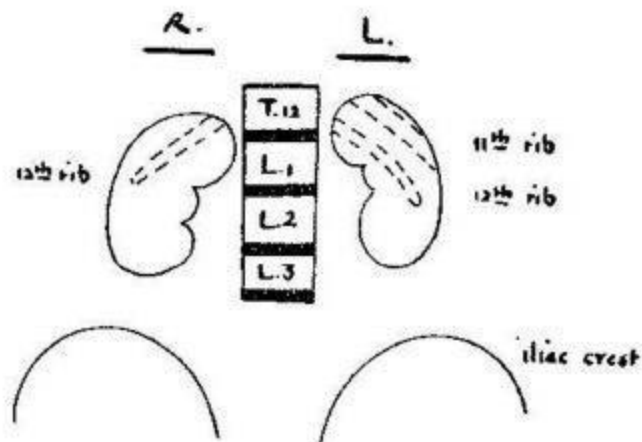


Relations of bile duct

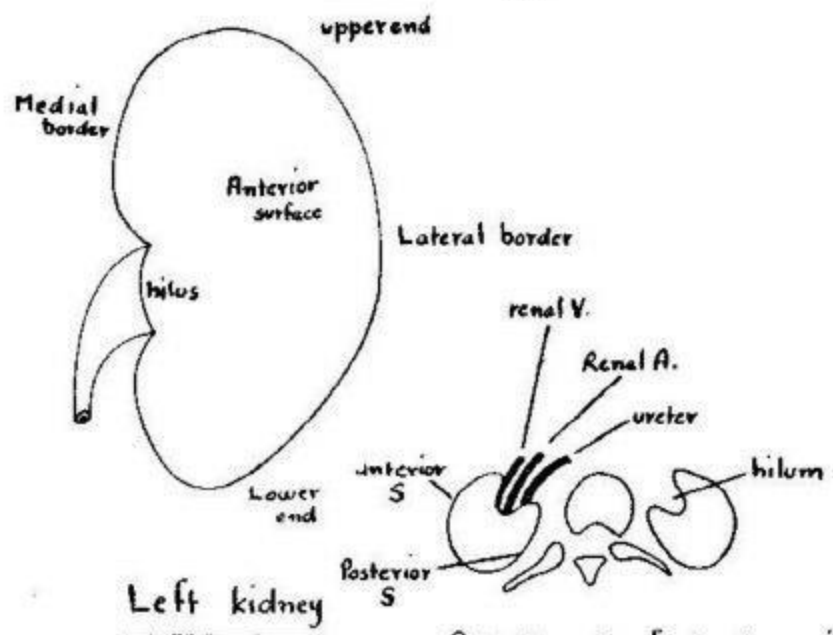




Arterial supply of suprarenal gland

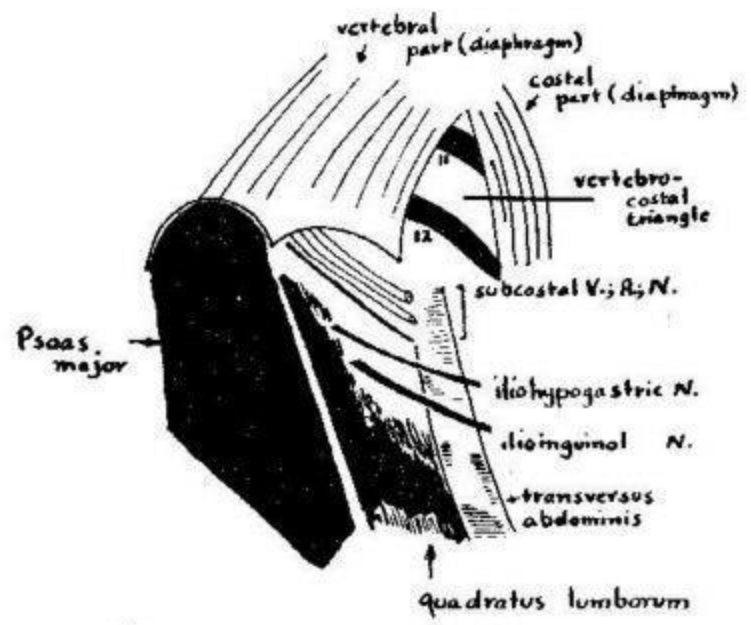


Position of both kidneys

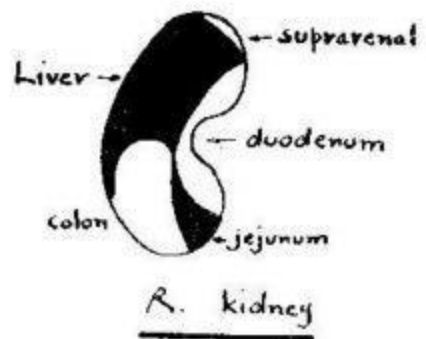
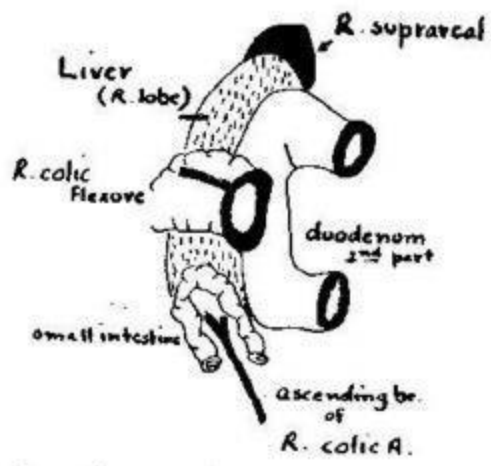


Left kidney

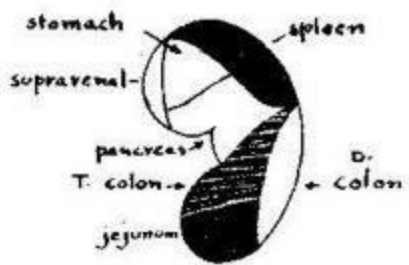
Arrangement of structures in hilum of kidney (T.S.)



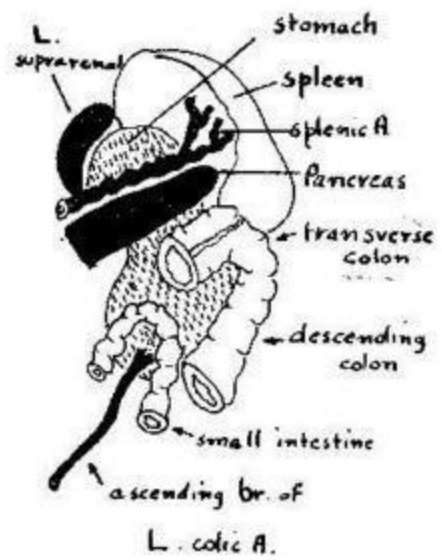
Posterior relations of Left kidney



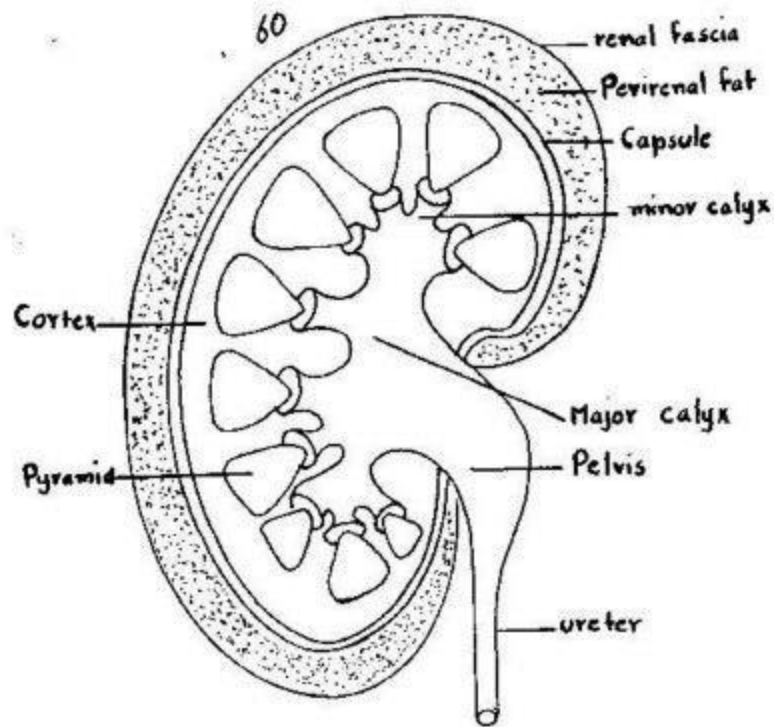
Anterior relations of R. kidney



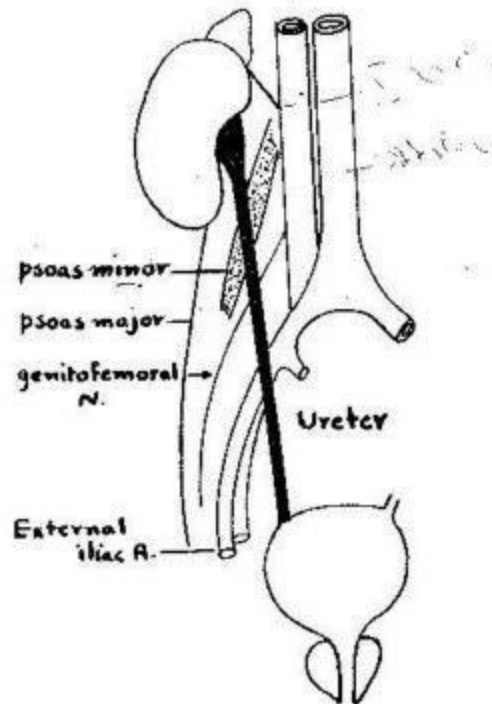
L. kidney



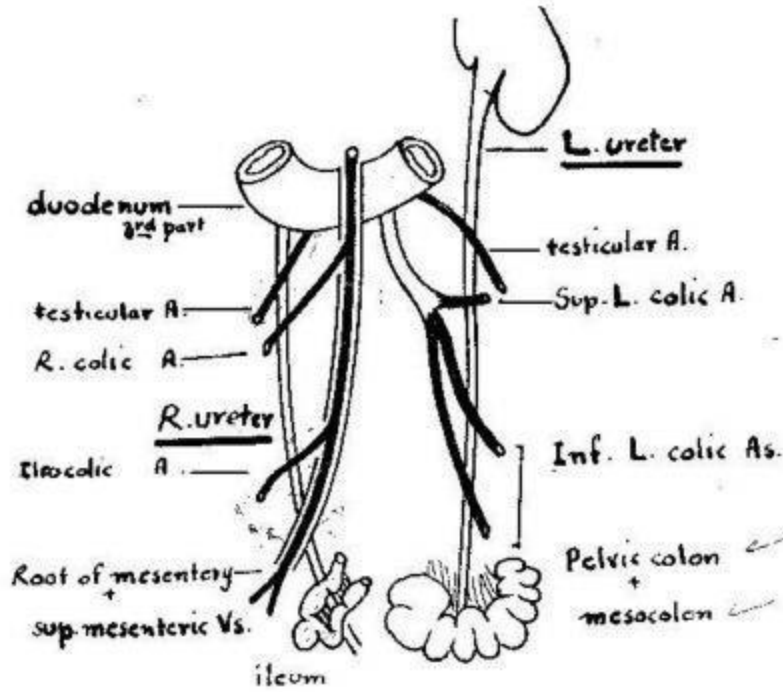
Anterior relations of L. kidney



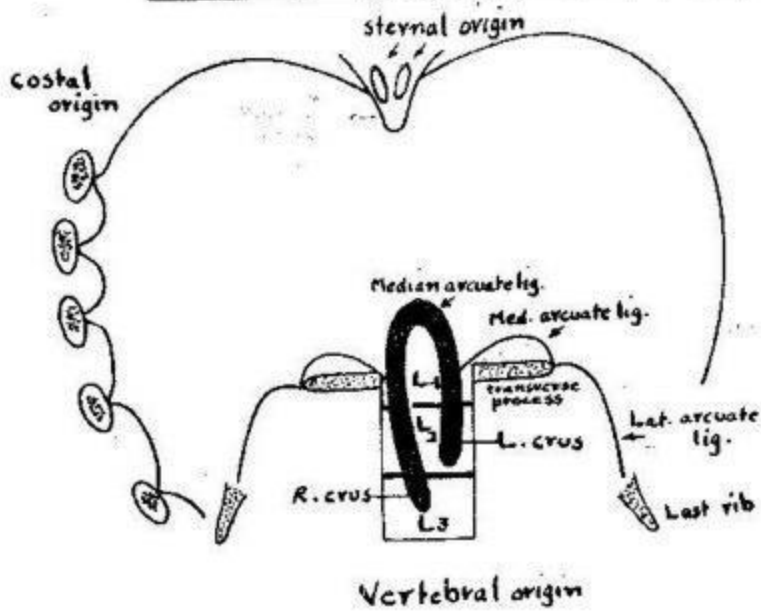
Longitudinal section in kidney



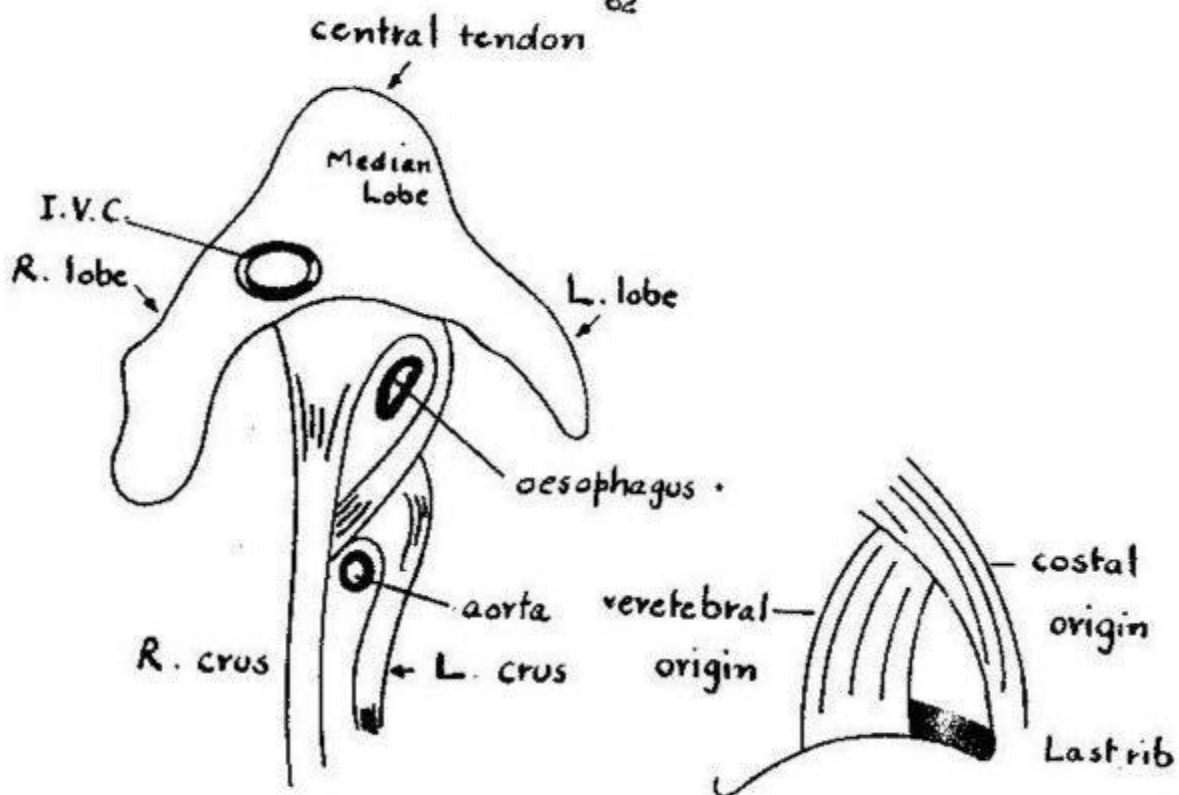
Posterior relations of ureter



Anterior relations of R. + L. ureters

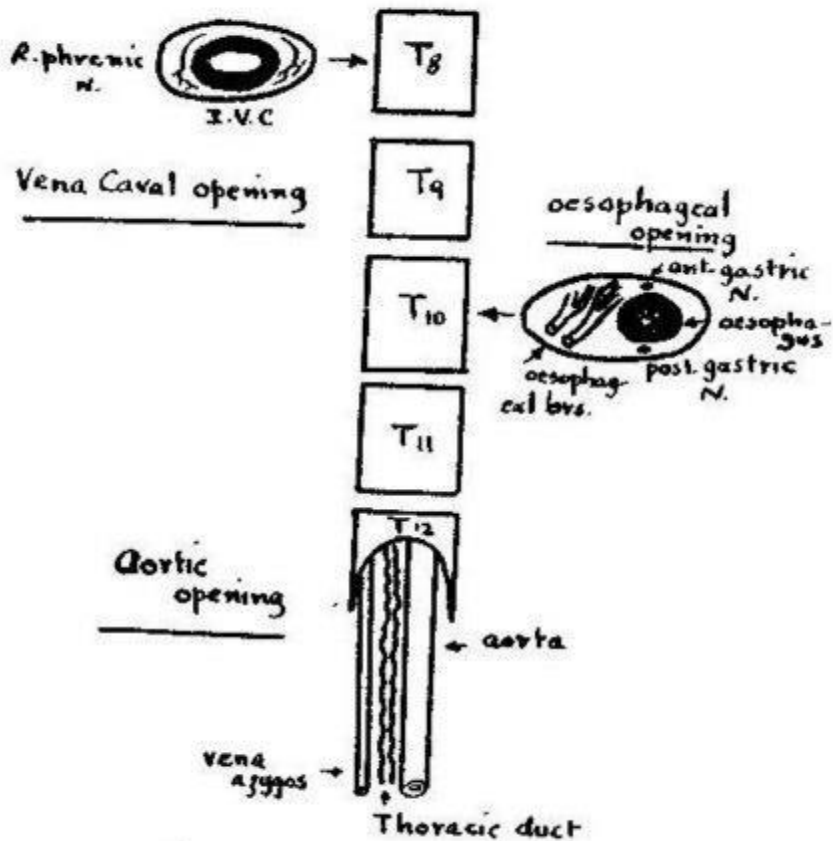


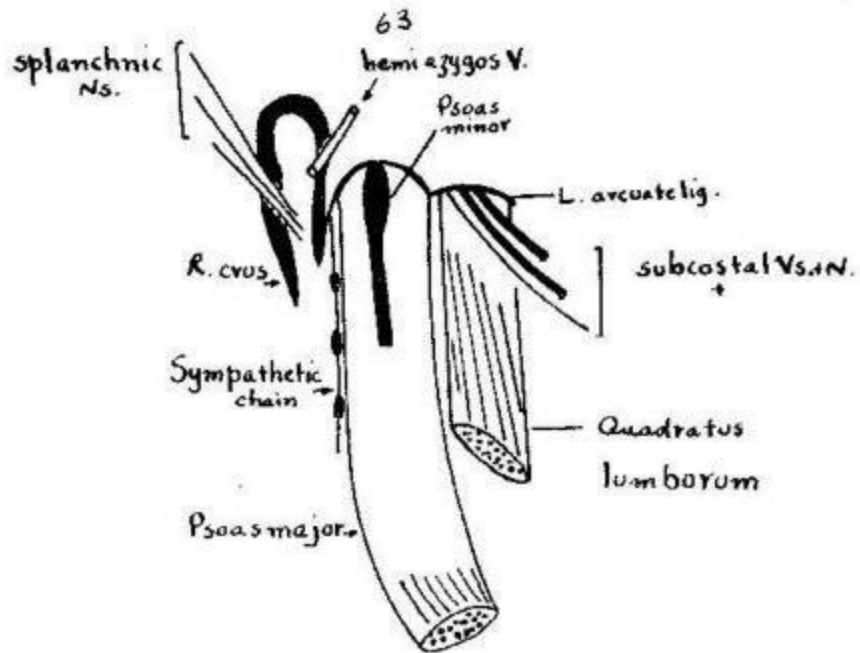
Origin of diaphragm



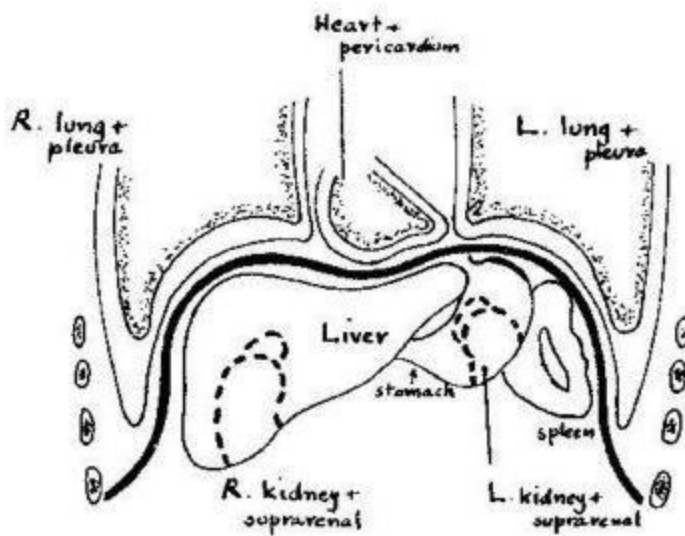
Insertion of diaphragm and its openings

L. vertebro-costal triangle

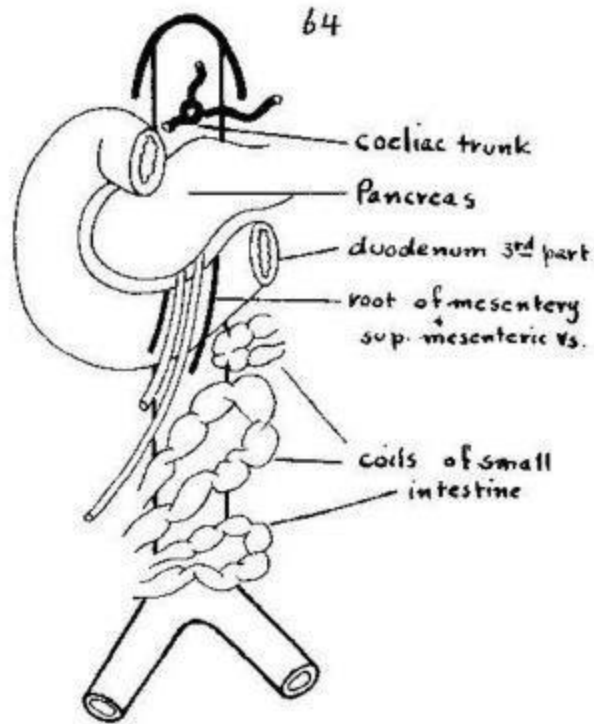




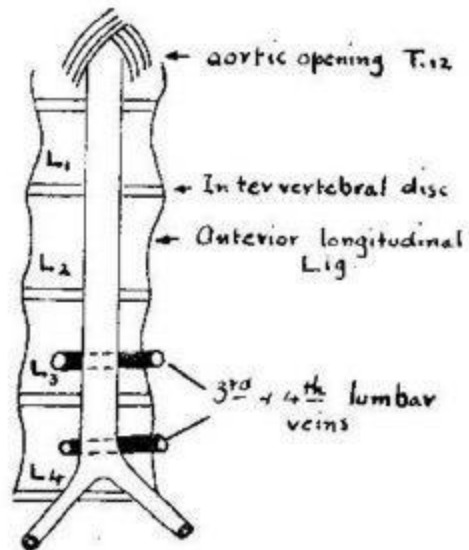
Structures passing through or behind diaphragm (Lt. side)



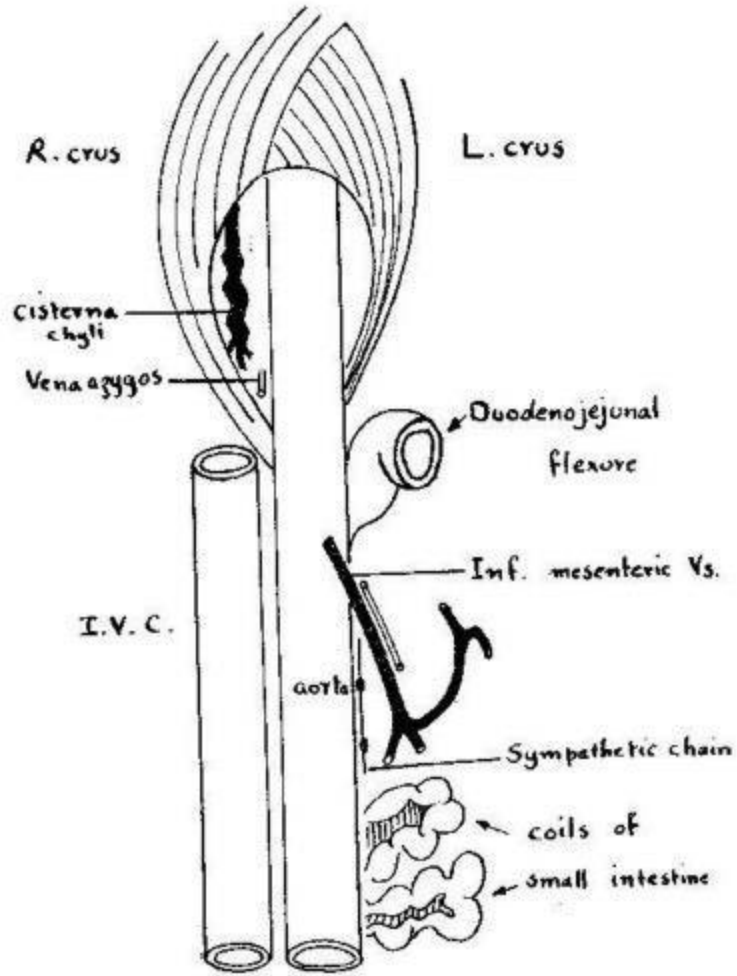
Relations of diaphragm



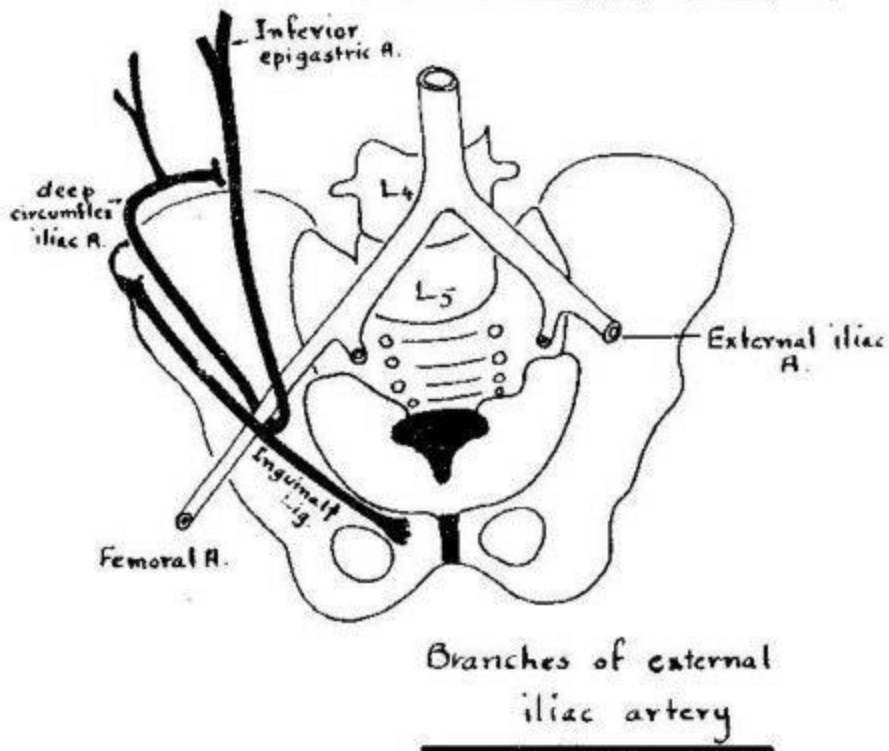
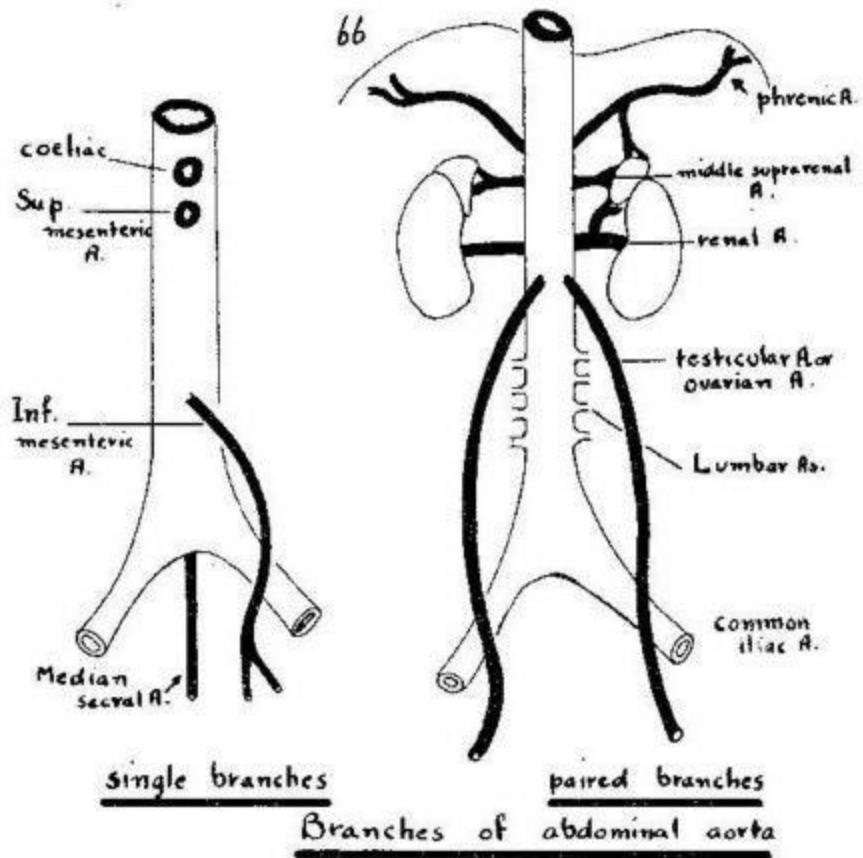
Anterior relations of
 abdominal aorta

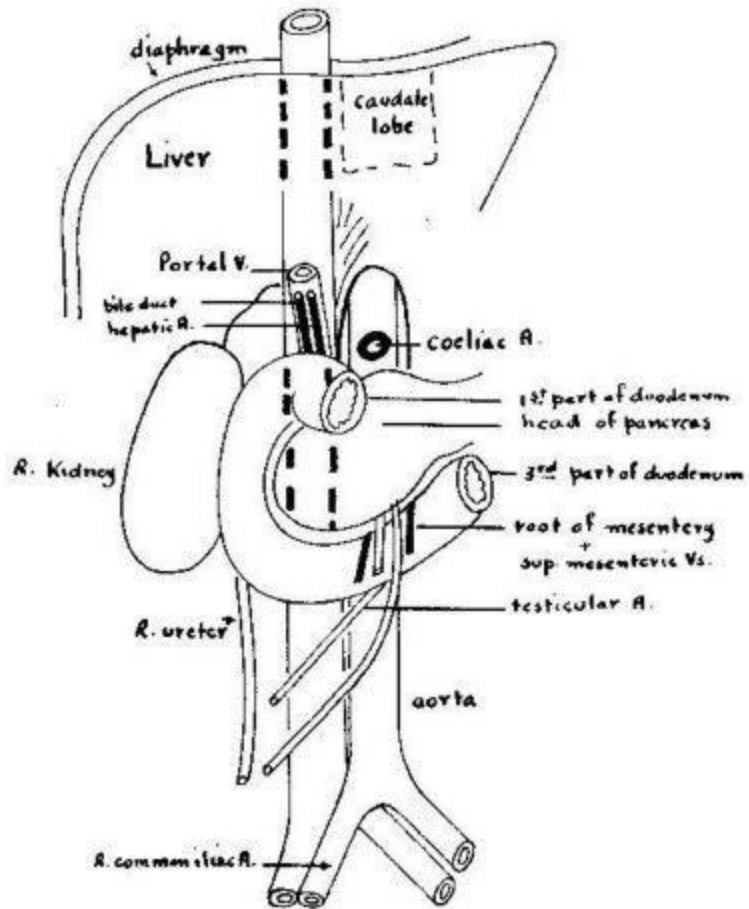


Posterior relations of
 abdominal aorta

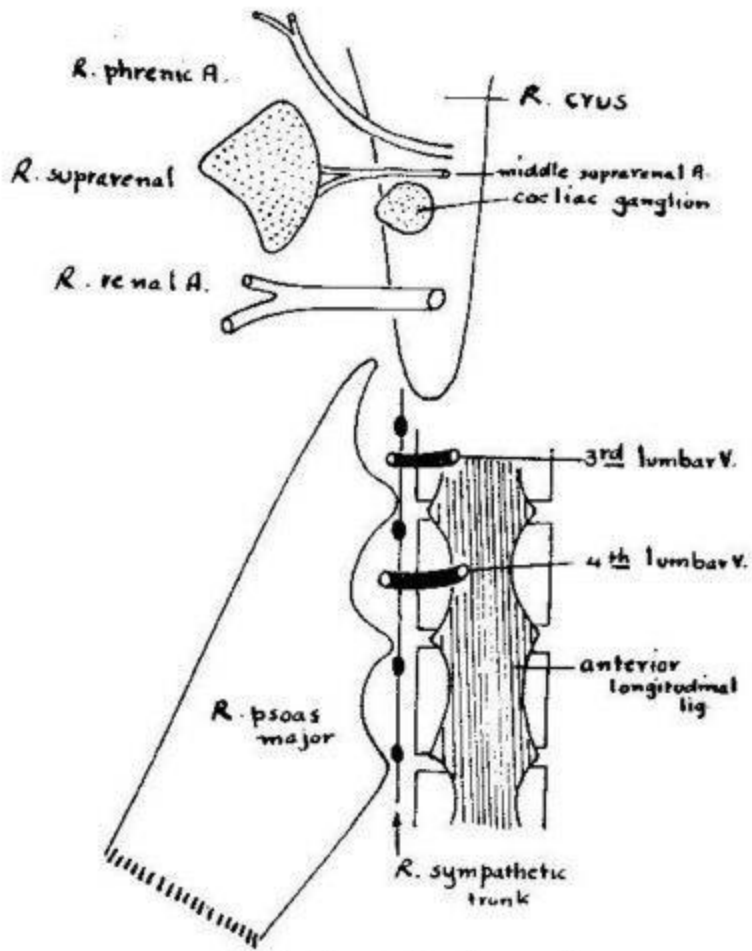


Abdominal aorta
Right and Left relations





Anterior, right and left relations of
Inferior vena cava



Posterior relations of
Inferior Vena Cava

69

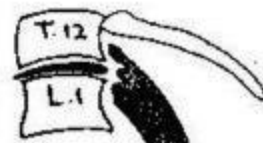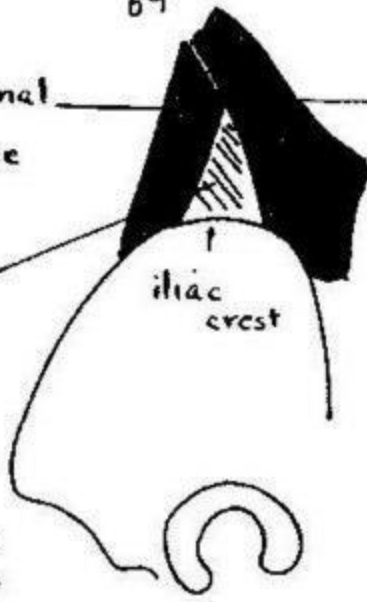
External oblique

Latissimus dorsi

Internal oblique

iliac crest

Lumbar triangle

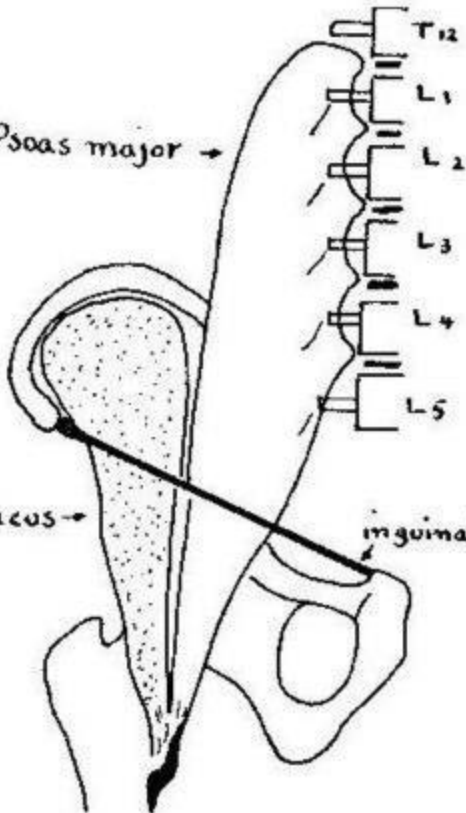


Psoas minor

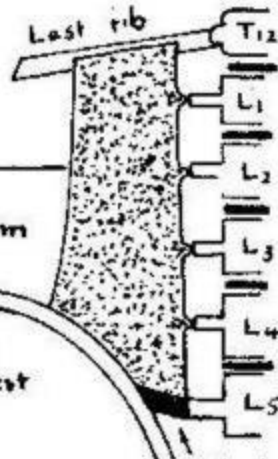
Psoas major →

Iliacus →

inguinal ligament

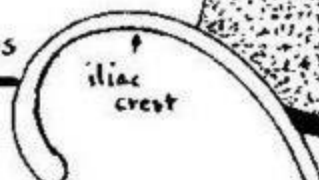

Psoas minor



Quadratus lumborum

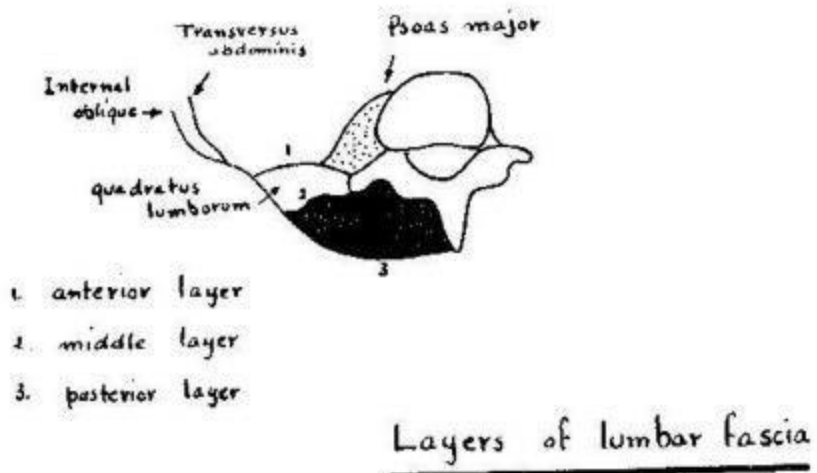
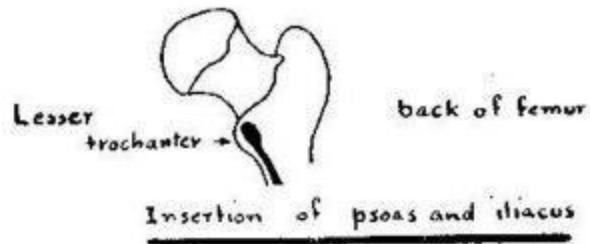
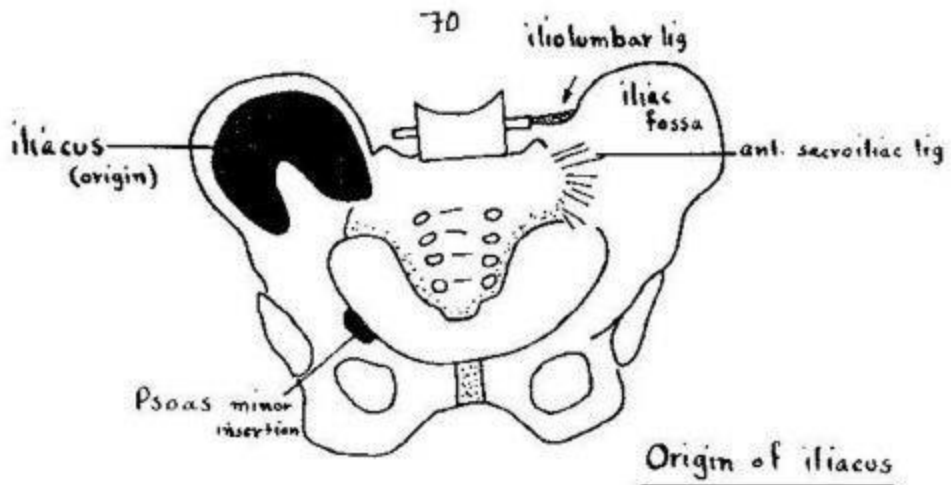
Origin of psoas and iliacus

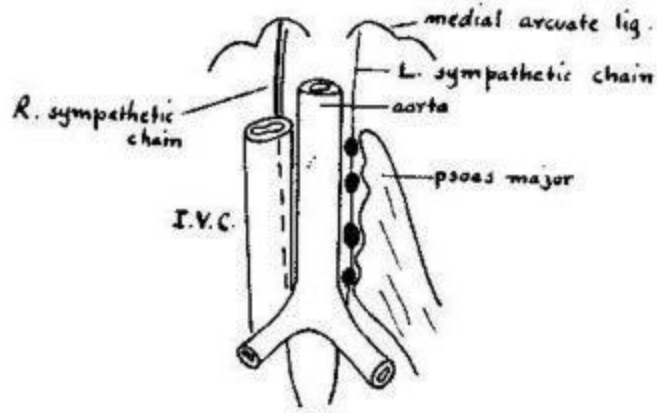


iliac crest

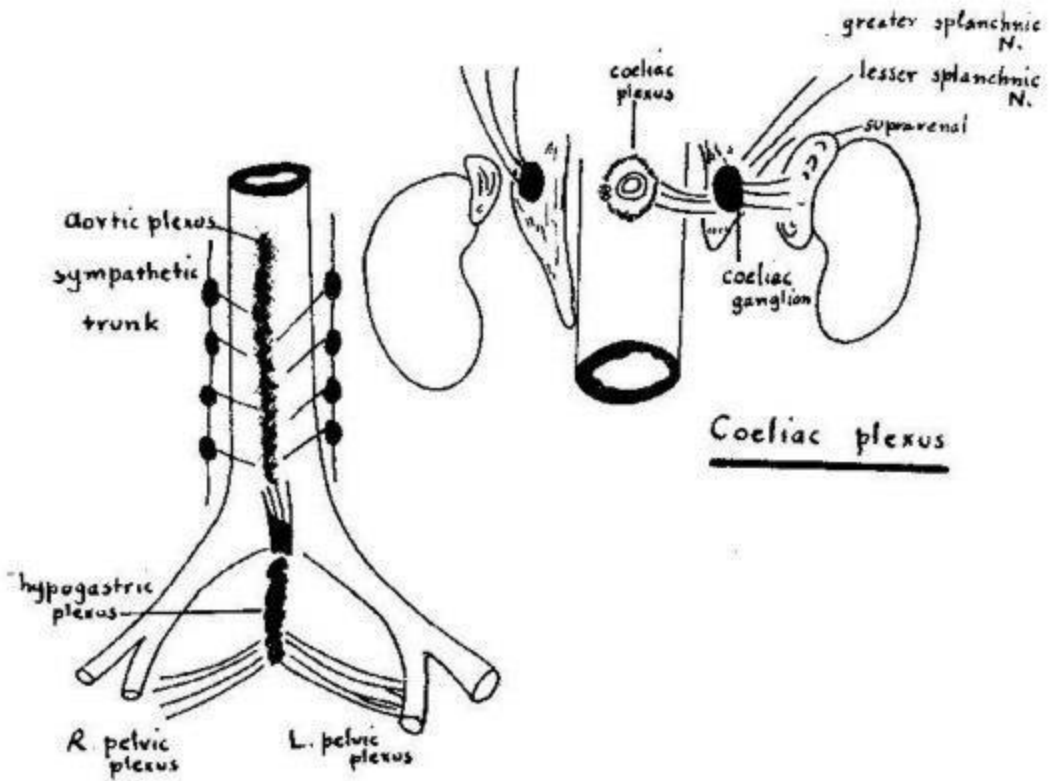
ilio-lumbar lig.

Quadratus lumborum



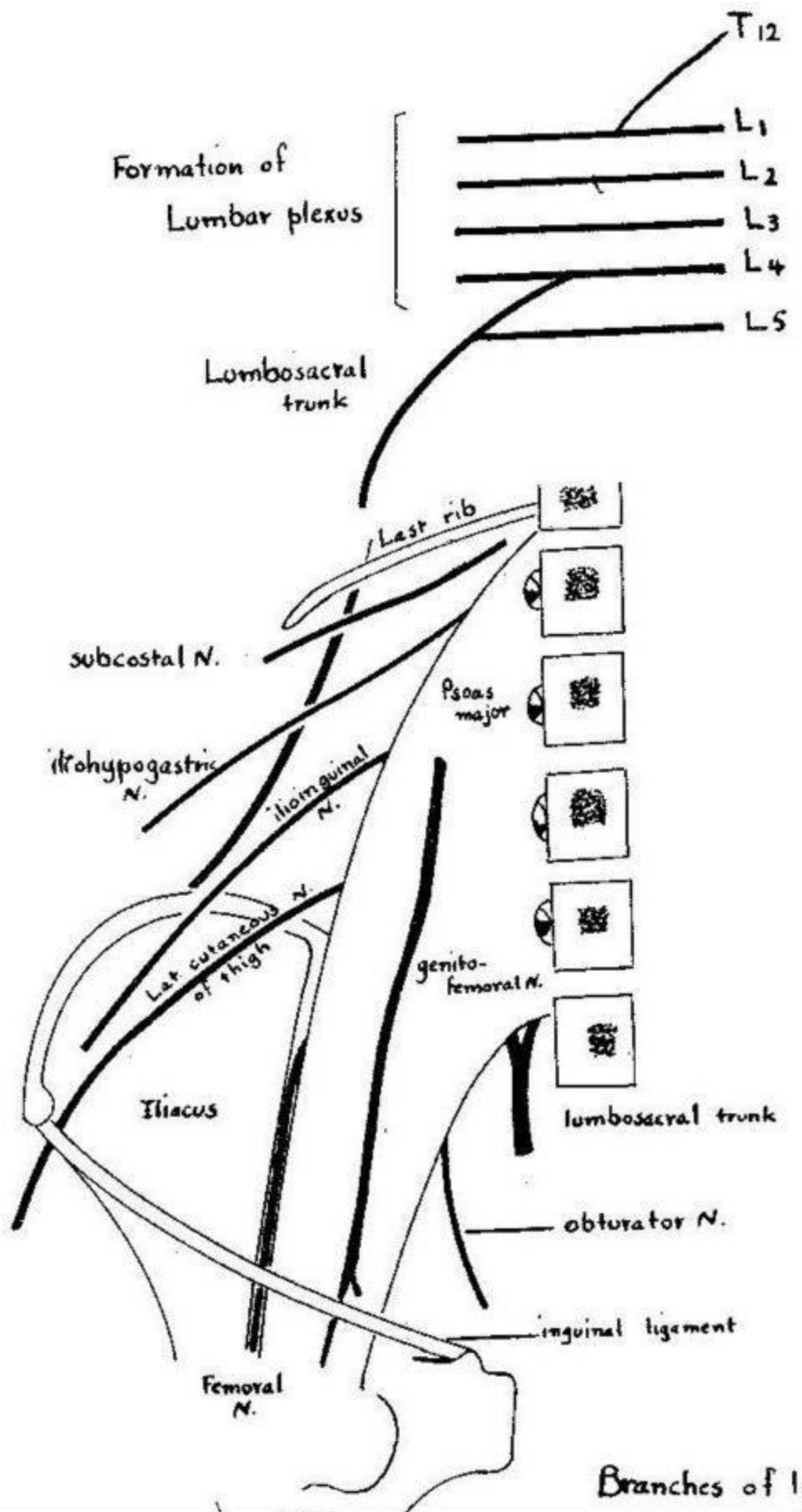


Lumbar sympathetic chain



Coeliac plexus

Aortic plexus



Branches of lumbar

