Anatomy – lecture #11

Nerves and arteries of the forearm and the hand

In the last lecture , we have learned that the forearm is divided into anterior compartment and posterior compartment by the deep fascia .
- the anterior compartment ---> flexor pronator compartment , which supplied by the median nerve and the ulnar nerve .

In this lecture we will learn about the nerves and the arteries of the forearm and the hand .

Nerves :

1) **Median nerve** :

- origin : medial cord and lateral cord of brachial plexus (medial root and lateral root)
- it doesn't supply any muscle in the upper arm .

- it will enter the forearm within the cubital fossa , then passing anteriorly to the medial epicondyle of the humerus .

- it pierces the pronator teres (and supplies it) , then being sandwiched between two muscles ; flexor digitorum superficialis " FDS " and flexor digitorum profundus " FDP " .

- before reaching the wrist , it becomes below and lateral to palmaris longus , and before passing below the bridge (flexor retinaculum) it gives a superficial branch to the palm called **palmar branch of median nerve** .

* Branches of median nerve :

A) **Anterior interosseous nerve** :

- given by the median nerve within the cubital fossa .
- is named like this because it passes anterior to the interosseous membrane (between radius and ulna)
- after passing anterior to the interosseous membrane , it continues and disappears below the pronator quadratus .

B) **Palmar branch** :

- passing above the flexor retinaculum .
- supplies the skin of the hand .
- the palmar branch supplies the lateral two third (2/3) of the anterior aspect
of the hand

★ The median nerve supplies :
- the whole muscles of the anterior compartment of the forearm except on and a half muscle supplied by ulnar nerve .
- skin of hand
-elbow joint and wrist joint according to hilton's law .

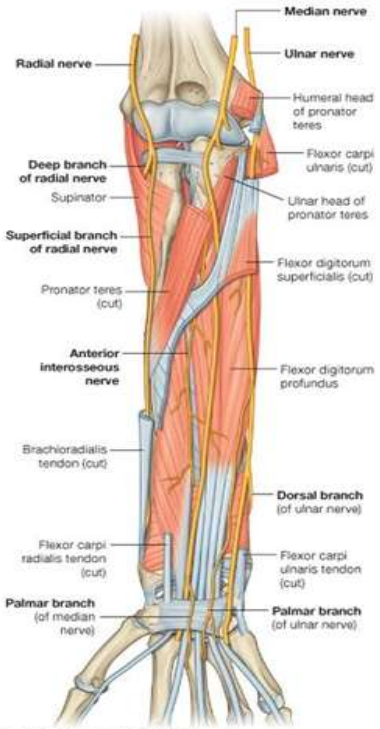

Nerves of anterior forearm.

note : the medial third of the hand consists of the little finger and the medial half if the ring finger and this part is supplied by the ulnar nerve .

- if we want to diagnose the medina nerve , we have to check any part of the lateral two third of the anterior aspect of the hand (using a needle) .

** there is a difference of the median nerve is cut in the cubital fossa or at the wrist
-if it is cut at the wrist , all muscles of the forearm are spared (not involved) but the skin of the lateral 2/3 will be involved .

2) **Ulnar nerve** :

-origin : medial cord of brachial plexus .
-doesn't supply any muscle in the upper arm .

- it passes behind the medial epicondyle of humerus , so it doesn't enter the cubital fossa , then it enters between the two heads of the flexor carpi ulnaris (passing flexor carpi ulnaris) so it supplies it .

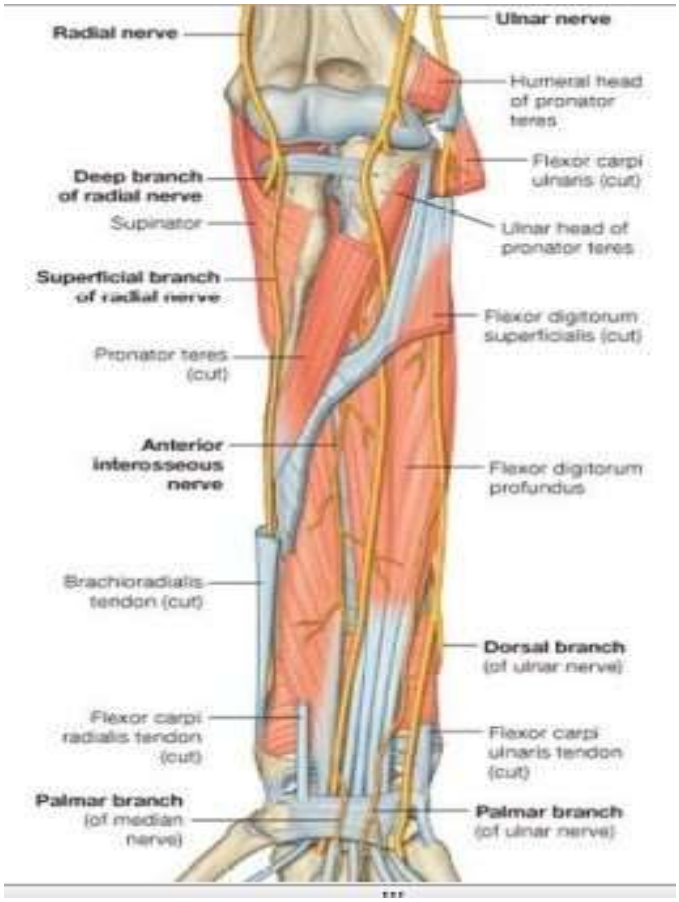

- after passing the flexor carpi ulnaris , it divides at the middle of the forearm into two branches :

a) **Dorsal branch** to the skin of the hand (medial one third 1/3 of the hand)

b) **Palmar branch** to the skin of the palm (medial one third 1/3) of the palm) .

- when ulnar nerve reaches the wrist , it passes above the flexor retinaculum , lateral to the pisiform bone and then continues down to the hand .

until now , the flexor retinaculum has two structures passing above it :
1.ulnar nerve
2.ulnar nerve's branch (palmar branch of ulnar nerve > for the skin) .

★ Ulnar nerve supplies
- the medial third 1/3 of the anterior and the posterior aspects if the hand.
- skin of hand
- elbow joint and wrist joint according to hilton's law .
- one and a half muscle of the anterior compartment of the forearm (FC Ulnaris & Ulnar Side of FD Profundus)

3) **Radial nerve** :

- origin : the largest branch of posterior cord of the brachial plexus
- passing within a groove called radial groove then passed between the two heads of the triceps muscle (medial and lateral heads)

- enters the cubital fossa anteriorly to the lateral epicondyle of the humerus then it passes between the brachioradialis and the brachialis .
- when it enters the cubital fossa , it divides into two branches :
a) Superficial branch { to the <u>skin</u> of the hand }

b) Deep branch { to all <u>muscles</u> of the posterior compartment ; supinator and all extensor muscles of the forearm }

Superficial branch of radial nerve (superficial radial nerve) :
- starts at the cubital fossa .
- passes deep to the brachioradialis then it changes it's position by passing below the tendon of the brachoradialis to reach the posterior compartment

in order to supply the skin of the lateral two third 2/3 of posterior part of the hand .

- passed posterior to the wrist .

Deep branch of radial nerve (deep radial nerve) :

- starts at the cubital fossa .
- passing through supinator muscle and supplies it .

- after piercing the supinator , it winds around the neck of the radius then continues to the wrist to supply it by many branches .

** the part of the nerve within the supinator is called deep branch of radial nerve but after passing and ends the supinator it continues as posterior interosseous nerve (named because it passes posterior to the interosseous membrane)

- this nerve supply all muscles in the posterior compartment .

- accompanied by an artery called posterior interosseous artery .

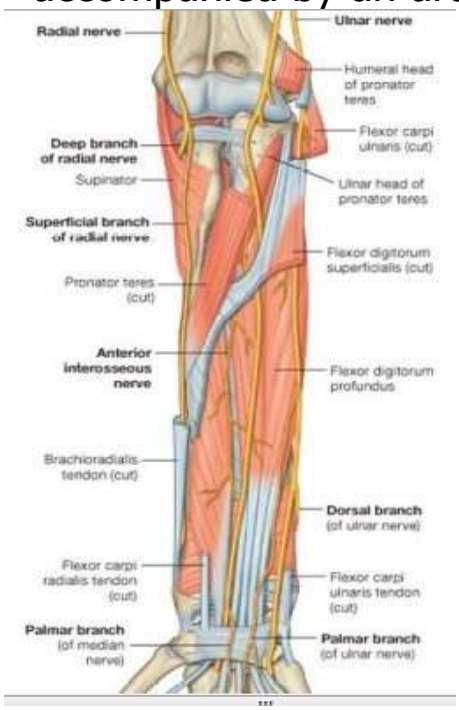

* median nerve gives arise to anterior interosseous nerve .
* radial nerve gives arise to posterior interosseous nerve .

* anterior interosseous nerve is accompanied by anterior
interosseous artery .
* posterior interosseous nerve is accompanied by posterior interosseous artery .

If there is a fracture in the neck of the radius , the deep branch of radial nerve will be involved .

★ Deep radial nerve supply :
- all muscles in posterior compartment .
- wirst joint and elbow joint according to hilton's law .

Now we have finished the nerves , we will move to the arteries .

arteries :

*** ALL parts of the forearm and the hand is supplied by brachial artery and it's branches .

- brachial artery divides at the opposite neck of the radius into :

1) **Ulnar artery** >> medial branch .
2) **Radius artery** >> lateral branch .

Ulnar artery :

- started at the opposite neck of the radius within the cubital fossa .
- larger branch of the brachial artery .
- it is sandwiched between :
  a. flexor digitorum superficialis .
  b. flexor digitorum profundus .

- after leaving the cubital fossa it gives :
* <u>common interosseous artery</u> : as the name shows , this branch gives two branches :

1. anterior interosseous artery .
2. posterior interisseous artery .

-- The ulnar artery is deep in the upper part and superficial in the lower part of the forearm .

** the ulnar artery passes above the flexor retinaculum and

located lateral to the ulnar nerve .

- After passing above the flexor retinaculum , at the end of it , the ulnar artery divides into two branches :

A) Superficial branch (larger)
B) Deep branch (smaller)

Pisiform>> lateral to it >>flexor carpi unlnaris>> lateral to it >>ulnar nerve >> lateral to it >>ulnar artery

Radial artery :

- starts at the opposite neck of radius .
- smaller branch of brachial artery .

- passes within the cubital fossa .

-then passes below (deep) the brachioradialis .
- after that it passes between the two radialis ; extensor brachioradialis and flexor carpi radialis .

- it doesn't pass above the flexor retinaculum ; before reaching it , it gives :
A) a larger deep branch .
B) a smaller superficial branch .
{ both to supply the hand }

P.S : CHECK the pictures on the Dr's slides they are much better .

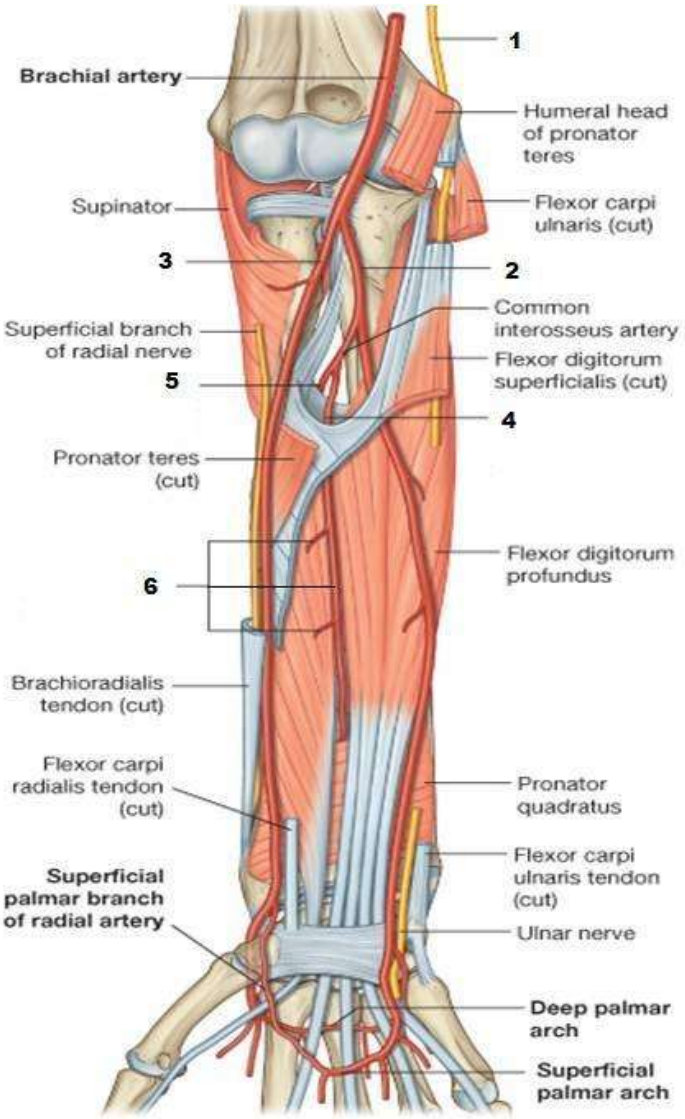

* the deep branch of the ulna and the radius unite together.
* and also the superficial branch of the ulna and radius unite together too.

- The branches of the radial artery and ulnar artery are connected together to from something we call <u>Arch</u> to supply the hand .

** There are two archs :

1) Superficial palmar arch.
2) Deep palmar arch.

{ They give branches that pass between metacarpal bones then to fingers. }

note : arteries , veins and nerves , move either medial or lateral and on both sides of fingers .

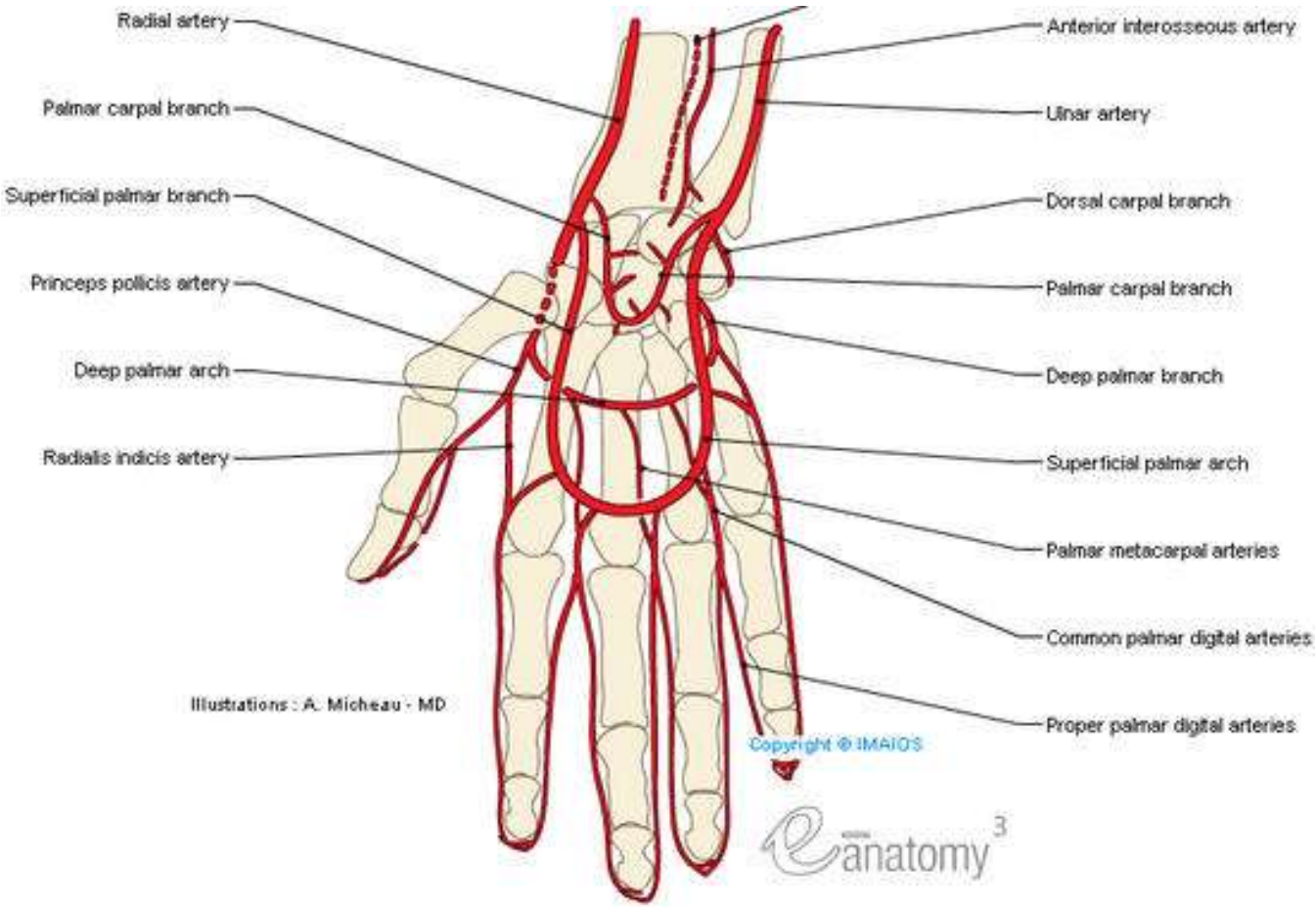

Superficial arch :
- contributed mainly by superficial branch of ULNAR artery and minimally by superficial branch of RADIAL artery.

- located at the level of the **distal** border of fully extended thumb.

Deep arch :
- contributed mainly by deep branch of RADIAL artery and minimally by deep branch of ULNAR artery.
- located at the level of proximal border of full extended thumb.

* the distance between the location of the deep arch and the superficial arch is the thumb width.

P.S : check all pictures in the slides .

and finally >> thank you all , love you all ❤

Good luck