ANATOMY

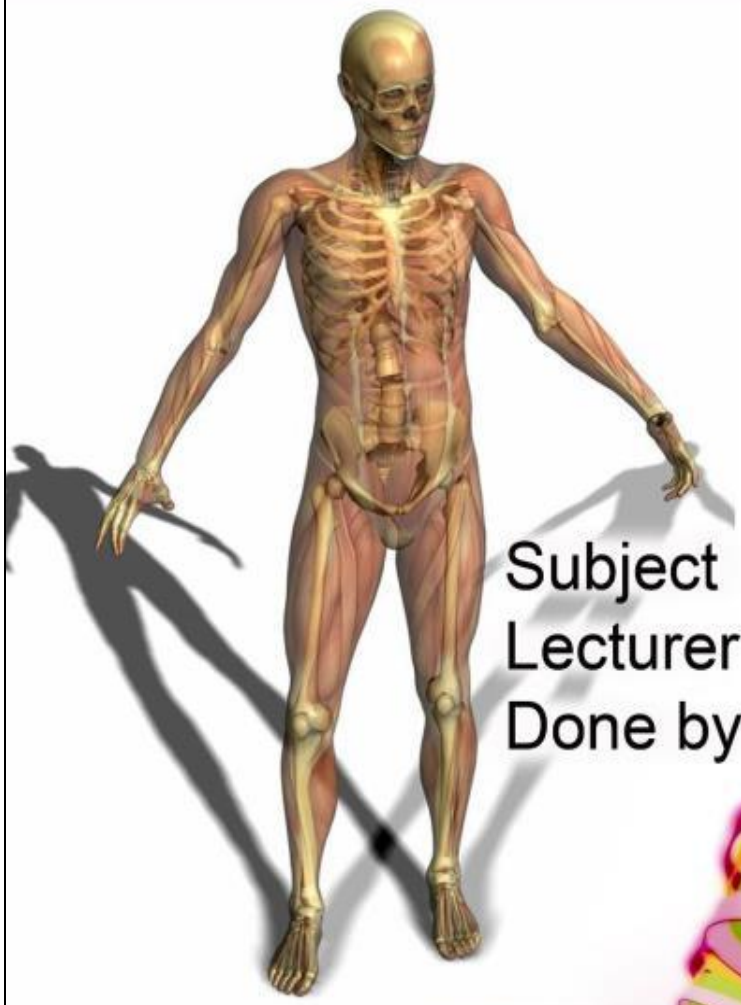

Sheet

Subject : *Introduction to Anatomy*

Lecturer : *Dr. Maher Hadidi*

Done by : *Ahmad Salameh*

lecture # : 25 Date : Mar/31th/2013

Faculty of medicine Thorax lecture # 2

Jordan University

Review: -

Last time we talked about the lungs, we said that lungs are located in a "pleural sac" and covered by visceral pleura, and the thoracic cavity is lined by parietal pleura, in between the is the pleural cavity with potential space. i.e. "no air no pressure".

…….....

Each lung should receive one branch from the trachea in order to be able for breathing. The function of the lungs is oxygenation of blood, so lungs need oxygen which comes from the outside through the trachea into its two branches.

Lungs receive deoxygenated blood from the right side of the heart (Right ventricle) then they oxygenate it by gas exchange which occurs in alveolar sac.

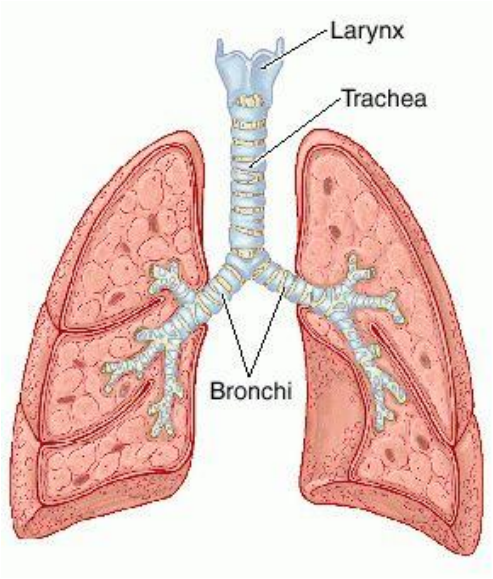

Trachea

Trachea is a tube about 12 centimeter in length; it is extending from larynx to the level of the sternal angle where it divides into right primary branch, and left primary branch.

Trachea passes within two regions; cervical part (neck) and thoracic part.

As mentioned; trachea at certain point is divided into two branches, right branch and left branch. Each branch has it's own characteristics : The left branch is horizontal, narrower and longer than the right branch. In contrast; the right branch is vertical, wider and shorter than the left branch. That is why inhaled foreign bodies are usually found in the right lung.

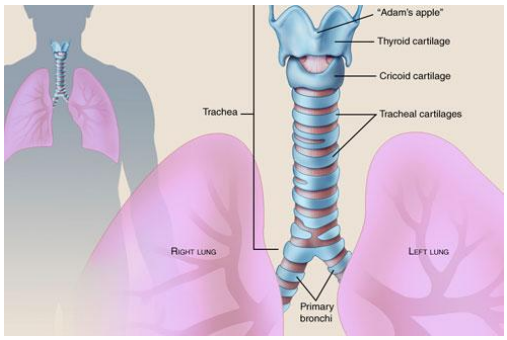

This is the anatomical difference between the two branches, and it can be clinically significant to let us know where possibly we can find the inhaled foreign bodies (because the right branch is within the alignment of the trachea)

The lungs

- conical shaped spongy organ (or pyramidal in shape)

-located on both sides of mediastinum

-attached to the mediastinum by the lung root (within it we have the bronchus)

*Between the two lungs we have the heart , heart has two sides 1 is the higher pressure side (arterial side P=120mmHg) and the other is the lower pressure side (venous side P=30 mmHg)

Each lung has an apex and base, the base of each lung is concave and rest on dome-shaped muscle of the diaphragm (when we make an inhale ,, the base compresses on the diaphragm). The apex which is superiorly projects into the thoracic space under the clavicle.

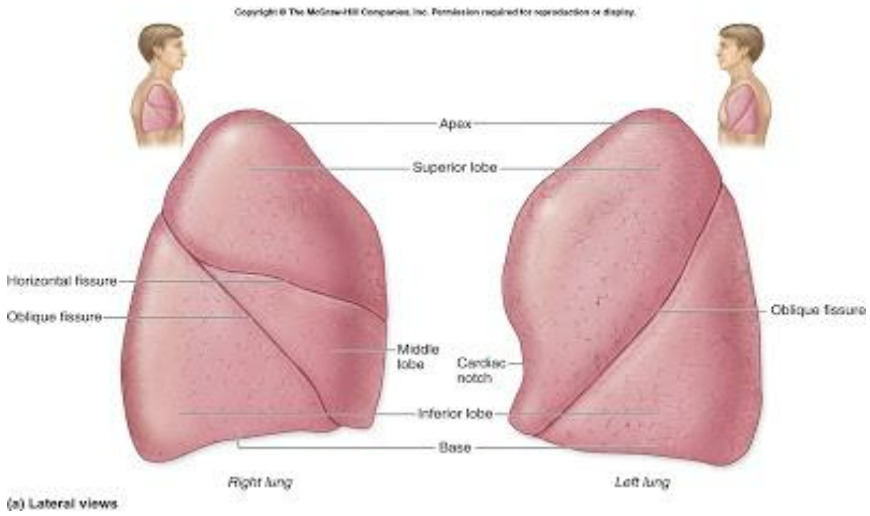

<u>Borders</u>: each lung has three borders and three surfaces, borders of the lung are:

1- Anterior border of the lung; which is thin, sharp and overlaps the front of the pericardium.

2- Posterior border of the lung; which is smooth, broad, rounded (on both sides of vertebral column)

3- Inferior border of the lung; which is thin, sharp and separates the base from the costal surface.

(parietal pleura has the following parts .. cervical pleura , costal pleura , diaphragmatic pleura and mediastinal pleura)

<u>Surfaces</u>: as previously mentioned, each lung has three borders and three surfaces, the surfaces are:

A- Diaphragmatic surface (inferior or base surface); which is the portion of the lung which border on the thoracic diaphragm. (concave because the dome of the diaphragm is convex)

B- Mediastinal surface; which is in contact with the Mediastinal pleura

C- Costal surface (external or thoracic surface); which is smooth, convex (because of the concavity of the ribs and madiastinum) and in contact with costal pleura.

Q:Is the right lung larger than the left?

Heart has two sides, right and left, in the left side run the arterious blood with 120 mmHg i.e. high pressure, while in the right side run the venous blood with 30 mmHg i.e. low pressure, as a result; heart is rotated 90 degrees to the left side, and two third of it is shifted to the left side and one third to the right. so the space where the left lung growing is small in comparison to the other side, so the answer is "YES" the right lung is larger.

Differences between the two lungs; although the two lungs are almost similar but they are not identical, the left lung is divided into two lobes upper and lower by one fissure, the oblique fissure which extend from the costal to the mediastinal surface of the lung. And as a result of the rotation of the heart to the left side, the **cardiac notch** is considered a feature for the left lung. The left lung in brief; has one fissure, two lobes, cardiac notch and it is longer, narrower, lighter and less functional than the right lung.

The right lung is divided to three lobes superior, middle and inferior by two fissures. One of these fissures is the oblique fissure, which separate the inferior lobe from the middle lobe and superior lobe . The other fissure is the horizontal fissure, which separate the superior from the middle lobe.

Right lung is situated in a quite larger space. The Right lung in brief; has two fissures and three lobes, and it is shorter, wider, heavier and more functional.

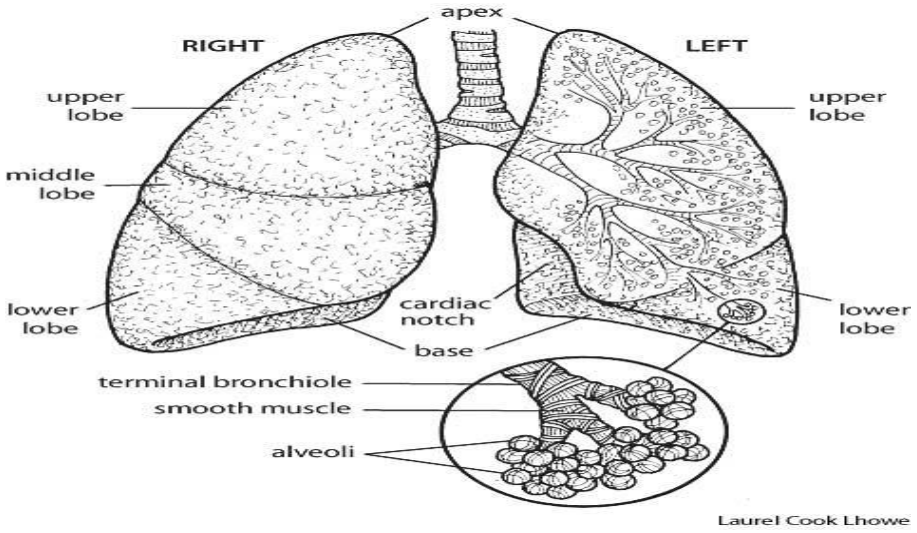

Functions of the lungs:

Lungs receive deoxygenated blood, i.e. RBC with more CO_2 and less O_2, from the right ventricle through the pulmonary artery, and this is an exception; because artery in general carries oxygenated blood while this artery "pulmonary artery" carries deoxygenated blood. And then the blood will be reoxygenated in the lungs. Now lungs send two veins -superior pulmonary vein and inferior pulmonary vein- carrying oxygenated blood -which is also an exception- to the left atrium.

The lung root

The lung root connect lungs to mediastinum, it is surrounded by pleura, and it contains; bronchus, pulmonary artery, two pulmonary veins, blood supply and innervations.

The innervations of lungs are of autonomic nervous system, sympathetic and parasympathetic. (no somatic nerves i.e no voluntary nerves)

*** The lung tissue is supplied by oxygenated blood through bronchial arches from the thoracic aorta. (arterial supply)

- Each cell in the body receives oxygenated blood only but only from the aorta (a branch from aorta)

Medical terms:

Tachycardia; it means a rapid resting heart rate

Tachypnea; is the condition of rapid breathing.

*When lungs receive polluted air .. lymph nodes work as filters to trap these foreign bodies so the lung (Crimson red originally) will have a black spots



"No matter how hard life is sometimes, you have to keep breathing... The sun will rise again tomorrow and who knows what the tide will bring..."