ANATOMY

Sheet

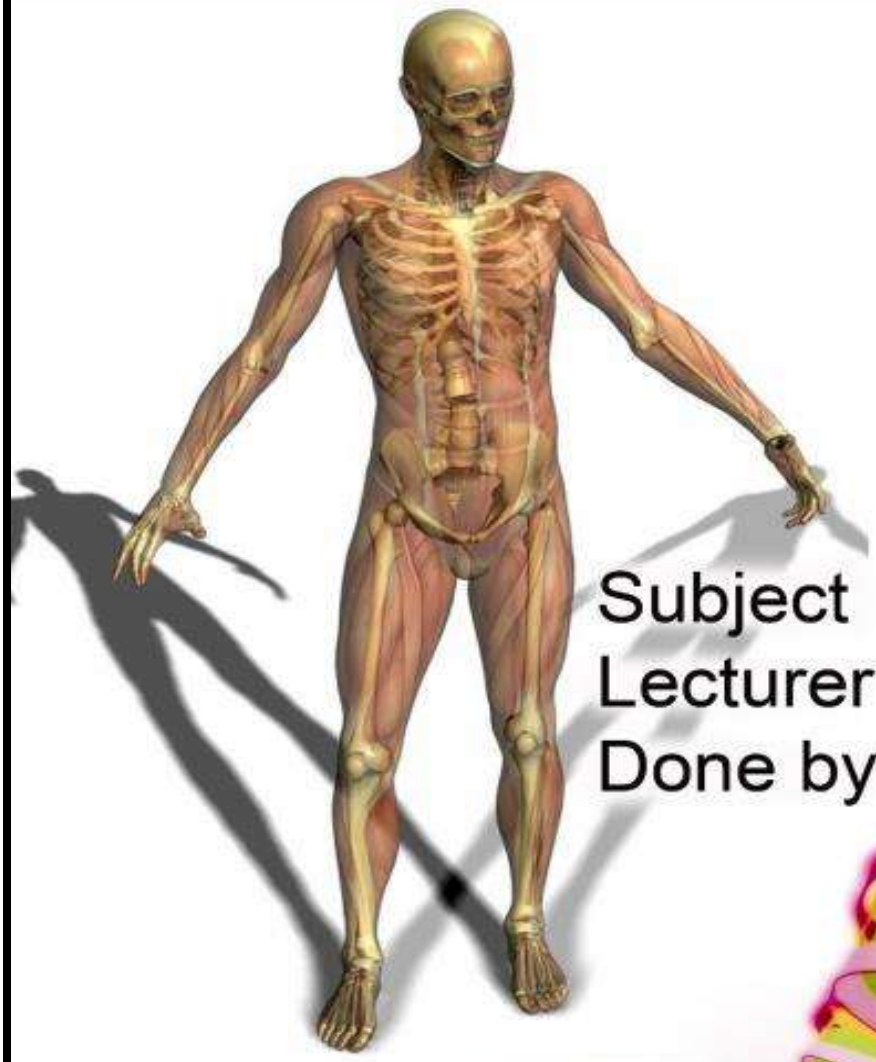

Subject : *Embryology*

Lecturer : *Dr. Maher Hadidi*

Done by : *Zain Al-Khamaiseh*

lecture # : 30 Date : April/16th/2013

Events during first week of pregnancy.

Lecture # 30:-

The Doctor began the lecture with the explanation of some information he was asked about:

First, out of 300 million sperms, only one which can penetrate zona pellucida and corona radiate of the ovum, this occurs after what we call it (capacitation).

**capacitation (conditioning): which is an interaction between the mucosal surface of the uterine tube of the lady and the head of the sperm, IF the sperm has a good or perfect motility beside enough amount of enzymes in the acrosome, the cell membrane of the head will unite with the cell membrane of the ovum forming two pronucleui inside ONE membrane.

Remember the series of cleavage:

Each of the male pronucleus from the head of the sperm and the female pronucleus contain 23 single chromosomes. NOW the nuclear membrane in the male and female pronucleui will unite to give a new cell which is called ZYGOTE (it contains 46 chromosomes).

This is the result of fertilization, by this time meioses ends and mitoses begins.

**formation of the zygote ends meioses.

-after the beginning of mitoses, as doctor said, each new cell is called **blastomere** (قسيم).

1- the zygote will give two identical cells, but each one is half the size of it's mother, also here it will give four cells and the four cells, each one is half in size of it's mother, SO at each time of mitoses the size of the cell will be smaller but larger in number..

At 16 cell stage:

The cells are too much, if they don't attach with each other, they will be spread every where, SO there will be a process which is called (COMPACTION).

by **compaction process, the cells will unite with each other forming a sphere (which is called morulla), NOW this sphere is from outside, but inside are spread (there are spaces in between).

At this time, the cells will connect well with each other to form one cavity and the cell inside will be pushed into one side (one pole).

** So the outer cells will be the outer cell mass, and the inner cell will be the inner cell mass and the cavity in between.

(Now in morulla –late or early- we have at the outer side well connected cells by compaction, and the spaces inside will unite as one space and push the inner cells into one side which will be called the inner cell mass)

NOW morulla has an outer cell mass, inner cell mass and a cavity, BUT there is a zona pellucida!!

At day four, it reaches the uterus but don't enter it (before reaching the uterus, it still at the end of fallopian tube and wants to enter the uterus)

But can it enter the uterus and implant it self WITH zona pellucid?!! The answer is **NO.**

At day five, it will enter within the cavity of uterus but before that it has to remove the zona pellucida then we call it **wandering blastocyst** (free blastocyst)

It becomes wondering,WHERE?

Within the cavity of the uterus…

At day five (after fertilization), the uterine endometrium is at the secretory phase so there is a large amount of mucus secretion.

Now, the blastocyst is wandering and the uterus is in the secretory phase, SO the uterine fluid will penetrate the outer cell mass (trophoplast)

*the inner cell mass---> embryoblast.

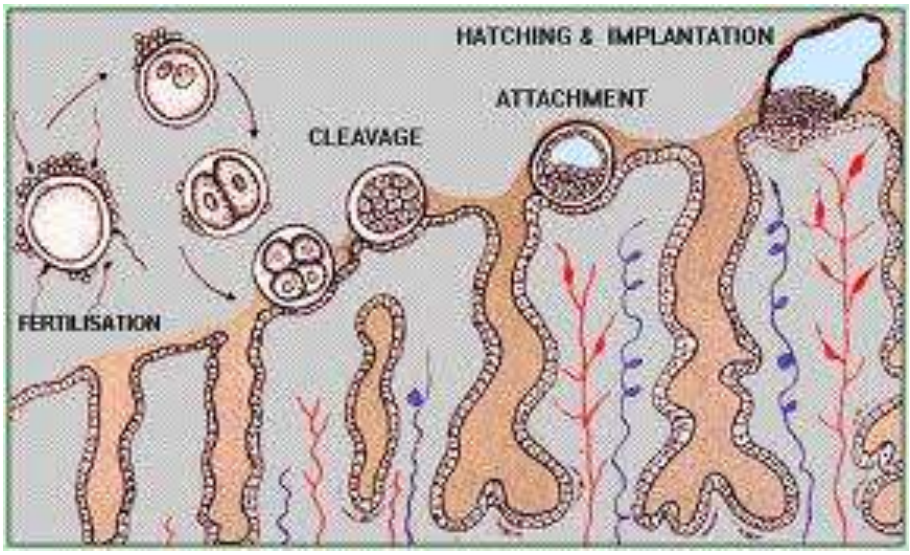

** after the late morulla with 32 cells reach the uterine cavity, and before it enters, the zona pellucid disappears, WHY: to prepare the blastocyst for implantation.

Now it is in stabilization state, but stability depend on the life style of the lady, if the lady is takes care of herself ,laying on her back---> the implantation will be in a good place (posterior wall of the uterus), but if the lady works hard and holds heavy things---> the implantation will be abnormal.

So at day five the blastocyst was wandering where it should implant itself.

** at day six (early implantation):

The blastocyst implant it self but we don't know if the implantation is normal or abnormal.

#1- the trophoblast cells (above the embryoblast) will penetrate endometrium and underlying tissue. it aims to reach the blood vessels of the mother.

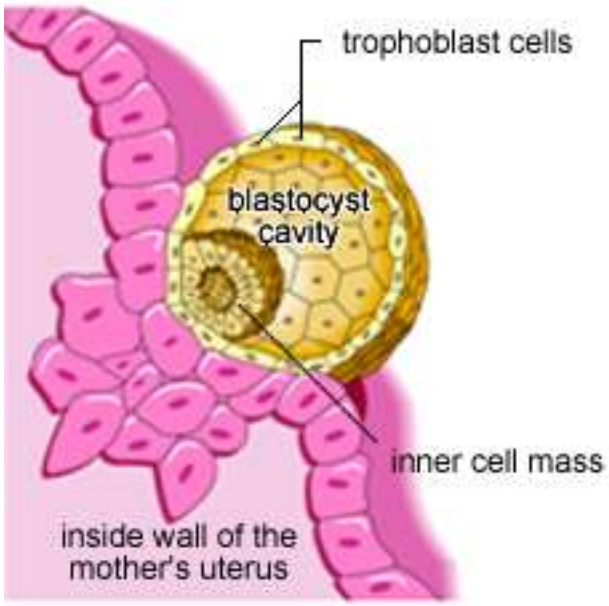

**But remember that the implantation started at the sixth day and completes at the day fourteen.

After implantation:

It is the end of the sixth day and the beginning of the seventh day(the first week ends) at this time the pregnancy starts!!

Then trophoblast cells enters to reach blood of the mother and they secrete a hormone which is called HCG hormone.
Human Chorionic Gonadotropin

H--> henry.. C--> country.. G--> good..

It was discovered by medical STUDENT!!

** now the penetrating cells which they are trophoblast cells (which penetrate the underlying endometrium) they secrete HCG hormone which can be detected in the urine of the lady.

** the seventh day (the 21th of the period of the lady): sometimes at this time the bleeding occurs BUT this is not a period, it is a show of pregnancy!!

**REMEMBER:

Ovulation occurs at day 14---> fertilization of ovum occurs---> wandering blastocyst appears in secretory phase---> corpus luteum begins secreting of progesterone BUT WHY?!! To maintain the uterus in it's secretory phase and good secretion of mucus (glands enlarge, good implantation site)

* If there is no pregnancy there is no progesterone and the corpus luteum becomes corpus albican.

BUT it must stay corpus lutium, SO the secretion of HCG will occur.

- what does the HCG do?!

The answer is : it maintains the corpus lutium of pregnancy and interrupt the period.

HCG: human chorinic gonadotropin) hormone---> chorion: placenta…. Gonad: ovary and testes…. Topic: stimulus.

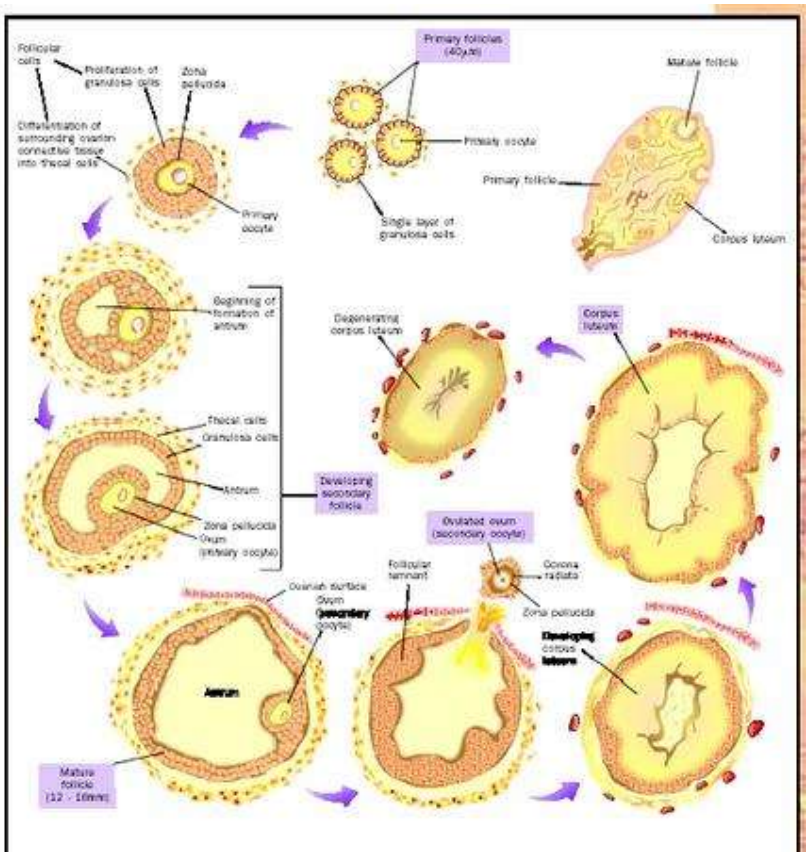

At the end of period the endometrium shed or go out as pieces BUT if pregnancy occurs, the endometrium will continue as one sac which is called **Decidua.**

* endometrium after pregnancy is known as Decidua (falling off) which falls with fetus at delivery.

SO the pregnancy test depends on HCG .

It is the end of the first week, we noticed that first week loves number one:

There are one inner cell mass, one outer cell mass and one cavity….

The beginning of the second week:

At day 22:

- embryoblast divides into two layers or differentiate:

Upper one---> **epiblast** (columnar cells---> ectoderm to be)

Lower one---> **hypoblast** (cuboidal cells---> endoderm to be---> mucus to be)

So embryoblast with two layers we call it **(bilaminar embryonic disc)** and there are spaces between these two layers will unite and form a cavity which called **AMNIOTIC cavity**…

SO the both layers form two layered thick plate (صفيحة) called bilaminar embryonic disc .

SO there are two cavities: amniotic cavity and blastocyst cavity.

Also trophoplast will divides into two layers :

*__cytotrophoblast__ (inner layer):mononucleated individual cells.

*__syncytiotrophoblast__ (outer layer): multinucleated protoplasmic mass lacking cells.

Trophoblast cells aim to reach the blood of the mother that why the red color appears.

*placenta: part of it from mother and the other part is from the baby…

Normal implantation : Posterior wall of the Uterus

** where will the abnormal implantation occurs??!

1-ovarian implantation

2-tubal implantation (Common one 95%)

3-at abdominal cavity

4-at ampulla (which is the common site for fertilization)

* abnormal sites of implantation mean ectopic…one of the worse abnormal implantation is tubal implantation… WHY?

Because when implanted it penetrate through mucosa and it is rupture the wall which means BLEEDING, so we must cut the tube and so it will not be able to be used sometimes !!Because cut and union will close the tube that be difficult to sperm to pass through…

Implantation at the internal OS is called Placenta Brevia , so the internal os is closed , when the delivery occur the cervix expand and the placenta falls off with the fetus,and this will cause uncontrollable bleeding which is life threatening on the baby and the mother, so the delivery will be cesarean.

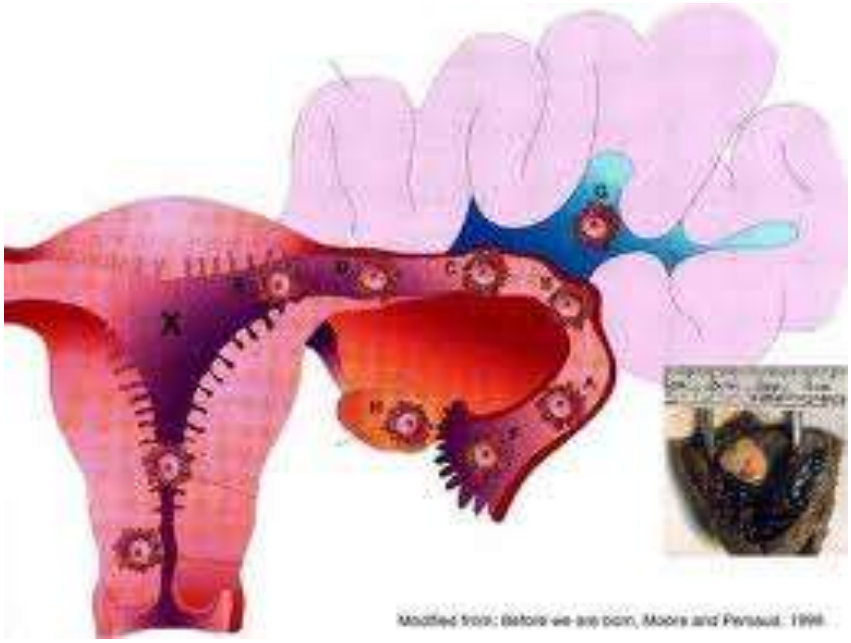

Please check the slides specially the last one…

GOOD LUCK ☺