ANATOMY

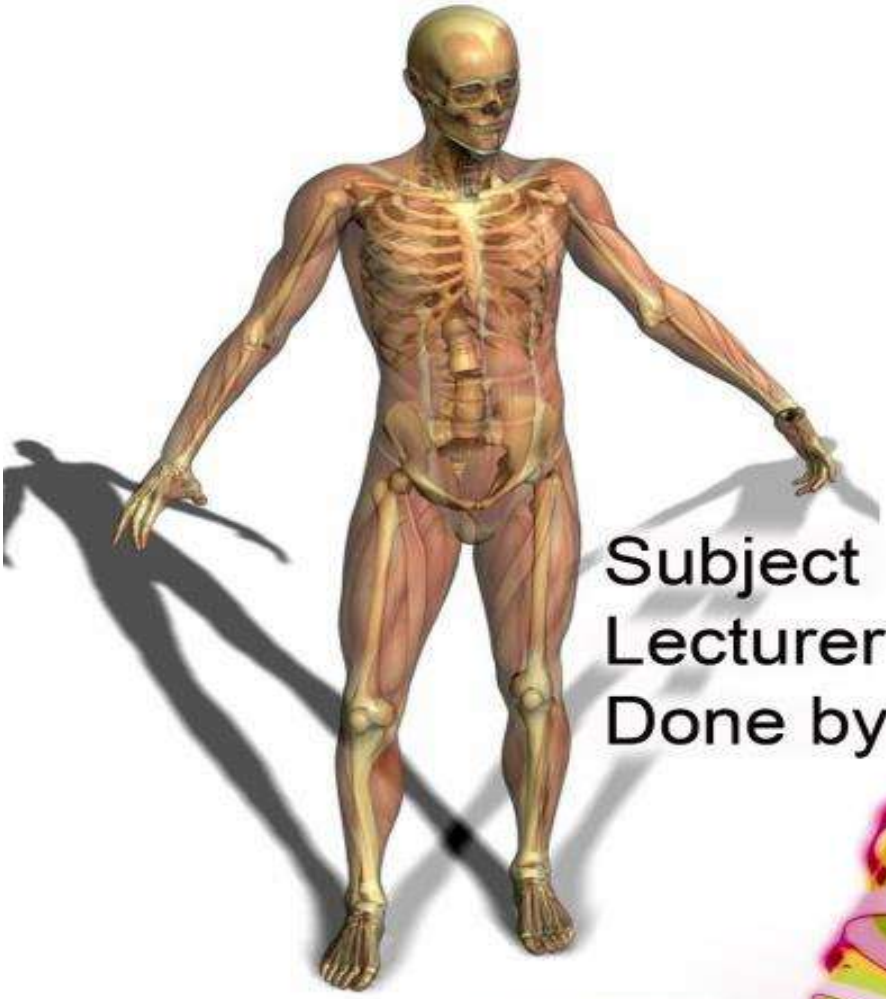

Sheet

Subject : *Introduction to Anatomy*

Lecturer : *Dr.Maher Hadidi*

Done by : *Asked us not to mention him*

lecture # : 36 Date : April. 30th 2013

Abdominal region

Liver:

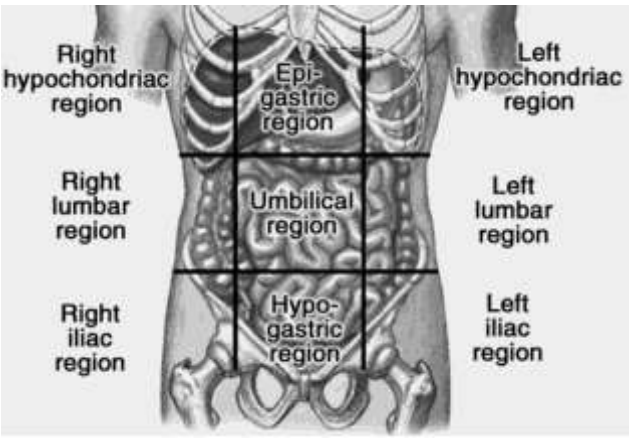

- Liver is the largest gland in the body; it's 1.5Kg in adults (represents 2%g of adults weight, and represents 10% of newborn babies body weight).
- Liver is located below diaphragm and breast, and it is located in the (1) right hypochondriac region, (2) epigarstric region, and it may extend to (3) left hypochondriac region.

Q: why does the liver in newborn babies represent 10% of total body weight?
Because liver in newborn babies is the site of blood formation.

- Liver has the general shape of a *wedge.
  It's triangular in anterior view; it has a superior border, right border and inferior border.
  Liver has 5 surfaces (Superior, inferior, anterior, posterior, and right surfaces).

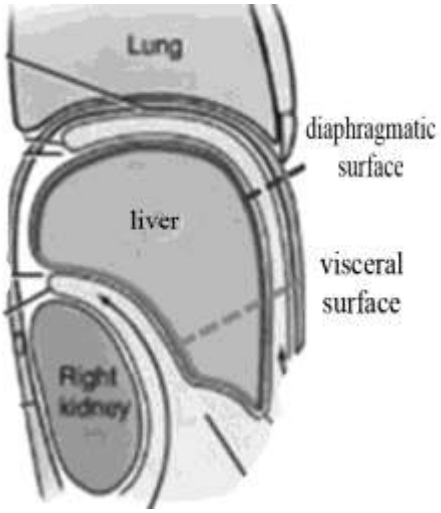

- The inferior border of liver divides it into two main surfaces (Diaphragmatic and Visceral)>

  Diaphragmatic: (Large, convex and Parietal)
  Visceral: (Concave, related to visceral organs)

---

*Wedge: اسفين

- Anatomical lobes:
  Falciform ligament, which is a double layer of peritoneum, divides the liver into two lobes:
  1. Right-larger
  2. Left-smaller

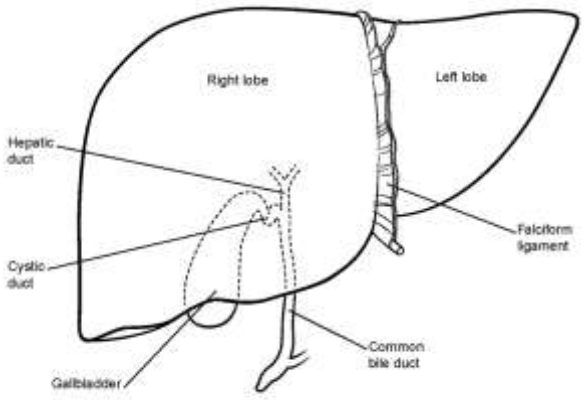

- ✓ When looking from the side of visceral surface we can find:

  <u>Hilum of liver (**Porta Hepatis**)</u>
  Which contains:
  Artery -in-
  Vein -in-
  Bile -out-
  Nerve -in-
  lymph -out-

- Physiological lobes:
  According to the arterial supply, venous drainage and bile secretion; the liver is physiologically divided into:
  1. Right lobe
  2. Left lobe and it includes:
     - Caudate lobe (above Porta hepatis).
     - Quadrate lobe (Below Porta hepatis).

- Bile from left lobe, caudate lobe and quadrate lobe drains into the left branch of the hepatic duct, and bile from right lobe drains into the right branch.

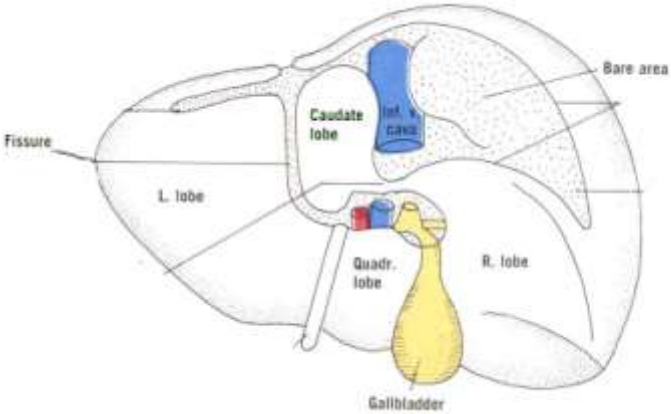

- Visceral surface of liver has a letter "H" shape.
  - Right limb:
    represented by 2 fossa:
    ~lower one – gall bladder
    ~above one – IVC
  - Left limb:2 fissures
  - Cross bar : Porta hepatis

  So, the Right lobe is located at the right side of the right limb, left lobe is located at the left side of the left limb, caudate lobe is located above porta hepatis and quadrate lobe is located below porta hepatis.

Then you can give the borders of these lobes:

- Caudate lobe
  Superiorly – superior surface
  Inferiorly – porta hepatis
  Right – IVC
  Left – Fissure
- Quadrate lobe
  Superiorly - porta hepatis
  Inferiorly – inferior surface
  Right – Gall bladder
  Left – Fissure

Porta Hepatis: (Hilum of liver)

- **Locates between caudate and quadrate lobe.**
- **Surrounded by peritoneum.**
- **It contents**:
  Hepatic Artery ------ Branch from celiac artery
  Portal Vein ------bring blood for filtration
  Bile Ducts ----- Convey bile
  Lymph nodes -----transfer lymph

- **Liver is an intraperitoneal organ except :**
  1. Bare area (sheltered by diaphragm and direct contact with diaphragm)
  2. Behind Gall Bladder
  3. Porta hepatis

- **Any infection in liver can be transmitted to nearby organs such as diaphragm and posterior media stinum.**

- **Types of liver's blood:**
  1. **Oxygenated: by Hepatic A. 30% to supply the liver.**
  2. **Deoxygenated: by portal vein for filtration 70%.**

- **Liver act as a checkpoint between GI tract & Blood.**
- **Major lymph in liver is drained by itself.**

Gall Bladder:

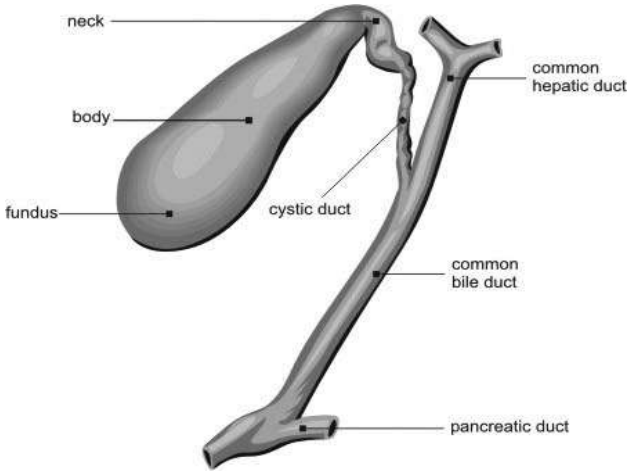

- **Located behind inferior border, Pear shape sac, and sheltered at visceral surface of right lobe.**
- **The capacity of gall bladder is about *30 ml.**
- **Gall Bladder Function:**
  - **Storage of Bile**
  - **Concentrate the bile 10 times by absorption of fluids by the direct contact between the bladder and the right lobe of the liver.**
- **Parts:** 1. Fundus 2. Body 3.Neck 4.Cystic Duct
  - **Fundus:**
    is intraperitoneal, it goes beyond the inferior border of the liver, located below the tip of the right 9th costal cartilage.
    Note: If we have a patient with a pain below the tip of the right 9th rib most likely the fundus is infected and he has **Cholecystitis (**التهاب في المرارة**).**
  - **Ducts:**
    -Common hepatic duct: (القناة الكبدية العامة**)**
    about 4cm in length.
    Form by the union of right and left hepatic ducts.
    -Cystic duct: (القناة الصفراوية المرارية العامة**)**
    S-shaped, about 4 cm in length.
    -Common bile duct: (القناة المرارية)
    about 8 cm in length.
    Form by the union of Cystic duct and common hepatic duct.
    It opens at 2nd part of duodenum.
    ⇨ The terminal part of the common bile duct is the narrowest part of the ducts of the liver that's why it's the common site of stone impaction (الحشر).

    - Bile from Gall bladder (cystic duct) is **concentrated.**
    - Bile from common hepatic duct is **diluted**.
    - Bile from the common bile duct is **mixed**.

❖ The Bile is secreted according to a stimulus, which is hormone from the duodenum.
Note: If we did a Cholecystectomy for a patient, during the first 6 months after the surgery if he eats fatty meals, he will suffer from diarrhea because most of the fats won't be digested since the bile is diluted.

❖ When a person is diagnosed by gallstone he may look pale and a yellow color in his eyes. Because in this case the stone closed the terminal part, so the secretion of bile is blocked -> then it retain back to liver -> to the blood -> to the skin and the sclera (the white of eye).

---

*In books they give ranges so it's about 30-50 ml.
Cholecystectomy: استئصال المرارة

Good Luck ☺