The Esophagus

The esophagus is a continuation of the pharynx, it starts at the *lower border of the cricoids cartilage* or C6 cervical vertebra, and it ends at the *cardia* of the stomach (cardiac orifice).

The length of the esophagus is about *25 cm or 10 inches*, but we said that *from the incisor it is 45 cm*, because nowadays, doctors use the gastroscope (a device that we insert through the oral cavity into the oropharynx then the pharynx and the esophagus till we reach the stomach and the duodenum, so we can describe the mucosa and view it under the light microscope using this device (it acts as a light microscope)).

The esophagus is a muscular tube and it is *divided into 3 parts*; upper striated, middle mixed "smooth and striated", and lower smooth.

Functions of the Esophagus:

- **Propulsion of the bolus** (passage of the bolus by peristaltic movement).
  The esophageal muscles undergo peristaltic movement and the *vagus nerve* is responsible for it, so around the esophagus there is the esophageal plexus of nerves, these nerves are mostly parasympathetic and come from the vagus nerve, as well as some sympathetic fibers that come from superior cervical sympathetic ganglia.
  As we said before, the parasympathetic fibers to the glands are secretomotor and motor to the smooth muscles, causing peristaltic movement and the propulsion of the bolus downward as well. At the end of the esophagus we have the cardiac orifice (lower esophageal sphincter), this is only a physiological sphincter and not an anatomical one (no thickening in the smooth muscles there), and it is a physiological one because it prevents the regurgitation of stomach chyme. There is an angle between the cardia and the esophagus which also helps prevent regurgitation.

CLINICAL APPLICATION:

We have a common disease affecting this area called the **esophageal hernia** which is a dilatation or a bulge through the diaphragm from the fundus of the esophagus. This always causes *heart burn* which is hyperacidity in the chest, so the patient feels some acidity in his chest; this is caused by the *esophageal reflux* which means that some of the chyme ascends to the esophagus indicating that the sphincter is not functioning well. The reflux of the chyme causes irritation and hyperacidity resulting in **esophagitis** "inflammation of the esophagus" and this needs treatment or it will turn into an *ulcer* (an ulcer is an open sore on an external or internal surface of the body, caused by a break in the skin or mucous membrane which fails to heal).

Relations of The Esophagus:

Anterior:

- *Trachea*
- *Recurrent Laryngeal Nerve.*

  The recurrent laryngeal nerve lies within a groove between the esophagus and the trachea. There is something you need to know about it; at the left side, it starts in the thorax below the arch of aorta, while at the right side it starts at the root of the neck below the subclavian artery, so we can say that the left recurrent laryngeal nerve is anterior to the esophagus in the thorax but both the right and the left are anterior to it above the root of the neck.
- *Left Principal Bronchus* which crosses from right to left anterior to the esophagus.
- *Pericardium* which is surrounding the heart.

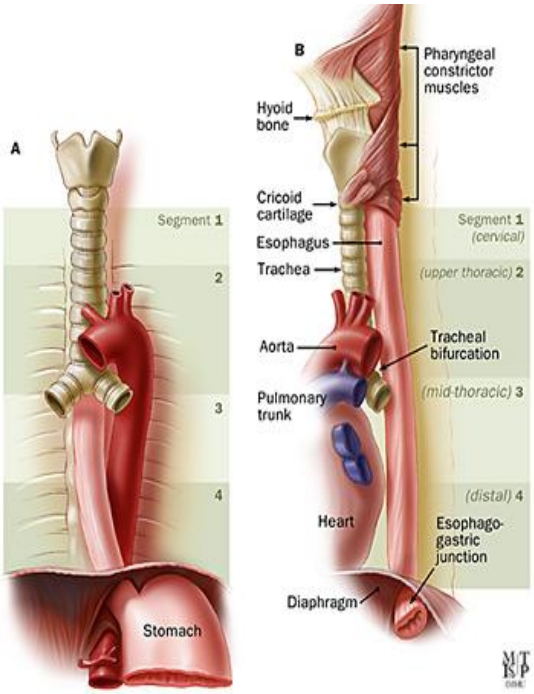

Posterior:

- *Bodies of Thoracic Vertebrae*
- *Thoracic Duct* which is the main lymphatic duct, it ascends upward, posterior to the esophagus and it ends at the beginning of the left brachiocephalic vein at the root of the neck.
- *Posterior Intercostals Arteries* which are branches from the descending thoracic aorta

At the Right Side:

- *Right Pleura and Lung*
- *Azygos Vein*

At the Left Side:

- *Left Pleura and Lung*
- *Subclavian Artery*
- *Aortic Arch*
- *Thoracic Duct* becomes on the left side (it was posterior)

Blood Supply of The Esophagus:

- **Upper third** of the esophagus: Inferior Thyroid Artery
- **Middle third** of the esophagus : present in the chest and takes its blood supply via *esophageal branches* from the Descending Thoracic Aorta
- **Lower third** of the esophagus: just above the diaphragm and takes its blood supply from the Left Gastric Artery which is *a branch from the Celiac Trunk*.

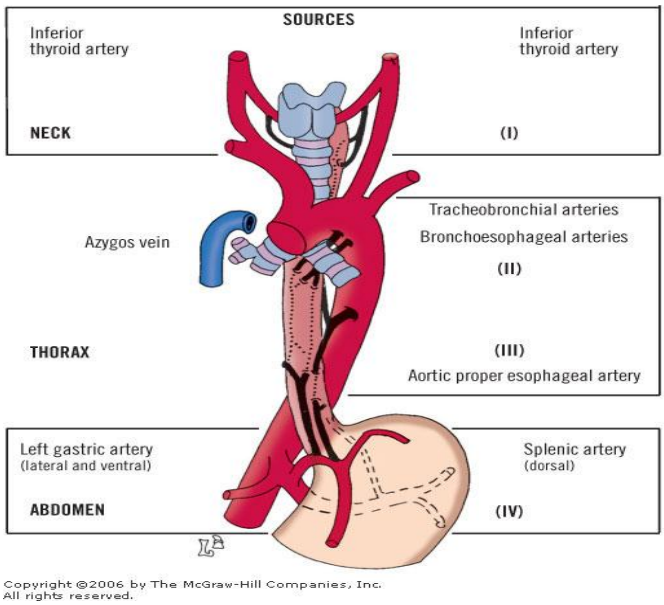

Venous Drainage of The Esophagus:

- **Upper third**: to the Inferior Thyroid Veins and then into the *Internal Jugular vein*.
- **Middle third**: to the Azygos Veins then into the *Azygos Arch* and then into the *Superior Vena Cava*.
- **Lower third**: to the Portal Vein.

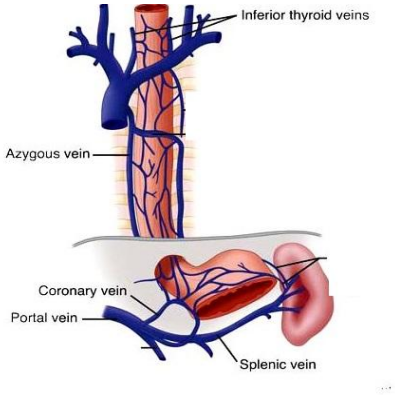

The lower part of the esophagus is supplied through the left gastric artery, its venous drainage is in the opposite direction and blood flows into the portal vein.

CLINICAL APPLICATION:

We have something called **Esophageal Varices**: which is dilatation and tortuousity of the veins around the lower third of the esophagus due to *portal hypertension* which results from Liver Cirrhosis. When there is cirrhosis, it means that there is obstruction ahead of the Portal Vein and the blood therefore regurgitates back towards the lower third of the esophagus causing dilatation and varices of the veins. Blood then could also flow back into the Azygos Veins and the Vena Cava, which is headed towards the heart. This may cause vomiting of blood.

Lymphatic Drainage of The Esophagus:

- **Upper Third** → *Deep Cervical* Lymph Nodes
- **Middle Third** → *Posterior Mediastinal* Lymph Nodes
- **Lower Third** → *Celiac* Lymph Nodes: large lymph nodes around the celiac trunk which lies at the level of the intervertebral disk between T12 and L1 (at the lower border of T12 and the upper border of L1).

Gastroesophageal Sphincter:

- It is a physiological sphincter and not an anatomical one since there is no thickening of the inner smooth muscle layer.
- **Contraction** of the sphincter prevents the regurgitation of the stomach chyme into the esophagus, and this contraction (closure) of the sphincter is under **Vagal (parasympathetic) Control**. This is unusual because normally the control over the contraction of sphincters in the GI tract is sympathetic (such as in the case of the pyloric sphincter). Sympathetic control normally causes vasoconstriction of the blood vessels and contraction of GI sphincters, except in the case of the Gastroesophageal Sphincter because it is only a physiological and not an anatomical one.

The Stomach

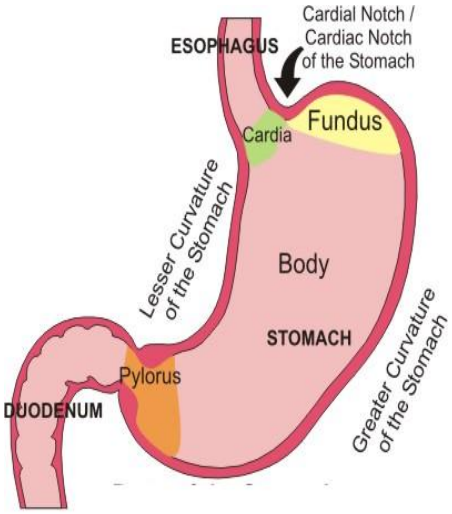

- The stomach is a dilated part of the alimentary canal
- The stomach has:

  Two Openings:
  1. Cardiac Orifice
  2. Pyloric Orifice

  Two Surfaces, each one has specific relations:
  1. Anterior
  2. Posterior – The stomach bed is related to it

  Two Curvatures:
  1. Lesser
  2. Greater
- The stomach lies in the *epigastric region*
- The Shape of The Stomach: Normally, it is roughly *J-shaped*. In obese people, the stomach is *Steer Horn-shaped* with a dilatation in its middle. The shape depends on the *volume* of its contents, the *body position* and the *phase of respiration*.

Histology of The Stomach:

- **Mucosa**: forms *rugae* (invaginations of submucosa through mucosa), which are *oblique and transverse*, except on the lesser curvature where they are *longitudinal* and highly folded rugae. This aids in the flow of fluids downwards, which flow directly through the lesser curvature and into the duodenum. (There are many rumors which say that you shouldn't drink fluids before or while eating food, but the truth is food and fluids rarely ever mix! Fluids reach the duodenum directly within less than a minute).
- **Submucosa**
- **Muscularis Externa**: 3 layers, the innermost one is oblique.

  The oblique layer is not present in all parts of the stomach, it is not present at the site of the pyloric sphincter and this is why the inner smooth muscle layer there is circular and is thickened.

  There is a plexus of nerves in between the inner and the outer longitudinal layers: The Myenteric Plexus.

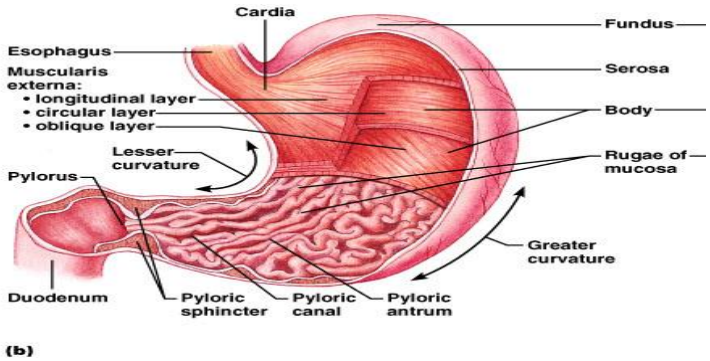

- **Serosa.**
- **Peritoneum** –around the stomach:

  The *lesser omentum* is attached to the *lesser curvature*. There is a large layer of fat surrounding it.

  The *greater omentum* is attached to the *greater curvature*. There is a large layer of fat surrounding it.

Functions of The Stomach:

- *The Storage of Food*; in the adult it has a capacity of about 1500 mL
- *Mixing of Food*
- *Forms Acidic Chyme* (a semi fluid) especially in the body of the stomach. The main function of the pylorus is to evacuate this chyme into the duodenum through the pyloric sphincter, which is contracted (closed) normally due to sympathetic control and opens (relaxes) due to parasympathetic control (which causes peristalsis). Food stays in the stomach for 2-4 hours after which the stomach is completely empty.
- It controls the rate of delivery of the chyme to the small intestine so that efficient digestion and absorption can take place.

CLINICAL APPLICATION:

Some diseases in children or babies lead to **spasm of the pyloric sphincter** resulting in *poor evacuation*. Their *stomach is dilated and distended*, and when they cry you feel as if their belly is bloated and full of air. This requires surgery → **Pyloroplasty**: dilatation of the sphincter, evacuation becomes easier.

Parts of The Stomach:

- **Cardiac Orifice:** histologically different from fundus, body, and pylorus.

There are no chief cells, very few (or none) parietal cells. No lymphatic Nodules; only scattered lymphocytes seen.

- **Fundus:**

It is Dome-shaped. It projects upward and to the left of the cardiac orifice, and it is always filled with air since some of the air goes down with eating or swallowing despite the constant contraction of the cricothyroid muscle of the pharynx which works to prevent the passage of air. A small amount of air still passes and gathers in the fundus. If this area was checked by a plain x-ray it will appear as a dark spot on the fundus.

- **Body:**

Extends from the level of the cardiac orifice to the level of the Incisura Angularis, which is an anatomical depression present on the lesser curvature. If we extend a line from it to the deepest point of the greater curvature it would mark the anatomical separation of the body from the pylorus.

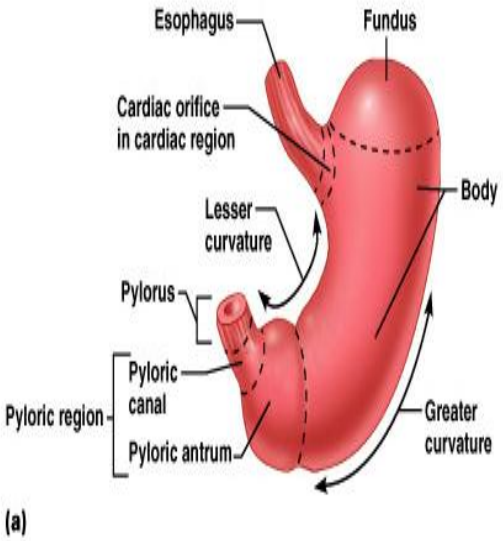

- **Pylorus;** divided into 3 parts:

1. *Pyloric Antrum*: receives acidic chyme
2. *Pyloric Canal*: 1 inch long
3. *Pyloric Sphincter*: It is both an anatomical and a physiological sphincter since there is a thickening in the smooth muscle layer.

There is a vein that always appears to cross the sphincter called the **Vein of Mayo**; it is considered a *landmark* on the pyloric sphincter and is used to find it.

- The duodenum follows which is C-shaped and divided into 4 parts.

The Orifices of The Stomach

- **Cardiac orifice:** A physiological and not an anatomical sphincter.
  Surface Anatomy:
  - *At the level of the 7th left costal cartilage*
  - *1 inch to the left of the midline*
  - *45 cm from the incisor*
  - *10 cm from the anterior abdominal wall*

- **Pyloric Orifice:** An anatomical and a physiological sphincter.
  Surface Anatomy:
  - *Lies at the level of L1*, the transpyloric line is also there and passes through the pylorus (it also passes through the fundus of the gallbladder and the 9th costal cartilage at the level of L1)
  - *The pyloric sphincter lies 1 inch to the right of the midline*. Also at the level of L1 on the transpyloric line.
  - *The Vein of Mayo* is also a landmark that indicates the site of the pyloric sphincter.

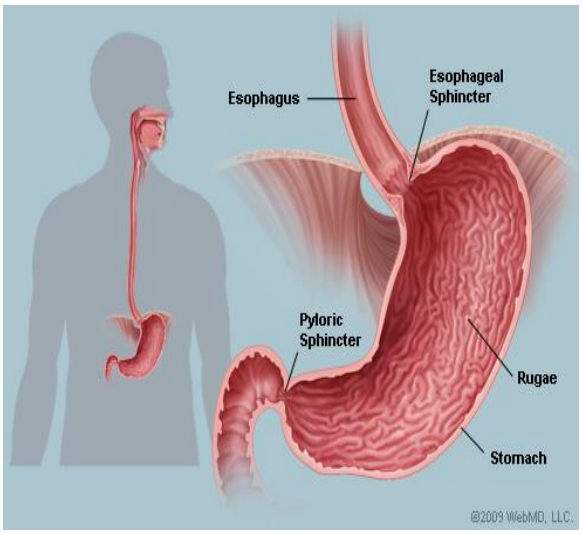

We have here the *Pyloric Sphincter*, which receives **sympathetic motor fibers** which lead to **constriction** of the sphincter. (Sympathetic innervations always lead to constriction of sphincters except for the cardiac orifice which received vagal "parasympathetic" innervations). When the stomach is being evacuated, the parasympathetic fibers are stimulated which inhibit the sphincter and cause it to relax.

- There is also hormonal control which will be explained in Physiology.

Curvatures of The Stomach:

1. **The Lesser Curvature**
   The lesser omentum attaches to it.
2. **The Greater Curvature**
   The greater omentum attaches to it, and it is much longer than the lesser curvature. It extends from the cardiac orifice, and ends at the first inch of the duodenum.

Peritoneum of The Stomach:

The stomach is completely covered by peritoneum; both its anterior and posterior walls are covered by it. The peritoneum is an extension of the **Lesser Omentum** and then forms the **Greater Omentum**. The free edge of the lesser omentum contains the Hepatic artery, the common bile duct and the portal vein.

The greater omentum descends as two layers and then ascends as two layers, attaches to the transverse colon and then meets the mesocolon.

The **Gastrosplenic Ligament** is a ligament that lies between the fundus and the spleen, on the greater curvature and extends from it to the spleen. It contains *Short Gastric Vessels* (5-7 small arteries and vein). The *Left Gastroepibloic Vessels* also descend from it to the greater omentum, those are branches from splenic arteries.

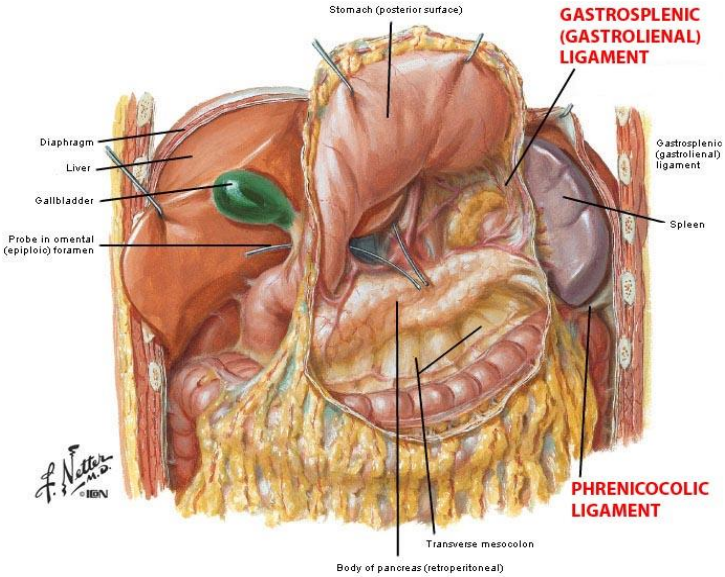

Relations of The Stomach:

- **Anterior-Superior:**

1. *The Anterior Abdominal Wall*
2. *The Left Costal Margin*
3. *The Left Pleura and Lung*
4. *The Left Cupula of The Diaphragm* (dome-shaped, above it lie the left pleura and lung)
5. *The Left Lobe of The Liver*

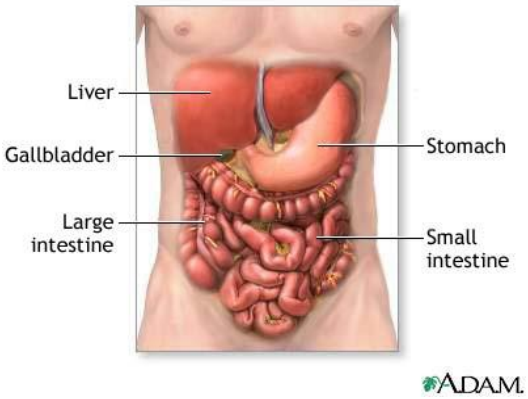

- **Posteriorly:**

Behind the stomach lies <u>The Stomach Bed:</u>

1. *Lesser Sac*: a space behind the stomach, when you eat and the stomach is filled it dilates. This sac allows for the distention of the stomach.
2. *The Left Crus of The Diaphragm*: because the origin of the left crus is from the bodies of L1, 2, 3.

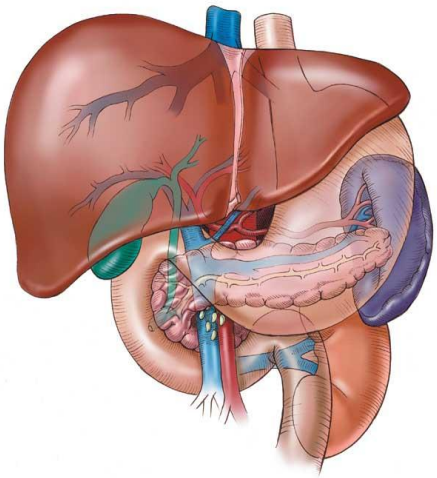

3. *Left Suprarenal Gland*
4. *Left Kidney*
5. *Pancreas*: especially the body of the pancreas. On the upper border of the pancreas lies the *Splenic Artery*, a branch of the Celiac Trunk. (The Splenic vein passes on the posterior surface of the pancreas and is therefore not considered a part of the stomach bed)
6. *Transverse colon*
7. *Mesocolon* (attached to the anterior border of the pancreas)

The Blood Supply of The Stomach:

The stomach follows the foregut, which is until the middle of the duodenum and is hence supplied by **The Celiac Trunk**. The celiac trunk originates *between T12 and L1* from the *anterior surface of the abdominal aorta*. It is found above the pancreas and behind the stomach, & is related to the crus of the diaphragm and lumbar nerves. It has Celiac Ganglia (sympathetic) and Celiac Lymph nodes (drain the stomach and foregut) on each side. It is a very short trunk (1cm) and directly gives 3 branches which are:

1. **The Splenic Artery** – passes behind the stomach on the upper border of the pancreas. Gives four or five branches when it reaches the spleen, some are:
- The *Left Gastroepibloic Artery*
- The *Short Gastric Arteries*; go mainly to the fundus of the stomach.
2. **The Left Gastric Artery** – goes to the body, the fundus, the upper part of the stomach and the lower third of the esophagus
3. **The Hepatic Artery** – goes to the liver; divides into right and left branches at the porta hepatis. It branches off to give the *Right Gastric Artery*, which supplies the right side of the stomach and runs along the lesser curvature.

The right branch of the hepatic artery gives the *Cystic Artery* which supplies the Gall Bladder.

The hepatic artery also gives The *Gastroduodenal Artery*, which passes behind the first inch of the duodenum.

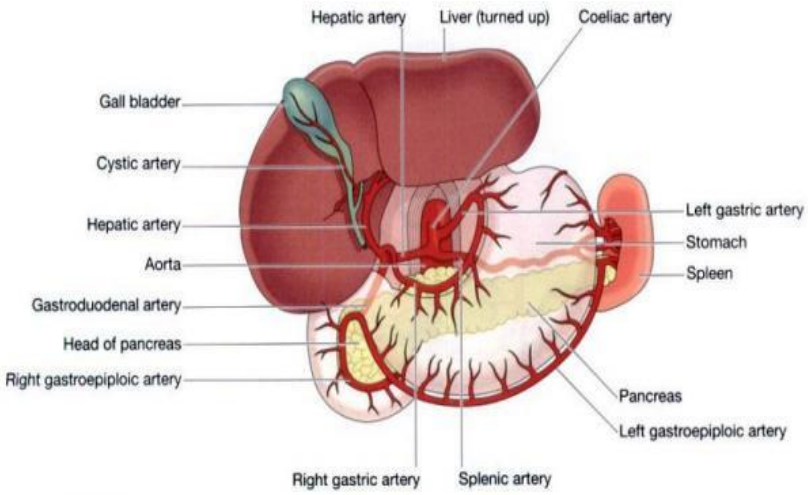

The Gastroduodenal Artery gives rise to the *Right Gastroepibloic Artery* which runs along the greater curvature of the stomach.

- So the left gastroepibloic artery comes from the splenic and the right one from the gastroduodenal branch of the hepatic artery.
- Left and right gastric arteries lie on the lesser curvature and are of the contents of the lesser omentum.

CLINICAL APPLICATION:

The Gastroduodenal Artery passes behind the first inch of the duodenum on the posterior wall; if there is an ulcer on the posterial wall of the duodenum it may result in perforation of the duodenum and then *erosion* of the gastroduodenal artery causing *bleeding*. This is a complication of **duodenal perforation** and requires urgent treatment.

The Venous Drainage of The Stomach:

The venous drainage of the stomach goes into *the portal vein* so:

- **The Left Gastric Vein** carries blood from the lower third of the esophagus and from the stomach then it goes directly to the *Portal Vein*.
- **Right Gastric Vein** and **Right Gastroepiploic** go to the *Superior Mesenteric Vein*.
- **Left Gastroepiploic Vein** and **Short Gastric Veins** go to the *Splenic Vein*, and then the Splenic Vein and the Superior Mesenteric vein form the *Portal Vein* behind the neck of the pancreas.

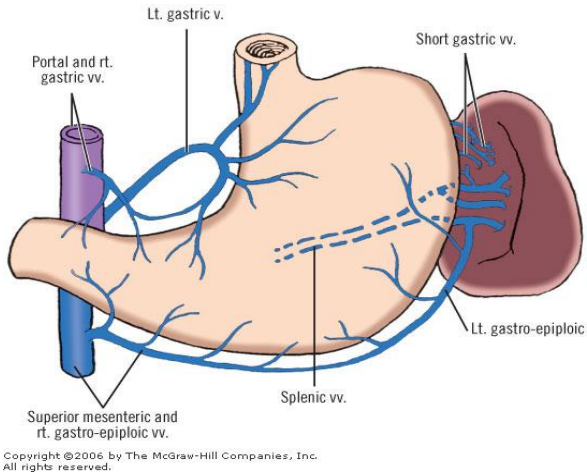

Nerve Supply of the stomach:

Nerve supply of the stomach has sympathetic and parasympathetic innervations:

- **Sympathetic Innervations:** Come from the Celiac Ganglia (around the celiac trunk)

1- *Give Motor Fibers to The Sphincters*
2- *Carry a Proportion of Pain Sensations*

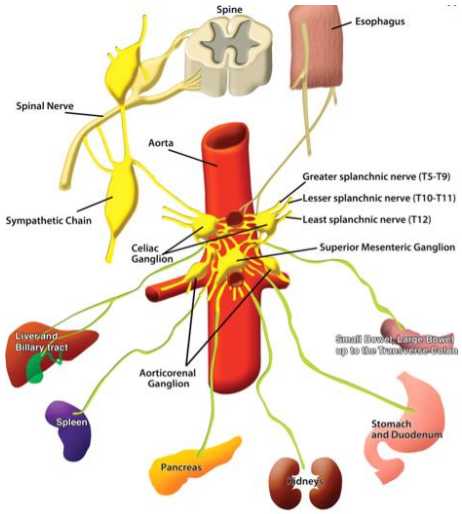

Therefore when someone has abdominal colic for example, sympathetic fibers carry that sensation of pain. (In some references it is stated that ascending parasympathetic fibers do this as well.)

Extra Note: The general visceral afferent fibers (ascending fibers) conduct sensory impulses (usually pain or reflex sensations) from the viscera, glands, and blood vessels to the central nervous system. They are considered to be part of the autonomic nervous system. However, unlike the efferent fibers of the autonomic nervous system, the afferent fibers are not classified as either sympathetic or parasympathetic.

- **Parasympathetic Innervations:** Come from the Right and Left Vagus Nerves, and they are:

1- *Secretomotor to The Gastric Glands*
2- *Motor to the Smooth Muscles*, responsible for the Peristaltic Movement.

There are Parasympathetic fibers in the Myenteric nerve plexus of the stomach. Parasympathetic innervations come from the Vagus Nerve as follows:

The Vagus Nerve gives two branches (two vagi) around the esophagus which form the esophageal plexus of nerves; it has both sympathetic and parasympathetic nerve fibers. In the abdomen, the Left Vagal becomes Anterior Gastric (Anterior Vagal Trunk), and the Right Vagal becomes Posterior Gastric (Posterior Vagal Trunk).

Anterior Vagal Trunk gives:

1- **Anterior Gastric Branches** which supply the *anterior surface of the stomach*.
2- **Hepatic Large Branches** to the *liver*.
3- **Latarjet Nerve**; goes to the *pylorus* to help with the evacuation.

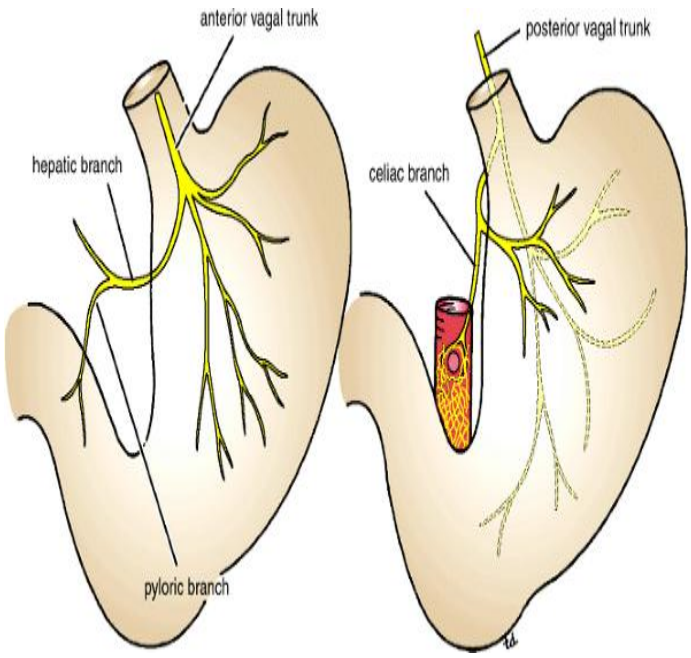

Posterior Vagal Trunk gives:

1- **Posterior Gastric Branches** which supply the *posterior surface of the stomach*, then join the anterior ones.
2- **Celiac Branch** goes to the *lateral third of the transverse colon* (the splenic flexure).
3- **Latarjet nerve** to the *pylorus*.

CLINICAL APPLICATION:

As we mentioned before, **The Latarjet Nerves** are important for the *evacuation of stomach contents*. When doctors used to perform an operation to treat Peptic Ulcer as they thought that it was due to hyperacidity; but fifteen years ago, this theory was disproven and they discovered that *peptic ulcer is caused by Helicobacter Pylori*, which is a type of bacteria in the normal flora of the stomach and causes the peptic ulcer when activated. The treatment became medical after it was surgical.

They used to perform **Truncal Vagotomy**: they cut the Vagi around the esophagus (1.3 cm below the diaphragm), this always used to cause problems because the pylorus won't evacuate anymore and they had to do **Pyloroplasty** as well. In an attempt to solve this, they tried to cut every branch of the Vagus nerve except for the latarjet nerve to maintain the evacuation. However, all of these treatments are not used anymore, and they only use antibiotics to treat the bacterial infection, and some drugs to decrease the acidity.

Lymphatic drainage of stomach

All of the lymphatics of the stomach and the foregut go into the **Celiac Lymph Nodes** and accompany the veins. The Celiac lymph nodes are located around the Celiac Trunk. The lymph nodes of the stomach are as follows:

- **Left and Right Gastric Lymph Nodes** go *directly* into the Celiac Lymph Nodes.
- **Gastroepiploic Lymph Nodes**:
  - *Right* Gastroepiploic accompany the *Superior Mesenteric Nodes*
  - *Left* Gastroepiploic accompany the *Splenic Nodes*

Eventually they go into the Celiac Lymph Nodes

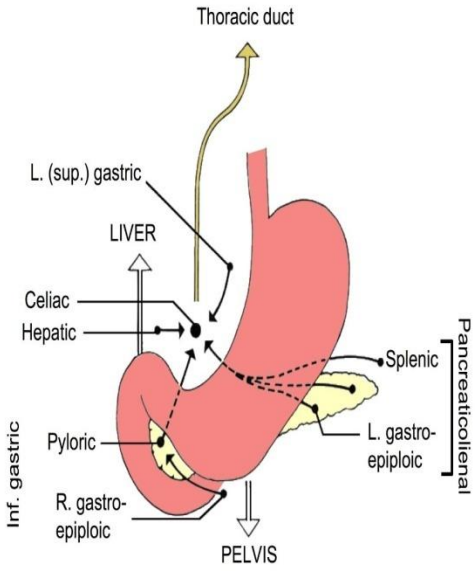

- Hepatic from the liver.
- Pyloric from the pylorus.

And they are all related to the venous drainage and finally reach the celiac lymph nodes.