3rd year

University of Jordan
Faculty of Medicine

Medical Committee
The University of Jordan

The Central Nervous System

Anatomy

1

- [ ] Slides
- [ ] Sheet
- [x] Handout

Title: _____

Professor: Dr.Faraj Bustami

Date: 1/2/2014

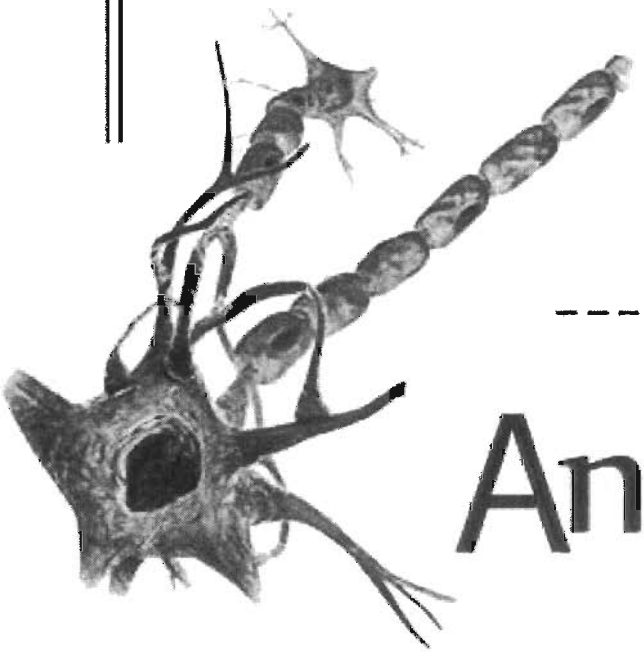

Sheet written by:

_____

Anatomy

Price: __75__

١/٢/٢٠١٤

Design:
Waseem Kamal

من محاضرات أ.م.د. مزرع البسطامي
لطلبة ثالثة طب بشري 2015

Neuroscience

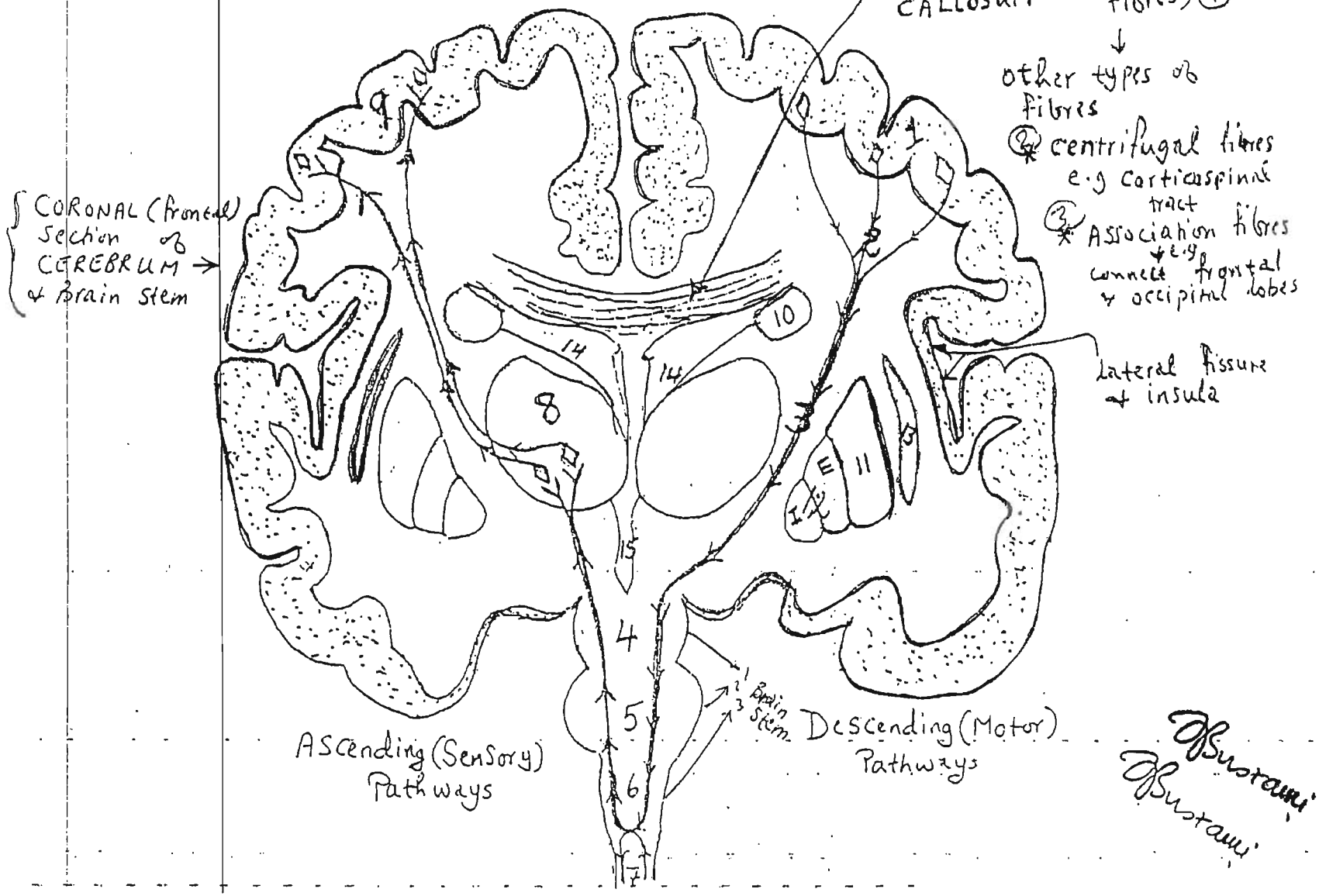

1

Bustami
Bustami

من محاضرات أ.م.د. مزرع البسطامي
لطلبة ثالثة طب 2015

1

Obustami 2

Explanation for the diagram

No. (1) → Cerebral cortex → formed of gray matter i.e Neurons → The axons of these neurons may descend forming projection fibres (centrifugal fibres) or cross from one cerebral hemisphere to the other forming commissural fibres (e.g corpus callosum). Note how the cortex is thrown into gyri separated by sulci or fissures → this is in order to increase the surface area.

No. (2) the descending axons form part of the corona radiata and continue down to form (3) → the corticospinal tract (a major motor pathway) which continues in the brainstem and most of its fibres decussate (cross) to the opposite side at the lower part of the medulla.

N.B. a - Notice that the descending fibres in the corticospinal tract CROSS at the lower medulla oblongata so that the right cerebral cortex will control muscles of the left half of the body and the left cerebral cortex will control muscles of the right side of the body.

b - The corticospinal tract is one component of the pyramidal tract, the other component is the corticobulbar tract which also begins at the motor cortex but ends at the motor nuclei of certain cranial nerves.

(2) Axons of motor neurons of the cerebral cortex forming the corona radiata.

(3) This is the internal capsule which represents the gate (بوابة → (porta cerebri)) to the cerebral cortex i.e. all the fibres that come from (i.e. motor) or go to (i.e. sensory) the cerebral cortex will run here in a compact bundle. As a result lesion in this part of the brain (e.g. obstruction of the blood vessels which supply this region by embolism or thrombosis will lead to widespread disturbances (خلل ثنائي) e.g. hemiplegia (paralysis of the contralateral half of the body and hemianaesthesia (loss of sensations in the contralateral half of the body) (المقابل)

(4) Midbrain : This is a part of the brainstem which contains ascending (sensory) and descending (motor) tracts. In addition it contains the nuclei of the third and fourth cranial nerves. ⊕ Red nucleus ⊕ Substantia nigra

(5) Pons : This is another part of the brain stem which contains ascending and descending tracts. In addition it contains the nuclei of the 5th, 6th, 7th and 8th cranial nerves.

(6) Medulla oblongata : this is the lower part of the brain stem. In addition the ascending and descending tracts it contains the nuclei of the 9th, 10th, 11th and 12th cranial nerves. The medulla oblongata has the following centres which control vital visceral activities:

a. cardiac centre: Impulses from this centre run along the vagus nerves and can cause the heart to beat more slowly or more rapidly

VMC

b. Vasomotor centre : impulses from this centre travel to smooth muscles in the walls of arterioles and causes either vasoconstriction (and a rise in blood pressure) or vasodilation (or drop in blood pressure)

c. Respiratory centre : it functions, together with the respiratory centre in the pons to regulate the rate and depth of breathing.

d. Other centres : for reflexes associated with coughing, sneezing, swallowing and vomiting.

N.B. Scattered throughout the medulla oblongata, pons and midbrain a complex network of nerve cells and nerve fibres known as the RETICULAR FORMATION. It is connected to most of the ascending (sensory) pathways as well as to the cerebrum, basal ganglia and cerebellum. When sensory impulses reach the reticular formation, it responds by signaling the cerebral cortex activating it into a state of wakefullness (hence the name reticular activating system RAS)

(RF)

Without this arousal, the cortex remains unaware of stimulation and cannot interpret sensory information or carry on thought processes. Thus if the reticular formation ceases to function as in certain injuries, the person remains unconscious. In addition many drugs e.g. anaesthetics and tranquilizers are believed to have some effect on the reticular formation.

(7) beginning of spinal cord

(8) Thalamus : This is the upper part of the diencephalon. The lower part of this region is called the hypothalamus. It lies below the thalamus and contains many nuclei. The thalamus serves as a central relay station for sensory impulses traveling upward from other parts of the nervous system to the cerebral cortex. It receives all sensory impulses (except smell) and send them to appropriate regions of the cortex for interpretation. In other words it acts as a SECRETARY to the sensory cortex. In addition it has a motor part connected to the motor cortex, basal ganglia and cerebellum and concerned with the regulation of voluntary motor activity

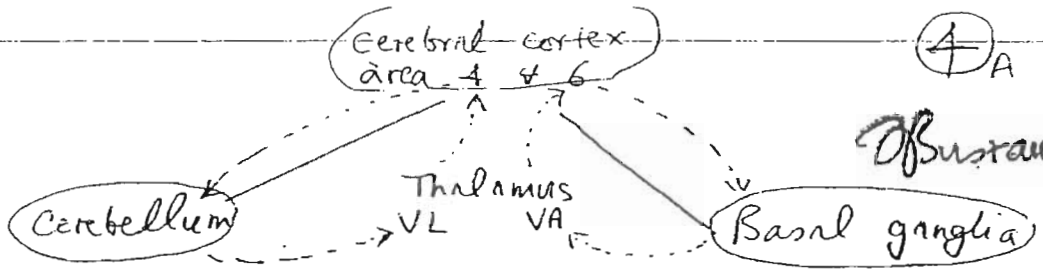

Dr Bustami

VA = Ventral anterior nucleus of thalamus
VL = ventral lateral >> " " "

Remember that the cerebral cortex (motor areas) initiates voluntary movement but inorder that this movement is smooth and accurate the cerebral cortex need the presence of functioning cerebellum and basal ganglia

The Hypothalamus : plays key roles in maintaining HOMEOSTASIS by regulating a variety of visceral activities and by serving as a link between the nervous and endocrine systems.

Among the many important functions of the hypothalamus are the following:-

1. Regulation of heart rate and arterial blood pressure
2. Regulation of body temperature
3. Regulation of water and electrolyte balance
4. control of hunger and regulation of body weight
5. control of movements and glandular secretions of the stomach and intestines
6. Production of neurosecretory substances that stimulate the pituitary gland to release various hormones
7. Regulation of sleep and wakefulness.

---

9. Sensory part of cerebral cortex which interpret impulses that arrive from various sensory receptors.
10. Caudate nucleus
11. Putamen → Lentiform nucleus (lenticular nucleus)
12. globus pallidus → external segment, internal >>
13. Claustrum

N.B. 10+ 11 + 12 + 13 = basal ganglia or basal nuclei → Contribute to motor activity (planning & programming of movement)

14. Lateral ventricle i.e. cavity of cerebrum
15. third ventricle

(Both ventricles contain cerebrospinal fluid - CSF).

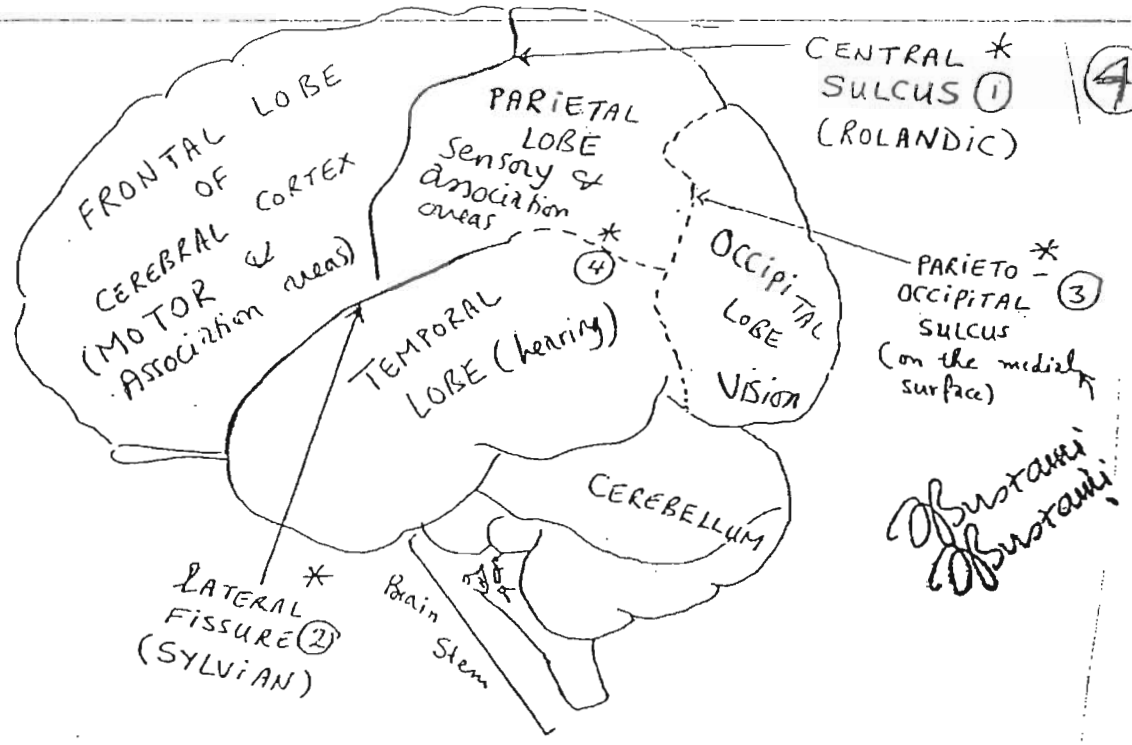

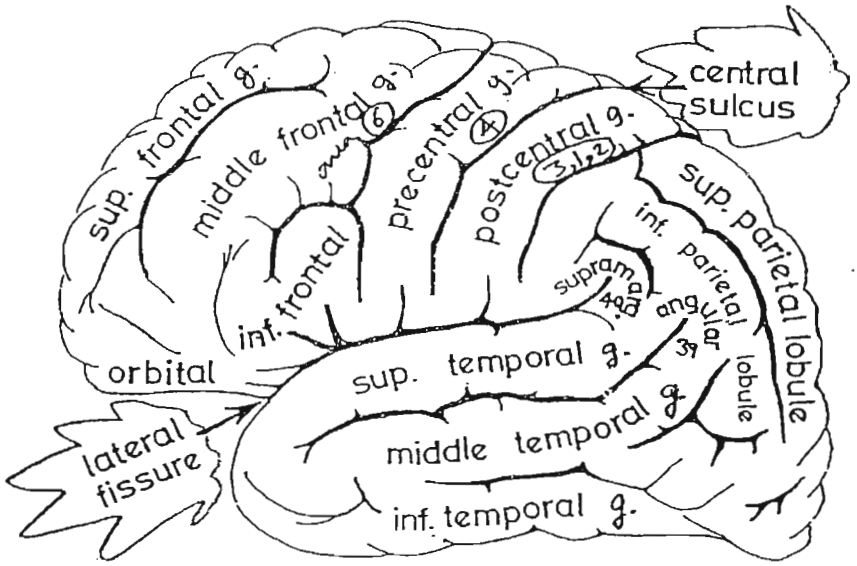

Fig. 48 The gyri of the lateral surface of the cerebral hemisphere.

Precentral gyrus (frontal lobe) = area 4 = Primary motor cortex

Premotor cortex (~~frontal lobe~~) = area 6

Supplementary motor area (SMA) = medial extension of area 6

Postcentral gyrus (parietal lobe) = area 3, 1, 2 = Somatic sensory cortex or Somasthetic cortex

ORIENTATION

Bustami
Bustami

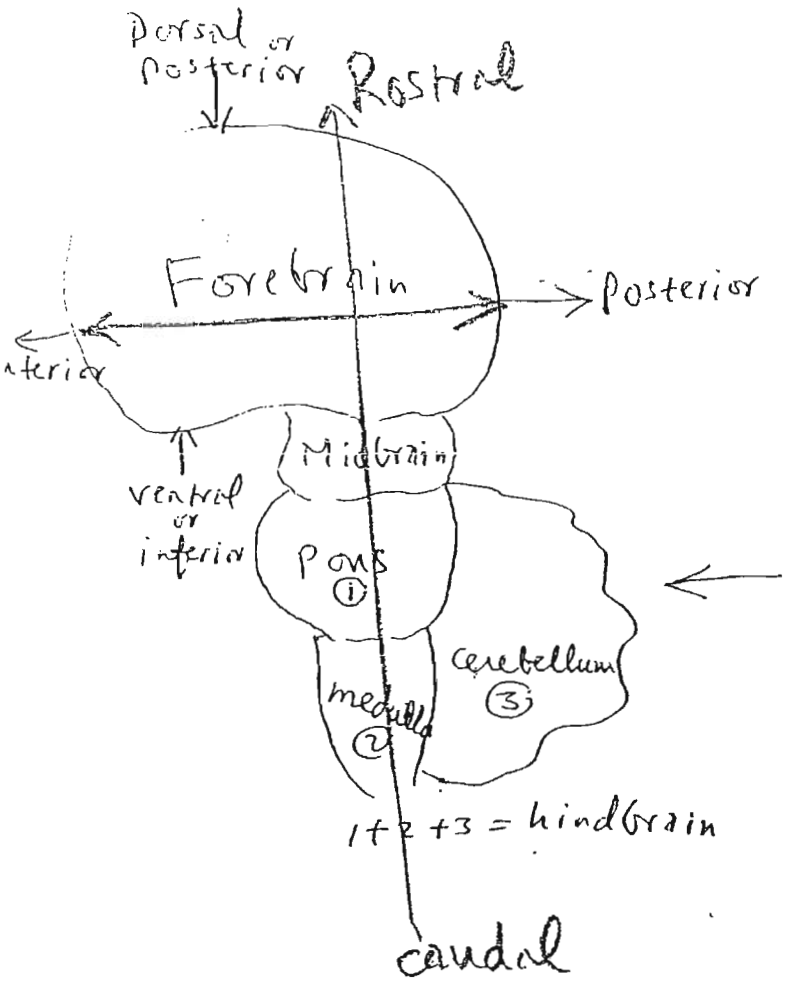

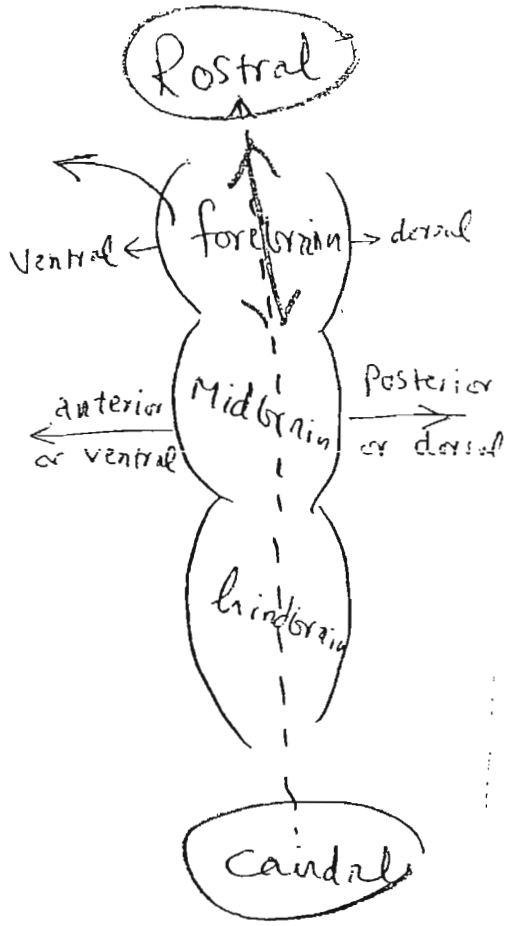

The midbrain, hindbrain, spinal cord → oriented almost vertically
whereas forebrain → oriented horizontally

{ A change in orientation at midbrain - forebrain junction (i.e) }

↓

the terms dorsal & ventral have different use

Table 1. Motor and Sensory Classification of Nerve Fibers

Sensory (Groups)		Sensory and Motor	Greatest Fiber Diameter (μ)	Greatest Conduction Velocity (meters/sec)	General Comments
Ia	=	$A\alpha$	22	120	Motor—the large alpha motor neurons of lamina IX Sensory—the primary afferents (annulospiral) of muscle spindles
Ib	=	$A\alpha$	22	120	Sensory—Golgi tendon organs, touch, and pressure receptors
II	=	$A\beta$	13	70	Sensory—the secondary afferents (flower spray) of muscle spindles, touch, and pressure receptors, Pacinian corpuscles (vibratory sensors)
		$A\gamma$	8	40	Motor—the small gamma motor neurons of lamina IX innervate muscle spindles
III	=	$A\delta$	5	15	Sensory—small lightly myelinated fibers, touch, pressure, pain, and temperature
		B	3	14	Motor—small lightly myelinated preganglionic autonomic fibers
IV	=	C	1	2	Motor—all postganglionic autonomic fibers (all are unmyelinated) Sensory—unmyelinated pain and temperature fibers

Notice → Afferents from muscle spindle are Ia & II

Afferents from Golgi tendon organ is → Ib

Pain fibres run in two types of afferents → Aδ & C

Remember that the greater the diameter of the nerve fibre → the thicker the myelin sheath and the faster the conduction velocity

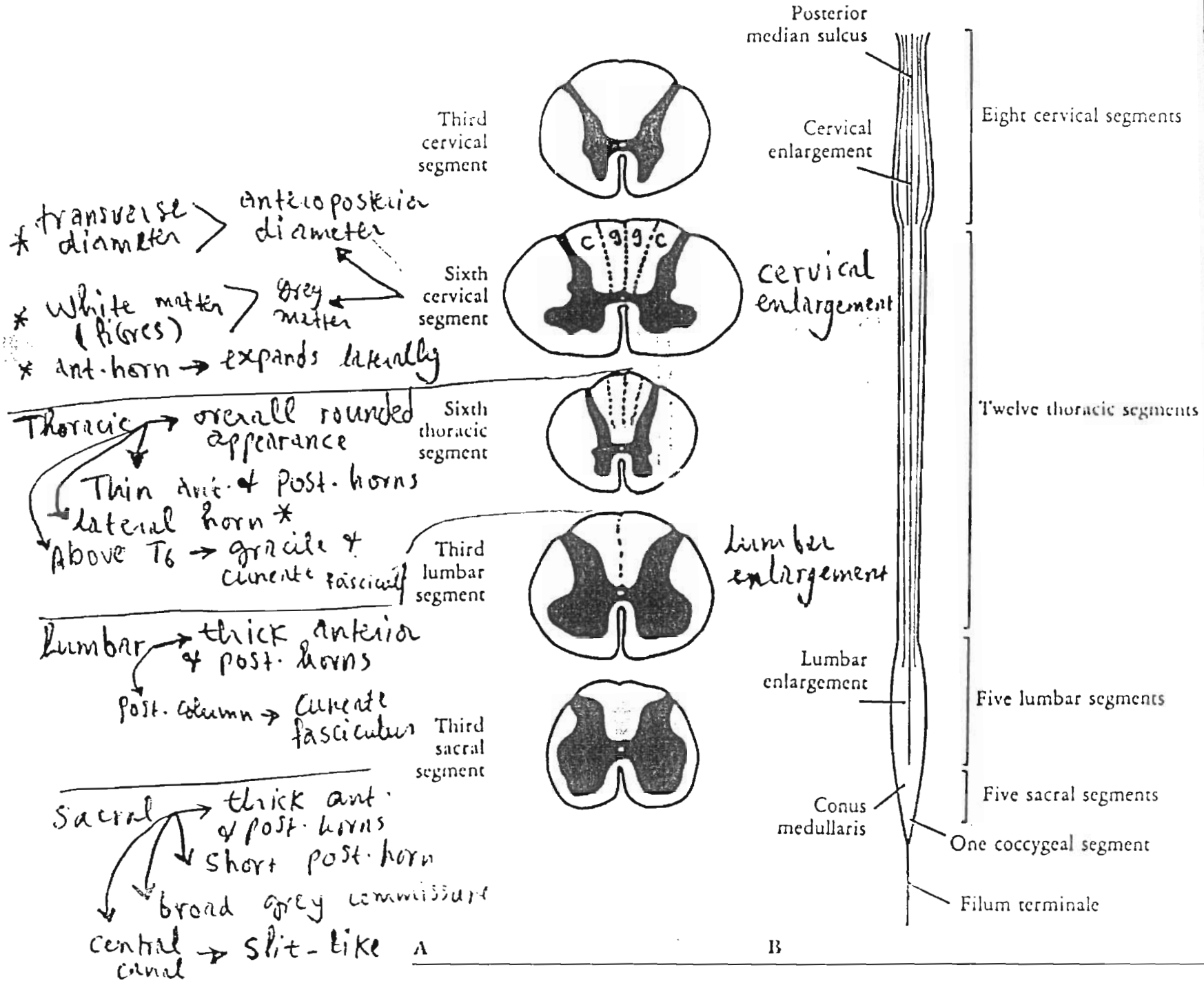
Posterior median sulcus
Cervical enlargement
Eight cervical segments
Third cervical segment
Sixth cervical segment
c g g c
cervical enlargement
Twelve thoracic segments
Sixth thoracic segment
Third lumbar segment
lumber enlargement
Lumbar enlargement
Five lumbar segments
Third sacral segment
Five sacral segments
Conus medullaris
One coccygeal segment
Filum terminale
A
B
* transverse diameter > anteroposterior diameter
* White matter (fibres) > grey matter
* ant. horn → expands laterally
Thoracic → overall rounded appearance
Thin ant. & post. horns
lateral horn *
Above T6 → gracile & cuneate fasciculi
Lumbar → thick anterior & post. horns
post. column → cuneate fasciculus
Sacral → thick ant. & post. horns
short post. horn
broad grey commissure
central canal → slit-like

5(5)

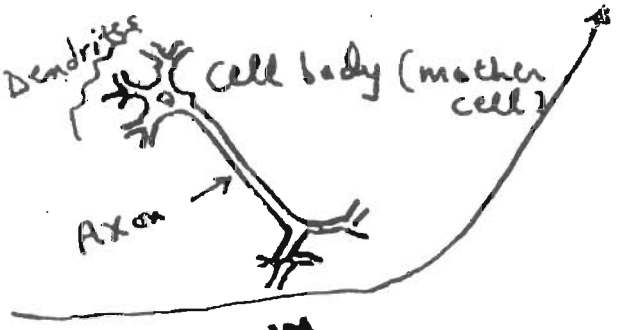

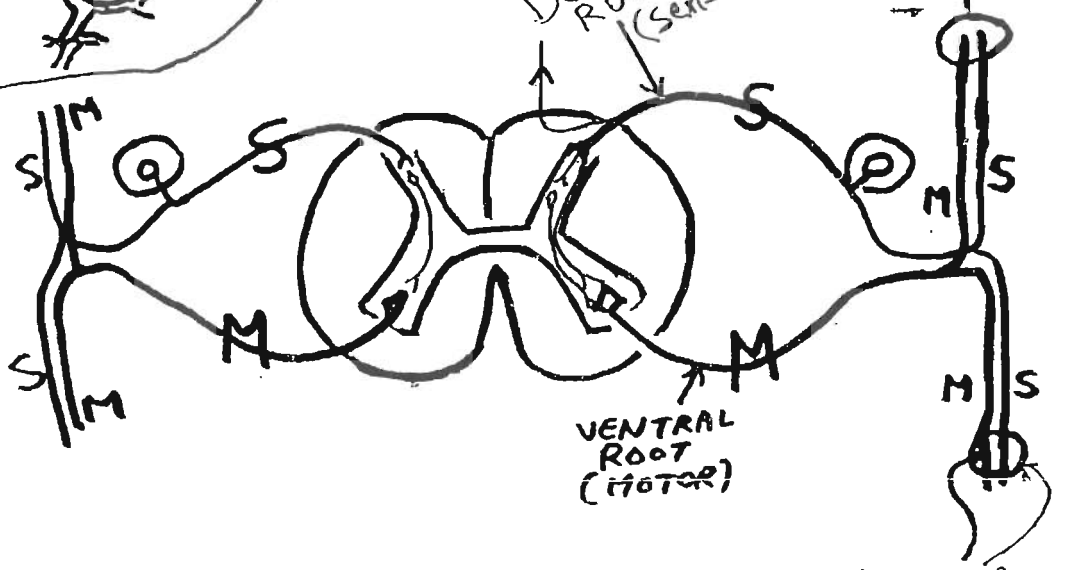

MIXED NERVE → Motor fibres, SENSORY Fibres, sympathetic fibres ??

NO Synapse

Dorsal root ganglion = Sensory ganglion = spinal ganglion

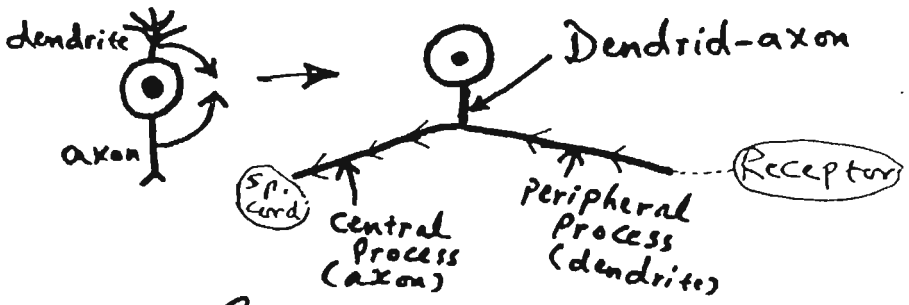

<Pseudo-unipolar neuron>

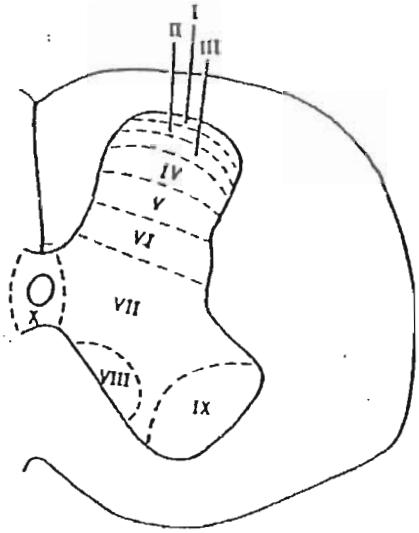

Schematic diagram of half of the spinal cord showing the location of Rexed

Laminae I to IV are concerned with exteroceptive sensations, whereas laminae V and VI are concerned primarily with proprioceptive sensations, although they respond to cutaneous stimuli. Lamina VII acts as a relay between midbrain and cerebellum. Lamina VIII modulates motor activity, most probably via the gamma neuron. Lamina IX is the main motor area of the spinal cord. It contains large alpha and smaller gamma motor neurons. The axons of these neurons supply the extrafusal and intrafusal muscle fibres respectively.

Table 5.1. Cellular Organization of Spinal Cord

Rexed terminology	Older terminology
Lamina I	Posteromarginal nucleus
II	Substantia gelatinosa
III, IV	Nucleus proprius
V	Neck of posterior horn
VI	Base of posterior horn
VII	Intermediate zone, intermediolateral horn
VIII	Commissural nucleus
IX	Ventral horn
X	Grisea centralis

The motoneurons of the spinal cord are arranged in *columns* which supply muscle groups having similar functions. The individual muscles are supplied from cell groups (nuclei) within the columns. Medially placed columns supply the axial (trunk) musculature. Laterally placed columns, present only in the cervical and lumbar enlargements, supply the limb musculature. Finally, motoneurons innervating extensor muscles lie in front of motoneurons innervating flexors (Fig. 10-1, Table 10-1).

Table 10-1 Motor cell columns

Cell column	*Muscles*
Ventromedial (all segments)	Erector spinae
Dorsomedial (T1–L2)	Intercostals, abdominals
Ventrolateral (C5–8, L2–S2)	Arm/thigh
Dorsolateral (C6–8, L3–S3)	Forearm/leg
Retrodorsolateral (C8, T1, S1, S2)	Hand/foot
Central (C3, C4, C5)	Diaphragm

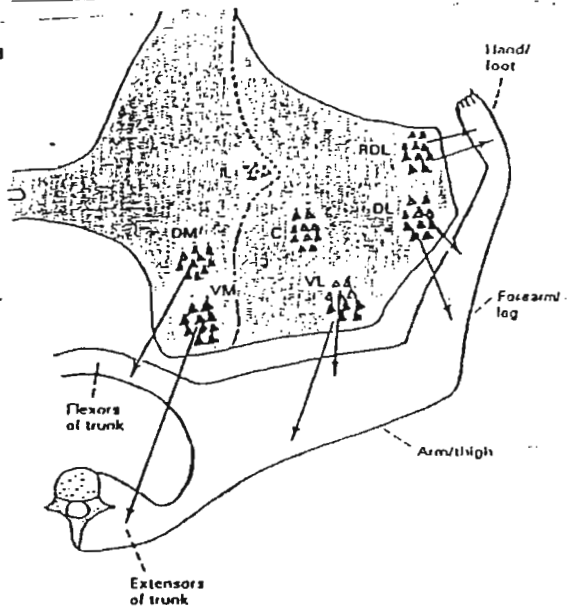

Fig. 10-1 Cell columns in the gray matter. Dotted line indicates limit of gray matter at thorack level. C, central; DL, dorsolateral; DM, dorsomedial; IL, intermediolateral (autonomic); RDL, retrodorsolateral (for intrinsic muscles); VL, ventrolateral; VM, ventromedial nucleus.

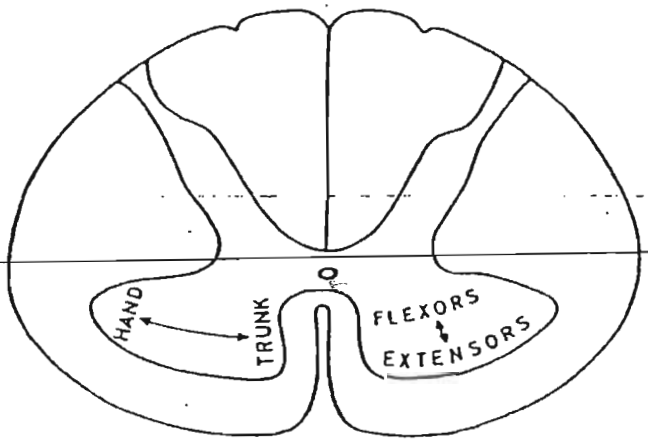

Figure 5.6.—Schematic diagram of the spinal cord showing somatotopic organization of ventral horn neurons.

Descending Motor pathways

Bustami

8

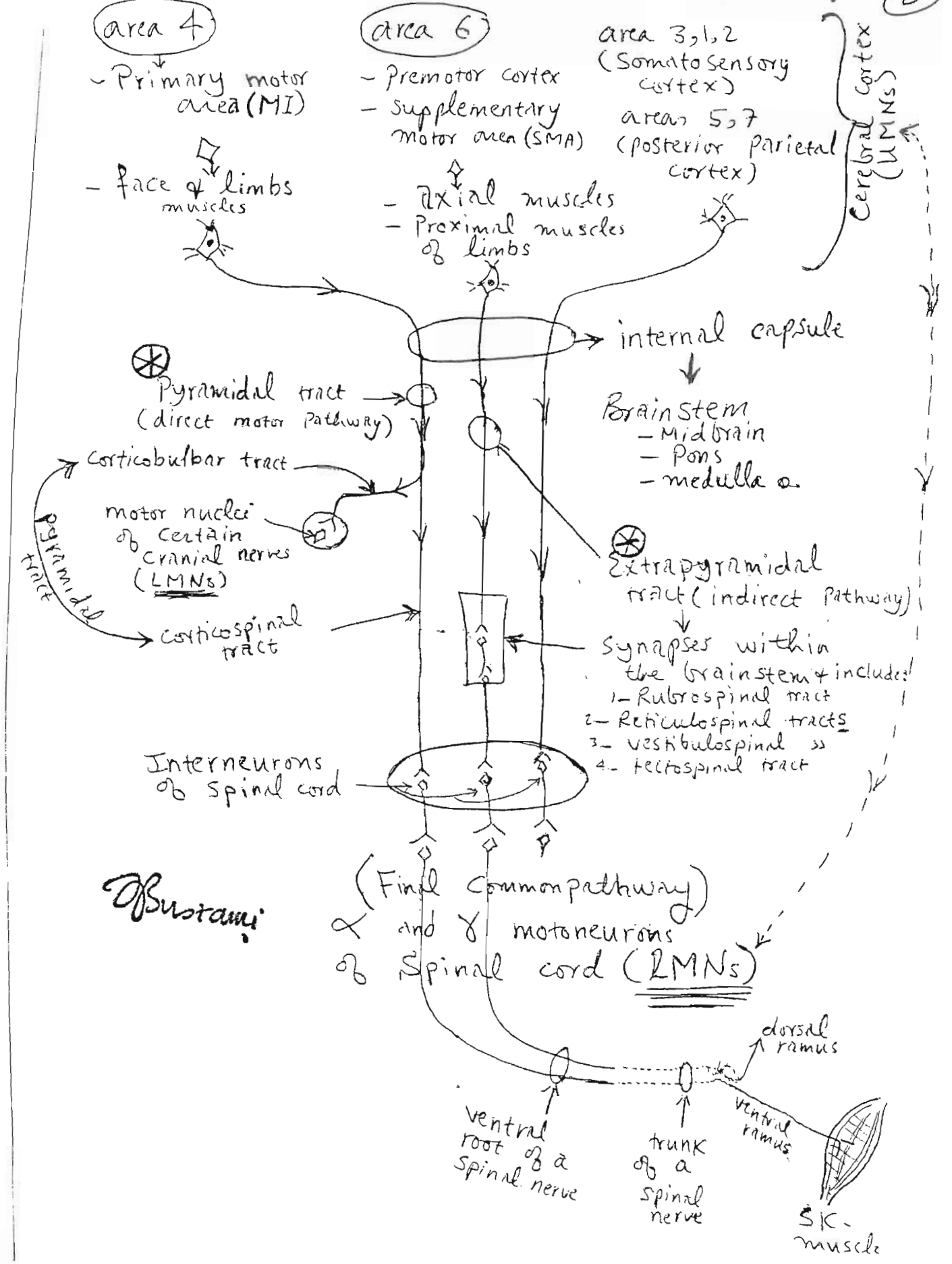

Bustami

Descending Tracts (Motor Pathways)

- A tract or pathway ? a bundle of nerve fibres that have the same origin, same termination and carry same function. Bustami
- The descending tracts or the motor pathways START at Supraspinal neurons present in the cerebral cortex (e.g areas 4 & 6) or in the medulla, Pons or midbrain (e.g neurons of reticular formation or red nucleus or superior colliculus). All these neurons which give rise to the descending motor pathways are called (UPPER MOTOR NEURONS)
- The (LOWER MOTOR NEURONS) are present in:-
  - → Brainstem ← medulla, pons, midbrain } where they give rise to motor fibres in certain cranial nerves
  - → Spinal cord → these are the alpha (α) and gamma (γ) motor neurons present in the ventral horn of grey matter of spinal cord and give rise to motor fibres in every spinal nerve
- The motor pathways run between the upper and lower motor neurons, however they do not synapse directly with the lower motor neurons (α and γ) but mostly through interneurons

Bustami

Descending (motor) tracts

Bostany

- PYRAMIDAL
  - Corticospinal
  - Corticobulbar (corticonuclear)
- Extra Pyramidal

10

Bostany

* Corticospinal tract → its name indicate that it begins in the cerebral cortex (areas 4, 6, 3, 1, 2) & terminates in the lower motor neurons of spinal cord (α and γ) mostly through interneurons. This pathway is concerned with voluntary skilled movement especially those of the distal parts of the limbs (hands & feet)
* Corticobulbar (corticonuclear) tract → has the same origin as the corticospinal tract however it DOES NOT reach the spinal cord → it terminates in the brainstem by synapsing on the motor nuclei of certain cranial nerves Mostly Bilaterally
* Extra Pyramidal tract: a group of descending tracts that arise in the brainstem but are under the influence of the cerebral cortex e.g

① Reticulospinal tract < medial (Pontine), lateral (medullary)
they arise from the reticular formation in the pons and medulla and terminate on α and γ motoneurons mostly through interneurons in laminae VII and VIII

② Rubrospinal tract from the Red nucleus in the midbrain to the spinal cord. It runs very close to the lateral corticospinal tract

③ Vestibulospinal tract < medial, lateral from the vestibular nuclei in the brainstem to the spinal cord

④ Tectospinal tract: from the superior colliculus of the midbrain to the spinal cord (cervical and upper thoracic regions)

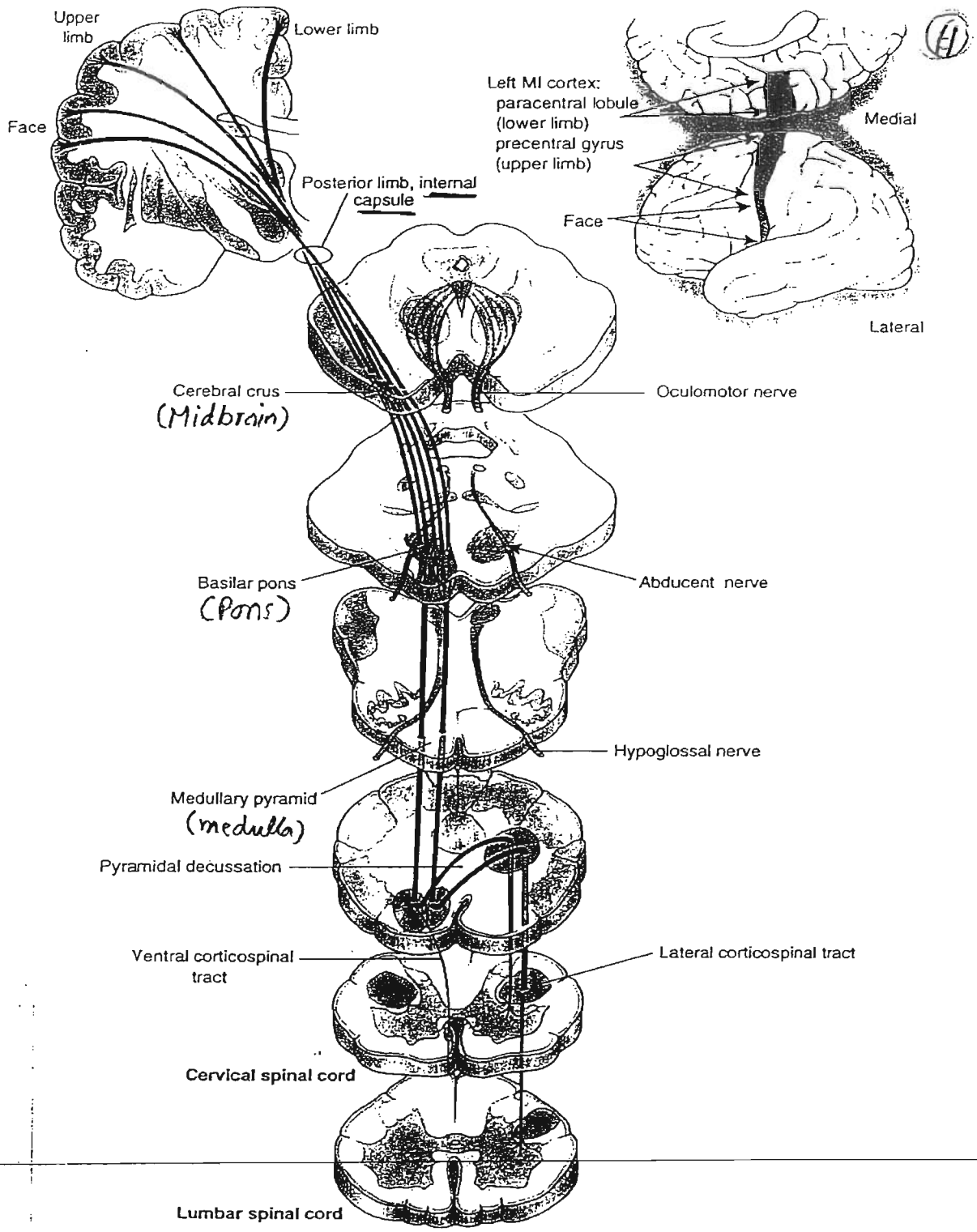

FIGURE 6-2. Schematic diagram of the pyramidal tract, showing its origin, course, and relations.

Alpha-Motoneurons: The only way in which the central nervous system can cause skeletal muscle fibers to contract is by evoking discharges in α-motoneurons. Therefore all motor acts DEPEND ON NEURAL CIRCUITS ⇒ that eventually impinge on α-motoneuron. This is why the α-motoneuron is called → the FINAL COMMON PATHWAY

Spinal cord interneurons: most of the synapses on α-motoneurons originate from spinal cord interneurons. By definition interneurons are neurons interposed between primary afferent neurons and motoneurons. Interneurons whose processes are confined to the spinal cord are often called propriospinal neurons.

- Most spinal cord interneurons are located in the dorsal horn. Many of these are involved in sensory processing and contribute directly or indirectly to the transmission of sensory information to the brain. However, neurons in the dorsal horn also project to the ventral horn and affect the discharges of motoneurons. Furthermore ⇒ axons of descending pathways from the brain RARELY TERMINATE DIRECTLY ON MOTONEURONS → Axons in descending pathways usually end on interneurons and alter motor output by changing the level of activity in spinal cord circuits.

Renshaw cells → are inhibitory interneurons located in the part of lamina VII that protrudes ventrally between the lateral part of lamina IX and lamina VIII. RECURRENT COLLATERALS FROM α-Motor axons SYNAPSE ON RENSHAW CELLS → when the motor axons discharge, they release acetylcholine at the synapses on Renshaw cells and excite these cells. The Renshaw cells in turn synapse on and *inhibit α-motoneurons; thus when motoneurons discharge, this causes an inhibitory feedback by way of Renshaw cells. This is called → Recurrent inhibition. α-motoneurons are always under tonic inhibition by Renshaw cells → Loss of this inhibition (by strychnine) → excessive firing of α-cells → convulsions

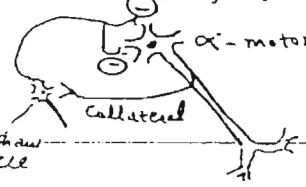

Obusrami

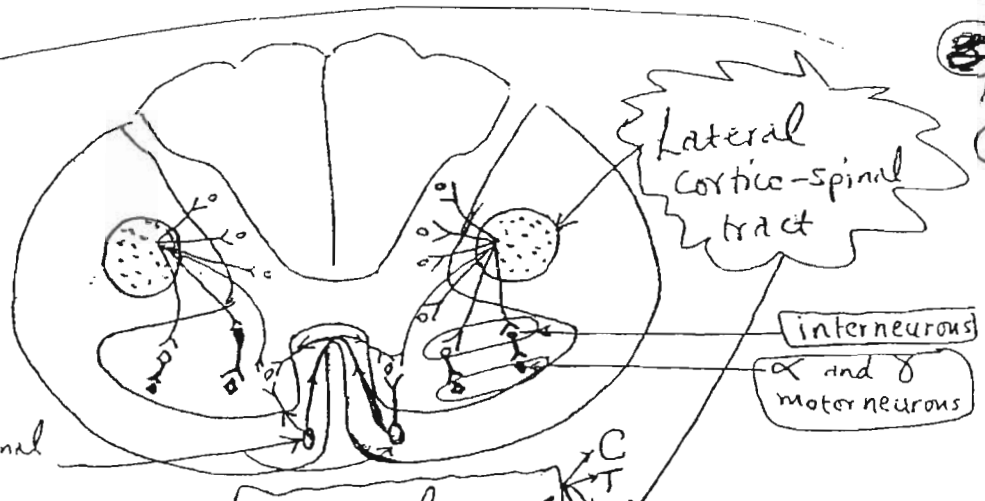

Descends the **full length** of the spinal cord, beside the base of the posterior horn → It is the principle voluntary motor pathway & has facilitatory effect on α & γ motoneurons that supply distal flexor muscles

Termination of axons of lateral corticospinal tract ⇒

On interneurons within laminae IV – VIII

→ Direct projection of a small number of axons on the α and γ motor neurons in lamina IX (9) ???

↓

The lateral corticospinal tract synapses on:

① interneurons of the dorsal horn where it modulates sensory transmission

② α MNs and γ MNs (mostly through interneurons)

↓

eventually influence the

- 55% of its fibres α and γ MNs of Cervical part of spinal cord
- 20% - - - - - - - - - - - - thoracic part - - - - -
- 25% - - - - - - - - - - - - lumbosacral part - - - -

↓

The **lateral** corticospinal tract acts primarily on the **distal** muscles of the limbs while the **ventral** corticospinal tract acts on the **Proximal** muscles . . . .

⇓

The ventral corticospinal tract acts on the Proximal muscles of the upper limb (shoulder muscle) of the ipsilateral (same) and contralateral sides.

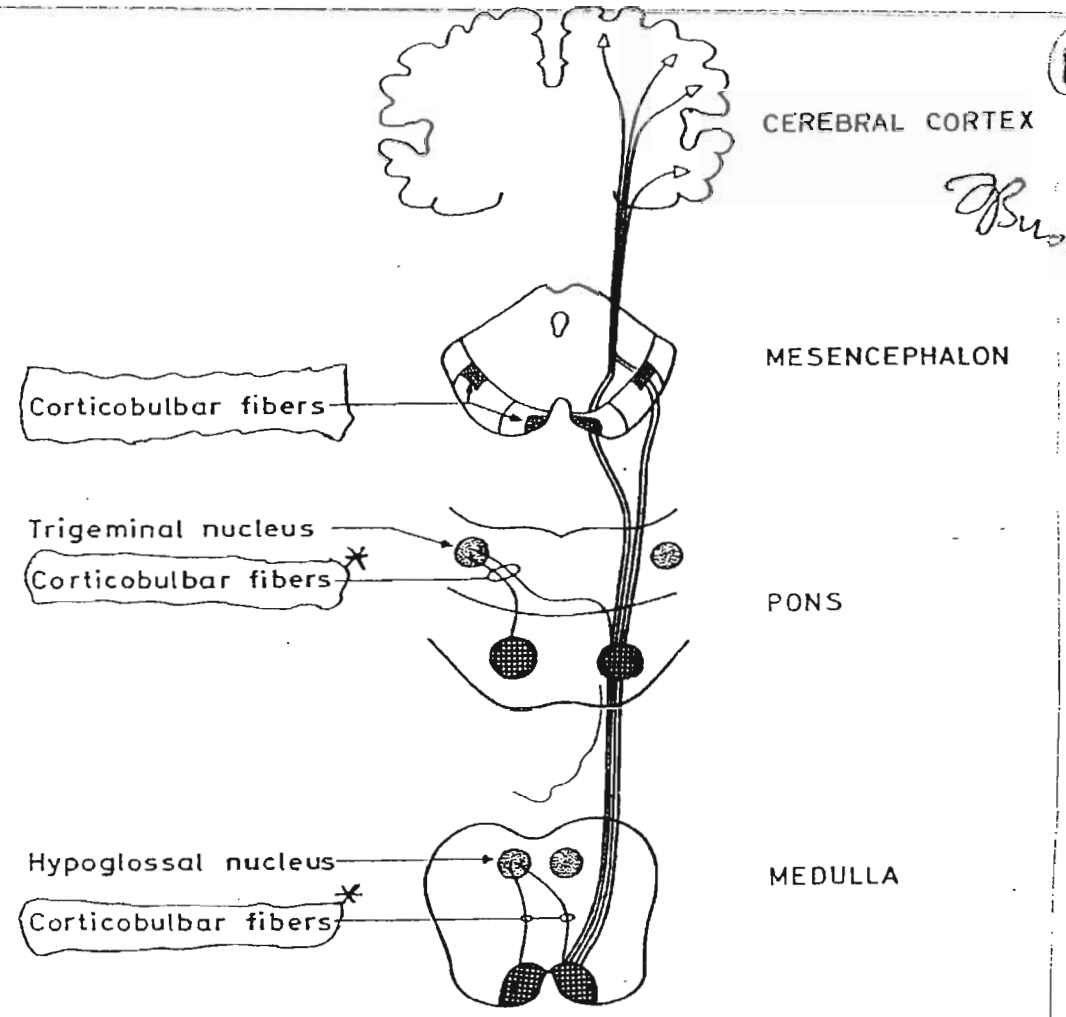

Figure 12.8. Schematic diagram of the corticobulbar pathway.

* CORTICOBULBAR pathway:
FROM the cerebral cortex to → MOTOR Nuclei of certain cranial nerves → 5, 7, 9, 10, 11, 12

* The corticobulbar input to
- 5
- part of 7 which supplies upper facial muscles
- 9, 10, 11
- 12 ??

} Bilateral

* The " input to that part of the facial nucleus which supplies lower facial muscles is from the contralateral hemisphere only.
* Bilateral interruption of the corticobulbar fibres Results in paresis (weakness) but Not paralysis of the muscles supplied by the corresponding cranial nerve nucleus → Pseudobulbar palsy
* Bulbar palsy → complete paralysis ---------- as a result of lesion of nucleus

SPINAL MOTOR NEURONS

The spinal alpha motor neurons innervating an individual muscle or a particular group of muscles are arranged in longitudinal columns extending for various distances in a specific part of the anterior horn. The medial cell column extends the entire length of the spinal cord and innervates the paravertebral or axial muscles. The lateral cell column, which is found at the spinal cord enlargements, innervates the muscles of the limbs. Within the lateral cell column further somatotopic organization exists: the proximal limb muscles are represented medially and the distal muscles, laterally (Figs. 5-11, 5-12, 7-1). The most distal muscles (in the fingers and toes) are represented most dorsolaterally and are limited to the most caudal segments of the cervical and lumbosacral enlargements, respectively.

THE PROPRIOSPINAL SYSTEM OF NEURONS

All movements require the activity of lower motor neurons in more than one spinal cord segment. The number of segments involved in a movement varies. Because axial movements depend on the activity of muscles that extend for great distances along the vertebral column, the paravertebral muscles are innervated by numerous spinal nerves. In contrast, individual finger movements are controlled by the intrinsic muscles of the hand that are innervated by only spinal nerves C8 and T1.

The intersegmental activity required for any particular movement is integrated by the propriospinal system of neurons. The propriospinal

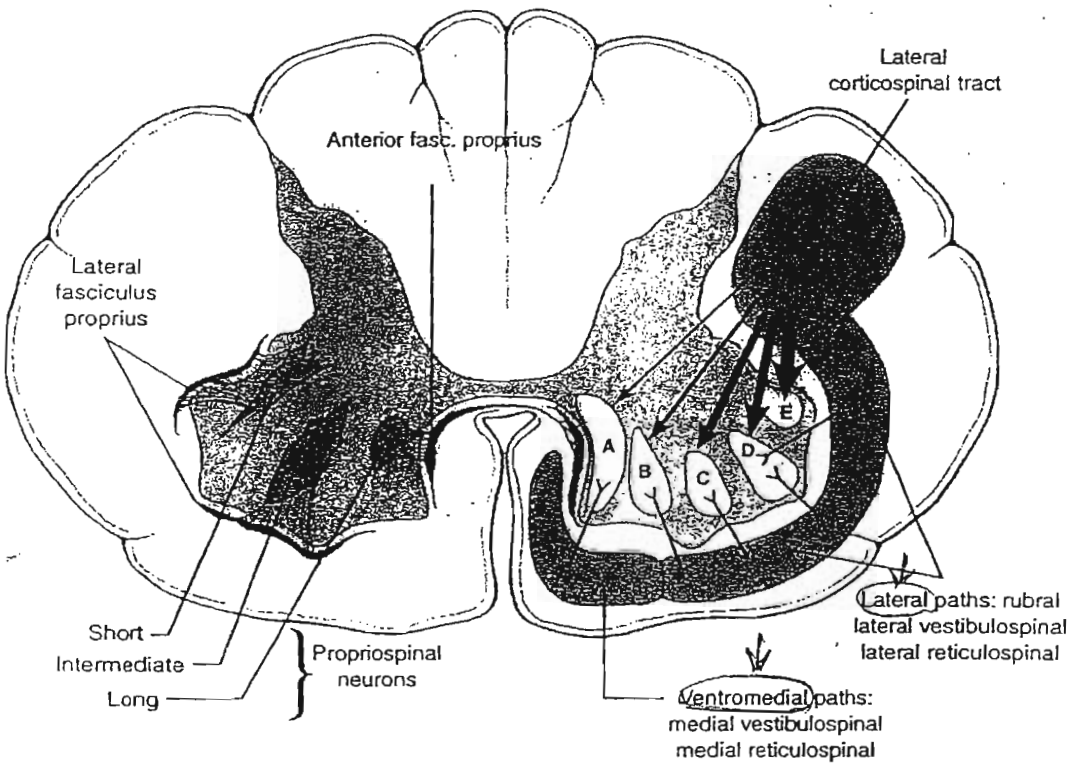

Figure 7-1 Motor organization of a spinal cord segment in the cervical enlargement (A, axial; B, shoulder; C, arm; D, forearm; E, hand; fasc, fasciculus).

system includes three groups of intraspinal neurons whose axons influence homologous areas of the spinal cord gray matter at different levels by traveling through the fasciculi proprii bordering the gray matter (Fig. 7-1):

1. The long propriospinal neurons have axons that ascend and descend in the anterior fasciculus proprius to all levels of the spinal cord. These neurons have a bilateral influence on the more medial motor neurons subserving movements of the axial muscles.
2. The intermediate propriospinal neurons have axons that extend for shorter distances in the ventral part of the lateral fasciculus proprius and influence the motor neurons that innervate the more proximal muscles of the limbs.
3. The short propriospinal neurons are limited to the cervical and lumbosacral enlargements. Their axons travel in the lateral fasciculus proprius and terminate within several segments of their origin. These propriospinal neurons influence the motor neurons that innervate the more distal muscles of the limbs.

12 E

Bustami

Propriospinal Neurons	Ascend & descend	Influence on which motor neurons?
1. Long	at all levels of the sp. cord (in anterior fasciculus proprius)	Bilateral influence on more medial motor neurons affecting movements of AXIAL MUSCLES
2. Intermediate	extend for short distance in the ventral part of the lateral fasciculus proprius	Influence motor neurons that innervate proximal muscles of limbs
3. Short	- limited to cervical & lumbosacral enlargements - extend for short distance - travel in the lateral fasciculus proprius	Influence motor neurons that innervate more distal muscles of the limbs

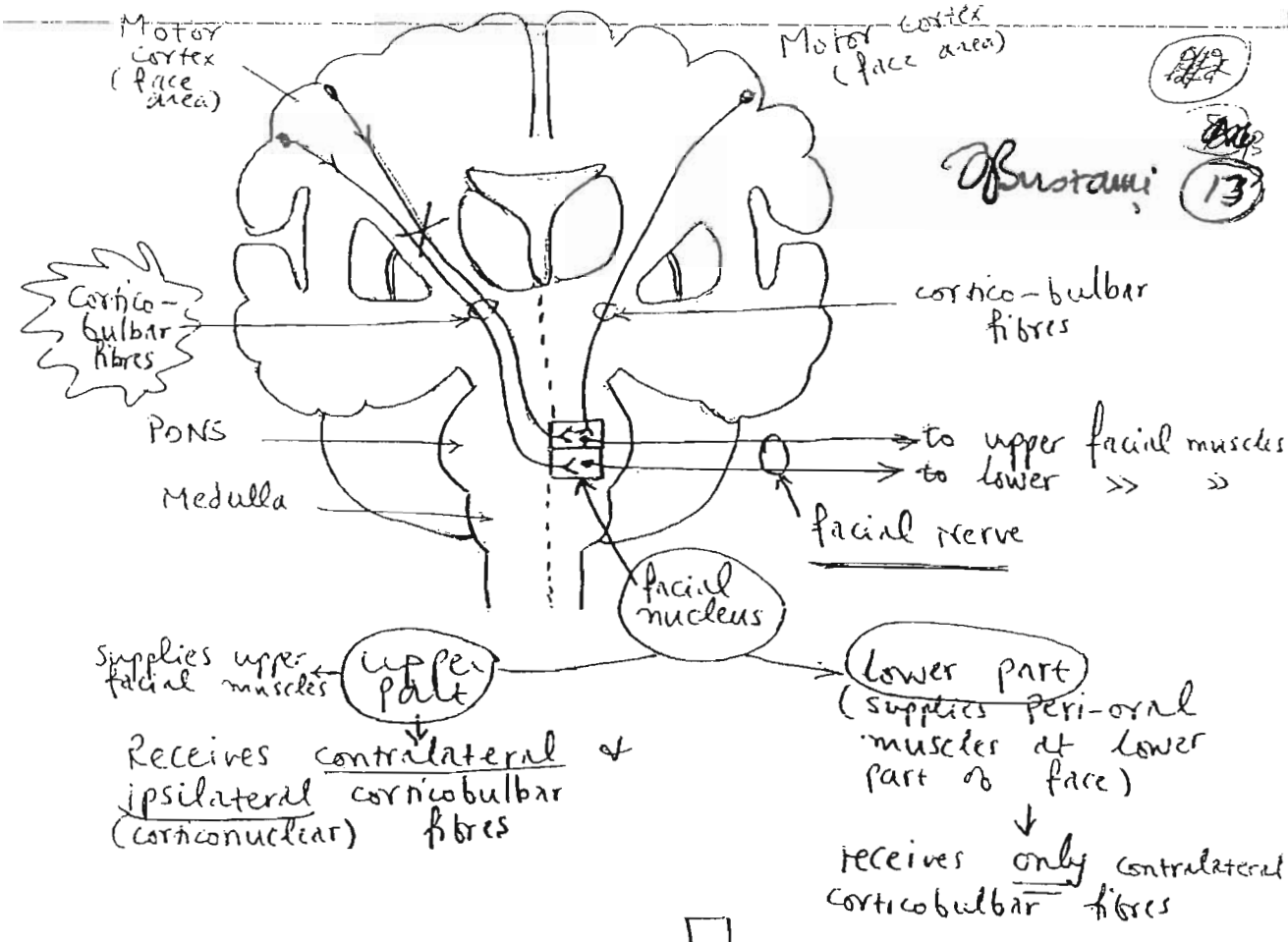

Lesion affecting the corticobulbar fibres on ONE side (usually called upper motor neuron lesion or stroke)

↓

Weakness (Paresis) of lower facial muscles (peri-oral muscles) CONTRALATERAL to the side of lesion (the upper facial muscles are much less affected ?? → Remember they receive bilateral corticobulbar fibres.

- Remember → muscles of pharynx & larynx receive bilateral corticobulbar fibres → significance ??

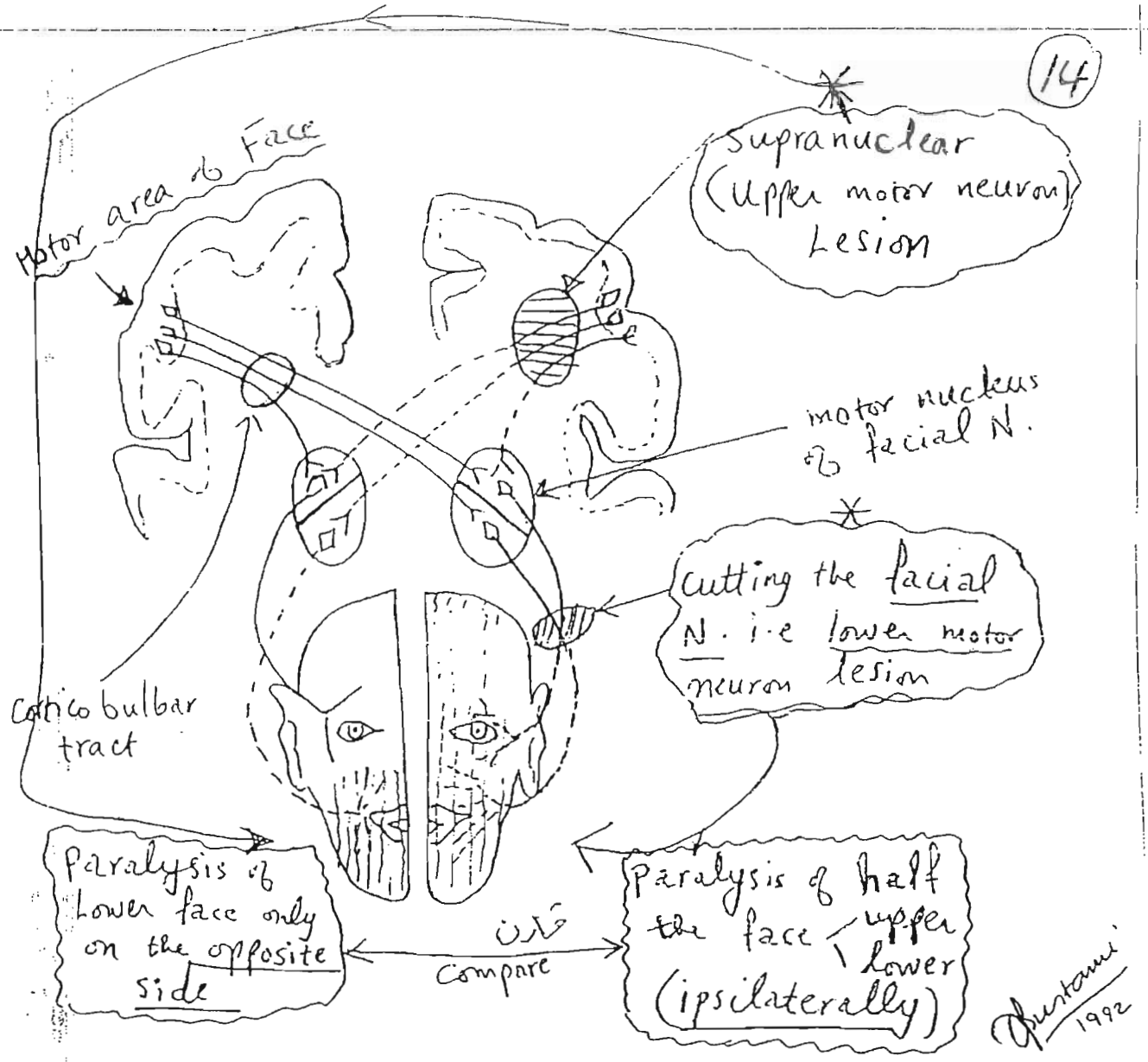

In a case of STROKE when the lesion involves the Left corticobulbar fibres → The patient will show weakness in the contralateral lower half of his face (perioral muscles) & the upper half will show less weakness WHY?

→ Look to the nucleus of facial nerve i.e (Motor nucleus) → its upper part (which supplies the upper face) receives both ipsilateral + contralateral corticobulbar fibres while its lower part (which supplies the lower face) receives ONLY contralateral corticobulbar fibres → which part of the nucleus will suffer more ???

Extrapyramidal tract

(A) RUBROSPINAL TRACT → a group of tracts

↓

Cortico-rubro-spinal tract

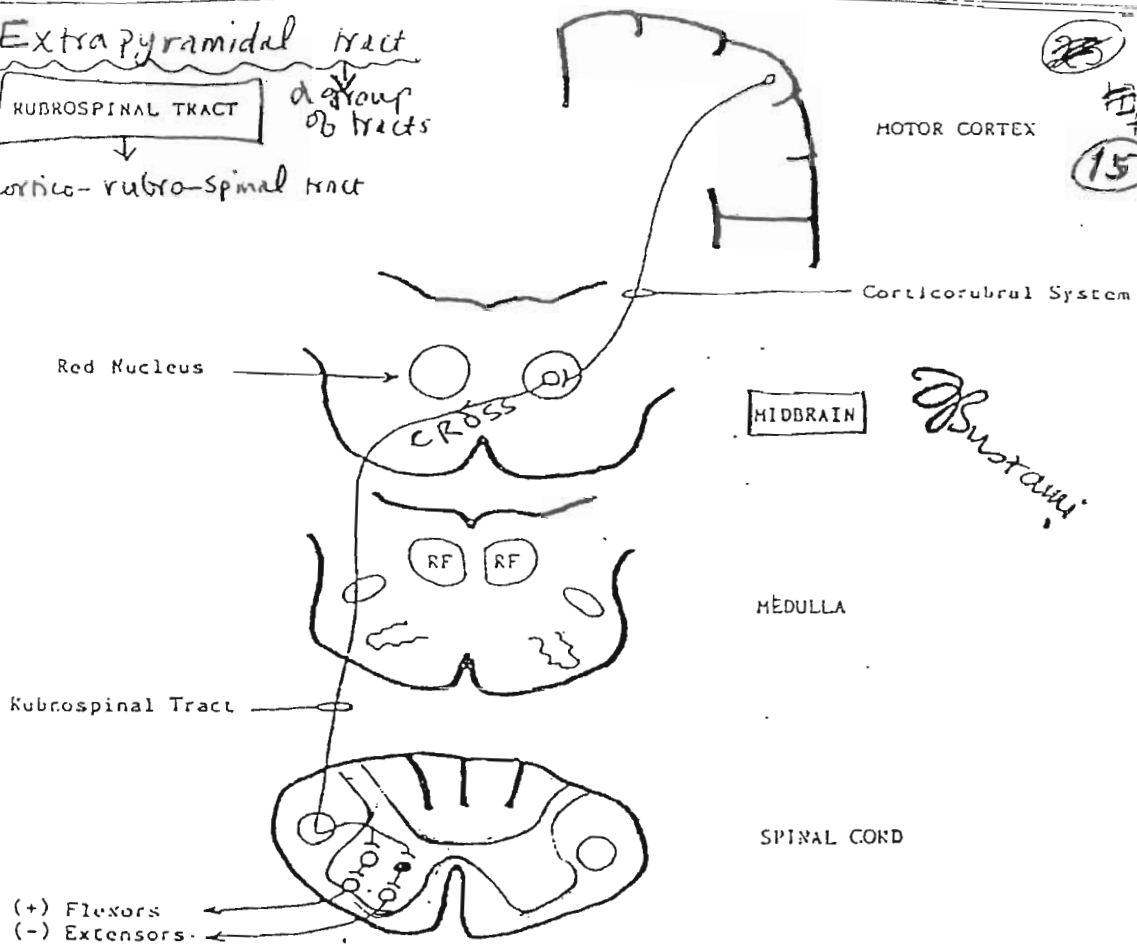

A. Rubrospinal Tract

This tract originates in the red nucleus. Fibers project to interneurons in the lateral region of the spinal cord. Stimulation of the red nucleus causes facilitation of flexors (+++) and inhibition of extensors (---).

Notice — rubrospinal tract is really cortico-rubro-spinal tract (i.e indirect corticospinal tract)

the rubrospinal tract CROSSES in the ventral tegmental decussation of midbrain & continues in the lateral funiculus of spinal cord VERY CLOSE to the LATERAL CORTICO-SPINAL tract → terminate on the same laminae as the lateral corticospinal tract i.e laminae IV to VIII

Rubrospinal ⊕ lateral corticospinal tracts form the LATERAL MOTOR SYSTEM (influence α and γ motoneurons present at the LATERAL part of ventral horn which supply DISTAL FLEXOR MUSCLES)

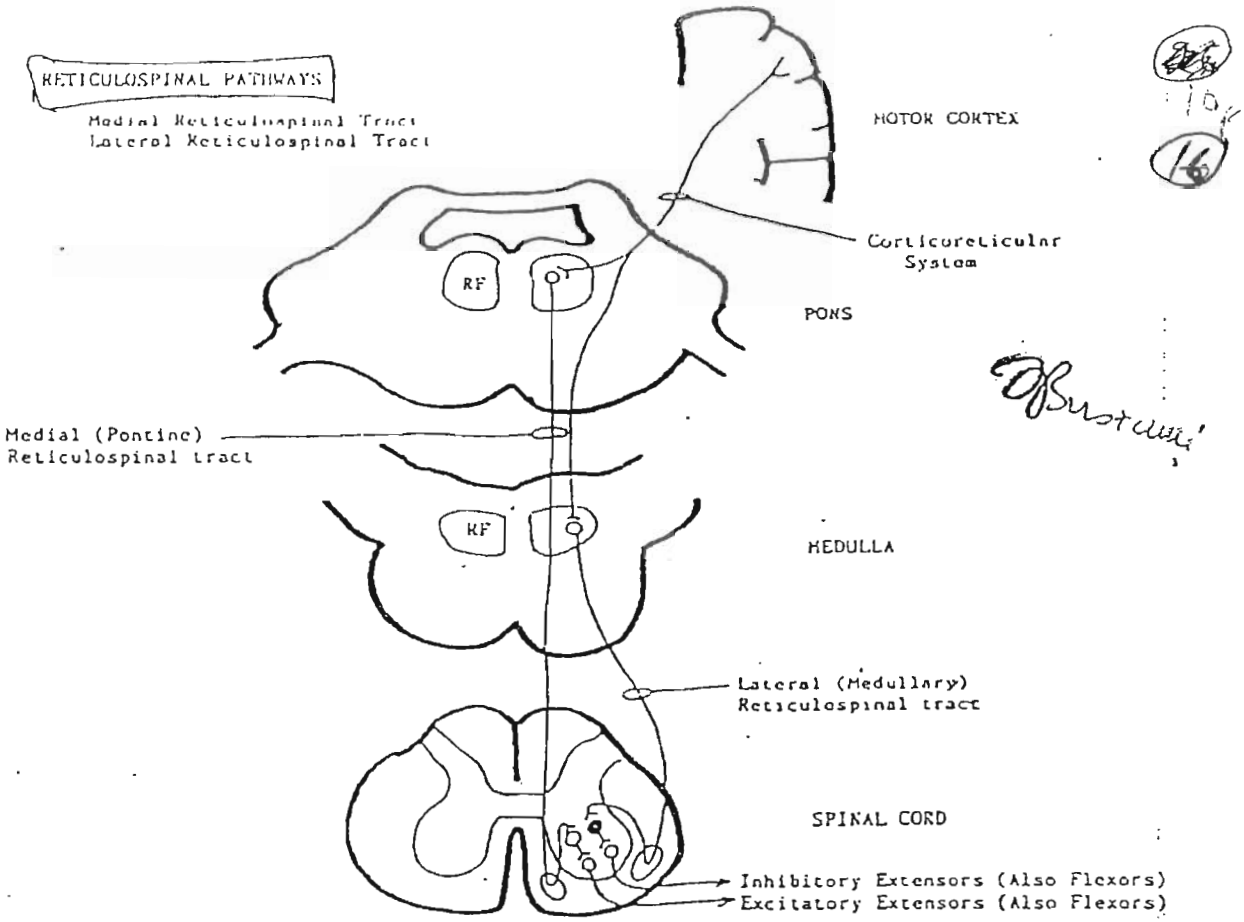

B. Pontine (medial) Reticulospinal Tract

This tract originates from cells in the nucleus pontis caudalis and nucleus reticularis pontis oralis located in the medial two thirds of the pons (Pontine reticular formation). Fibers project to the ventromedial spinal cord where they have a general excitatory effect* on both extensor and flexor motoneurons, although maximal excitation is on the extensors.

C. Medullary (lateral) Reticulospinal Tract

Cells originate in the medullary reticular formation (nucleus reticularis gigantocellularis) and terminate on spinal cord interneurons in the intermediate gray. The medullary reticulospinal tract has the opposite effect of the Pontine reticulospinal tract, in that it has a general inhibitory effect* on motoneurons with a stronger inhibition on extensors.

Notice → both Reticulospinal tracts form part of the MEDIAL MOTOR SYSTEM → they synapse with α and γ motor neurons present at the MEDIAL part of ventral horn which supply Axial (trunk) & Proximal muscles (of limbs)

→ the reticulospinal tracts are the principle supraspinal pathways that control POSTURE such as sitting & standing and automatic movements such as walking & running

both reticulosp. tracts synapse on (inter-neurons) within laminae VII & VIII

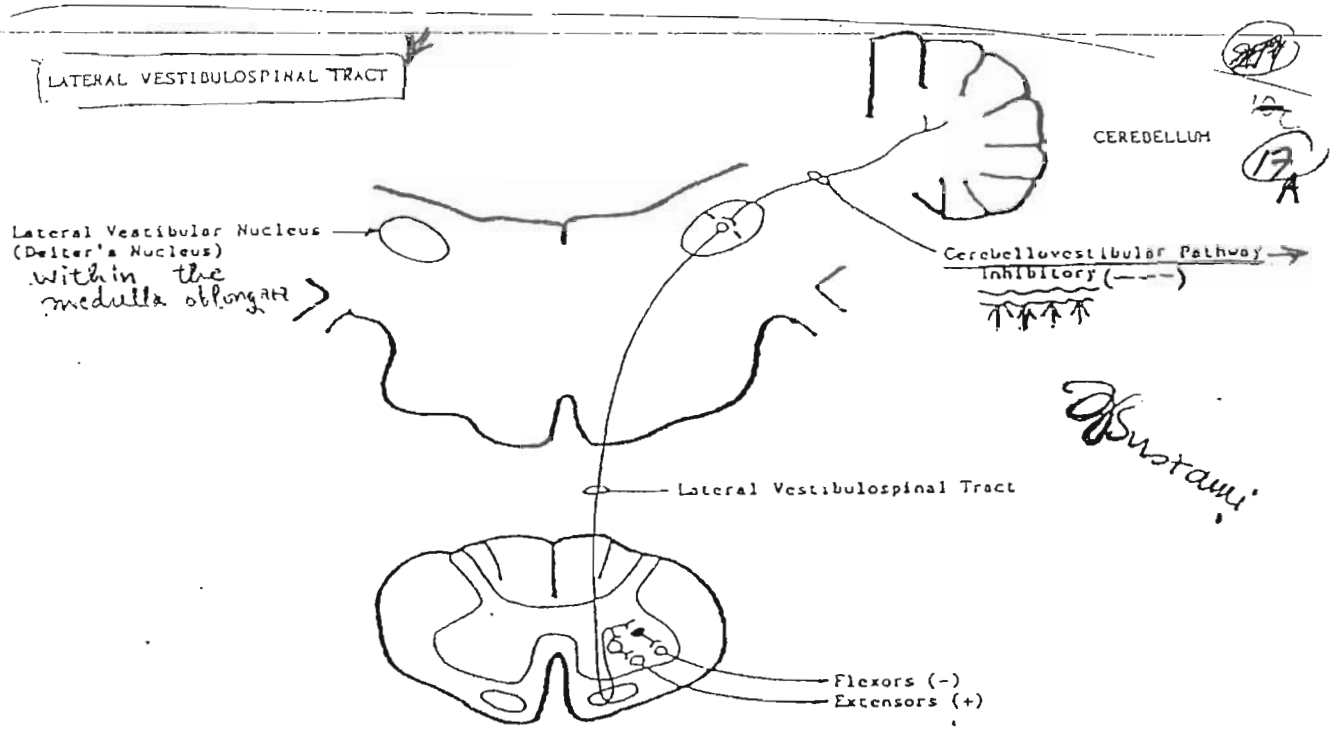

D. Lateral Vestibulospinal Tract

Cells originate in the lateral vestibular nucleus (Deiters' nucleus) and project to ipsilateral motoneurons and interneurons. Stimulation of cells in Deiters' nucleus produces a powerful excitation of extensors and inhibition of flexors It plays an important role in the control of antigravity muscles and the maintenance of posture.

Notice → Both lateral vestibulospinal tract (+) Pontine (medial) reticulospinal tract are Excitatory to EXTENSOR muscles while the medullary (lateral) reticulospinal tract is inhibitory to extensors

→ Cells in the lateral vestibular nucleus (Deiter's nucleus) are normally inhibited by projections from the cerebellum → Removal of cerebellum (in experimental animals) → increases the activity of these cells → increase tone in extensor muscles

E. Medial vestibulospinal tract: descends as a component of medial longitudinal fasciculus (MLF) and is excitatory to flexor motor neurons

Notice → Both vestibulospinal tracts (lateral, medial) form part of the MEDIAL MOTOR SYSTEM

F. Tectospinal Tract

Cells of origin are in the superior colliculus. Fibers project to the cervical spinal cord where they control neck muscles involved in head movement.

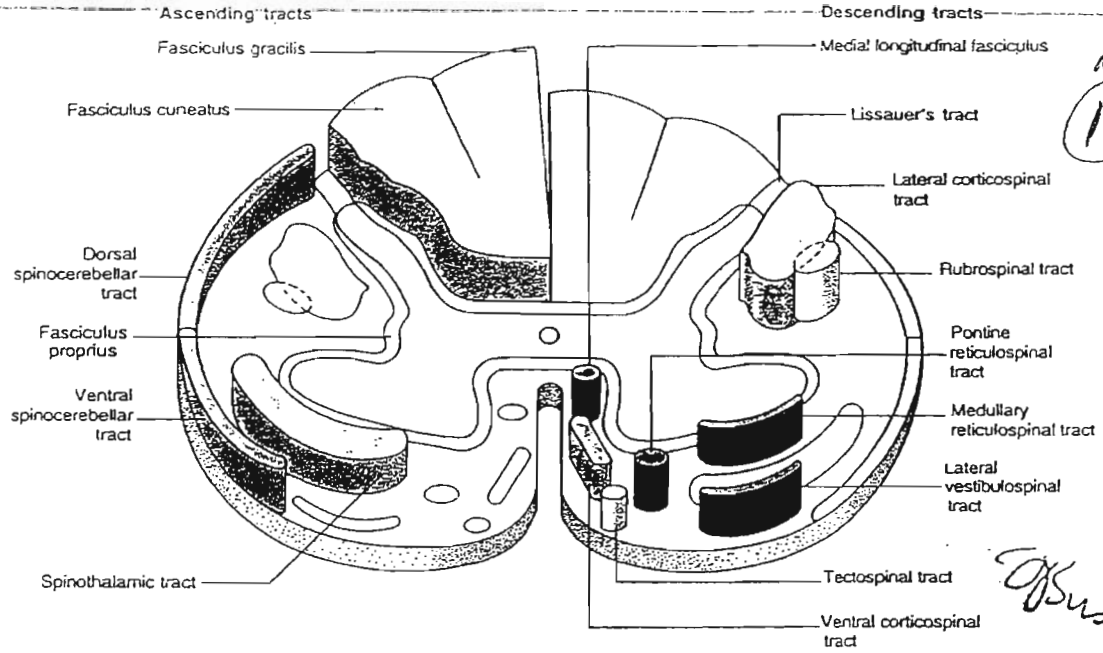

17/B

Fig. 5.13 **Ascending and descending tracts of the spinal cord.**
All ascending and descending tracts are present bilaterally. In this figure, ascending tracts are emphasised on the left side and descending tracts are emphasised on the right side. In addition, the locations of Lissauer's tract and the fasciculus proprius (which contain both ascending and descending fibres) are shown.

Descending motor Pathways → classified according to their site of termination in the spinal cord

Lateral System

Ends on α-motoneurons in the lateral part of lamina IX OR on the interneurons that project to these neurons.

↓

Controls muscles of the distal and part of the proximal limbs

↓

These muscles subserve fine movements used in manipulation and other precise actions especially of the digits

↓

Includes 2 pathways from the brain to the spinal cord → the lateral corticospinal tract and the rubrospinal tract

In addition, the part of the corticobulbar tract that controls the lower face and tongue can be considered part of the lateral system.

Medial System

Ends on motoneurons in the medial part of lamina IX or on interneurons that project to these neurons

↓

controls axial and girdle muscles as well as most cranial nerve nuclei

↓

The muscles of the body regulated by the medial system contribute to Posture, Balance & locomotion. Those in the head are involved in such activities as closure of the eyelids, chewing, swallowing & phonation

↓

includes ventral corticospinal tract, Much of the corticobulbar tract & several pathways descending from brainstem

tectospinal
lat. & med. vestibulospinal
& pontine & medullary reticulospinal

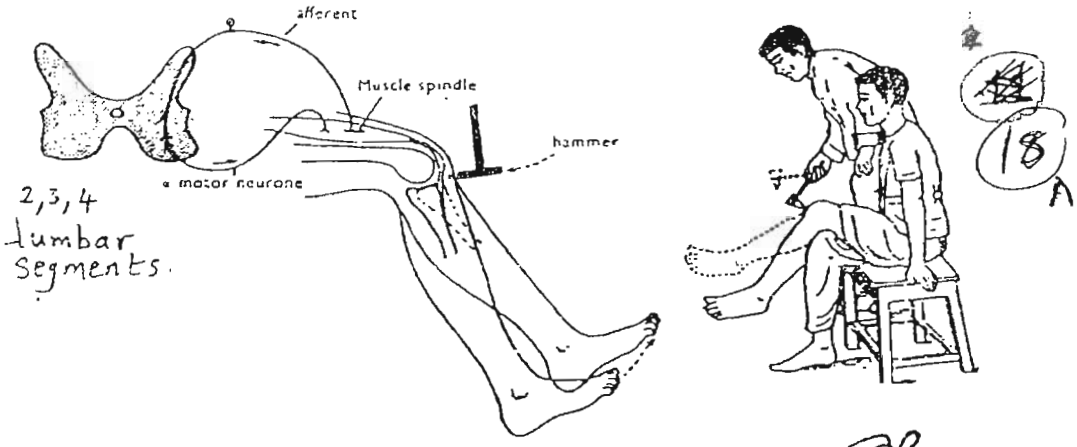

Figure 33 : The knee Jerk.

THE STRETCH REFLEX AND SKELETAL MUSCLE TONE

What is the stretch reflex ? :

When a skeletal muscle is passively stretched, it contracts reflexly. This response of a skeletal muscle to stretch, is known as the stretch reflex.

Nervous pathway of the stretch reflex :

The stretch reflex is the **only monosynaptic reflex** in the body. The **stimulus** that starts this reflex is passive stretching of skeletal muscles. This results in stimulation of specialised **stretch** receptors located in the fleshy part of the muscles known as the **muscle spindles** (see below), which discharge impulses in **afferent fibres.** These are thick myelinated, rapidly conducting (Ia afferent) nerve fibres, which end **directly** (i.e. without intervening interneurons) on large A.H.C. (= the **alpha motor neurons)** that supply the stretched muscle. These neurons constitute the **centre of the reflex,** from which **efferent fibres arise.** These, like afferent fibres, are thick myelinated (about 16 microns in diameter), rapidly conducting (group A alpha) nerve fibres that supply the skeletal muscle resulting in its contraction (Ia afferent)

THE MUSCLE SPINDLES (intrafusal fibres)

Structure :

These are capsulated fusiform stretch receptors present in the fleshy parts of skeletal muscles ~~parallel to their fibres.~~ Each spindle is few millimeters in length, and is formed of 4-10 small muscle fibres called **intrafusal fibres** which are enclosed in a connective tissue capsule. The spindles are attached either to the tendon of the muscle or to the sides of ordinary muscle fibres, which are called the **extrafusal fibres.** The intrafusal fibres are smaller and less developed than the extrafusal fibres, and each consists of a **central non-contractile part called the receptor area,** and a **peripheral contractile part.**

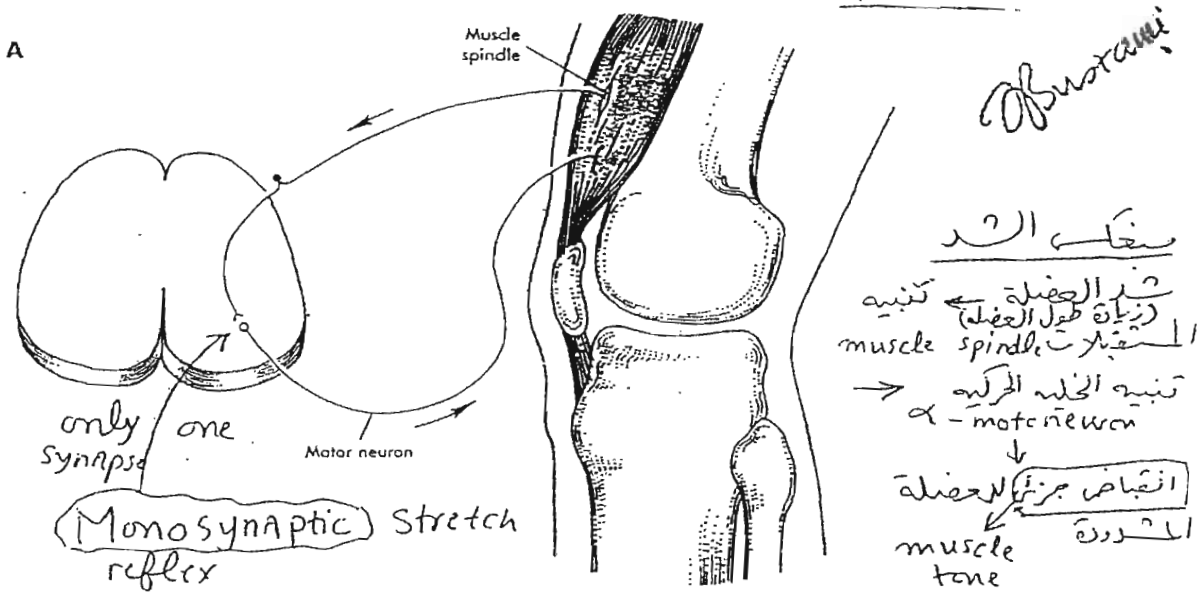

FIGURE 12-7
A The stretch reflex arc runs from muscle spindle stretch receptors in the stretched muscle to motor neurons that excite the muscle.
B Reciprocal inhibition in the stretch reflex involves connections among afferent neurons, interneurons, and motor neurons that simultaneously excite motor neurons innervating the stretched muscle (and its synergists, not shown) and inhibit ongoing activity in motor neurons innervating the muscles' antagonists.

Summary

منعكس الشد

شد العضلة (زيادة طول العضلة) ← تنبيه المستقبلات muscle spindle

→ تنبيه الخلية الحركية α-motoneuron

↓

انقباض جزئي للعضلة المشدودة

muscle tone

monosynaptic reflex شد العضلة يؤدي الى انقباض الجزئي

وإرتخاء العضلة المضادة (disynaptic reflex)

There are 2 types of intrafusal muscle fibres : (19)

1. **Nuclear bag fibres :** These have many nuclei, which are grouped together forming a dilated bag in the central part of the receptor area.

2. **Nuclear chain fibres :** These have a smaller number of nuclei, forming a chain throughout the receptor area. These fibres are thinner and shorter than the nuclear bag fibres, and their ends are connected to the sides of these fibres.

Innervation :

(1) **Afferent fibres :**

These arise from 2 types of sensory nerve endings in the muscle spindles, which are stimulated by stretch of the central receptor area :

a) **Primary or annulospiral endings :** These encircle the central parts of the receptor areas of both the nuclear bag and nuclear chain

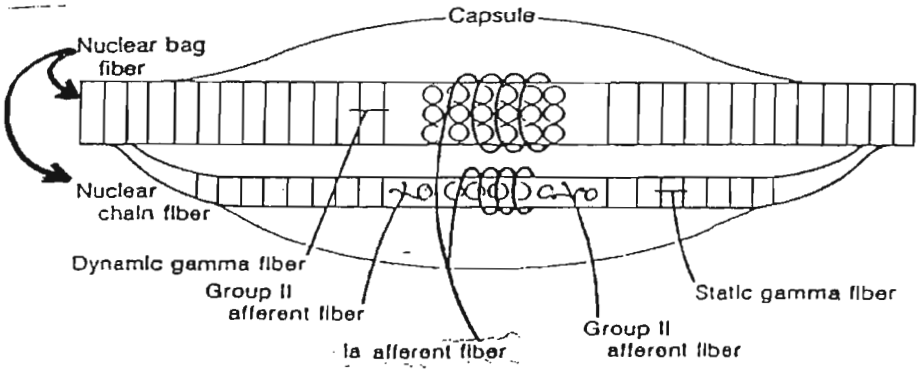

Figure 1-52. Diagram of an intrafusal muscle fiber, showing its nuclear bag and nuclear chain fibers. The afferent innervation (Ia and II fibers) and efferent innervation (gamma dynamic and gamma static fibers) of the intrafusal muscle fiber also are illustrated.

intrafusal fibres, and give rise to thick (about 16 microns in diameter) myelinated group A (rapidly-conducting) afferent fibres.

b) **Secondary or flower spray endings :** These lie on both sides of the primary endings and encircle the peripheral parts of the receptor areas of **only the nuclear chain fibres.** They give rise to thinner (about 8 microns in diameter) myelinated group B (less rapidly conducting) afferent fibres.

(2) **Efferent fibres : THE GAMMA EFFERENT FIBRES :**

The peripheral contractile parts of the intrafusal fibres of the muscle spindles are supplied by thin motor nerves about 4 microns in diameter called gamma efferent fibres. These nerves are the axons of small A.H.C. called the **gamma motor neurons,** and constitute about 30% of the efferent nerves that leave the spinal cord in the ventral roots.

There are 2 types of these gamma efferent fibres :

a) **Dynamic fibres (gamma-d fibres)** : These supply the nuclear bag intrafusal fibres.

b) **Static fibres (gamma-s fibres)** : These supply the nuclear chain intrafusal fibres.

When the gamma efferent fibres are stimulated, the peripheral parts of the intrafusal fibres contract, leading to stretch of the central

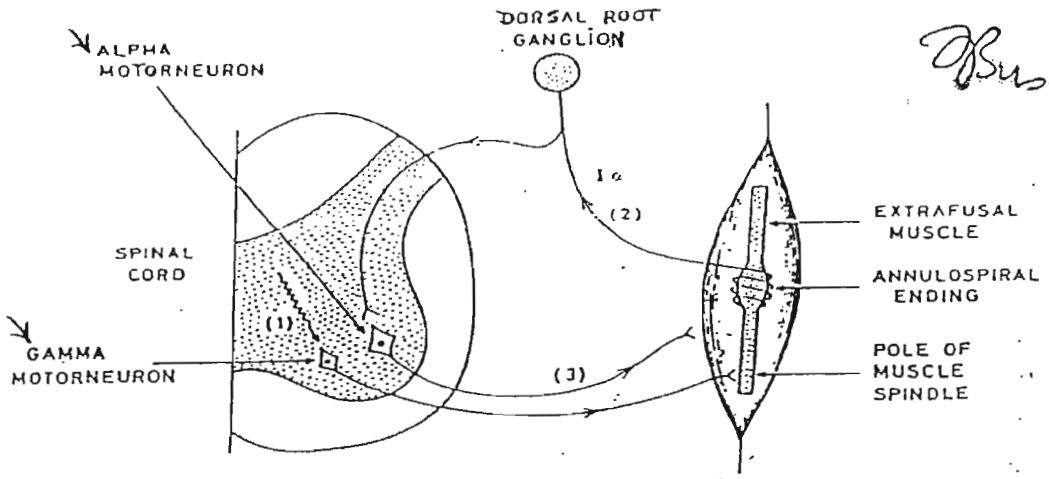

Figure 18.2. Schematic diagram of the components of the gamma loop.

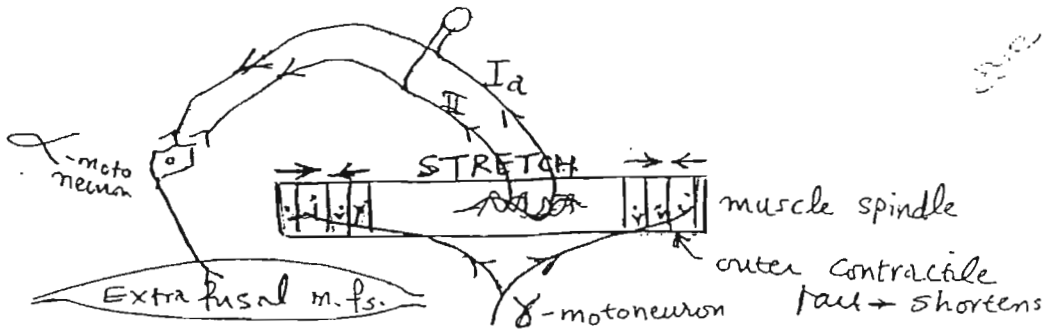

receptor area, thus the primary and secondary endings are stimulated and discharge impulses in their afferent nerves, which produce reflex contraction of the extrafusal muscle fibres.

Methods of stimulating the muscle spindles :

1) Stretching of the whole muscle.

2) Stimulation of the gamma efferent fibres (as described above).

The muscle spindles are **silent** i.e. not stimulated during active contraction of the muscles (which releases the stretch of the spindles), provided they are not stretched by gamma efferent fibre activity. On the other hand, they are **maximally stimulated** when the muscle is stretched and the intrafusal muscle fibres are contracted through stimulation of the gamma efferent fibres.

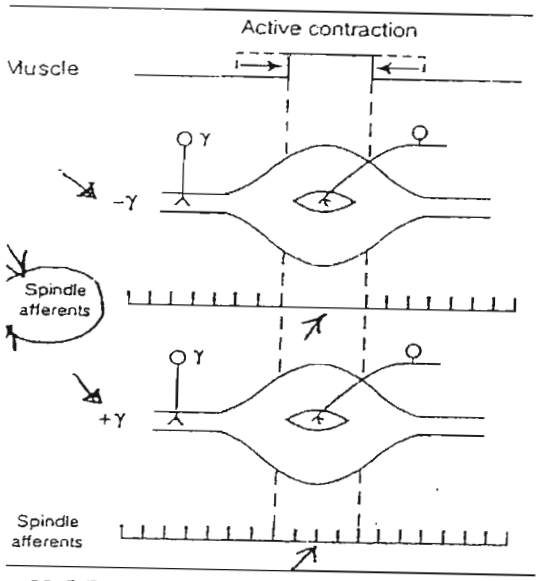

g. 11-5. Response of muscle afferents to muscle con-
ction without and with activation of gamma motor neu-
ns. During active contraction, discharge in afferent
ers ceases in the absence of gamma activation because
: spindle becomes unloaded as extrafusal muscles
orten. Activation of gamma motor neurons prevents un-
ding of the spindle, and the discharge in the afferents
m the spindle is maintained.

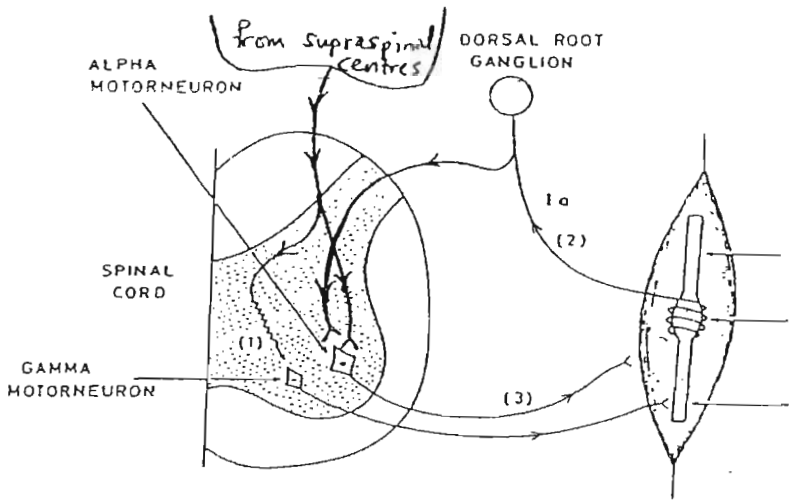

21

The alpha motor neurons that innervate the extrafusal muscle fibres are stimulated by 2 ways :

1. Directly by descending impulses from supraspinal centres

2. Indirectly (reflexly) by afferent impulses discharged from the muscle spindles along Ia & II fibres

Alpha-gamma linkage (coactivation of alpha and gamma motor neurons) :

It seems that during active muscle contraction, the muscle spindles are not completely silent. There is evidence that impulses from supraspinal centres stimulate both the alpha and gamma motor neurons, leading to contraction of both the extrafusal and intrafusal muscle fibres at the same time. This has been called the **alpha-gamma linkage,** through which the muscle spindles continue discharging throughout contraction, thus remaining capable of reflexly adjusting the alpha motor neuron discharge, in spite of the change that occurs in the length of the muscle (due to contraction).

Oversensitivity of the gamma system may lead to hypertonia

Activation of gamma neurons alone can produce a reflex contraction of the muscle. Since gamma motor neurons are smaller than alpha motor neurons, they have a lower threshold for excitability than the alpha motor neurons, are more easily excited, and have higher tonic discharge rates. Therefore, tonic discharge of the gamma motor neurons may be responsible in large part for maintenance of muscle tone. Overactivity of the gamma system may lead to hypertonia.

Function of the muscle spindles :

The muscle spindles and their reflex connections constitute a feed-back mechanism which maintains the length of muscles constant e.g. if a muscle is stretched, its spindles discharge leading to reflex contraction, so the muscle will be shortened. On the other hand, if the muscle is shortened, the discharge from its spindles decreases helping its relaxation, so the muscle will be lengthened.

Response of muscle spindles to stretch :

When the muscle spindles are stretched, both the primary (annulospiral) and secondary (flower spray) endings will be stimulated, but the pattern of response of each is different as follows :

• FIGURE 6–4 Tonic and Phasic Receptors (a) Tonic receptor. This receptor type does not adapt at all or adapts slowly to a sustained stimulus and thus provides continuous information about the stimulus. (b) Phasic receptor. This receptor type adapts rapidly to a sustained stimulus and frequently exhibits an off response when the stimulus is removed. Thus, the receptor signals changes in stimulus intensity rather than relaying status quo information.

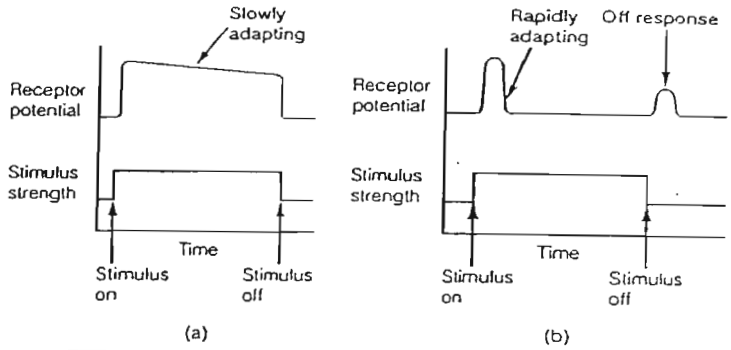

1) Dynamic response of the primary endings :

The primary endings are rapidly-adapting receptors, so when the muscle spindle is stretched, the rate of discharge of impulses from these receptors initially increases, but it rapidly declines to the original level when the stretching force is maintained and the length of the muscle stops to increase.

Ia

Since the primary endings are stimulated only during the stretching movement (i.e. during actual increase in the length of the muscle), their response has been called the **dynamic response,** which informs the nervous system about the rate of change in the length of the stretched muscle.

This dynamic response is the result of stretching of the **nuclear bag** intrafusal fibres, from which the primary endings arise. Therefore, this response can be increased by stimulating the gmma-d (dynamic) fibres, which supply the nuclear bag fibres .

2) Static response of the secondary endings :

The secondary endings are slowly-adapting (= tonic) receptors, so when the muscle spindle is stretched, the number of impulses discharged from these endings increases in proportion to the degree of stretch. But when the stretching force is maintained, these receptors (unlike

the primary endings) continue to discharge at a fast rate for a long period of time, as long as the muscle stretch is maintained. Therefore, this response has been called the **static response,** which continuously informs the nervous system about the length of the stretched muscle.

This static response is the result of stretching of the **nuclear chain intrafusal** fibres, from which the secondary endings arise. Therefore,

this response can be increased by stimulating the gamma-s (static) fibres, which supply the nuclear chain fibres (figure 30).

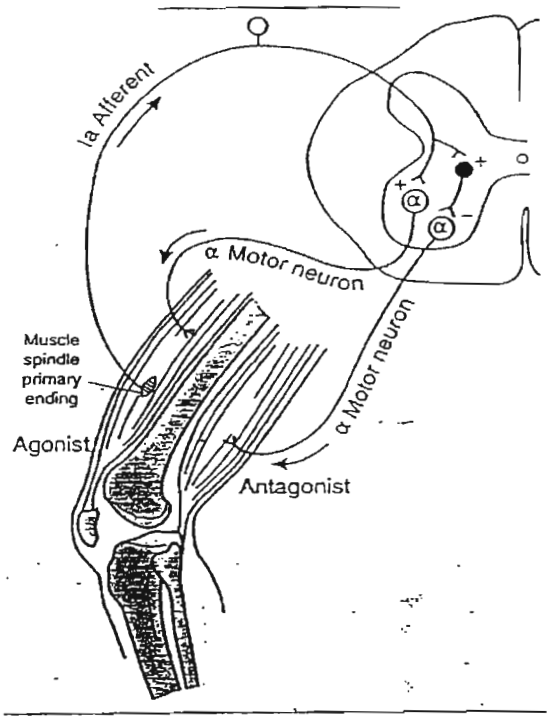

Fig. 11-4. The elements of the monosynaptic stretch reflex, including reciprocal inhibition.

TYPES OF STRETCH REFLEX :

Depending on the dynamic and static responses of the muscle spindles to stretch (see above), the stretch reflex **has dynamic and static components,** thus it can be divided into the following 2 types :

(1) Dynamic stretch reflex :

This occurs when a muscle **is suddenly stretched.** This increases the discharge **from the primary endings** which leads to reflex contraction of the stretched muscle. However, such discharge of impulses rapidly declines (due to adaptation) leading to rapid relaxation of the muscle. Therefore, the dynamic stretch reflex leads to both rapid contraction and rapid relaxation of the muscle, and this is the basis of the **tendon jerks** (see later).

(2) Static stretch reflex :

This occurs on **maintained stretch** of the muscle (during which the dynamic response disappears). This increases the discharge from the **secondary endings** which leads to reflex contraction of the stretched muscle. Such contraction continues as long as the muscle is stretched (due to slow adaptation of the secondary endings). Therefore, the static stretch reflex leads to continuous muscle contraction, as long as its stretch is maintained, and this is the basis of the **skeletal muscle tone** (see below).

24

Osurami

SKELETAL MUSCLE TONE :

Definition : It is a continuous reflex sub-tetanic (i.e. partial) contraction of skeletal muscles during rest. It is produced through the stretch reflex (as described below), so it is a **neurogenic** property.

Plain muscles also have tone, but in this case, it is due to a **myogenic** property i.e. it is produced as a result of inherent properties in the plain muscles themselves, and not as a result of nervous reflexes.

Mechanism :

During rest, the skeletal muscles are usually **shorter** than the distance between their origin and insertion, so they are continuously subjected to stretch. This stimulates the muscle spindles which send impulses, mostly from the **secondary endings** (see above), resulting in reflex partial contraction of these muscles. Since during rest this partial contraction is a continuous process, it has been called the **muscle tone**.

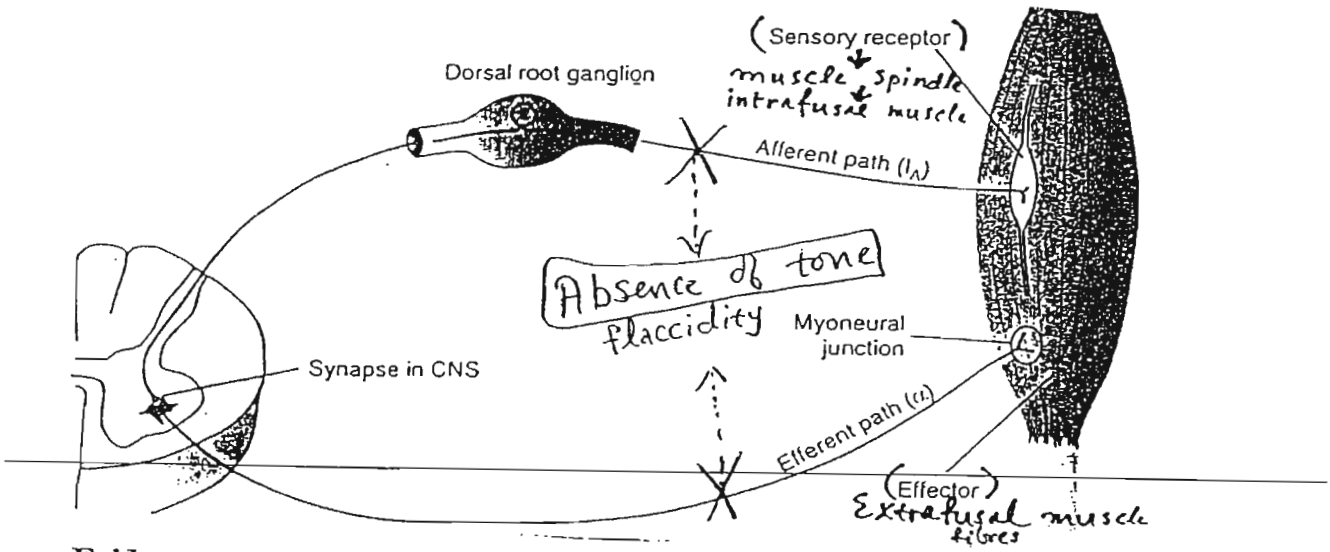

Evidence of the reflex nature of muscle tone :

Cutting the afferent or efferent nerves of a certain muscle, leads to **atonia** (= loss of tone) in this muscle, which will accordingly become **flaccid** i.e. completely relaxed.

Distribution of muscle tone :

Tone is present in all skeletal muscles of the body, but it is more marked in the **antigravity muscles,** because they are the most stretched muscles in the body, by the effect of gravity. These muscles are the extensors of the lower limbs, flexors of the upper limb, extensors of the back and neck, elevators of the lower jaw (the mandible), and the anterior abdominal wall muscles.

Functions of the muscle tone :

1. It maintains the erect (standing) posture against the force of gravity.

2. It helps both venous return and lymph flow from the lower parts of the body against the effect of gravity. This effect is known as the **muscle pump** (refer to circulation).

Inverse Myotatic Reflex (Fig. 18.3)

Severe tension in a muscle produced by stretch or contraction will stimulate nerve endings in its tendon (Golgi tendon organ). Impulses from Golgi tendon organs travel via Ib nerve fibers. In the spinal cord, they project upon inhibitory neurons, which in turn will inhibit alpha motor neurons supplying the muscle under tension (homonymous motor

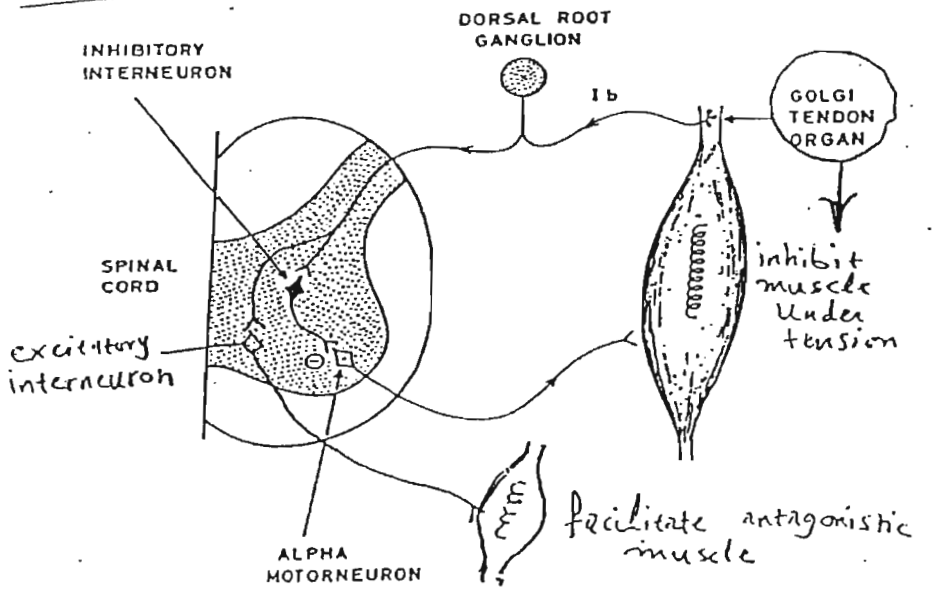

Figure 18.3. Schematic diagram of the components of the inverse myotatic reflex.

neurons). The result is relaxation of the muscle (lengthening reaction, autogenic inhibition). At the same time, the Ib activity will facilitate motor neurons that supply the antagonistic muscle. This is a protective mechanism to prevent tearing of the muscle under great tension. This reflex also underlies the mechanism of the "clasp knife" phenomenon noted in spastic muscles. In such situations, passive stretching of the spastic muscle will be met with great resistance up to a point, after which the muscle gives way suddenly. The phenomenon has been termed "clasp knife" by Sherrington because of its similarity to the action of a jack-knife

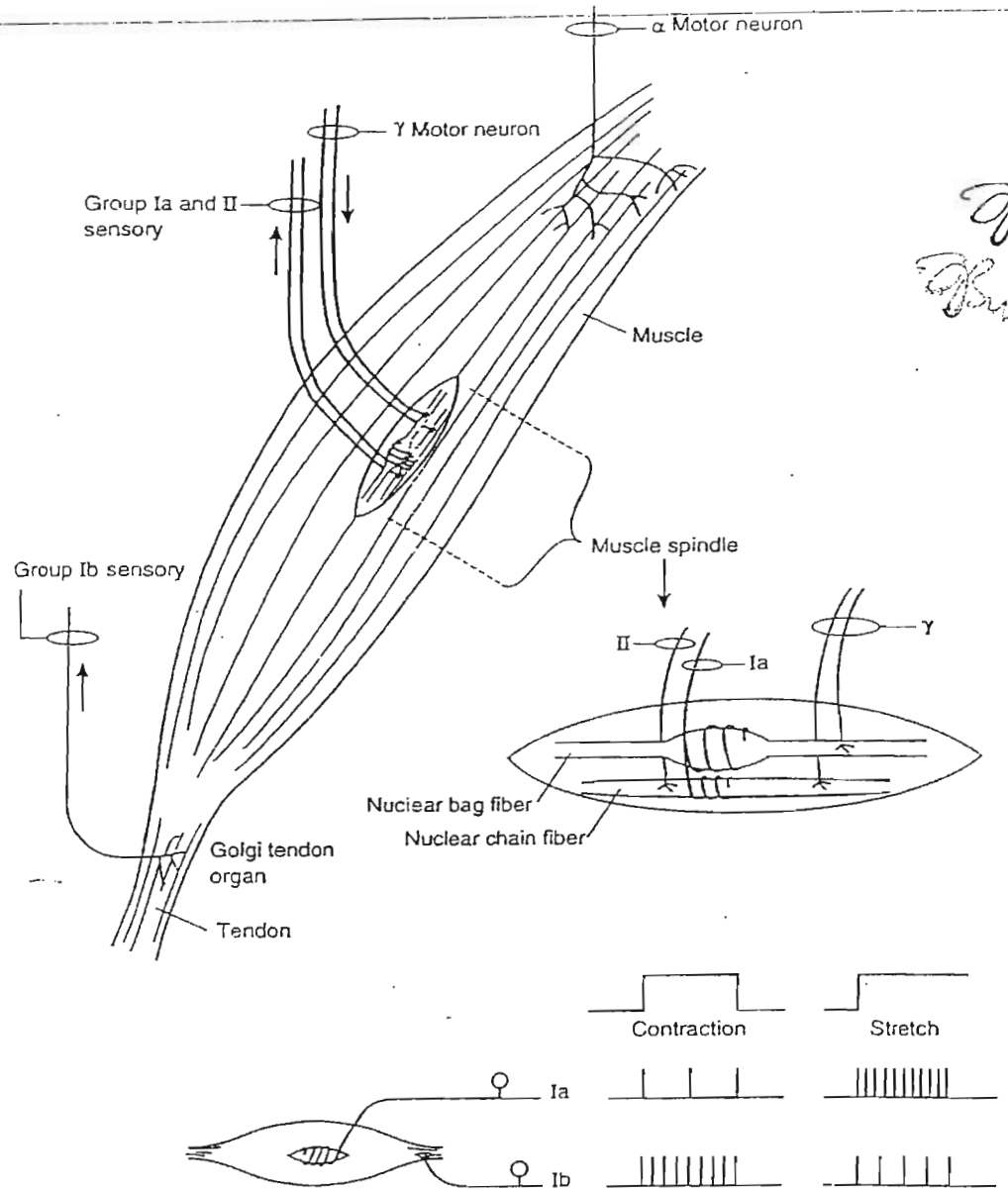

Fig. 11-3. Localization of muscle spindles and Golgi tendon organs in relation to extrafusal muscles. Enlarged view of the muscle spindle illustrates the two types of intrafusal muscle fibers and their innervation. Responses of muscle spindle and Golgi tendon organ to muscle stretch and contraction are illustrated at the lower right part of the figure.

Make use of this diagram to explain one of the upper motor neuron lesion signs → CLONUS ?

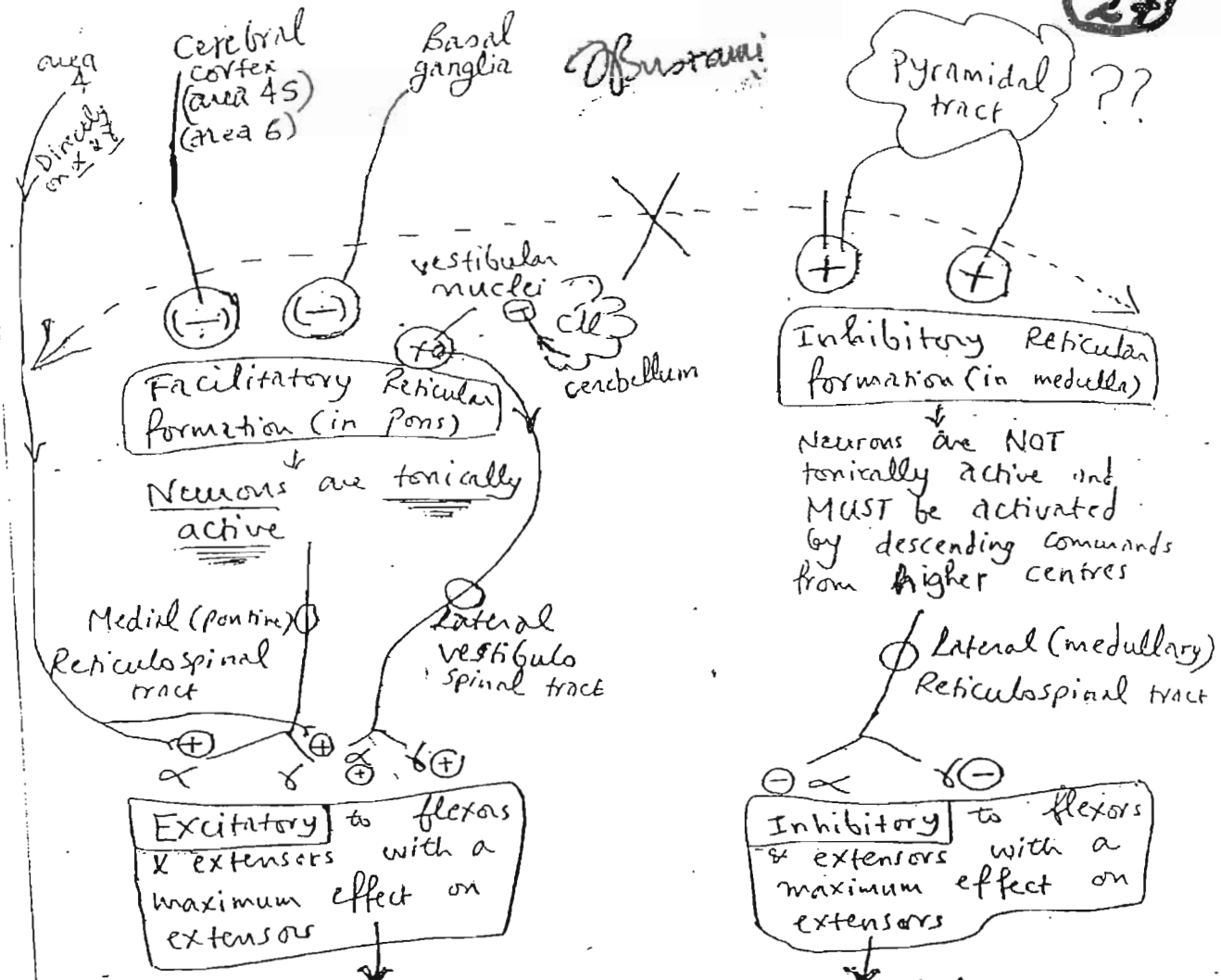

In the normal state there is a balance between the facilitatory and inhibitory descending influences ensuring a proper activation of stretch reflex → proper activation of antigravity muscles and regulation of postural tone

Experimental decerebrate rigidity is produced by transection of the brainstem above vestibular nuclei at the boundary between midbrain and Pons

Release of brainstem mechanisms from control by higher centres → excessive contraction of antigravity muscles (spasticity)

Is it alpha or gamma rigidity (spasticity) ??

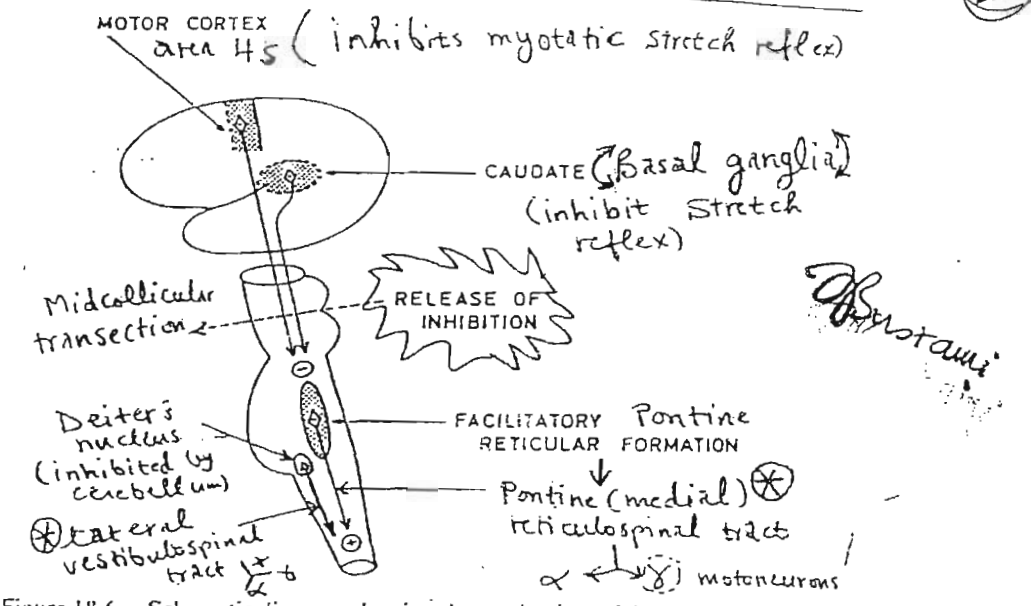

Figure 18.6. Schematic diagram showing the mechanism of decerebrate rigidity.

In the normal state there is a balance between facilitatory (medial reticulospinal tract & lateral vestibulospinal tract) and inhibitory (lateral or medullary reticulospinal tract) descending tracts ⇒ Proper activation of γ-motoneuron ⇒ Proper activation of antigravity muscles and regulation of postural tone by the myotatic reflex

↓

The release of brainstem mechanisms from control by the higher centres results in increased γ efferent discharge → hyperactive stretch reflex → excessive contraction of antigravity muscles producing various forms of extensor rigidity & spasticity, a condition that can be experimentally demonstrated in the decerebrate animal

B. Decerebrate Rigidity (Mid-Collicular Transection)

Two brainstem centers that are very important to the maintenance of muscle tone in antigravity muscles (primarily extensors) are the pontine reticular formation (medial reticulospinal tract), and Deiter's nucleus (lateral vestibulospinal tract). Both centers have an excitatory influence on extensors. Stimulation of cells in the pontine reticular formation has a very powerful excitatory effect on extensors, but its activity is normally modulated *(inhibited) by central (cortical) projections. If the Brain Stem is cut above the level of the pontine reticular formation (mid collicular), the inhibitory influence is removed and there is an exaggerated activation of muscle tone in extensors (antigravity muscles). This produces a rigid posture which is referred to as decerebrate rigidity. In humans arms and legs are extended, back is arched, head dorsiflexed, and feet ventroflexed (curling of toes lifts against gravity). This stiff posture does not permit joints to bend and the body is capable of standing upright. This is very different from spinal transection, where extensor muscle tone is abolished and the body becomes limp.

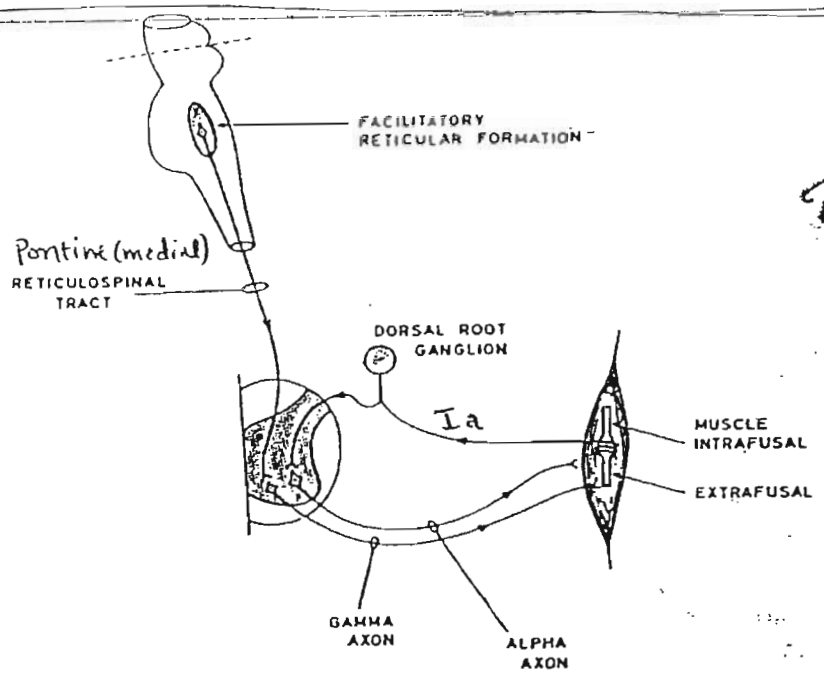

29

D Bustami

1. Gamma rigidity

Cutting the dorsal roots abolishes decerebrate rigidity. Cutting the dorsal roots interrupts Ia spindle afferents that act to excite homonymous motoneurons via the myotatic stretch reflex. Since Ia afferents signal spindle activity, this demonstrates that the decerebrate rigidity was primarily due to the hypersensitivity of muscle spindles resulting from descending excitation of gamma motoneurons. Removal of the Ia spindle afferents abolishes the rigidity. Therefore, decerebrate rigidity is considered primarily a gamma rigidity.

2. Alpha rigidity

A selective increase in alpha motoneuron activity can produce what is referred to as alpha rigidity. This can be demonstrated after reversing decerebrate rigidity caused by gamma excitability (cutting the dorsal roots) and increasing the excitation of alpha motoneurons. Since cells in the lateral vestibular nucleus (Deiters' nucleus) are normally inhibited by projections from the cerebellum, removal of cerebellar projections increases the activity of these cells. The result is an increase in descending excitation of extensors and rigidity is restored by alpha motoneurons (gammas may fire too, but they are ineffective since the dorsal roots have been cut).

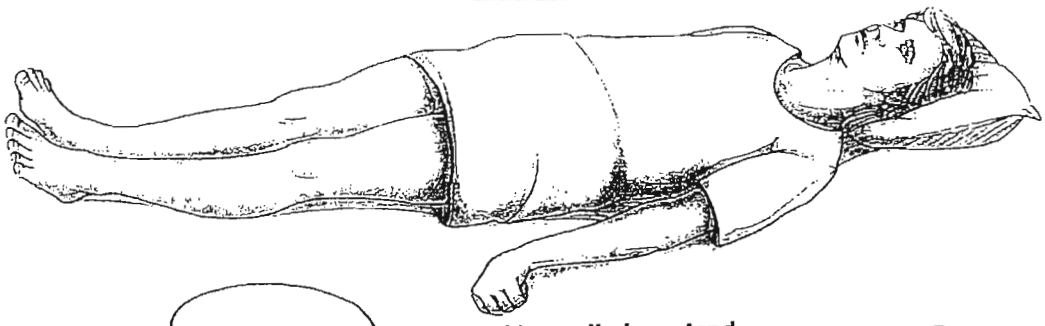

A. Decerebrate: upper and lower limbs extend

Bustami
Bustami

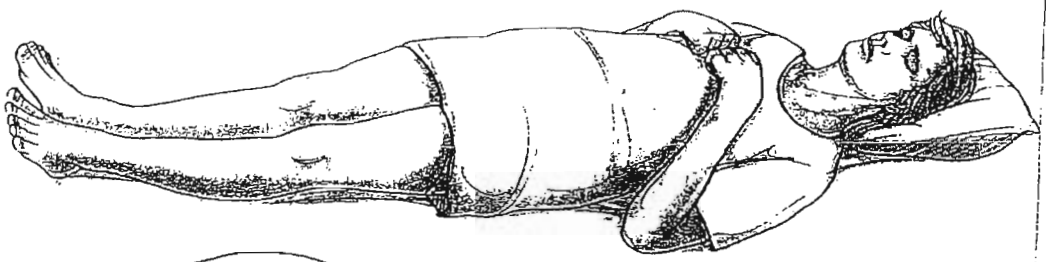

B. Decorticate: upper limbs flex, lower limbs extend

FIGURE 7–4. Abnormal posturing in comatose state. A. Decerebrate (upper and lower limbs extend). B. Decorticate (upper limbs flex, lower limbs extend).

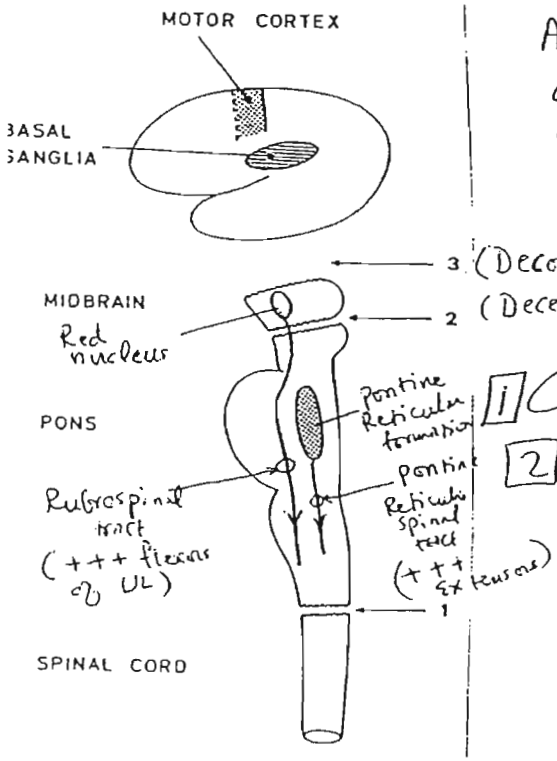

A. Decerebrate & B. Decorticate → Both are in comatose state → what happens if both receive a painful stimulus?

↓

In Decerebrate patient → Extension of both UL & LL

In Decorticate patient → lower limb extend but the upper limbs flex

1 Comment ?? ??

2 Decorticate posture indicates a higher or more rostral level of brainstem impairment than decerebrate posture ✓

↓

In a comatose patient whose condition alters from decerebrate to decorticate posture → the prognosis is better or worse ??

Comment !!

Bustami

Remember : →
the antigravity muscles in the cat are the forelimbs & hindlimbs
↓
In human they are flexors of UL & Extensors of LL

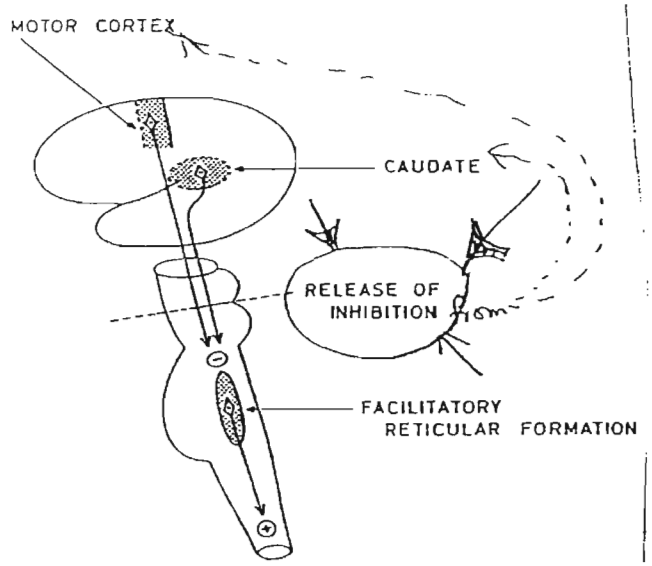

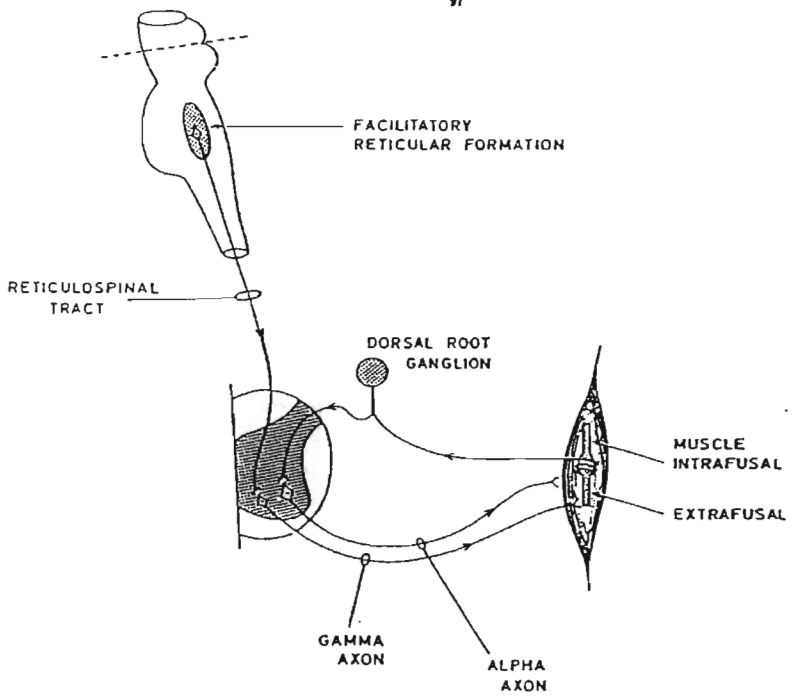

Mechanism

Figure 18.7. Schematic diagram showing the mechanism of decerebrate rigidity.

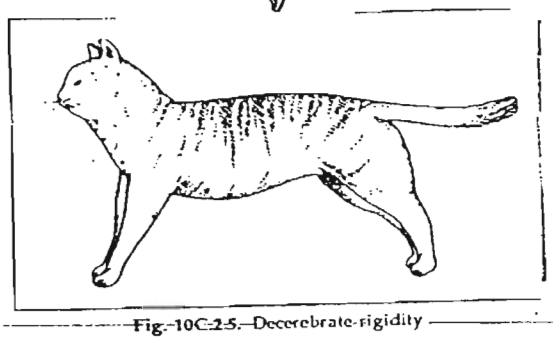

Fig. 10C-2.5.—Decerebrate-rigidity

Fig. 11-7. Schematic of the organization of the flexion–crossed extension reflex.

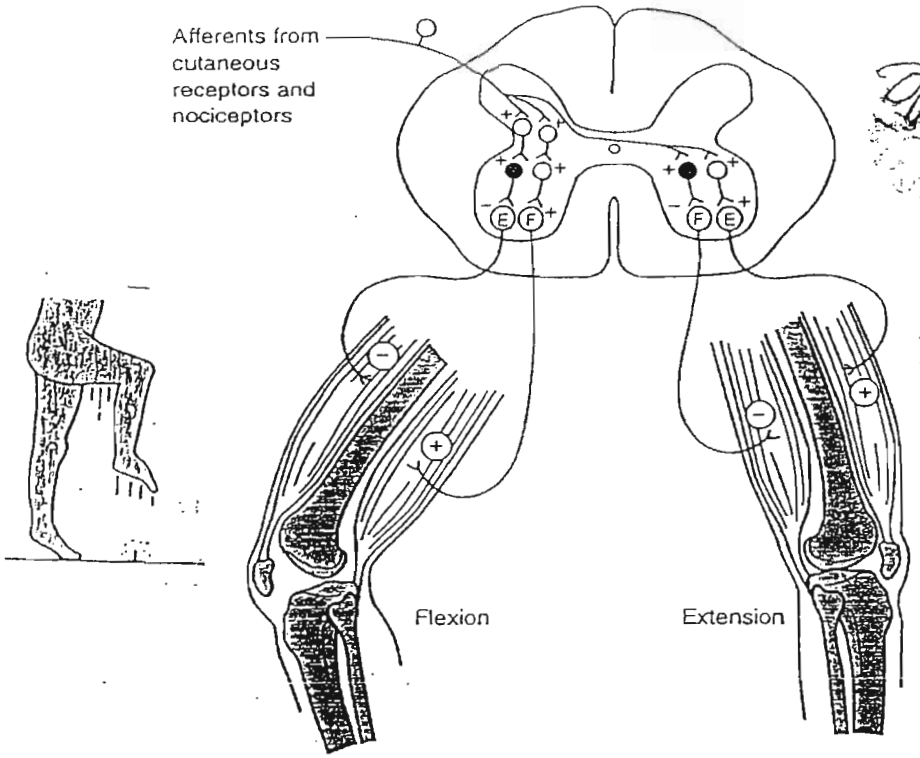

Flexion Reflex

Flexion reflexes are important in a number of behavioral patterns; e.g., flexion of limbs is part of the activity involved in walking. One of the most obvious functions of the flexion reflex is withdrawal of a limb from painful, noxious stimuli. Hence the flexion reflex is frequently called the **withdrawal reflex.** Also, since flexion of the limb ipsilateral to the stimulus is usually accompanied by an extension of the contralateral limb(s), this reflex is also referred to as the **flexion-crossed extension reflex.**

The flexion reflex is polysynaptic (Fig. 11-7). The afferent fibers enter the spinal cord and excite interneurons of the dorsal horn. The interneurons then act on alpha motor neurons through relay pathways involving other interneurons. The response is an excitation of alpha motor neurons to the flexor muscles and inhibition of alpha motor neurons to the extensor muscle of the stimulated limb (ipsilateral). In addition, this is frequently accompanied by excitation of alpha motor neurons to extensor muscles and inhibition of flexors to the contralateral muscle. This behavior is the appropriate response to painful stimuli; for example, if a person steps on a sharp object, the injured foot is withdrawn (flexion), while the other limb of the pair is extended, thereby providing support for the body and preventing the person from toppling.

The flexion reflex can be initiated by activity in afferent fibers from a variety of sensory receptor organs. These sensory receptors may be in the skin, in muscle, and in joints and involve afferent fibers II, III, and IV; collectively, these are called **flexor reflex afferents** (FRA). The degree of flexion response can vary from a flexor twitch in response to relatively innocuous stimulation to a complete withdrawal of the limb from a noxious stimulus. A very strong stimulus to the FRA fibers results in activity of all four limbs. This response is mediated via intersegmental connections and is sometimes referred to as **irradiation of the stimulus**; the stronger the stimulus, the more extensive is the reflex reaction.

Bustami
Bustami

Sequence of events in a voluntary movement (Knee flexion)

↓

① Activation of Ia interneurons → inhibits ANTAgonist α MN

↓

② Activation of Agonist α MN & γ MN

↓

③ Contraction of extra- and intrafusal muscle fibres

↓

④ feedback from contracting spindle increases α MN excitation and Ia inhibition

⑤ Antagonist Ia fibre finds its homonymous α MN Refractory but it transmits to higher centres (arrow)

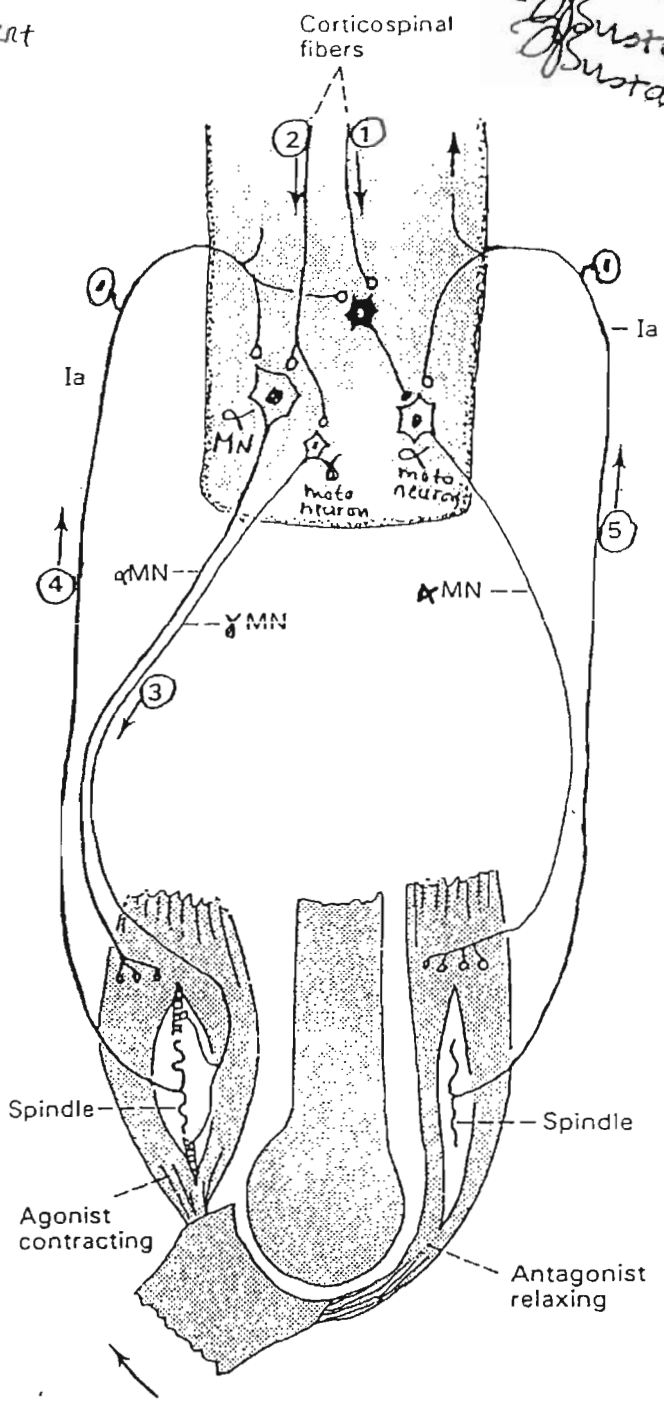

Remember ① γMN, Ia and αMN constitute the gamma loop

② In voluntary movements αMNs and γMNs are recruited (stimulated) together → This is known as α–γ coactivation or linkage

③ The γMNs REINFORCE α-excitation through what is known as the gamma loop

IN THE EXECUTION OF VOLUNTARY MOTOR ACTIVITY → THE DESCENDING INFLUENCES FROM THE CORTEX and SUBCORTICAL STRUCTURES VIA THE TWO PATHWAYS < PYRAMIDAL / EXTRAPYRAMIDAL ⟹ MOST LIKELY ACT SIMULTANEOUSLY on Alpha and gamma motor neurons of the spinal cord. Alpha activation, however, predominates in the case of rapid movements whereas gamma activation predominates in connection with slow, graduated movements

↓

* Selective lesions in the two pathways (Pyramidal and extrapyramidal) are difficult to produce and BOTH are usually affected TOGETHER to varying degrees.

↓

Motor deficits Produced by lesions of the motor cortex or its outflow (descending tracts) depends on the extent to which Pyramidal and extrapyramidal tracts are affected

↓

1- Interruption of the corticospinal tract by Unilateral Section of the Pyramid ⟹ Paresis (weakness) ⊕ hypotonia of the distal muscles of the limbs on the contralateral side (These findings are consistent with a loss of the descending facilitatory effects on the spinal α and γ metoneurons)

2- Experimentally produced localized lesions of cortical Primary motor area (area 4) resemble the effects of Pyramidotomy i.e Distal Paresis (weakness) or paralysis (loss of function) and hypotonia ⟹ when the lesion is increased to include premotor area 6 (in which proximal muscles are represented) → the loss of control over brainstem centres generates a state of Spasticity that overshadows the hypotonia due to area 4 lesion.

3- Lesions at the level of the internal capsule (a common lesion in cases of Stroke السكتة الدماغية and could be the result of haemorrhage or thrombosis or embolism of the blood vessels of internal capsule) → results in interruption of corticospinal fibres (Pyramidal) as well as projections to the brainstem (extrapyramidal) → The Extrapyramidal effects OVERSHADOW the Pyramidal effects → In addition to Paresis or paralysis of the contralateral half of the body → hemiparesis or hemiplegia ← the predominant signs of such a lesion are:

a- Spasticity → increased muscle tone particularly affecting antigravity muscles (flexors of upper limb and extensors of lower limb)

b- HYPERREFLEXIA → Exaggerated muscle stretch reflex (MSR) (used to be called deep tendon reflexes or JERKS)

c- Clonus → rhythmic contractions of muscles when they are subjected to Sudden sustained stretch.

d- Positive Babinski's sign } Reversal of certain
e- absent { abdominal reflex, Cremasteric reflex } FRA-Driven reflexes

⇓

Spasticity, hyperreflexia & Clonus → Reflect RELEASE of the brainstem centres from descending controls (i.e brainstem centres are released from inhibition) → imbalance between facilitatory and inhibitory effects on stretch reflex → increased γ efferent discharge → hyperactive stretch reflex → Hyperreflexia
→ excessive contraction of antigravity muscles (spasticity)

What are the signs of upper motor neuron lesion (UMNL)? → (Paresis) or (Paralysis) - - - - - - → distal muscles (hand)
(+) Signs a, b, c, d, e

Bustami
Bustami

35

Spasticity and Rigidity

Bustami

* Both are fundamentally the same phenomenon in that they reflect RELEASE of the brainstem mechanisms from descending controls resulting in IMBALANCE between the facilitatory and inhibitory influences on the spinal motor circuits (esp. stretch reflex)

* How you examine for spasticity? → increased resistance of spastic muscles to PASSIVE movement that is usually greater in antigravity muscles (unidirectional) → a clasp-knife reflex is observed.



This patient has an upper motor neuron lesion (UMNL) known as stroke or cerebrovascular accident (CVA)

↓

The lesion which is either haemorrhage or thrombotic vessel or embolism affecting his Right internal capsule (So, the lesion will affect both pyramidal & extrapyr. tracts) → He suffers spastic weakness or paralysis of his left upper and lower limbs (Hemiparesis or Hemiplegia)

Remember → Spasticity (of upper motor neuron lesion) is accompanied by Hyperreflexia & clonus, Why??

→ the underlying mechanism is the same

RELEASE of - - - - - - - -

Four Primary Reflexes

Reflex	Roots Needed for Reflex	Muscle Carrying out the Relex
Ankle jerk	S1	Gastrocnemius
Knee jerk	L2, L3, L4	Quadriceps
Biceps	C5, C6	Biceps
Triceps	C7, C8	Triceps

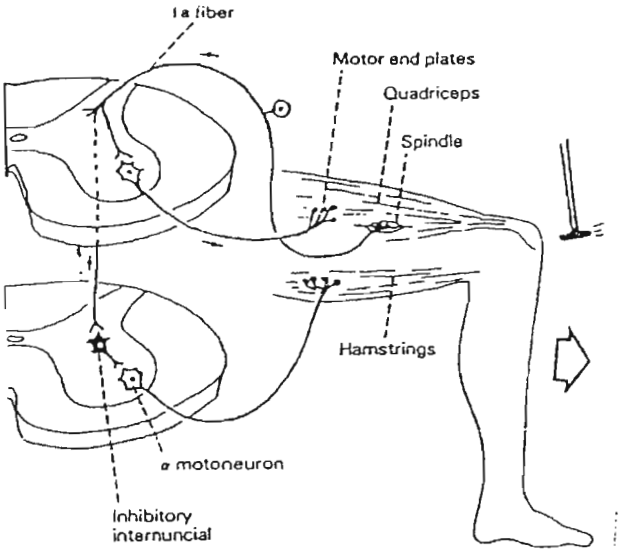

ig. 4-9 The knee jerk.

I HYPERREFLEXIA signifies an upper motor neuron lesion along the neuraxis from cortex to lateral columns of the spinal cord.

Exaggerated tendon reflexes. These are seen on the affected side, exemplified by the knee and ankle jerks, and are due to the release of the stretch reflex from inhibition by higher centres

4 *Clonus.* This is the occurrence of rhythmic contractions of muscles when they are subjected to sudden sustained stretch, e.g. ankle clonus. The precise cause of clonus is not known. This phenomenon is associated with increased gamma efferent discharge, occurring as a result of the release of the stretch reflex from inhibition.

II Positive Babinski's Sign
||
(up-going toes) → Extensor plantar response

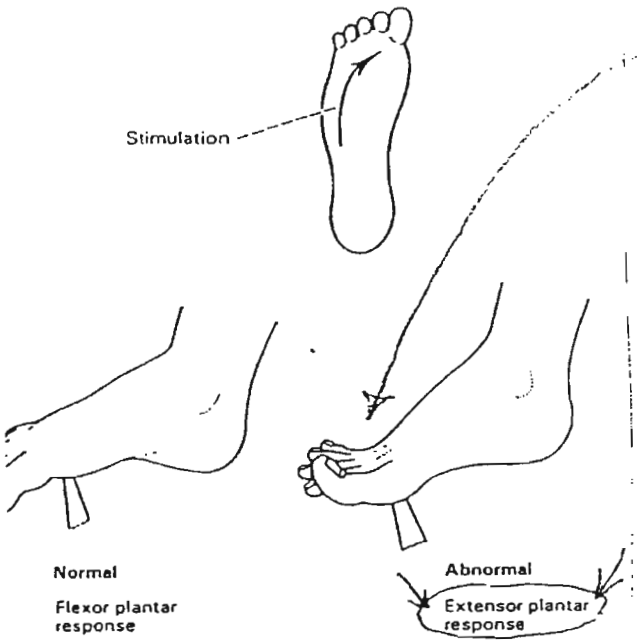

g. 11-11 Plantar reflex, showing the Babinski sign – an extensor intar response to a stimulus applied to the sole.

the plantar reflex becomes extensor, known as a positive *Babinski's sign* (i.e. scratching the outer aspect of the sole by a blunt object results in dorsiflexion of the big toe and fanning of the other four toes). The abnormal response is thought to be a primitive reflex that reappeares following injury of the pyramidal fibres.

The Babinski's sign is considered physiological during the first year of life, due to immaturity of the pyramidal tract, and in adults during sleep, deep anaesthesia or coma, due to the depressed activity of the motor cortex.

Remember → If the hyperactive reflexes truely reflect upper motor neuron lesion → the toes should also be abnormal i.e up-going toes → Positive Babinski's Sign

The clinical term rigidity is one of the major signs of Parkinson's disease which affects the functions of the basal ganglia. In contrast to spasticity this type of rigidity has the following characteristics: (37)

(a) increased resistance to passive movement is bidirectional (i.e both flexors and extensors are affected) Bustami

(b) patients with Parkinson's disease do not have a hyperactive muscle stretch reflex (deep tendon reflexes) Bustami

Remember → If the upper motor neuron lesion (UMNL) occurs above the level of motor (pyramidal) decussation i.e in the motor cortex or internal capsule or brainstem → the paresis or paralysis will be CONTRALATERAL to the side of the lesion

However if the lesion is below the level of decussation → paresis or paralysis will be ipsilateral to the side of lesion (i.e within the lateral funiculus of white matter of spinal cord)

	Lower Motor Neuron	Upper Motor Neuron
1	Flaccid weakness or paralysis	Spastic weakness
2	Decreased or absent MSR	Increased MSR with or without clonus
3	Signs of muscle denervation; fasciculations, fibrillations, profound atrophy	No signs of muscle denervation
4	Muscles affected singly or in small groups innervated by a common nerve or spinal root	Muscles affected in large groups, organized by quadrants or halves of the body

The term lower motor neuron (LMN) is used to designate the ventral horn cells of the spinal cord (α & γ MNs) which innervate skeletal muscles of body (+) the motor neurons of the brainstem which innervate muscles (facial muscles, tongue muscles, muscles of pharynx & larynx) supplied by certain cranial nerves

Destruction of lower motor neurons (LMNs) or their axons (e.g by poliomyelitis) → Loss of voluntary & reflex response of muscles supplied by these neurons

Signs of Lower motor neuron lesion (LMNL)

1. Paresis or paralysis } Flaccid paralysis
2. Decreased muscle tone (flaccidity)
3. Decreased or absent muscle stretch reflexes (MSR)
4. Fasciculation → fibrillation (spontaneous activity of muscle fibres at rest)
5. Marked denervation atrophy

All these signs occur ipsilateral to the spinal cord lesion → in the muscle or muscles supplied by the spinal cord segment involved

N.B Fasciculations are the earliest objective sign of muscle denervation

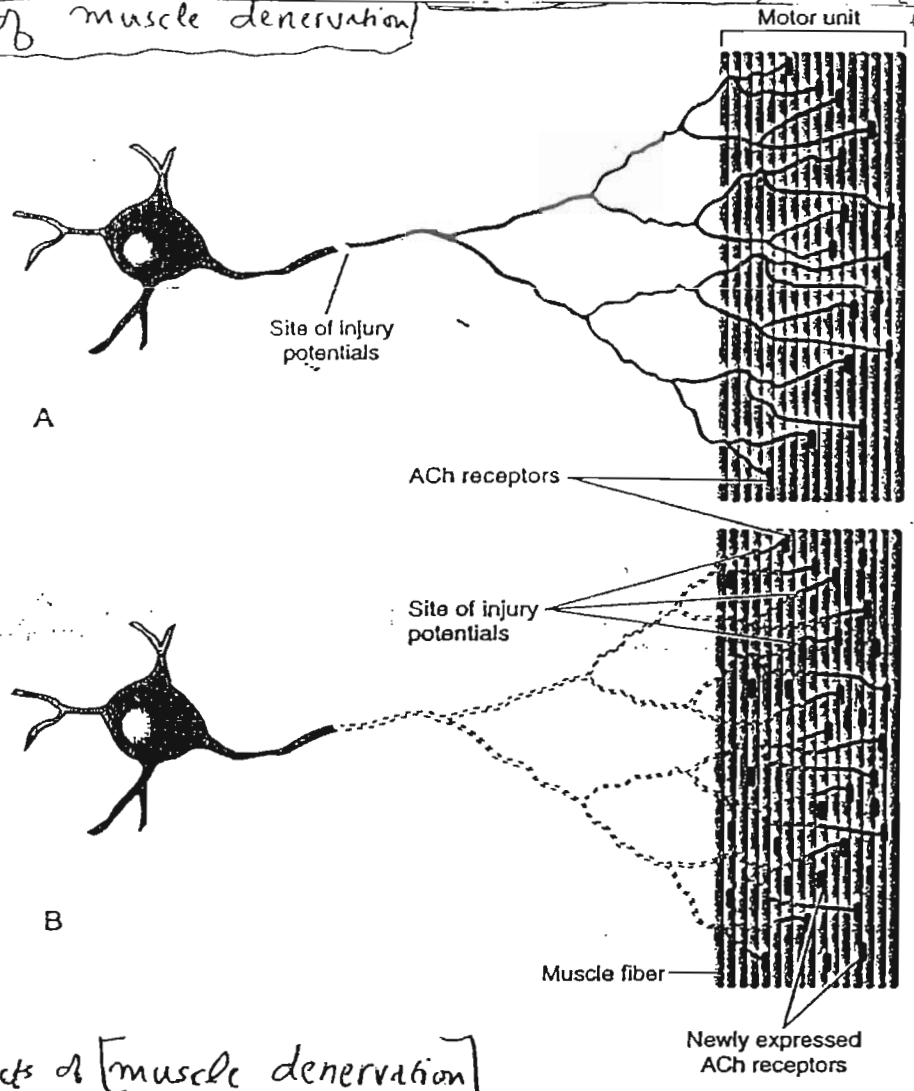

Effects of [muscle denervation]

Fasciculations and fibrillations are caused by injury potentials generated at the site of injury to a motor neuron axon. **A.** Injury potentials cause all of the elements of the motor unit to contract simultaneously, producing a coordinated twitch (fasciculation) that is visible on the surface of the body. **B.** As the distal axon degenerates, the distal branches disconnect, and each has its own site where injury potentials are generated. Because the individual muscle fibers no longer contract as a unit, the twitches (fibrillations) are uncoordinated among the individual muscle fibers and not visible on the surface. In addition, as a consequence of denervation, the muscle fibers express numerous ACh receptors that make the muscle fibers hypersensitive to circulating ACh.

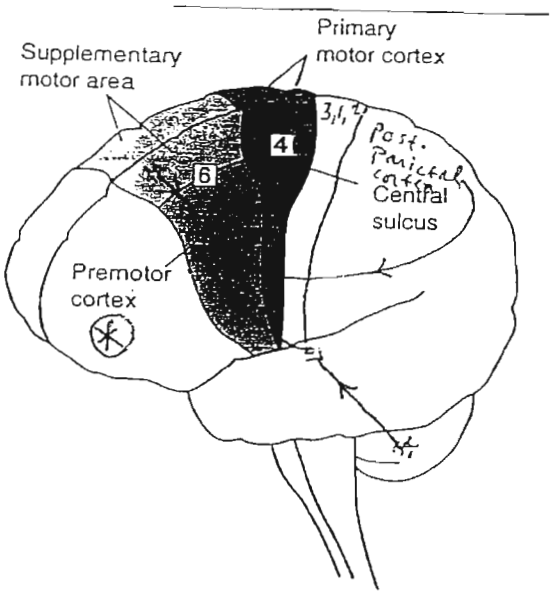

Premotor cortex

The premotor cortex receives its main inputs from the posterior parietal cortex, the cerebellum (via the ventrolateral thalamus) and the supplementary motor area. The main outputs project to the motor cortex, the brainstem and the spinal cord via the ventral corticospinal tract.

As with the supplementary motor area, the premotor cortex shows neural activity beginning well before movement onset. The premotor cortex appears to be involved in postural preparation for the coming movement, as indicated by its input to the anterior corticospinal tract.

Lesion : appearance of grasp Response ??

Remember that the Premotor cortex controls Proximal & axial muscles (through anterior (ventral) corticospinal tract as well as extrapyramidal tracts)

Remember that a lesion limited to area 4 → flaccid paralysis while a lesion affecting both areas 4 & 6 → Spastic paralysis ?? (Loss of control over brainstem inhibitory reticular formation .....)

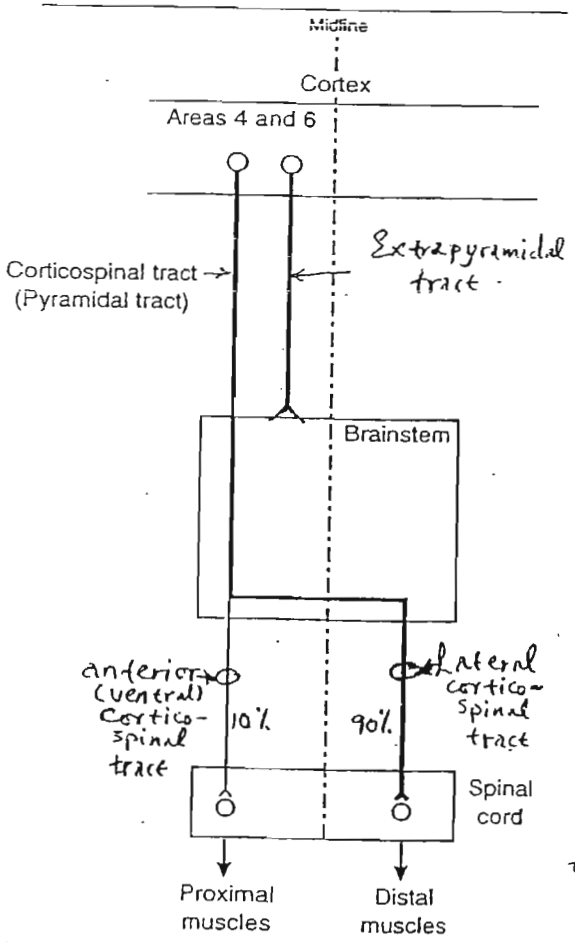

Posterior parietal cortex (5,7)

The posterior parietal cortex lies posterior to the somatic sensory cortex (Fig. 3.7.3A). The inputs to the posterior parietal cortex come from sensory areas of cerebral cortex carrying visual, auditory, cutaneous & proprioceptive informations as well as inputs from the motor areas → i.e in this region of brain (Sensorimotor) information is brought together to generate the conscious map of the body & of the body's position in space.

Lesion of Posterior parietal cortex → (a) inability to direct attention to sensory stimuli (b) the condition of hemi-neglect where the patient ignores & even denies the existence of one side of body (c) failure of movement planning → inability to relate the position of objects in space to that of the body

Fig. 12-4. Motor areas of the cerebral cortex.

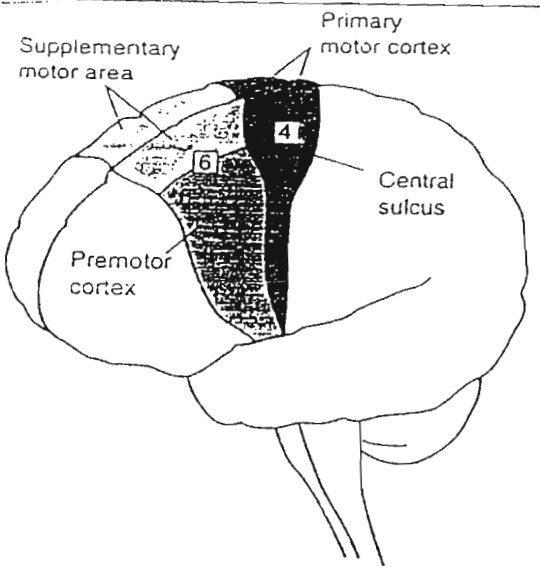

Supplementary motor area

In order to produce complex movements, there must be a motor plan that specifies the sequence and extent of the muscle contractions needed to execute the movement itself and to effect the necessary postural adjustments associated with the movement; for example, compensating for a change in the position of the centre of gravity.

The output of the motor cortex activates specific muscles but does not of itself produce complex motor behaviour. This appears to be the role of the supplementary motor area and the premotor cortex (Fig. 3.7.3A).

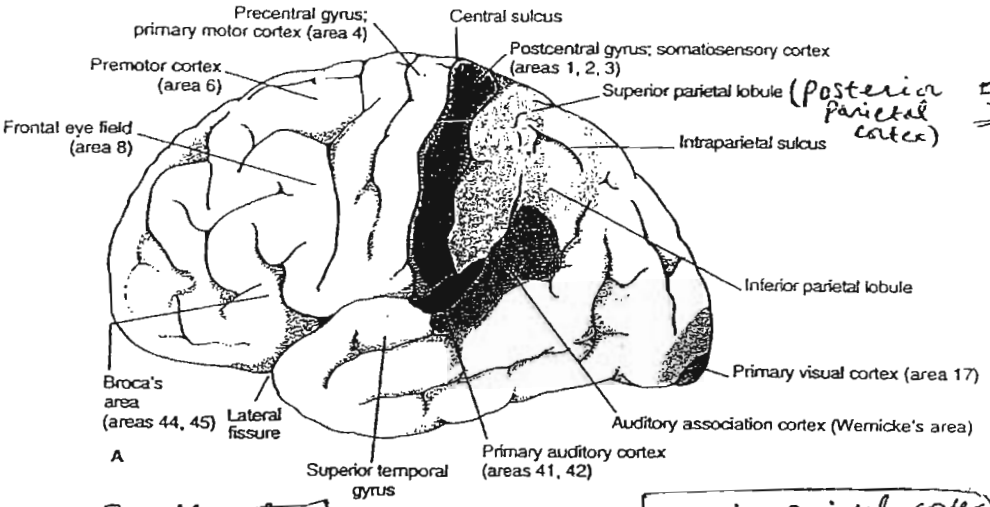

The supplementary motor area receives inputs from the basal ganglia and the cerebellum (via the ventrolateral nucleus of the thalamus) and from the posterior parietal cortex. It also has outputs going to both the basal ganglia and the cerebellum as well as to the motor cortex and brainstem and a minor component direct to the spinal cord via the corticospinal tract. The input–output loops with the basal ganglia and the cerebellum indicate a role in movement programming.

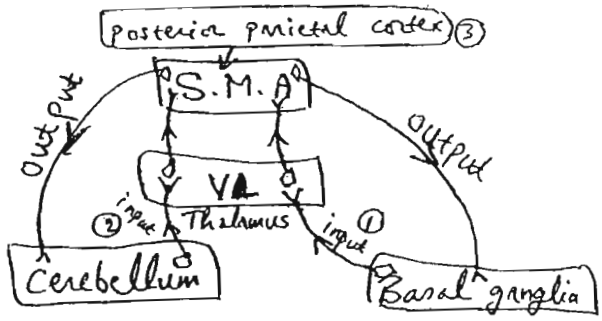



Electrical stimulation of the supplementary motor area often produces complex, bilateral movements; and measurements of cortical blood flow reveal that the area is active during movements involving extensive coordination, particularly of both hands, but not during simple flexion/extension movements of single joints.

Lesions of the supplementary motor area result, for example, in the inability to orient the hand correctly when reaching for a target or to coordinate the hands during bimanual tasks.

40

Grasp Response (Reflex)*

Grasp Reflex. Stroke the patient's palm so he grasps your index finger between his thumb and index finger (Fig. 11-35). When the grasp reflex is present, he cannot release the fingers when he tries. This is a normal response in young infants; later in life, lesions of the premotor cortex may uncover the reflex as a pathologic finding.

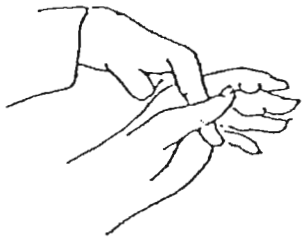

Fig. 11-35. Grasp reflex. *With your index finger between his thumb and index finger, stroke the patient's palm as he grasps your finger. In lesions of the premotor cortex, he may be unable to release his grasp.*

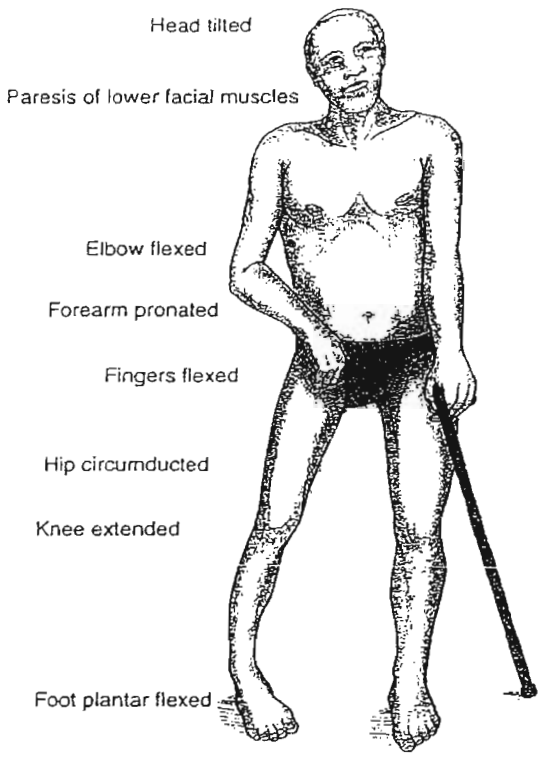

FIGURE 6-5. Right spastic hemiplegic. Gait resulting from left capsular lesion.

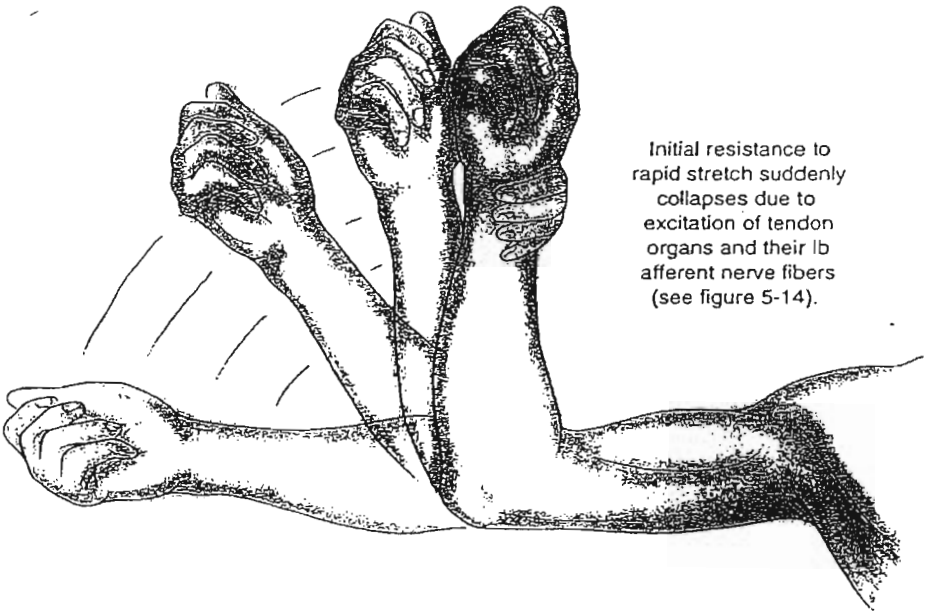

FIGURE 6-6. The clasp-knife response.

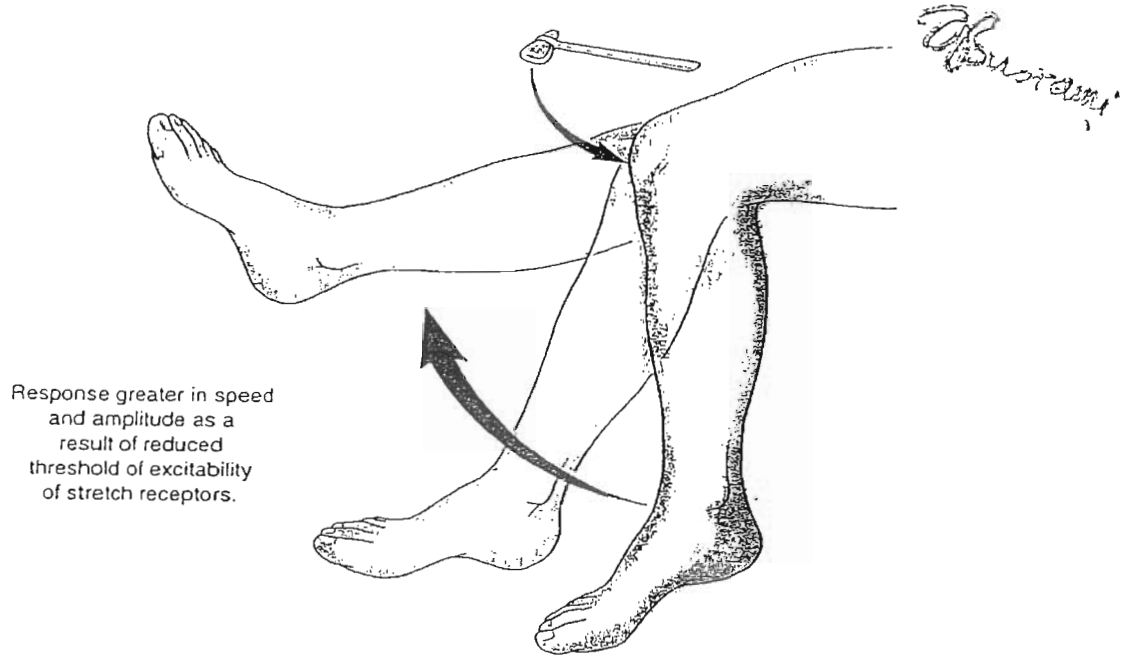

FIGURE 6-7. Exaggerated patellar reflex.

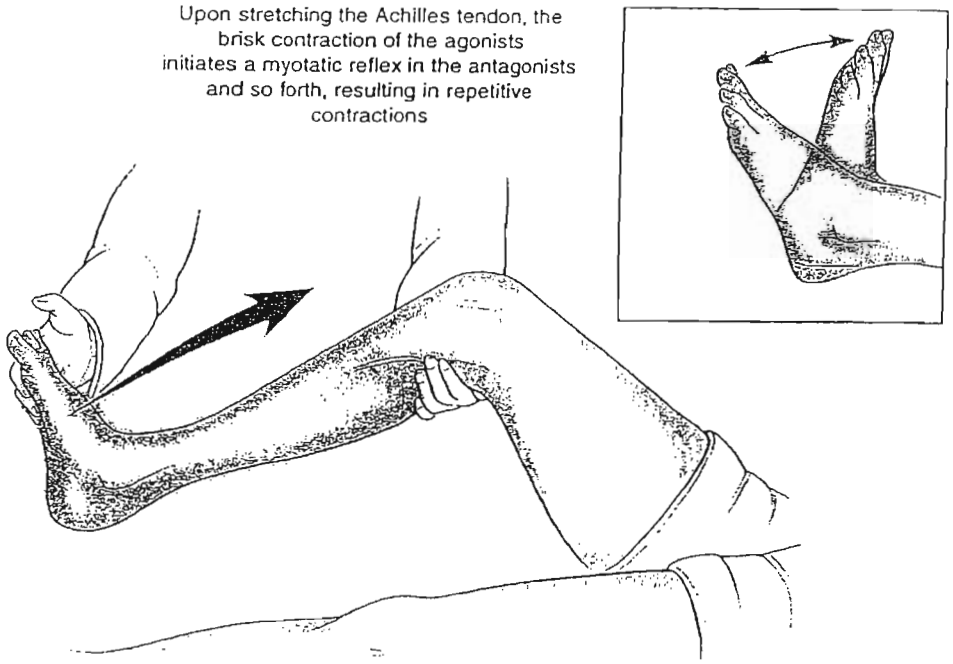

FIGURE 6-8. Clonus.

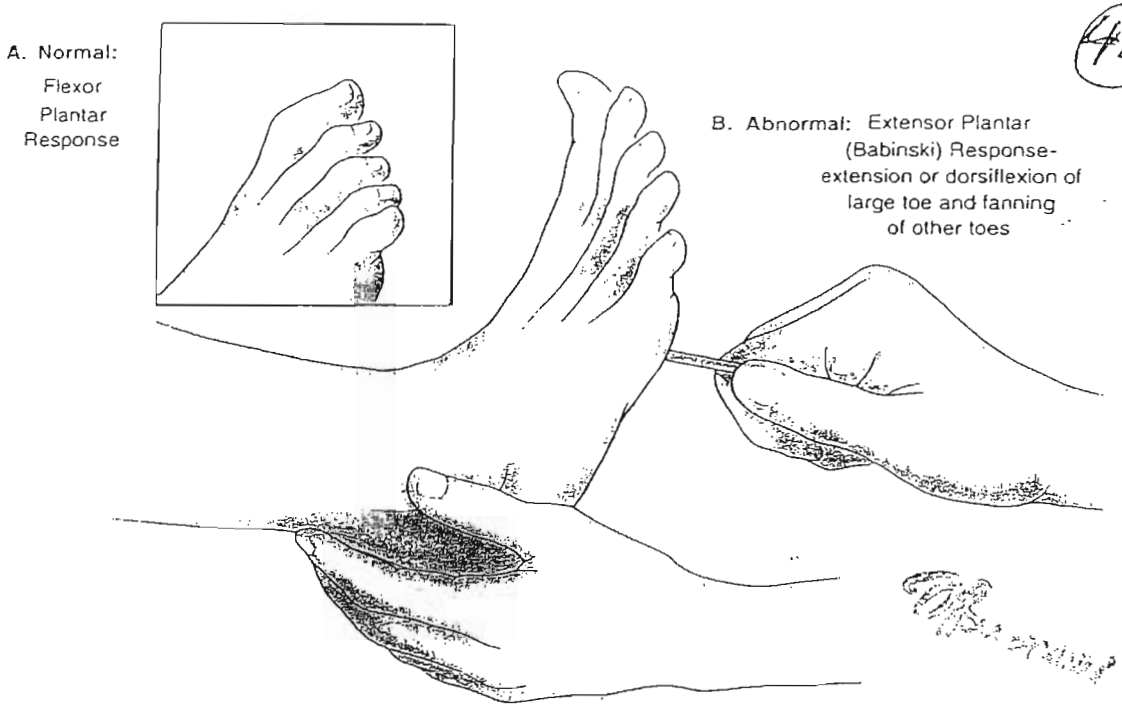

FIGURE 6–9. Plantar responses. **A.** Normal flexor. **B.** Abnormal extensor or Babinski.

MOTOR NEURON DISEASE

OBustami

Degeneration of both upper & lower motoneurons

e.g Lesion at lower cervical region of sp. cord at C.8, T1

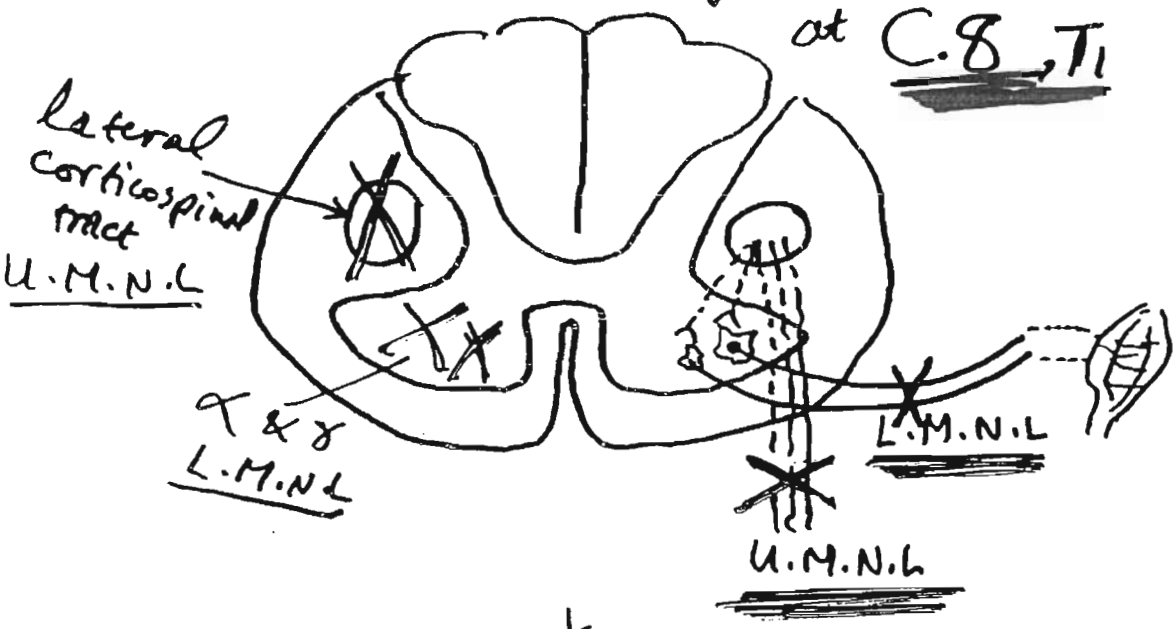

* L.M.N.L at upper limb ..... → Paralysis & ATROPHY of small muscles of hand

* U.M.N.L at lower limb
  Paralysis ⊕ Hyperreflexia ⊕ +ve Babinski ....
  ⊕ clonus

3rd year

University of Jordan
Faculty of Medicine

Medical Committee
The University of Jordan

The Central Nervous System

Anatomy

1

- [ ] Slides
- [ ] Sheet
- [x] LAB

Title: _____

Professor: Dr.Faraj Bustami

Date: 1/2/2014

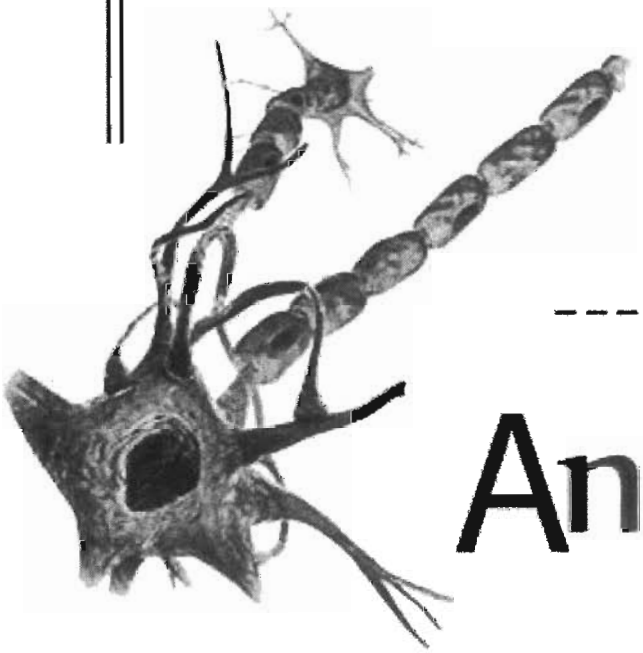

Sheet written by:

_____

Anatomy

Central Nervous system (1)
C. N. S

- BRAIN
  - Cerebrum
  - Cerebellum
  - Brain stem
    - Midbrain
    - Pons
    - medulla oblongata
- SPINAL CORD

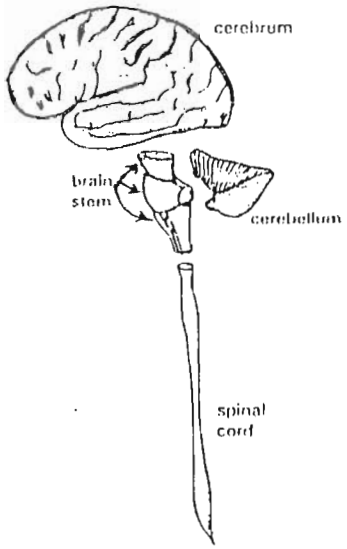

Fig. 1-15. Divisions of the CNS.

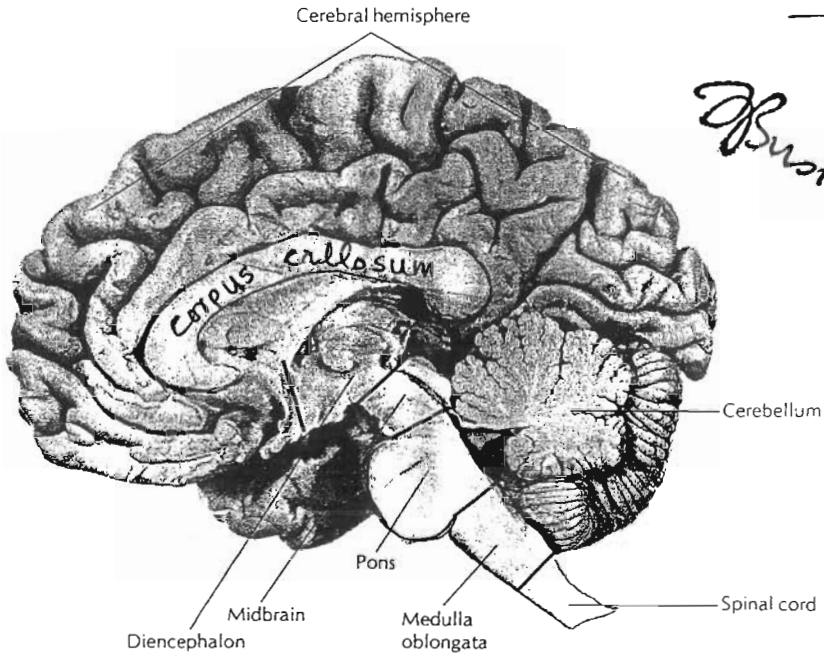

Bustami

من شفافيات الدكتور
فرح البسطامي
لطلبة الطب البشري
2/2015

Figure 1-3. Regions of the mature central nervous system, as seen in sagittal section. (×0.5; *photograph kindly provided by Dr. D. G. Montemurro.*)

Developmentally
BRAIN is formed of 3 major Parts:

1. Forebrain (Prosencephalon)
   - Telencephalon (2 cerebral hemispheres)
   - Diencephalon:
     - Thalamus, hypothalamus
     - Subthalamus
2. Midbrain (mesencephalon)
3. hind brain (Rhombencephalon)
   - myelencephalon (medulla oblongata) (a)
   - metencephalon
     - Pons (b)
     - cerebellum (c)

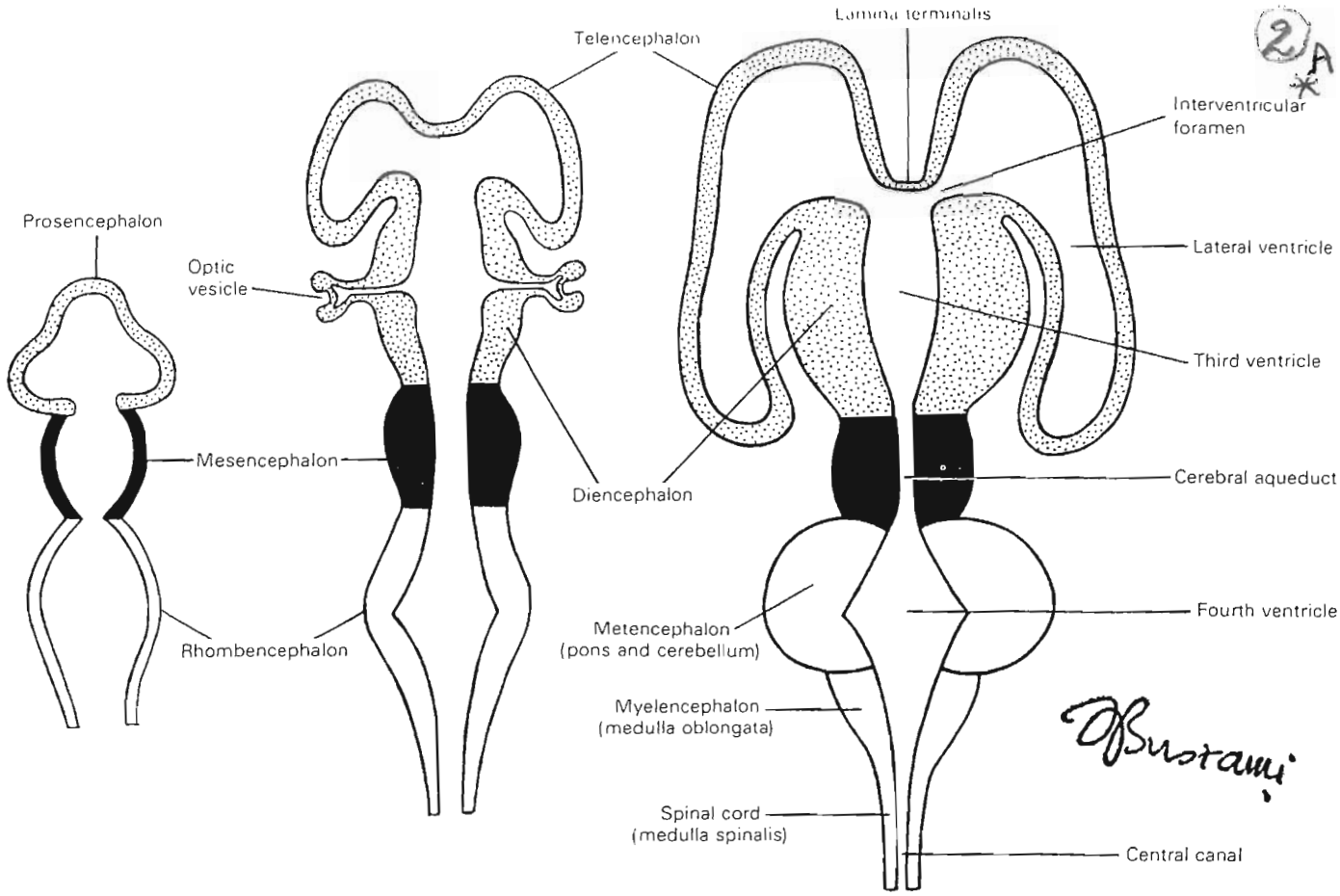

Fig. 1.3 Diagrams of stages in the differentiation of cerebral vesicles and the ventricular system.

Developmentally → 3 brain vesicles < forebrain, midbrain, hindbrain develop from the rostral (superior) part of the Neural tube → the cavities of these vesicles become the ventricular system of the adult brain as follows :-

1. The cavity of the telencephalon (each cerebral hemisphere) will form the LATERAL VENTRICLE
2. The cavity of the diencephalon (thalamus and hypothalamus) is the Third Ventricle
3. The cavity of the mesencephalon (midbrain) remains a narrow canal called the CEREBRAL AQUEDUCT
4. the cavity of the rhombencephalon (hindbrain) will form the Fourth Ventricle (a cavity bounded by the cerebellum, pons and medulla oblongata)

Nervous System

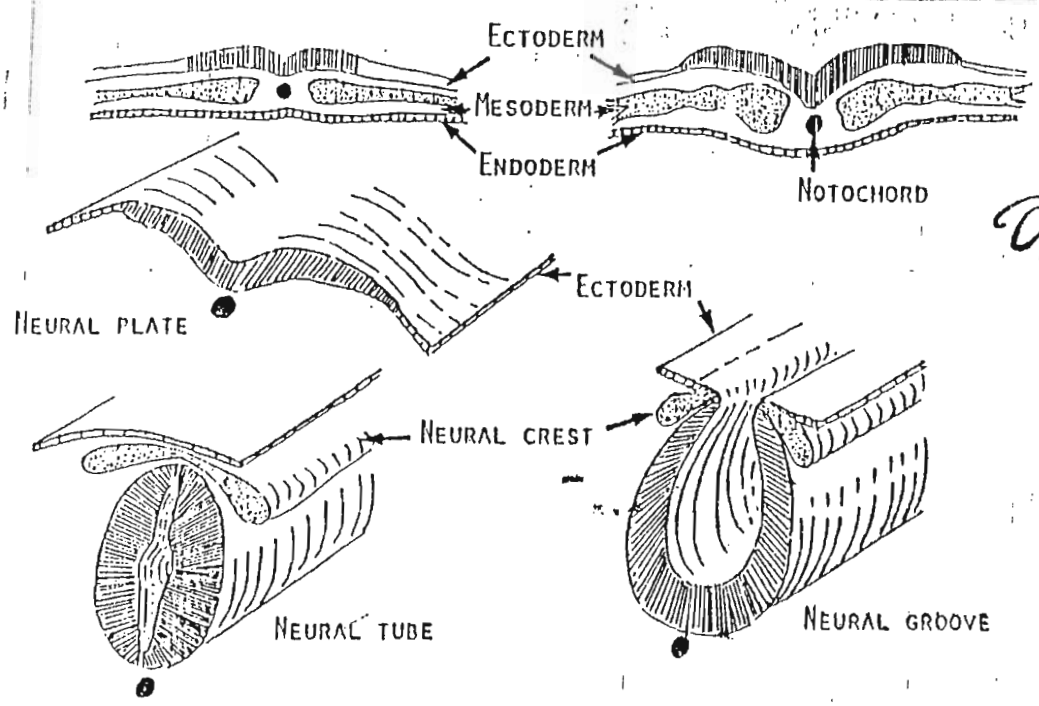

Fig. 21-1. Formation of neural tube.

NEURAL TUBE FORMATION

I. At the beginning of the third week, under the inductive influence of the notochord, the dorsal ectoderm thickens in the midline to form the neural plate (Fig. 21-1).

II. Due to the changes in the shape and size of the neural epithelial cells and the changes in their connections with surrounding cells, the lateral margins of the plate become elevated to form the neural folds.

III. The depression between these folds is known as neural groove.

IV. At about the 25th day the neural folds fuse to form the neural tube. The fusion begins at the fourth somite and progresses rostrally and caudally.

V. For a short time the neural tube remains open at both ends as the rostral and caudal neuropores (Fig. 21-2).

VI. The rostral neuropore closes at about the 25th day, and two days later the caudal neuropore closes.

VII Some cells at the margin of neural fold do not incorporate into the neural tube, and thus form the neural crest.

VIII The neural tube detaches itself from the ectoderm and sinks into the underlying mesoderm.

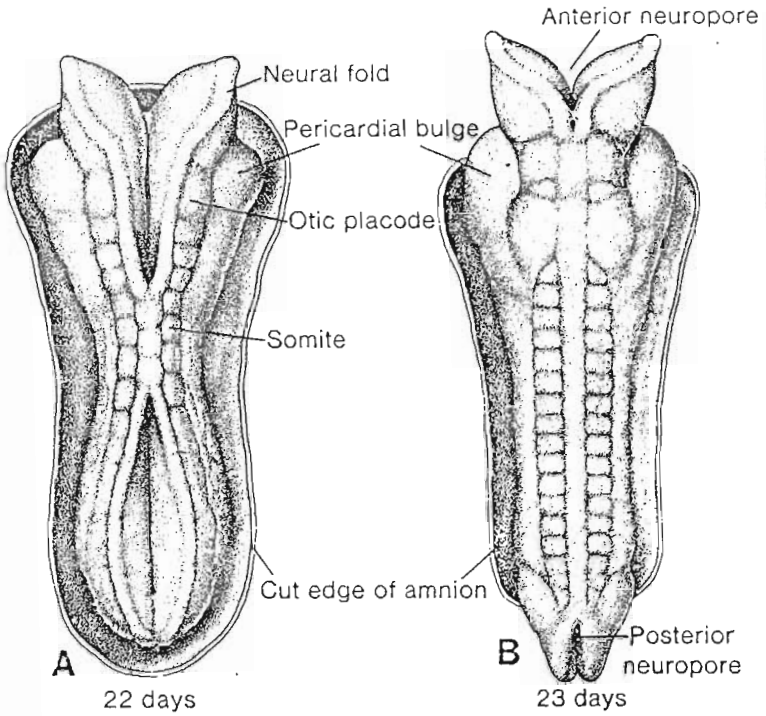

Figure 5-4. A, Dorsal view of a human embryo at approximately day 22. (Modified after Payne.) Seven distinct somites are visible on each side of the neural tube. B, Dorsal view of a human embryo at approximately day 23. (Modified after Corner.) Note the pericardial bulge on each side of the midline in the cephalic part of the embryo.

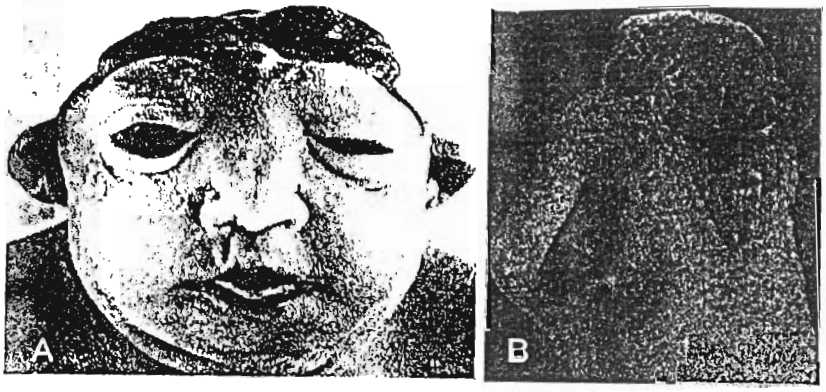

Figure 20-31. A, Photograph of anencephalic child. Ventral view. This abnormality is frequently seen (1:1000 births). Usually the child dies a few days after birth. (Courtesy Dr. J. Warkany. From Warkany J: *Congenital Malformations*. Chicago, Year Book Medical Publishers, 1971. Used by permission.) B, Dorsal view of an anencephalic child with spina bifida in cervical and thoracic segments.

Anencephalus → failure of the cephalic part of the neural tube (anterior neuropore) to close

At birth → the vault of the skull is absent
→ the brain is represented by a mass of degenerated tissue exposed to the surface
→ often → rachischisis (open spinal cord) in the cervical region + the neck is ~~absent~~ present

* The foetus lacks the central mechanism for swallowing
→ the last 2 months of pregnancy are characterized by hydramnios (2000 ml) ⊕ → high level of α-fetoprotein (AFP)

* more common in ♀ than ♂ (4 : 1)
* common abnormality [illegible]

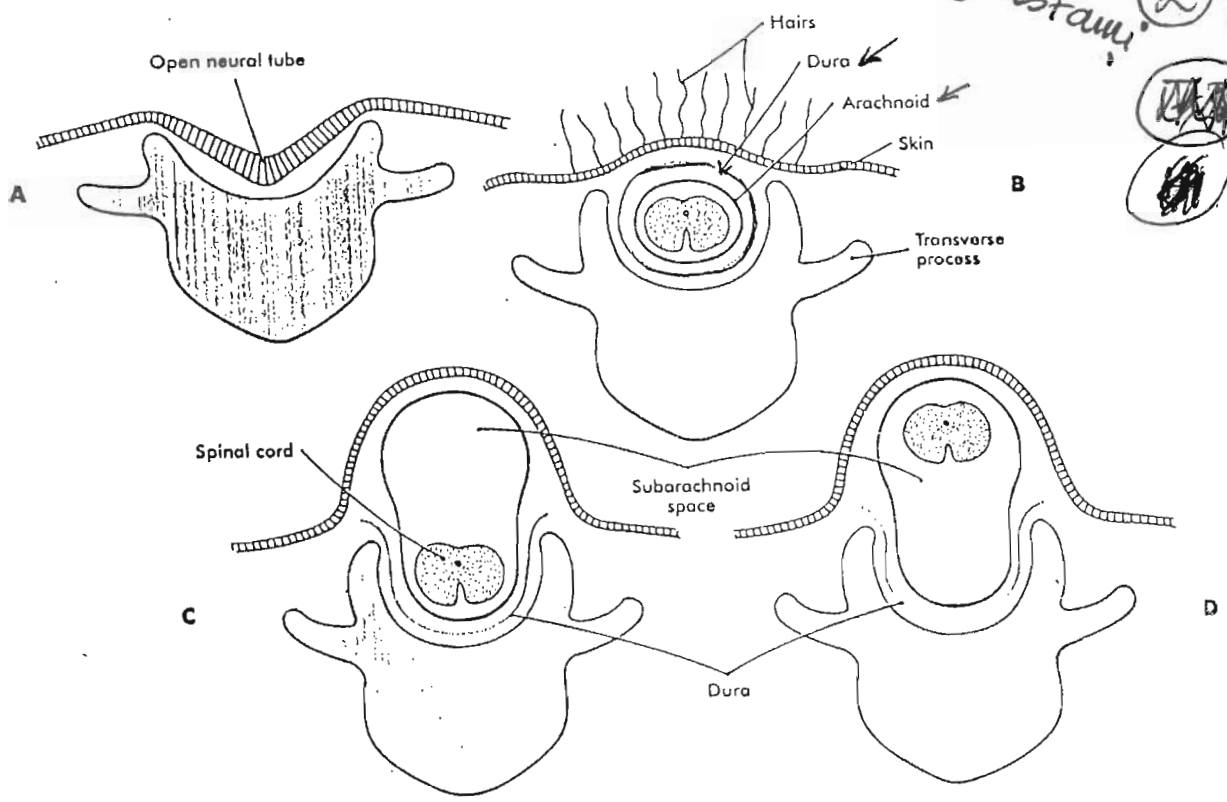

FIG. 12-38 Varities of closure defects of the spinal cord and vertebral column. **A,** Rachischisis. **B,** Spina bifida occulta, with hair growth over the defect. **C,** Meningocele. **D,** Myelomeningocele.

Other Closure Defects

A defect in the formation of the bony covering overlying either the spinal cord or brain can result in a graded series of structural anomalies. In the spinal cord, the simplest defect is called **spina bifida occulta** (Fig. 12-38, *B*). The spinal cord and meninges remain in place, but the bony covering (neural arch) of one or more vertebrae is incomplete. Sometimes the defect goes unnoticed for many years. The site of the defect is often marked by a tuft of hair. The next most severe category of defect is a **meningocele,** in which the dura mater may be missing in the area of the defect and the arachnoid layer bulges prominently beneath the skin (Fig. 12-38, *C*). The spinal cord, however, remains in place, and neurological symptoms are often minor. The most severe condition is a **myelomeningocele,** in which the spinal cord bulges or is entirely displaced into the protruding subarachnoid space (Figs. 12-38, *D* and 12-39). Because of problems associated with displaced spinal roots, neurological problems are commonly associated with this condition.

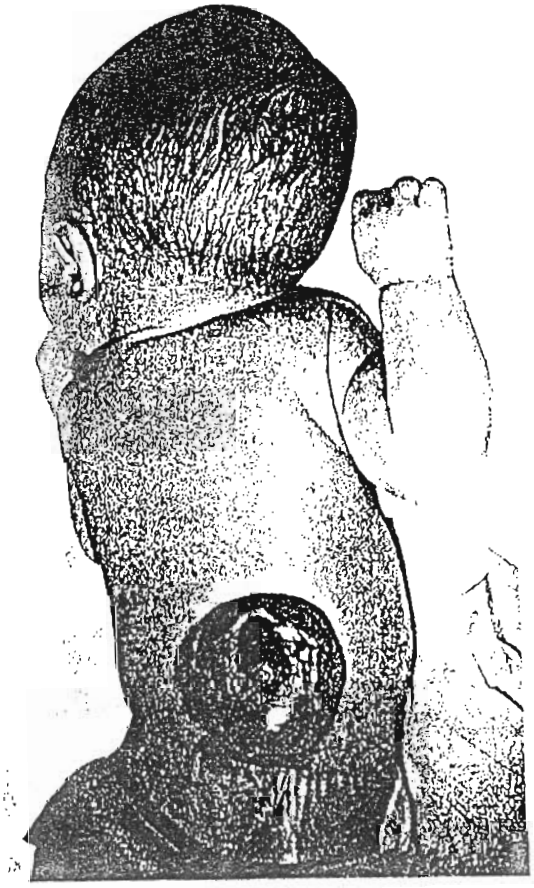

FIG. 12-39 Infant with a myelomeningocele and

"Upustami"

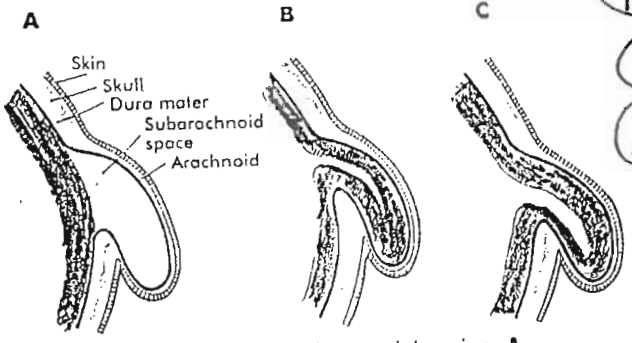

FIG. 12-40 Herniations in the cranial region. **A**, Meningocele. **B**, Meningoencephalocele. **C**, Meningohydroencephalocele.

A similar spectrum of anomalies is associated with cranial defects (Figs. 12-40 and 12-41). A **meningocele** is typically associated with a small defect in the skull, whereas brain tissue alone **(meningoencephalocele)** or brain tissue containing part of the ventricular system **(meningohydroencephalocoele)** may protrude through a larger opening in the skull. Depending on the nature of the protruding tissue, these malformations may be associated with neurological deficits. The mechanical circumstances may also lead to secondary hydrocephalus in some cases.

Microcephaly is a relatively uncommon condition characterized by underdevelopment of both the brain and the cranium (see Fig. 10-9). Although it can result from premature closure of the cranial sutures, in most cases its etiology is uncertain.

Many of the functional defects of the nervous system are poorly characterized, and their etiology is not understood. Studies on mice with genetically based defects of movement or behavior due to abnormalities of cell migration or histogenesis in certain regions of the brain suggest there is likely a parallel spectrum of human defects. **Mental retardation** is common and can be attributed to many causes, both genetic and environmental. The timing of the insult to the brain may be late in the fetal period.

FIG. 12-41 Fetuses with (A) an occipital meningocele and (B) a frontal encephalocele.
(Courtesy Mason Barr, Ann Arbor, Mich.)

FIG. 12-37 Fetus with a severe case of rachischisis. The brain is not covered by cranial bones, and the light-colored spinal cord is totally exposed.
(Courtesy Mason Barr, Ann Arbor, Mich.)

A number of the closure defects can be diagnosed by the detection of elevated levels of alpha-fetoprotein in the amniotic fluid or by ultrasound scanning.

Defects in Closure of the Neural Tube

Failure of closure of the neural tube occurs most commonly in the regions of the anterior and posterior neuropore, but other locations are also possible. In this condition the spinal cord or brain in the affected area is splayed open, with the wall of the central canal or ventricular system constituting the outer surface. A closure defect of the spinal cord is called rachischisis and, in the brain, cranioschisis. Cranioschisis is incompatible with life. Rachischisis (Fig. 12-37) is associated with a wide variety of severe problems, including chronic infection, motor and sensory deficits, and disturbances in bladder function. These defects commonly accompany anencephaly (see Fig. 8-4), in which there is a massive deficiency of cranial structures.

Myelination in the Spinal Cord

In the spinal cord the nerve fibers are heavily myelinated or slightly myelinated. The myelin sheath is formed and maintained by the *oligodendrocytes* of the neuroglia. The cervical portion of the cord is the first part to develop myelin, and from here the process extends caudally. The fibers of the anterior nerve roots are myelinated before those of the posterior nerve roots. The process of myelination begins within the cord at about the fourth month, and the sensory fibers are affected first. The descending motor fibers are the last to myelinate, which process does not begin until term; it continues during the first 2 years of postnatal life.

Myelination in the Brain and the Onset of Function

Myelination in the brain begins at about the sixth month of fetal life but is restricted to the fibers of the basal ganglia. Later the sensory fibers passing up from the spinal cord myelinate, but the progress is slow so that at birth the brain is still largely unmyelinated. In the newborn there is very little cerebral function; motor reactions such as respiration, sucking, and swallowing are essentially reflex. After birth the corticobulbar, corticospinal fibers, and the tectospinal and corticopontocerebellar fibers begin to myelinate. This process of myelination is not haphazard but systematic, occurring in different nerve fibers at specific times. The corticospinal fibers, for example, start to myelinate at about 6 months after birth, and the process is largely complete by the end of the second year. It is believed that some nerve fibers in the brain and spinal cord do not complete myelination until puberty.

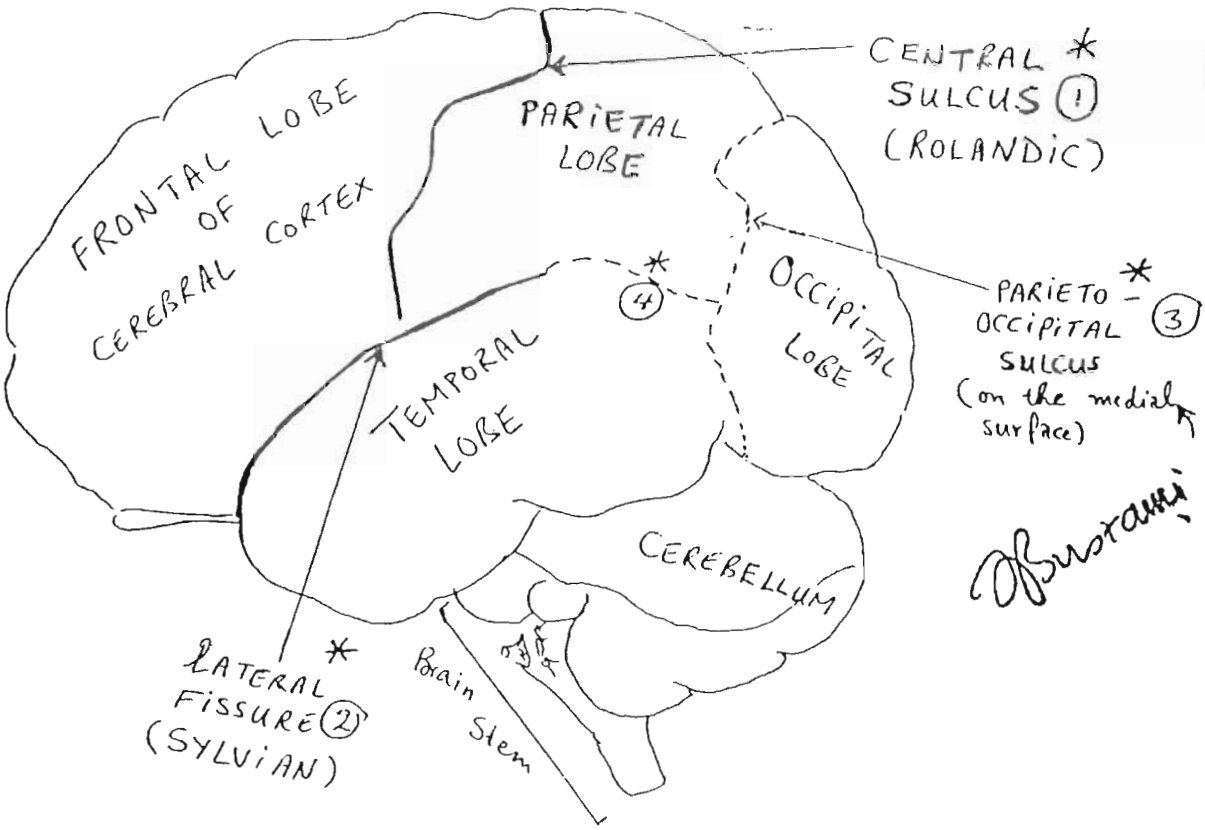

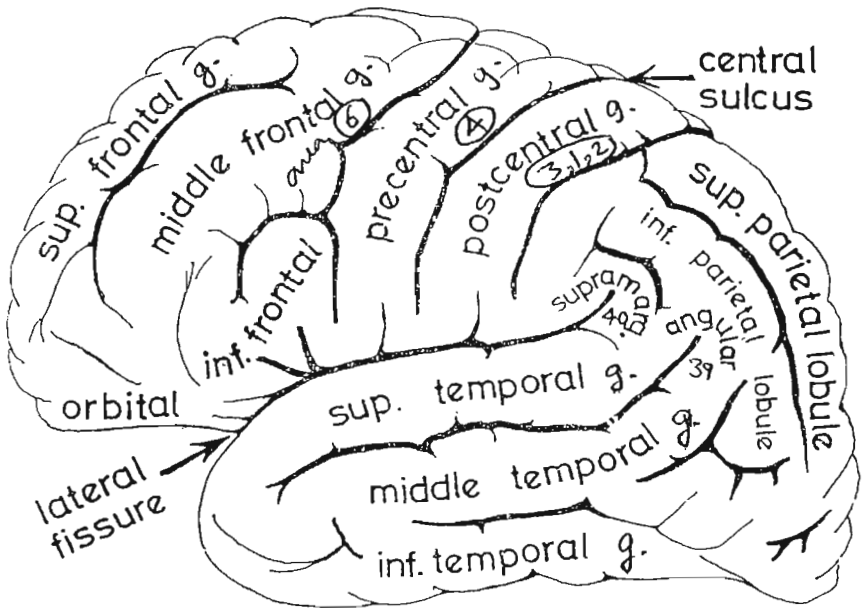

Fig. 48 The gyri of the ateral surface of the cerebral hemisphere.

Precentral gyrus (Frontal lobe) = area 4 = Primary motor cortex

Premotor cortex (frontal lobe) = area 6

Supplementary motor area (SMA) = medial extension of area 6

Postcentral gyrus (parietal lobe) = area 3, 1, 2 = Somatic sensory cortex or Somasthetic cortex

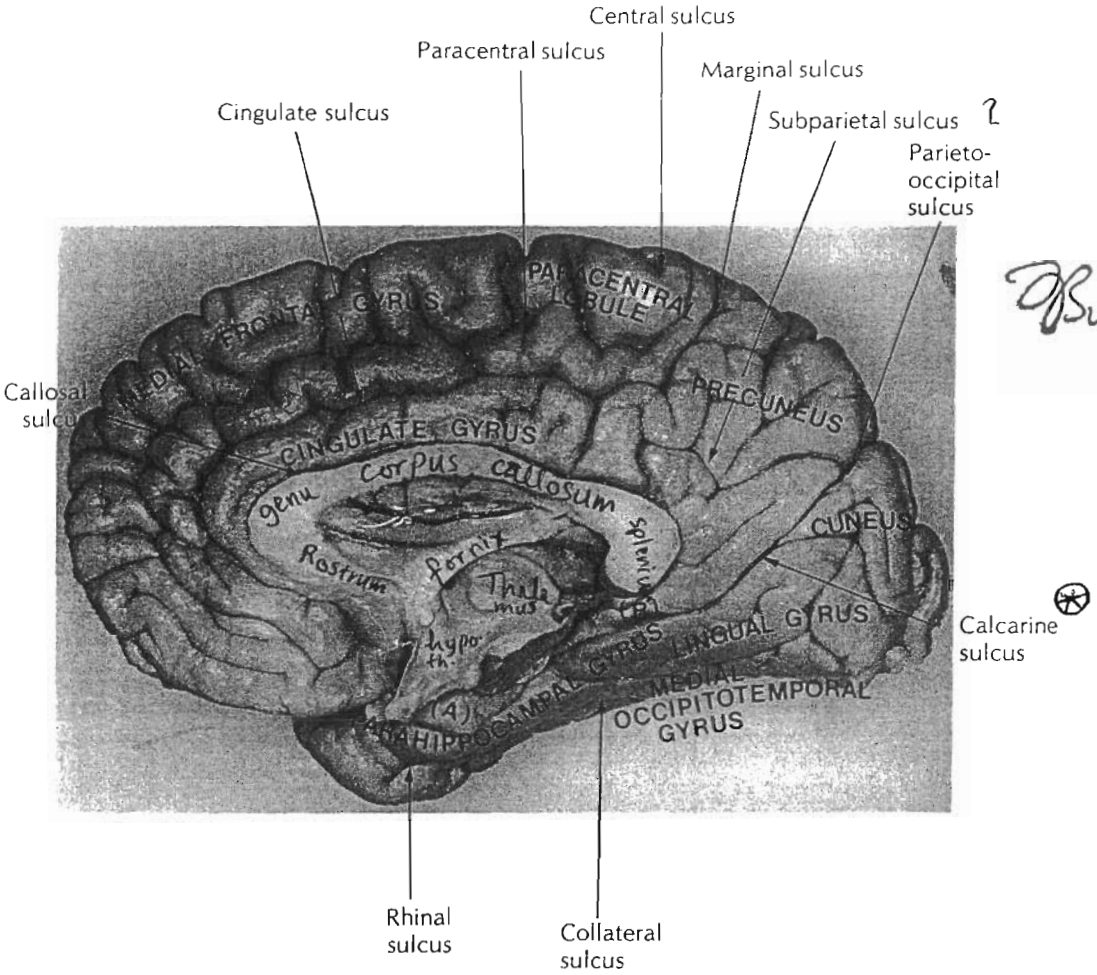

Figure 13-5. Gyri and sulci on the medial and inferior surfaces of the right cerebral hemisphere. (**A**) Uncus. (**B**) Isthmus (retrosplenial cortex) connecting the cingulate and parahippocampal gyri. (× 0.63)

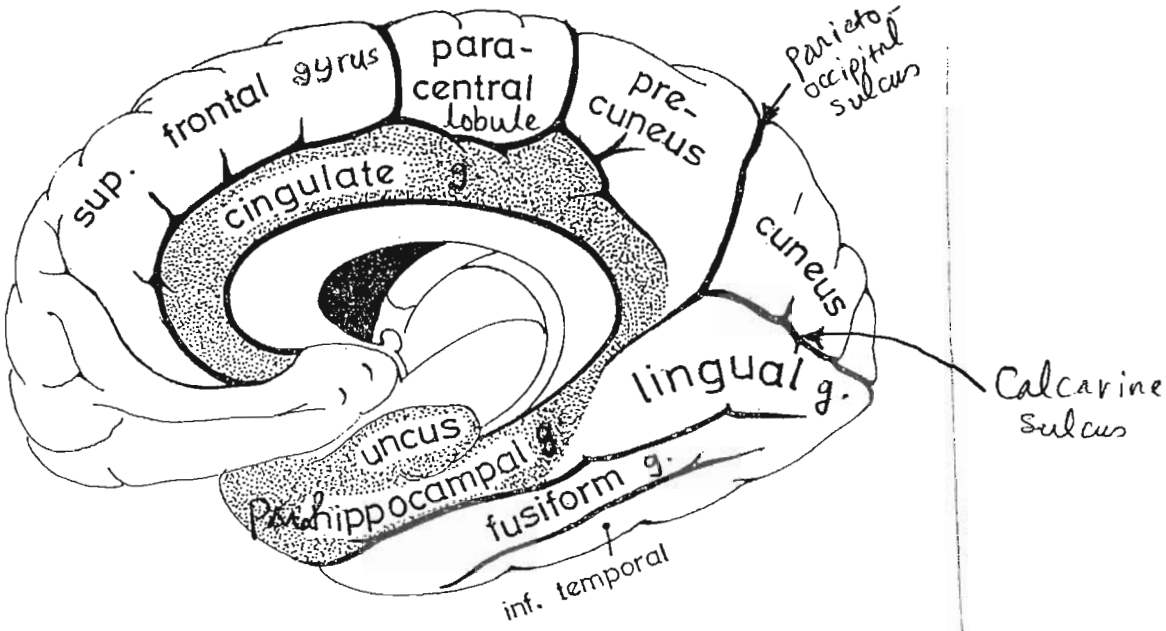

Fig. 53 The gyri of the medial surface of the cerebral hemisphere (The different parts of the limbic lobe are shaded)

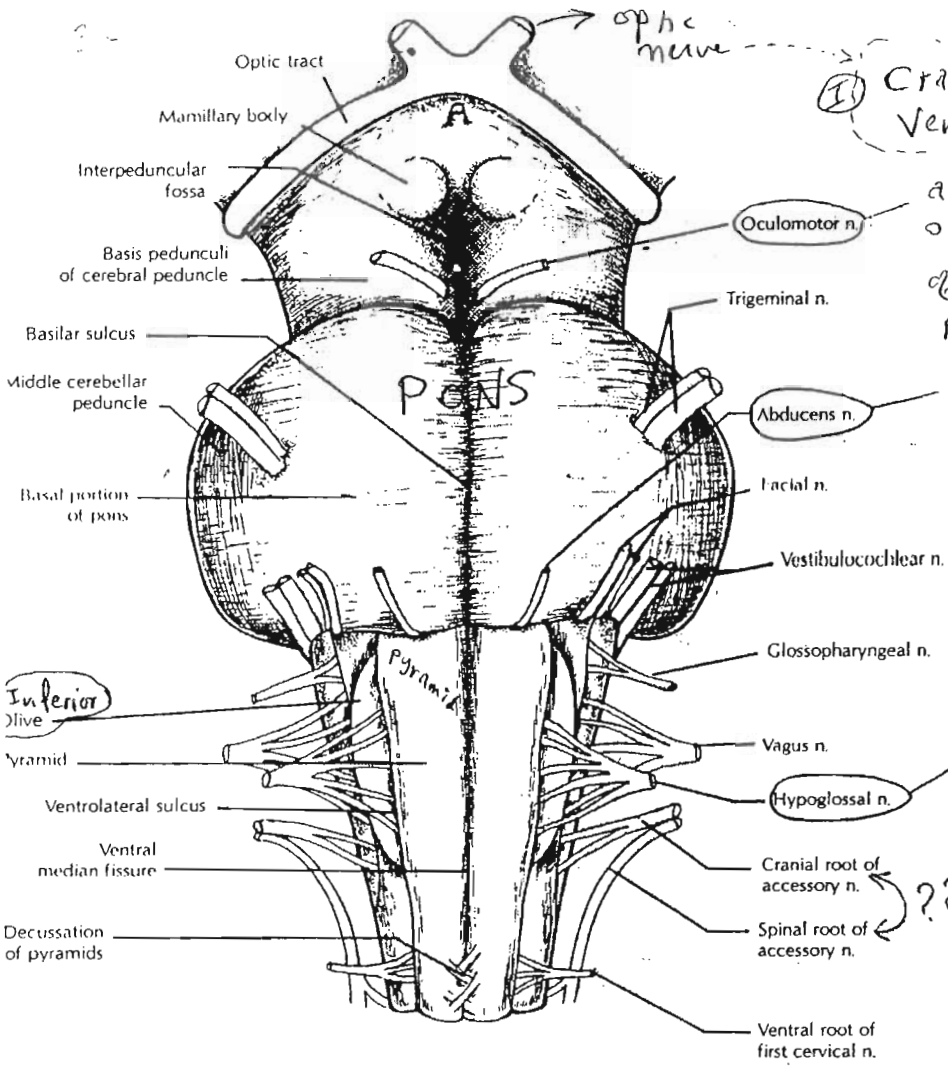

optic nerve

Figure 6–1. Ventral aspect of the brain stem.

(I) Cranial nerves with Ventral attachments

arises from the groove on the medial aspect of the crus cerebri (basis pedunculi) → Midbrain

emerges at the inferior border of the pons immediately lateral to the pyramid

formed by a row of rootlets which arise from the anterior aspect of the medulla in the groove between the pyramid & the olive

???

(II) Cranial nerves with lateral attachment → 5, 7, 8, 9, 10, 11

* The trigeminal nerve (the largest of the cranial nerves) attached to the junction of the pons with the middle cerebellar peduncle and consists of 2 roots: a larger posterolateral sensory root, a smaller anteroposterior motor root

(7+8) * Facial & vestibulocochlear nerve → These 2 nerves with the small nervus intermedius inbetween emerge on the inferior border of the pons posterior to the olive. N.B the facial nerve is motor while the nervus intermedius carries its sensory and parasympathetic fibres. It lies anterior to the vestibulocochlear nerve

(9,10,11) * Glossopharyngeal, vagus & accessory nerves → These nerves arise as a vertical series of rootlets from a groove posterior to the olive in the medulla oblongata

(III) Cranial nerves with dorsal attachment → Trochlear nerve

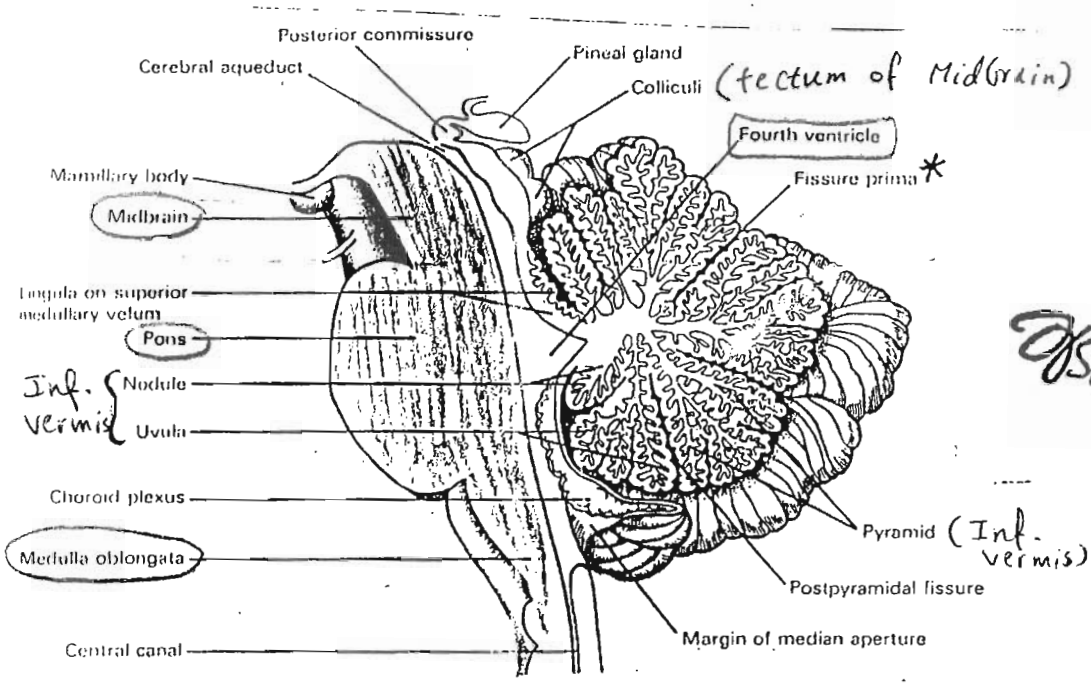

Brostami

Fig. 7.3 Median sagittal section of the cerebellum and brainstem.

- Brainstem
  - Midbrain
  - Pons
  - medulla oblongata
- The contents of each part of the brainstem ?
  - → Ascending and descending tracts
  - → nuclei of certain cranial nerves
    - 3 + 4 → in midbrain
    - 5, 6, 7, 8 → in Pons
    - 9, 10, 11, 12 → in medulla
  - → certain nuclei
    - Red nucleus in midbrain
    - substantia nigra " "
  - → RETICULAR FORMATION
  - → certain vital centres within RF
- hind brain
  - cerebellum
    - Median part → Vermis
    - 2 lateral parts → 2 cerebellar hemispheres
  - Pons
  - medulla oblongata
- 4th ventricle
  - cavity of hind brain
  - boundaries
    - Anteriorly – Posterior surface of Pons + upper part of medulla
    - Posteriorly → cerebellum (indirectly)

Figure 75 Medial view of the brain, arachnoid and pia mater removed. Median section (×1.5)

A. Medial frontal gyrus
B. Cingulate sulcus
C. Cingulate gyrus
D. Isthmus of cingulate gyrus
E. Parieto-occipital sulcus
F. Cuneus
G. Calcarine sulcus
H. Lingual gyrus
I. Interventricular foramen
J. Thalamus
K. Hypothalamic sulcus (position of)
L. Hypothalamus
M. Optic recess of third ventricle
N. Optic chiasma
O. Infundibulum and infundibular recess of third ventricle
P. Tuber cinereum
Q. Mamillary body
R. Posterior commissure
S. Superior colliculus } Tectum of midbrain
T. Inferior colliculus
U. Cerebral peduncle of midbrain
V. Pons (anterior or basilar part)
W. Medulla
X. Cerebellum (vermis)
Y. Cerebellum (hemisphere)
Z. Pons (tegmentum or posterior part)

Can you locate:

Corpus callosum (rostrum, genu, trunk, splenium)
Fornix
Anterior commissure
Pineal recess of third ventricle
Cerebral aqueduct
Fourth ventricle
Pineal body

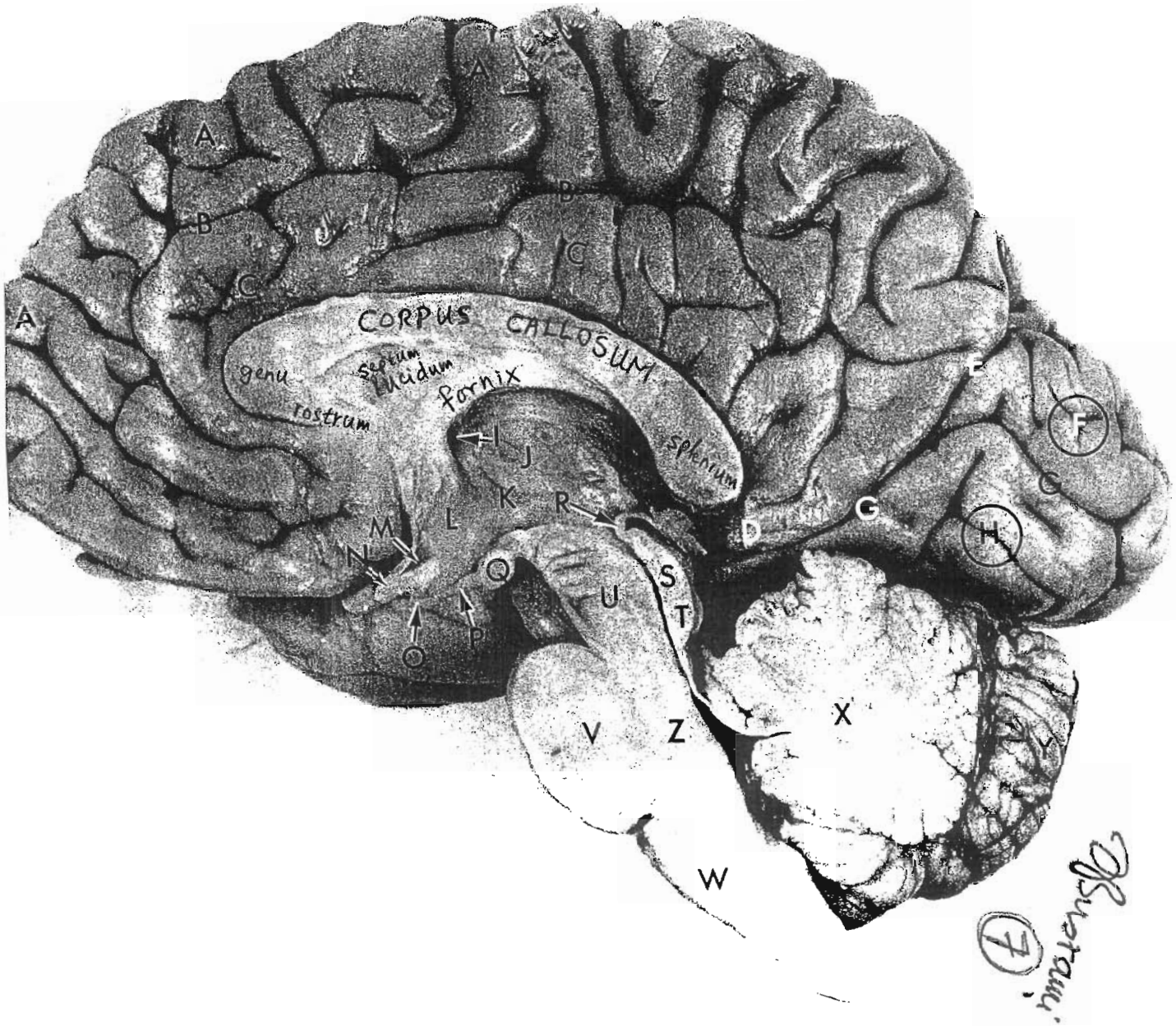

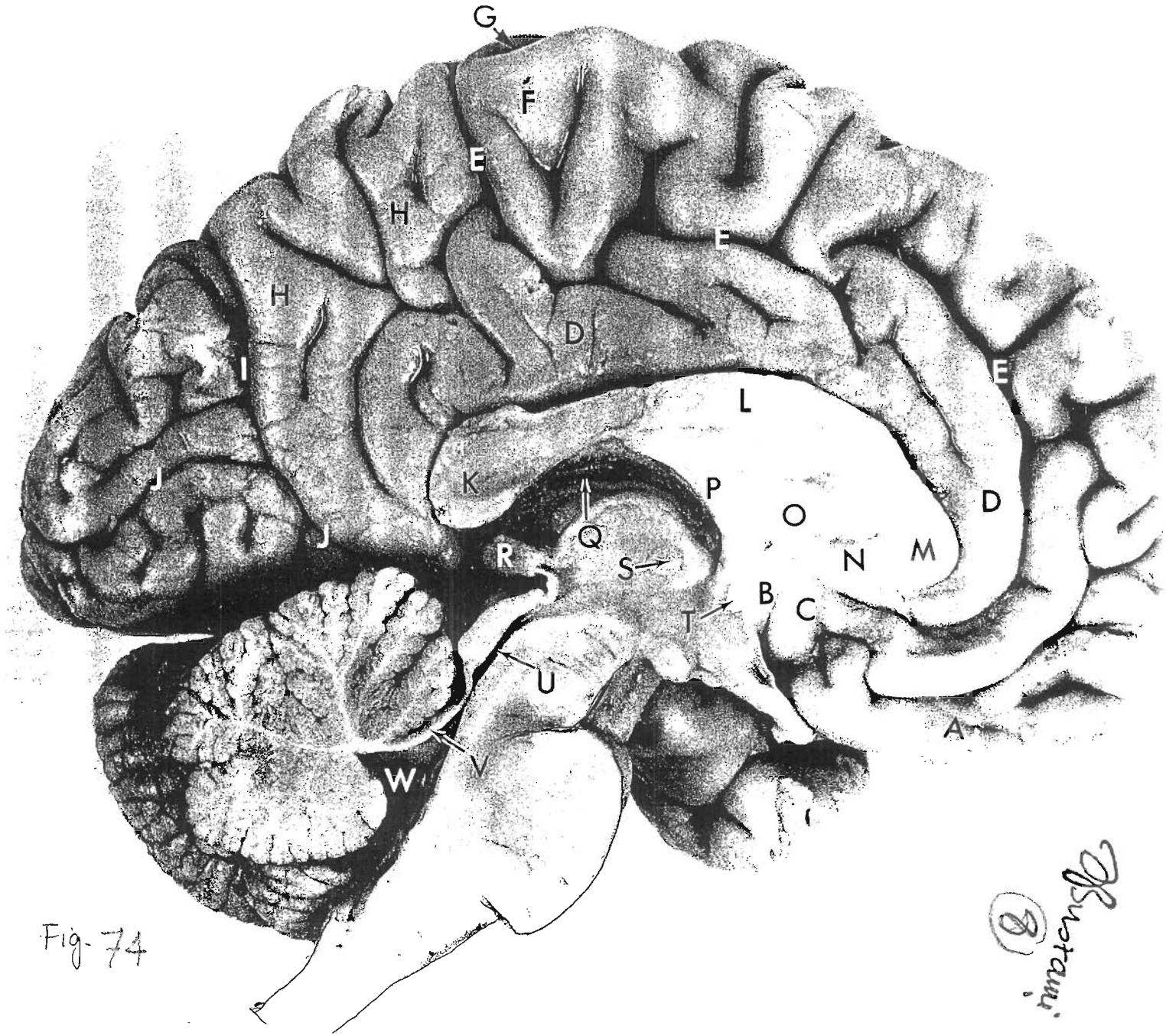

Fig. 74

Figure 74 **Medial view of the brain, arachnoid and pia mater removed. Median section (×1.5)**

A. Straight gyrus (gyrus rectus)
B. Paraterminal gyrus
C. Subcallosal area
D. Cingulate gyrus
E. Cingulate sulcus (and its marginal ramus)
F. Paracentral lobule
G. Central sulcus
H. Precuneus
I. Parieto-occipital sulcus
J. Calcarine sulcus
K. Splenium of corpus callosum
L. Trunk of corpus callosum
M. Genu of corpus callosum
N. Rostrum of corpus callosum
O. Septum pellucidum
P. Body of fornix
Q. Choroid plexus of lateral ventricle
R. Pineal body
S. Interthalamic adhesion
T. Anterior commissure
U. Cerebral aqueduct
V. Superior medullary velum
W. Fourth ventricle

Can you locate:

Medial frontal gyrus
Cuneus
Lingual gyrus
Interventricular foramen
Thalamus and hypothalamus
Optic nerve and chiasma
Optic recess of third ventricle
Midbrain (cerebral peduncle and tectum)
Pons
Medulla
Posterior commissure

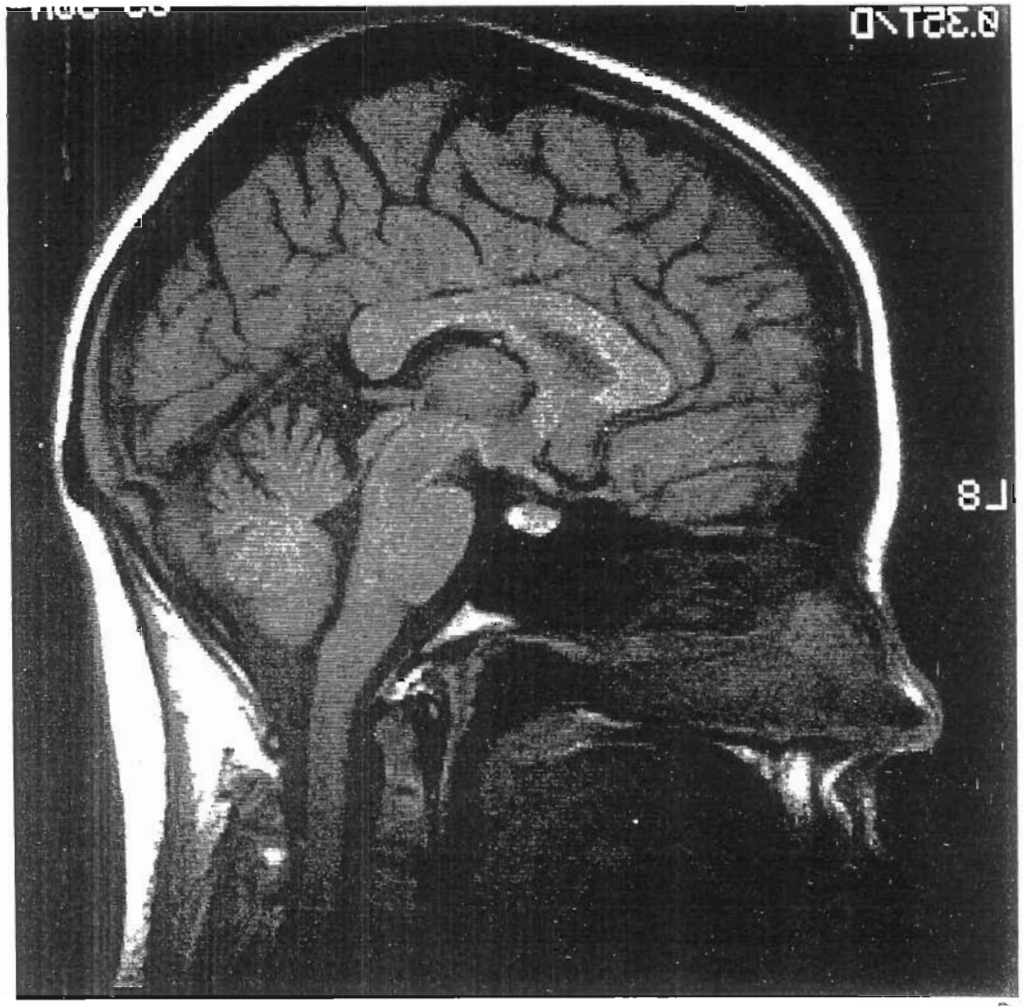

Normal T1-weighted MRI scan

(10)

J Bustami

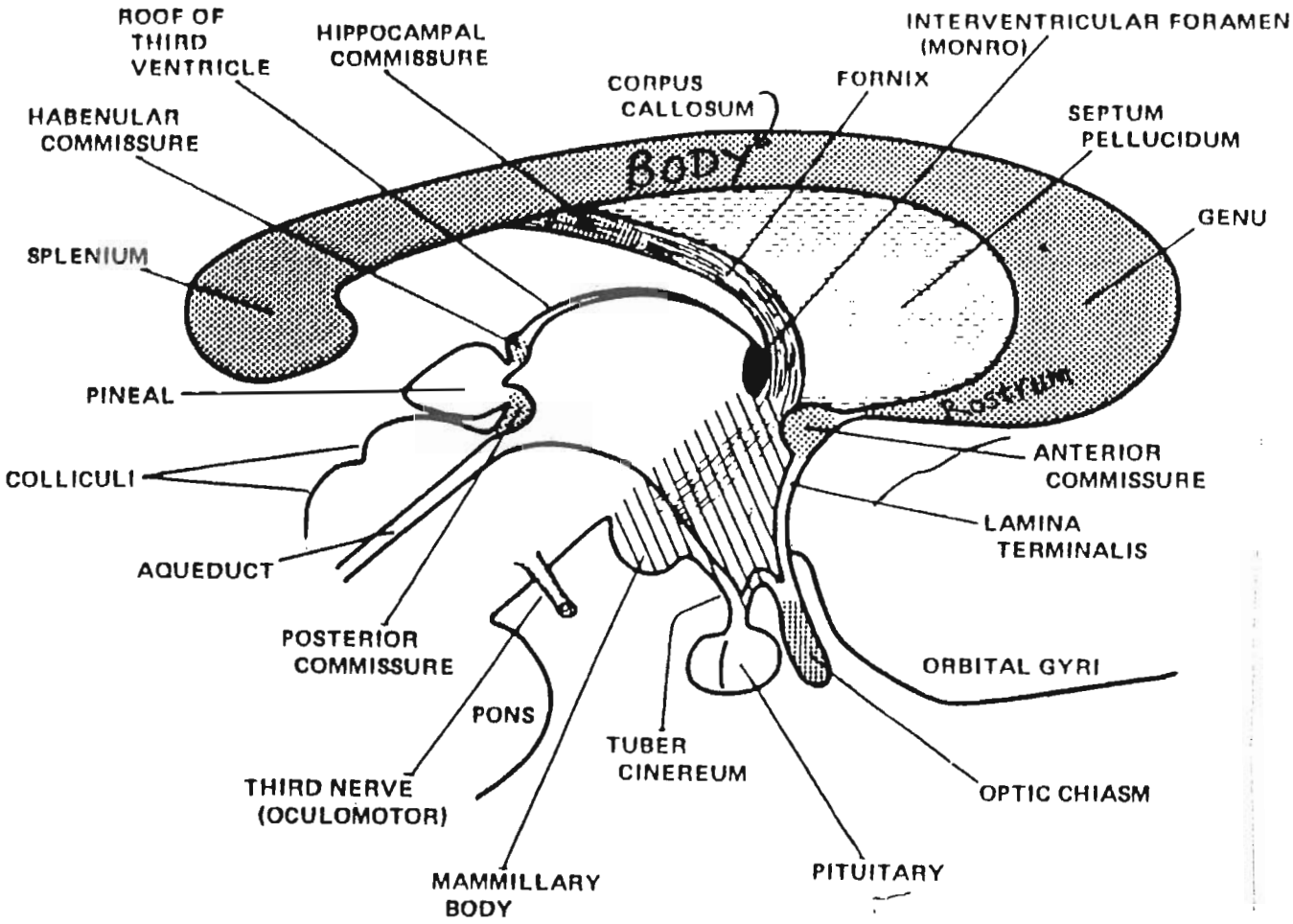
ROOF OF THIRD VENTRICLE
HIPPOCAMPAL COMMISSURE
INTERVENTRICULAR FORAMEN (MONRO)
CORPUS CALLOSUM
FORNIX
HABENULAR COMMISSURE
SEPTUM PELLUCIDUM
BODY
GENU
SPLENIUM
PINEAL
Rostrum
ANTERIOR COMMISSURE
COLLICULI
LAMINA TERMINALIS
AQUEDUCT
POSTERIOR COMMISSURE
ORBITAL GYRI
PONS
TUBER CINEREUM
THIRD NERVE (OCULOMOTOR)
OPTIC CHIASM
MAMMILLARY BODY
PITUITARY

White matter of Cerebrum

Bustami

I Corpus callosum : Large commisural fibres

- Connect the two hemispheres
- Froceps minor connects the two frontal lobes
- Tapetum connects the two pariatal and two temporal lobes
- Forceps major connects the two occipital lobes.

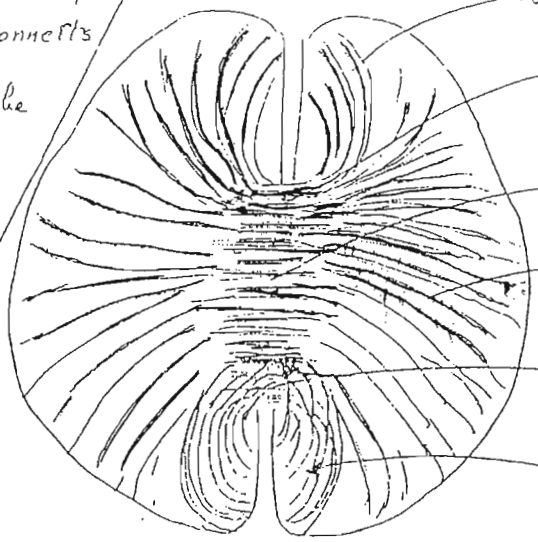

II Projection fibres

Internal capsule

1. Ant. limb : Contains
   a) fronto pontine fibres
   b) ant. thalamic fibres
2. Genu : Corticobulbar
3. Post. limb : three parts
   a) Lentiform part :
      1. Corticospinal tract.
      2. Sensory radiation (middle thalamic fibres)
   B) Retrolentiform part
      1. visual radiation
      2. occipitopontin
   C) Sublentiform part
      1. auditory radiation
      2. temporopontine

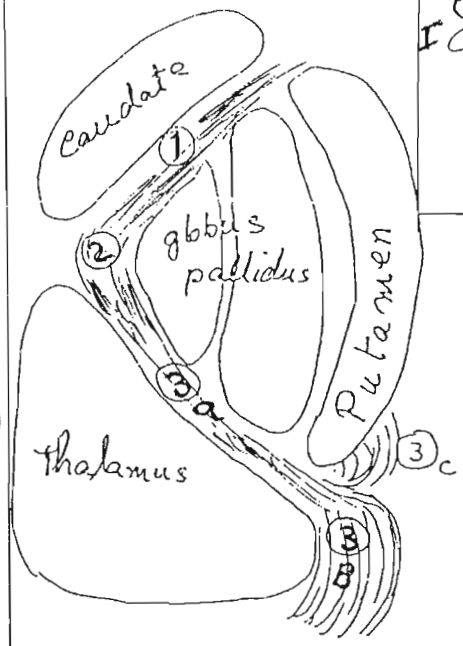

Corpus striatum (Basal ganglia)

I Caudate (head-body and tail).

II lentiform (Putamen and globus pallidus

Osorano

III. Association fibres : are the fibres that connect the gyri of hemisphere
- short : from one gyrus to another.
- long : connect the gyrus with a very large number of other gyri of the same hemisphere

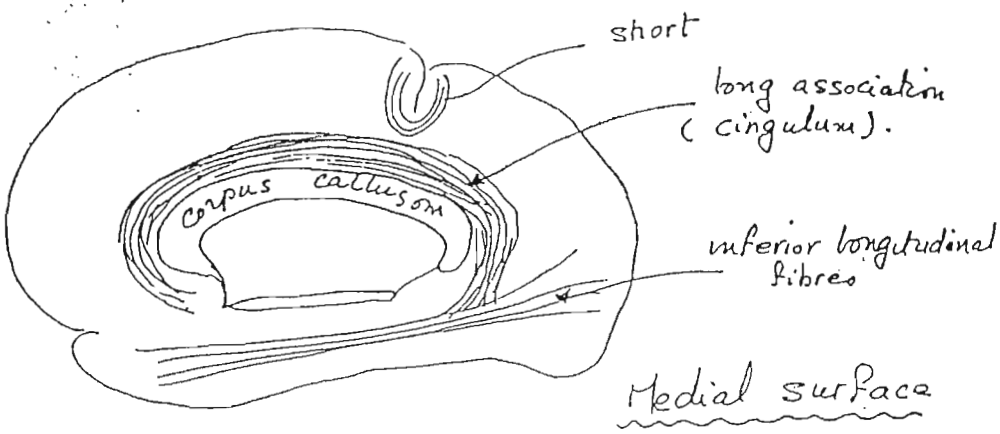

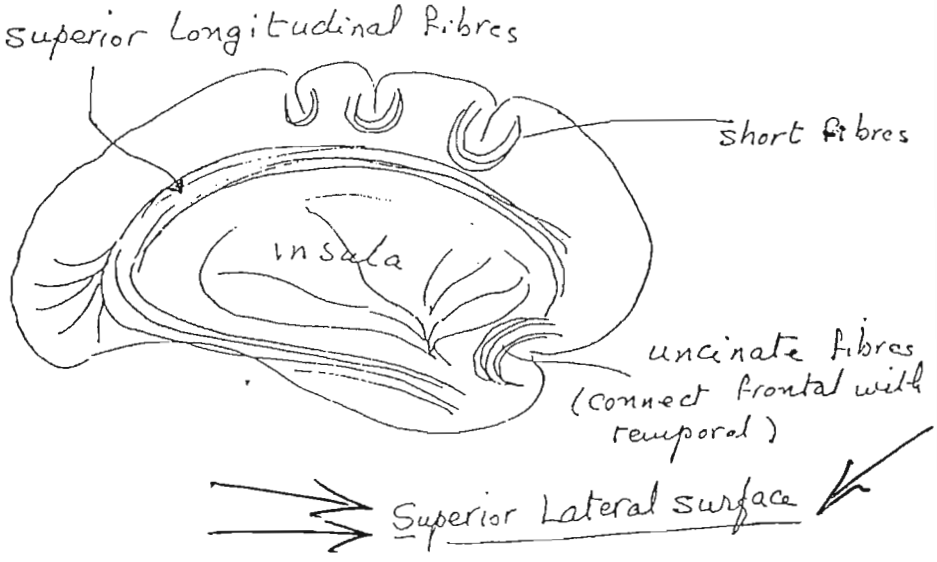

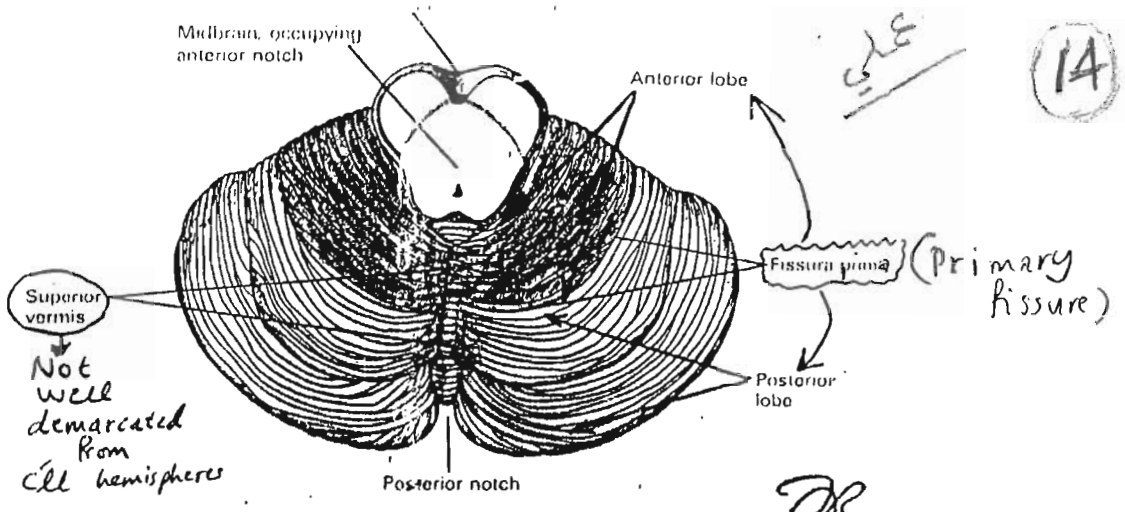

Fig. 7.1 Superior surface of the cerebellum.

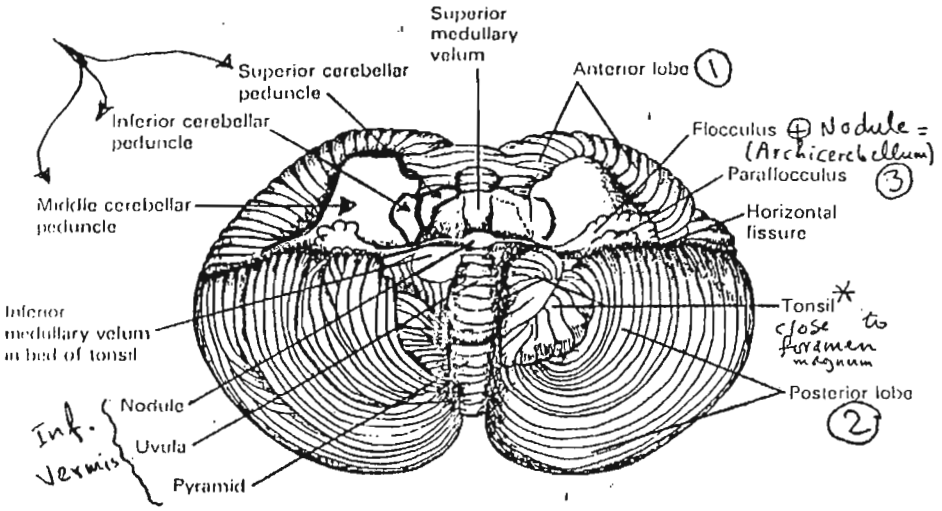

Fig. 7.2 Anteroventral surface of the cerebellum. The right tonsil of the cerebellum has been removed to show the inferior medullary velum.

Cerebellar peduncles (see Figure 1.7)

(1) Inferior cerebellar peduncle

–connects the cerebellum to the medulla.
- consists of two divisions:

a. Restiform body

–is an afferent fiber system containing:
(1) Dorsal spinocerebellar tract
(2) Cuneocerebellar tract
(3) Olivocerebellar tract

b. Juxtarestiform body

–contains afferent and efferent fibers:
(1) Vestibulocerebellar fibers (afferent)
(2) Cerebellovestibular fibers (efferent)

(2) Middle cerebellar peduncle (Brachium Pontis)

–connects the cerebellum to the pons.
–is an afferent fiber system containing **pontocerebellar fibers** to the neocerebellum.
- formed of axons of Pontine nuclei of opposite side

(3.) Superior Cll Peduncle
- connect Cll to midbrain
- represents major output from the Cll
- contains the Dentatorubrothalamic tract (+ other components)

علي

15

Fig. 12-4. Motor areas of the cerebral cortex.

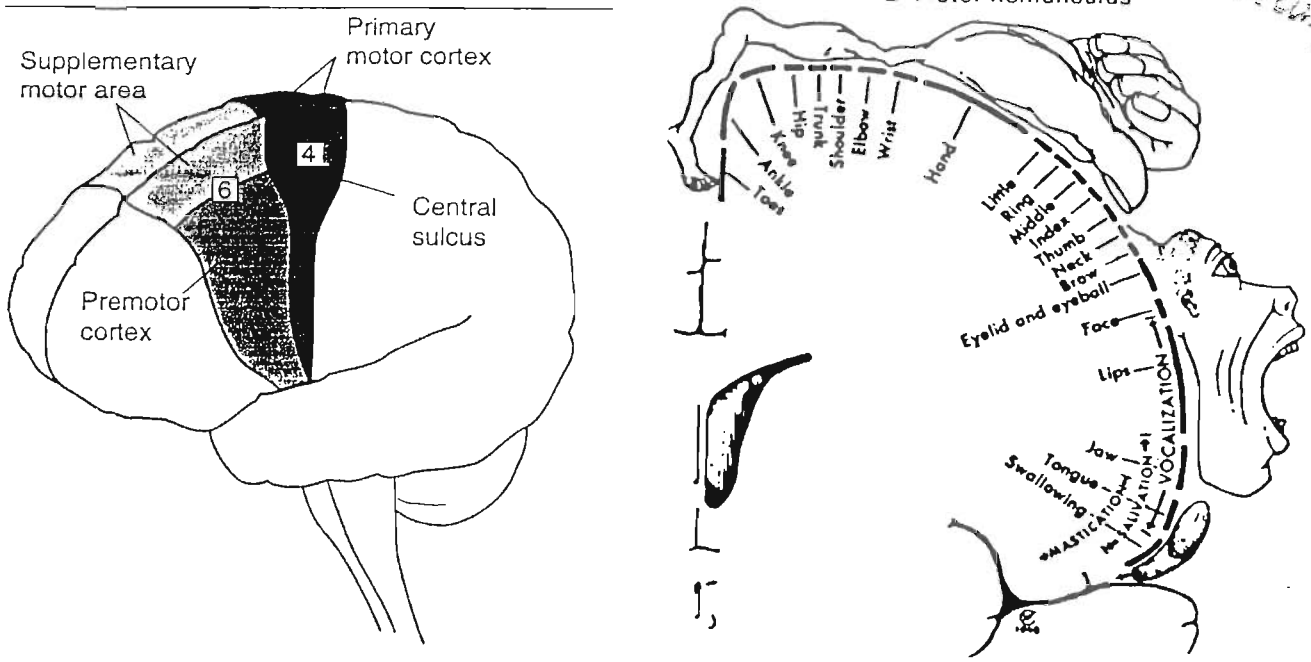

B. Motor areas

1. Primary motor cortex (area 4)

- is located in the **precentral gyrus** and in the anterior part of the **paracentral lobule** (on the medial surface) → lower limb ⊕ sphincters
- *contributes to the corticospinal tract.
- is somatotopically organized as the **motor homunculus** (see Figure 23.2*B*). → (Face & limbs) are represented here
- contains the giant cells of Betz in layer V.
- stimulation results in contralateral movements of voluntary muscles.
- ablation results in a **contralateral upper motor neuron lesion.**
- bilateral lesions of the paracentral lobule (e.g., parasagittal meningiomas) result in **urinary incontinence.**
- lesion in area 4 → flaccid paralysis of distal muscles of limbs ⊕ hypotonia ⊕ decreased muscle stretch reflexes → when the sphere of lesion is increased to include premotor area 6 (in which trunk and axial muscles are represented) → loss of control over brainstem centres generates a state of spasticity that overshadows flaccidity

2. Premotor cortex (area 6)

- is located anterior to the precentral gyrus.
- *contributes to the corticospinal tract.
- plays a role in the **control of proximal and axial muscles;** it prepares the motor cortex for specific movements in advance of their execution.
- stimulation results in adversive movements of the head and trunk and flexion and extension of the extremities.
- plays a role in planning & execution of movement
- lesion → appearance of (grasp response) → look at page 24

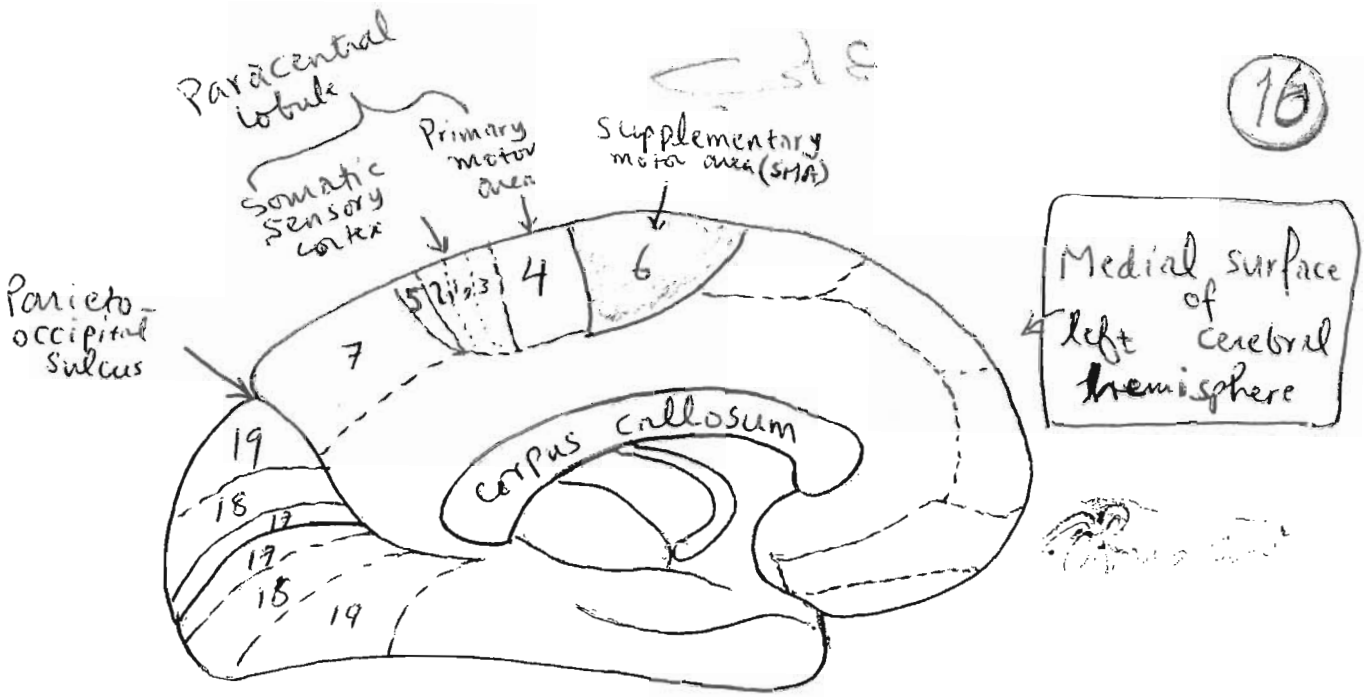

3. Supplementary motor cortex (area 6)

- is located on the medial surface of the hemisphere anterior to the paracentral lobule.
- ✱ contributes to the corticospinal tract.
- plays a role in **programming complex motor sequences** and in **coordinating bilateral movements;** it regulates the somatosensory input into the motor cortex.

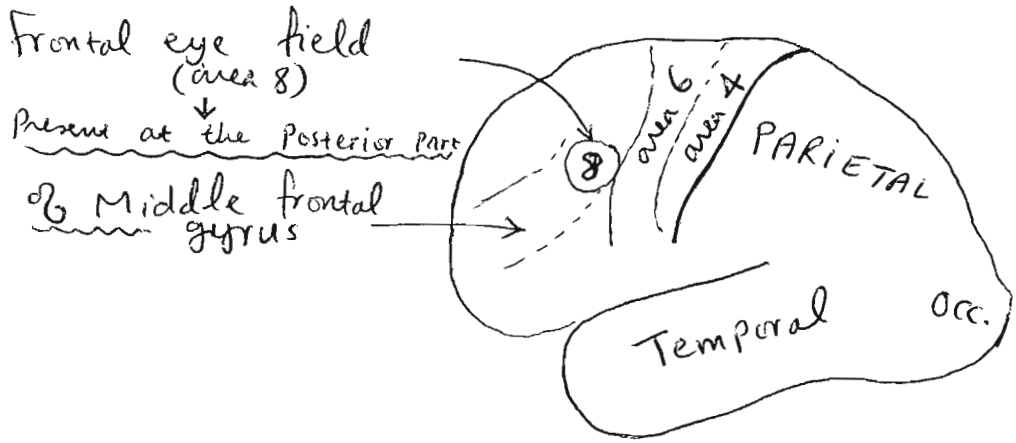

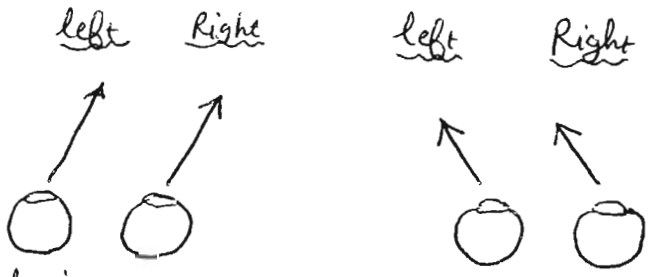

Destructive lesion of Rt. frontal eye field → conjugate deviation of the eyes toward the side of the lesion (Rt.)

Stimulation (irritative lesion) of frontal eye field → conjugate deviation of eyes to the opposite side (in the diagram stimulation of Rt. frontal eye field)

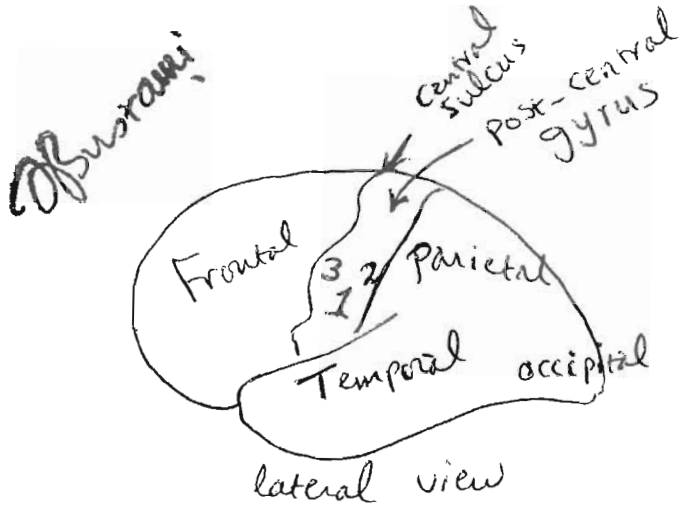

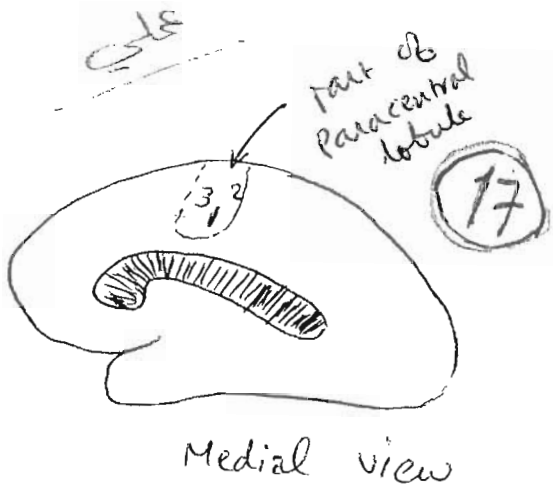

- Primary Somatosensory cortex (area 3, 1, and 2)
- location → in the post-central gyrus (parietal lobe) and in the posterior part of the paracentral lobule (on medial surface)
- Somatotopically organized as the **Sensory homunculus**

A Sensory homunculus

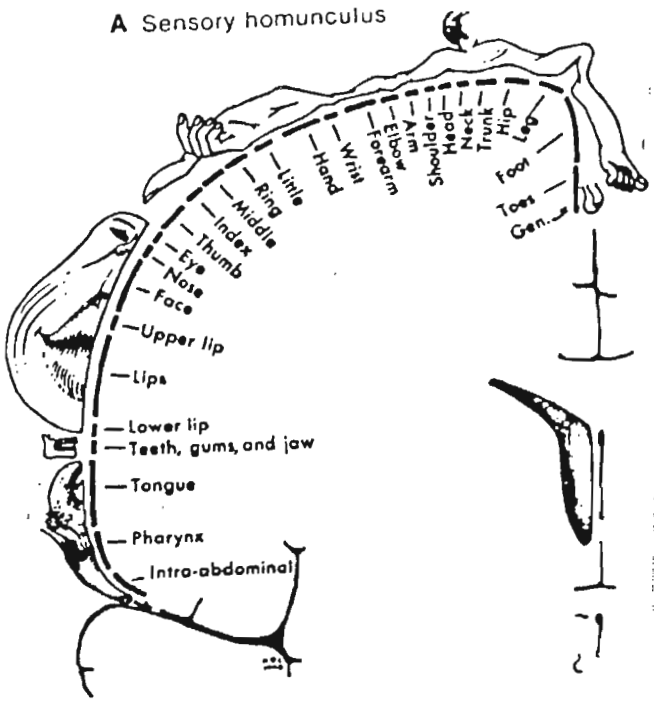

→ The contralateral half of the body is represented in a precise but disproportionate manner in the somatosensory cortex I

↓

The representation of the face, lips, hand, thumb, index finger is disproportionately large in comparison with their relative size in the body. This is a reflection of the functional importance of these parts in sensory function.

↓

The 1ry somatosensory cortex is formed of functional units which are modality specific → each unit is in the form of a vertical column of cells

- Neurons within a cortical unit are activated by the same peripheral stimulus and are related to the same receptive field e.g area 3 is activated by cutaneous stimuli (pain, temperature, touch) whereas area 2 receives proprioceptive impulses (from muscles, tendons & joints)

(3b + 1 = cutaneous input) (3a + 2 = proprioceptive)

Lesion of area 3,1,2 (Primary Somatosensory area) → contralateral loss of all types of sensations, Soon, however pain & temperature sensations will return → It is beleived that pain & temperature sensations are determined at thalamic level Whereas { source, severity, quality } of such sensations are perceived at Postcentral gyrus (3,1,2)

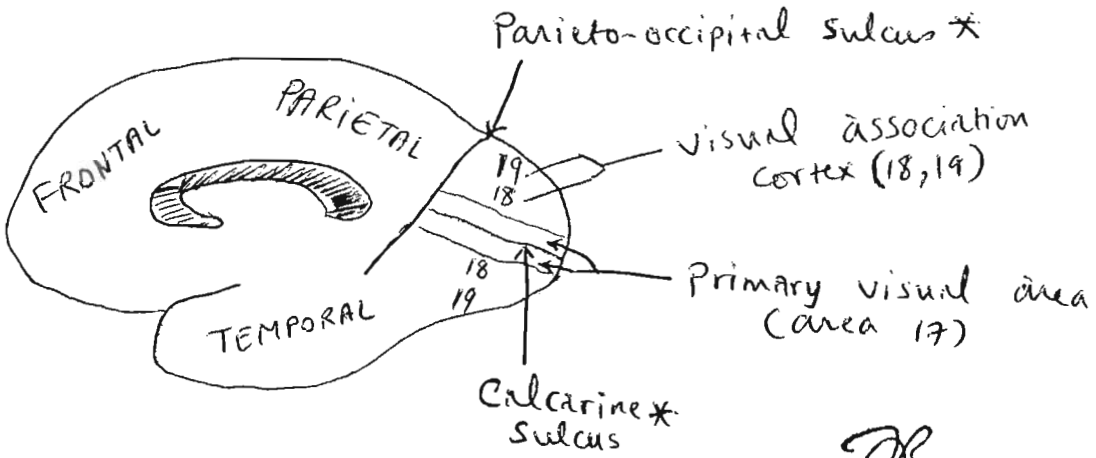



Visual cortex → Cuneus (above) ⊕ lingual gyrus (below) the calcarine sulcus

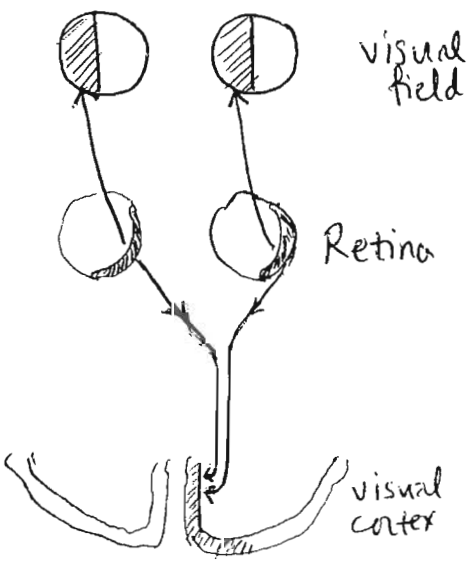

- Each Primary visual cortex receives fibres from the ipsilateral half of each retina which convey information about the contralateral half of the visual field
- lesion of area 17 → Defects in visual field
- lesion of areas 18,19 → visual agnosia (patient is able to see objects but is unable to recognize them)

The Cerebrospinal Fluid, the Ventricles of the Brain, and the Brain Barriers

19

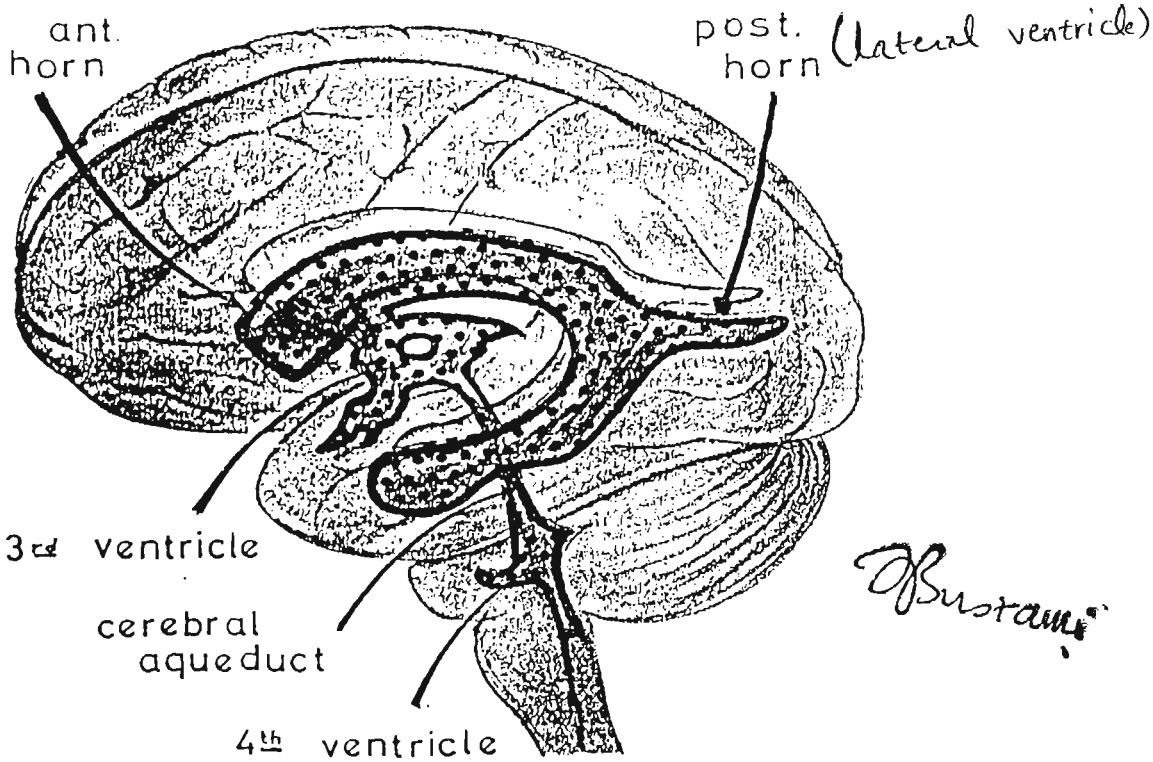

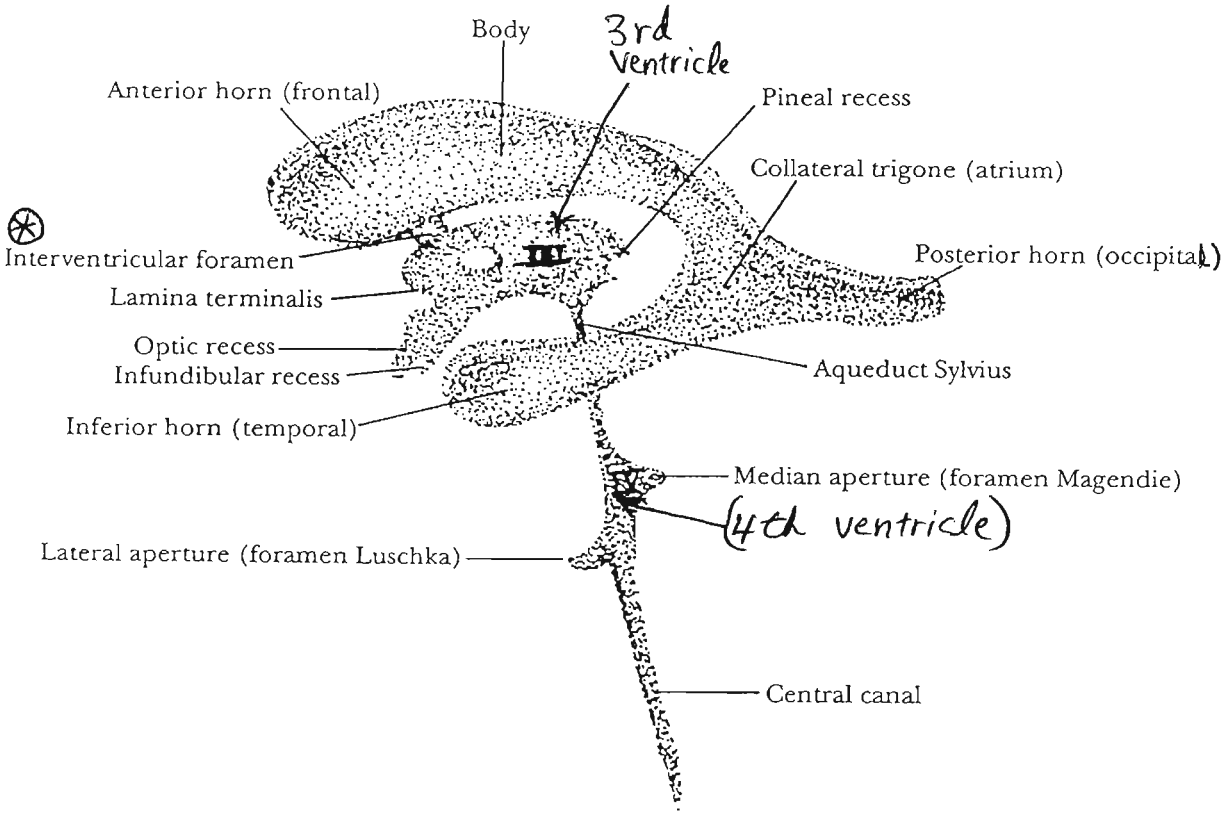

Ventricles – lateral view

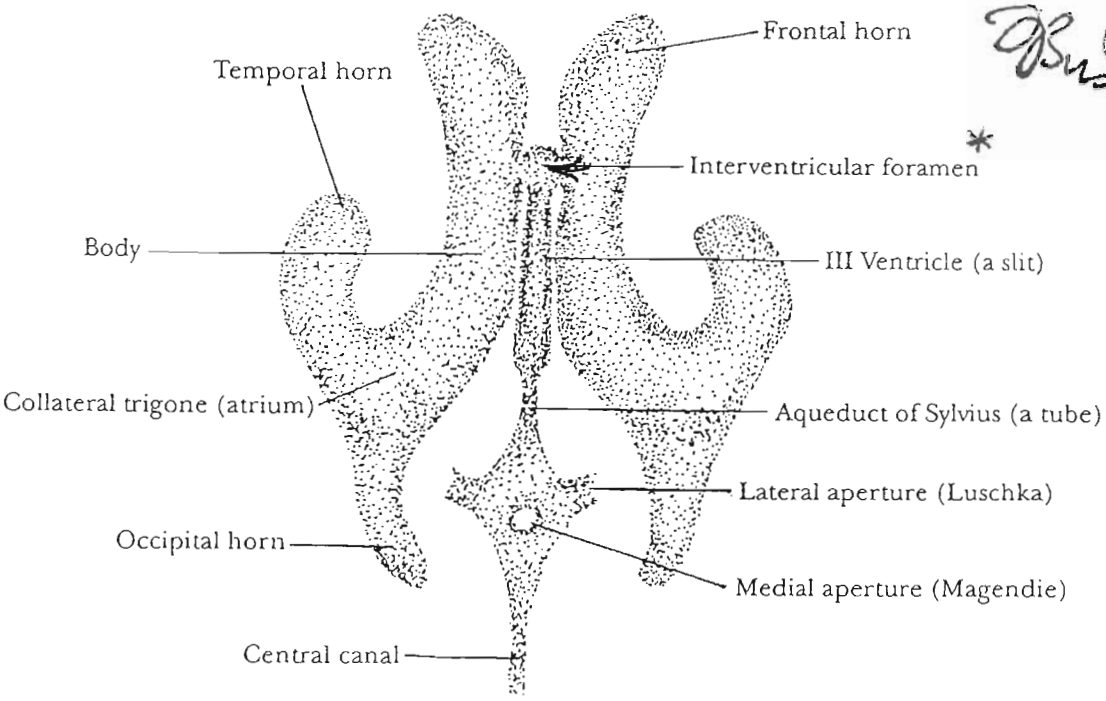

Ventricles – dorsal view

TABLE 3–6. Composition of CSF

[CSF] ≈ [Blood]	[CSF] < [Blood]	[CSF] > [Blood]
Na^+	K^+	Mg^{2+}
Cl^-	Ca^{2+}	Creatinine
HCO_3^-	Glucose	
Osmolarity	Cholesterol*	
	Protein*	

* Negligible in CSF.

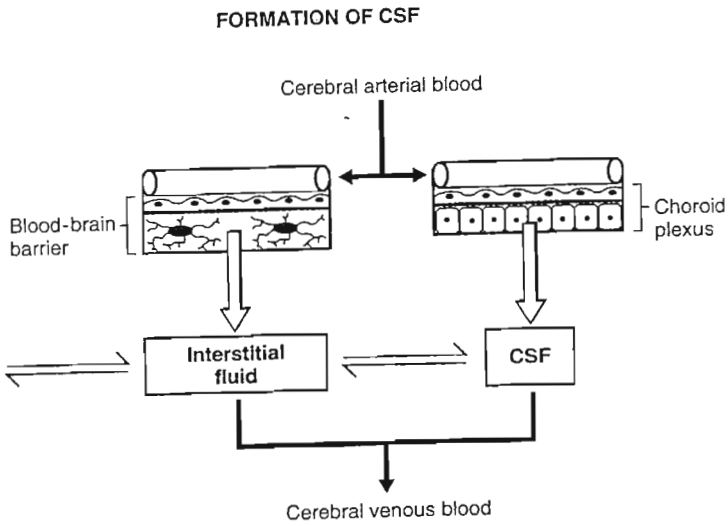

FIGURE 3–35. Mechanism for production of cerebrospinal fluid. CSF, cerebrospinal fluid.

The barrier between cerebral capillary blood and CSF is the **choroid plexus**. This barrier consists of three layers: capillary endothelial cells and basement membrane, neuroglial membrane, and epithelial cells of the choroid plexus. The choroid plexus epithelial cells are similar to those of the renal distal tubule and contain transport mechanisms that move solutes and fluid from capillary blood into CSF.

The barrier between cerebral capillary blood and interstitial fluid of the brain is the **blood-brain barrier**. Anatomically, the blood-brain barrier consists of capillary endothelial cells and basement membrane, neuroglial membrane, and glial end feet (projections of astrocytes from the brain side of the barrier). Functionally, the blood-brain barrier differs in two ways from the analogous barrier in other tissues. (1) The junctions between endothelial cells in the brain are so "tight" that few substances can cross *between* the cells. (2) Only a few substances can pass *through* the endothelial cells: Lipid-soluble substances (e.g., oxygen and carbon dioxide) can cross the blood-brain barrier, but water-soluble substances are excluded.

Formation of CSF

CSF is formed by the epithelial cells of the choroid plexus. Transport mechanisms in these cells secrete some substances from blood into CSF and absorb other substances from CSF into blood. Molecules such as protein and cholesterol are excluded from CSF because of their large molecular size. On the other hand, lipid-soluble substances such as oxygen and carbon dioxide move freely and equilibrate between the two compartments. Thus, depending on the transport mechanisms and the characteristics of the barrier, some substances are present in higher concentration in CSF than in blood, some are present at approximately the same concentration, and some are present in lower concentration in CSF than in blood. Many substances readily exchange between brain interstitial fluid and CSF (see Figure 3–35), thus the compositions of interstitial fluid and CSF are similar to each other but different from blood. Table 3–6 compares the composition of CSF and blood.

MENINGES :
Dura Mater, Arachnoid, & Pia Mater

21

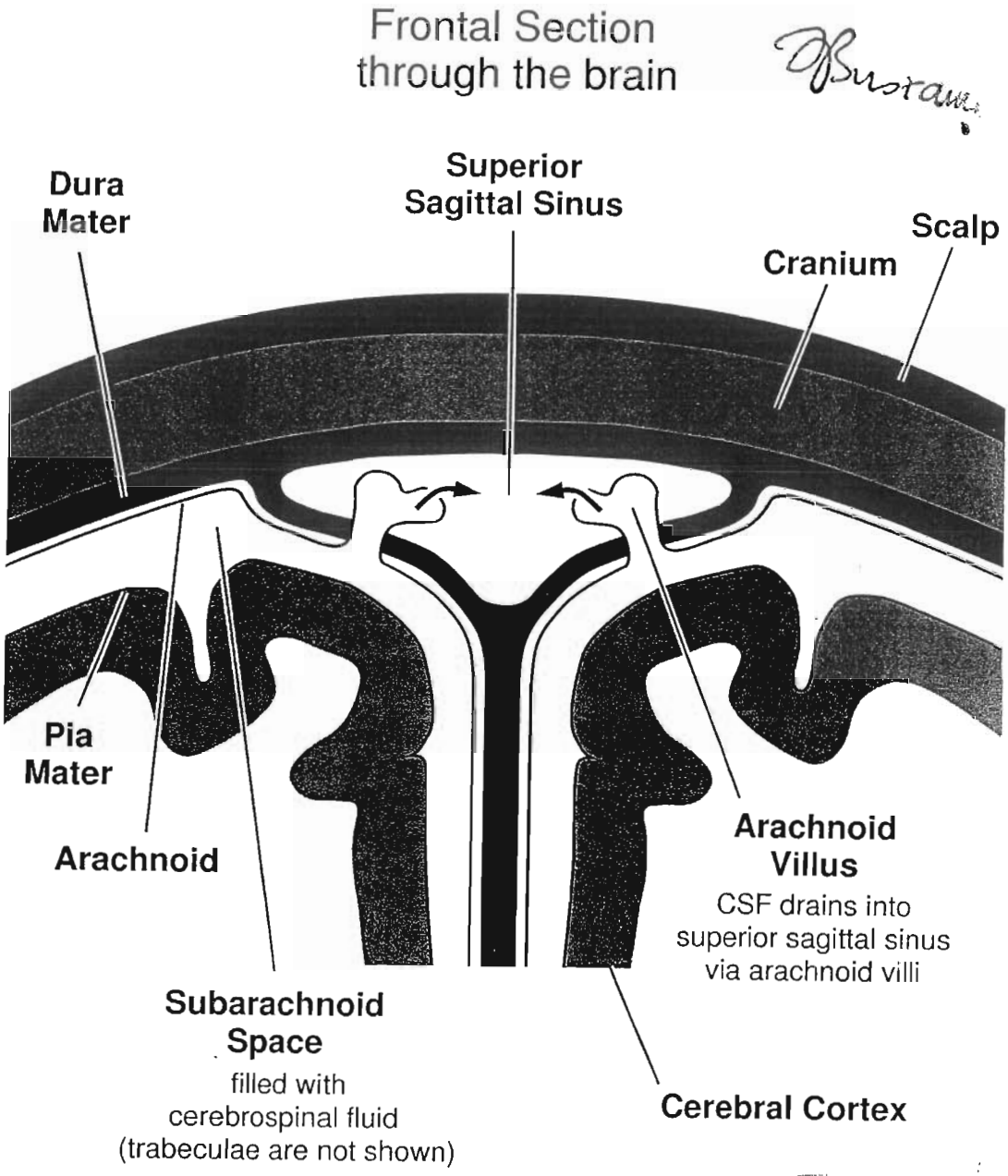

ABSORPTION OF CEREBROSPINAL FLUID

The cerebrospinal fluid is absorbed into the **arachnoid villi** that project into the dural venous sinuses, especially the **superior sagittal sinus** (Fig. 17-1). The arachnoid villi are grouped together to form **arachnoid granulations.** Each arachnoid villus is a diverticulum of the subarachnoid space that pierces the dura mater.

Absorption of cerebrospinal fluid into the venous sinuses occurs when the cerebrospinal fluid pressure exceeds that in the sinus. Studies of the arachnoid villi indicate that fine tubules lined with endothelium permit a direct flow of fluid from the subarachnoid space into the lumen of the venous sinuses. Should the venous pressure rise and exceed the cerebrospinal fluid pressure, compression of the villi closes the tubules and prevents the reflux of blood into the subarachnoid space.

Some of the cerebrospinal fluid is absorbed directly into the veins in the subarachnoid space and escapes through the perineural lymph vessels of the cranial and spinal nerves.

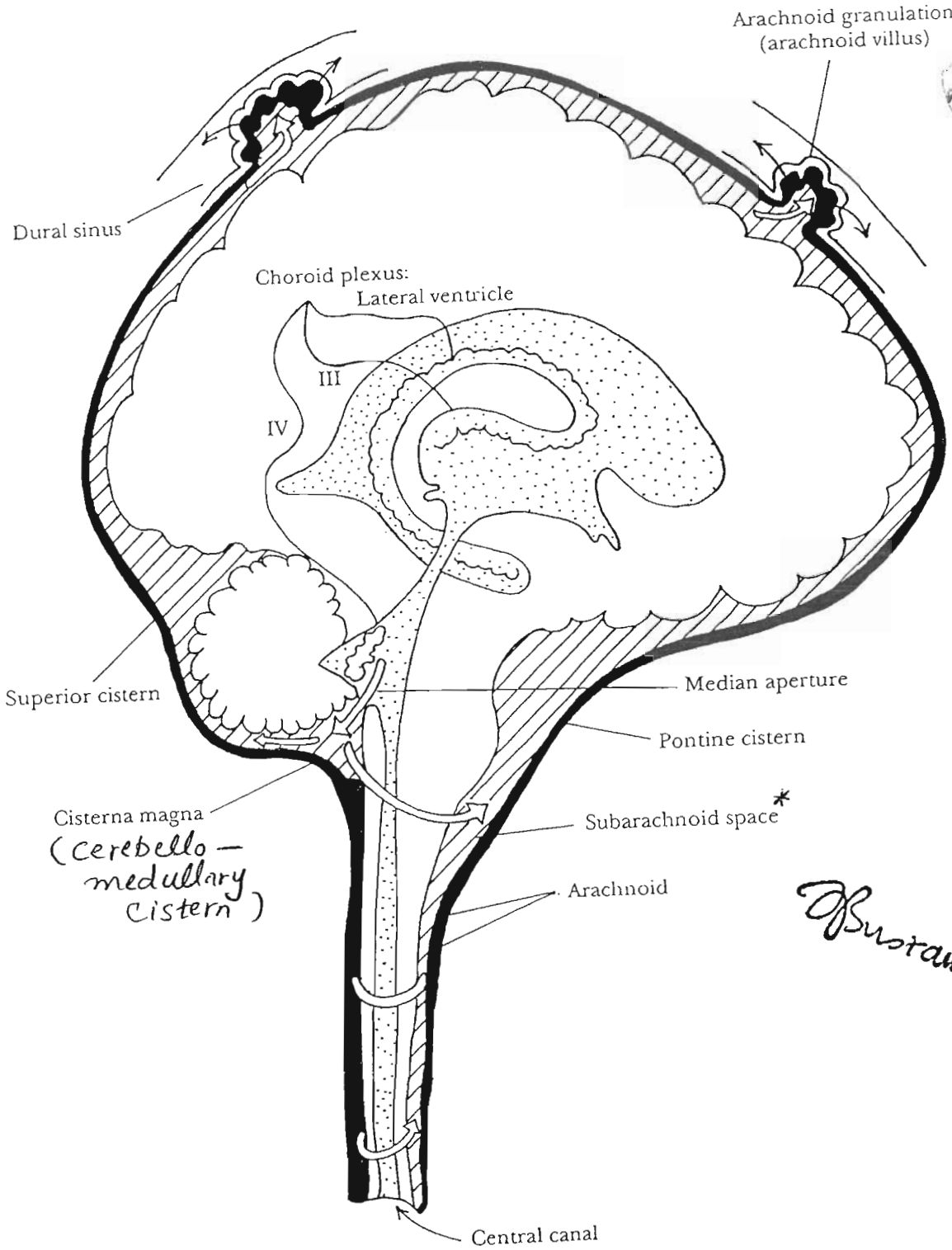

SUBARACHNOID SPACE

The subarachnoid space is the interval between the arachnoid mater and pia mater and envelops the brain and spinal cord (Fig. 17-1). The space is filled with cerebrospinal fluid and contains the large blood vessels of the brain. Inferiorly, the subarachnoid space extends beyond the lower end of the spinal cord and invests the **cauda equina.** The subarachnoid space ends below at the level of the interval between the second and third sacral vertebrae.

Subarachnoid Cisterns. In certain locations around the base of the brain, the arachnoid does not closely follow the surface of the brain so that the subarachnoid space expands to form cisterns. The **cerebellomedullary cistern** lies between the cerebellum and the medulla oblongata, the **pontine cistern** lies on the anterior surface of the pons, and the **interpeduncular cistern** lies on the anterior surface of the midbrain between the crura cerebri.

The circulation of the cerebrospinal fluid

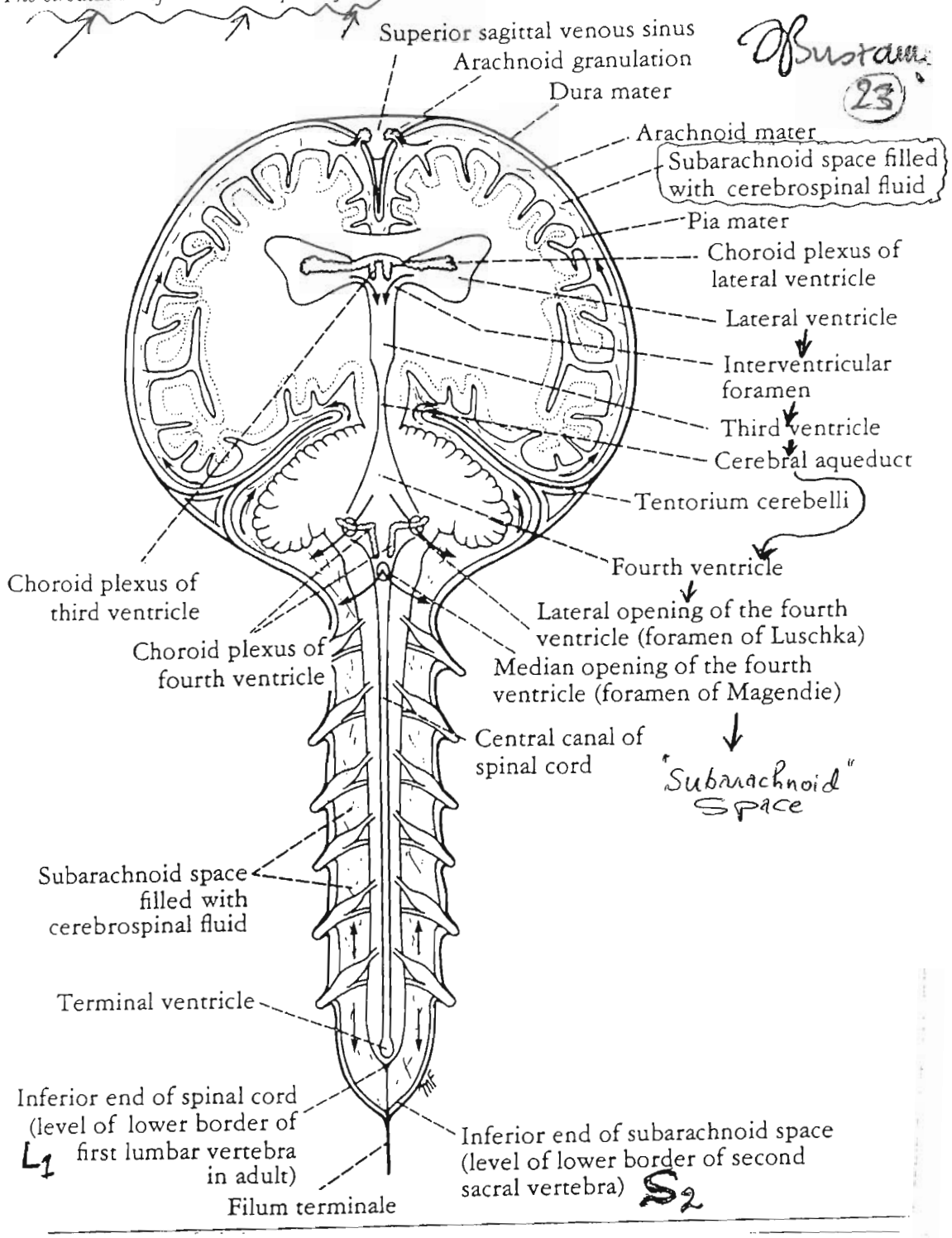

CIRCULATION OF CEREBROSPINAL FLUID

The fluid passes from the lateral ventricles into the third ventricle through the interventricular foramina (Fig. 17-1). It then passes into the fourth ventricle through the cerebral aqueduct. The circulation is aided by the arterial pulsations of the choroid plexuses.

From the fourth ventricle, the fluid passes through the median aperture and the lateral foramina of the lateral recesses of the fourth ventricle and enters the subarachnoid space. The fluid then flows superiorly through the interval in the tentorium cerebelli to reach the inferior surface of the cerebrum (Fig. 17-1). It now moves superiorly over the lateral aspect of each cerebral hemisphere. Some of the cerebrospinal fluid moves inferiorly in the subarachnoid space around the spinal cord and cauda equina. The pulsations of the cerebral and spinal arteries and the movements of the vertebral column facilitate this flow of fluid.

Papilledema = oedema of the optic nerve head

(24)

Bustami

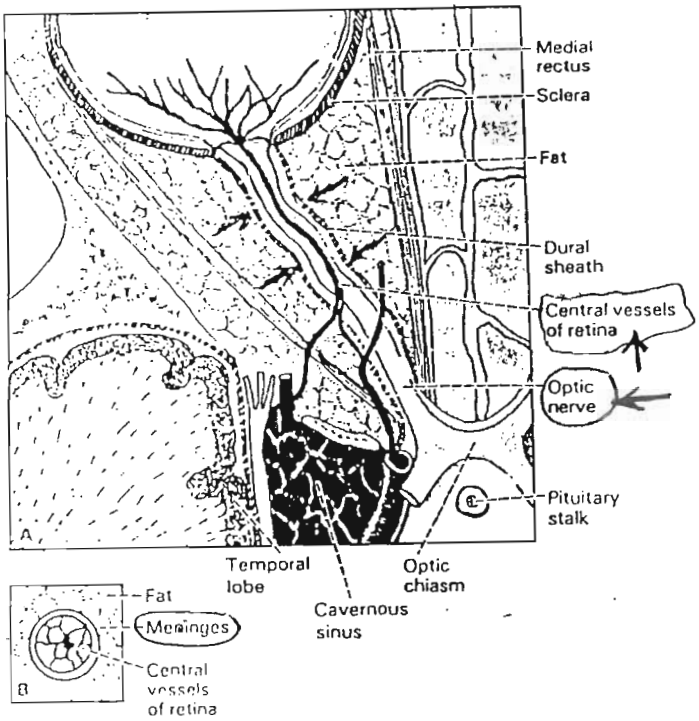

Fig. 29-13 A, horizontal section of the orbit. B, transverse section of the optic nerve.

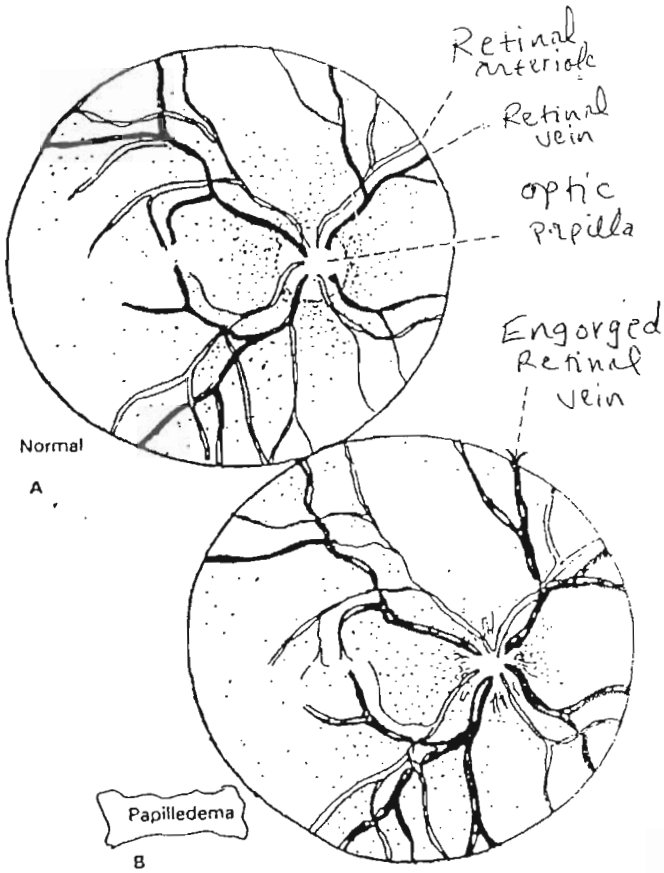

Fig. 29-12 A, normal fundus oculi. B, papilledema.

Extensions of the Subarachnoid Space. A sleeve of the subarachnoid space extends around the optic nerve to the back of the eyeball. Here the arachnoid mater and pia mater fuse with the sclera. The central artery and vein of the retina cross this extension of the subarachnoid space to enter the optic nerve and they may be compressed in patients with raised cerebrospinal fluid pressure. Small extensions of the subarachnoid space also occur around the other cranial and spinal nerves.

The Pressure of the Cerebrospinal Fluid

Any obstruction to the normal passage of cerebrospinal fluid causes the fluid to back up in the ventricles and leads to a general increase of intracranial pressure. After the pressure has been elevated for some time, usually a matter of days or weeks, the effect can be seen by inspecting the fundus of the eye with an ophthalmoscope. Due to the high pressure inside the sleeve of dura mater which surrounds the optic nerve, the retinal veins are dilated and the optic nerve head (optic disc) is pushed forward above the level of the retina. This is known as *papilledema*, or *choked disc*. If papilledema has persisted for a long time, the fibers of the optic nerve will be damaged and the disc assumes a chalk-white color instead of the normal pale pink.

RETINA
left eyeball as seen through an ophthalmoscope (fundus exam.)

25

Optic Disc
(blind spot)
blood vessels & optic nerve
enter and exit here

Fovea Centralis
concentration of cones
for color vision &
high visual acuity

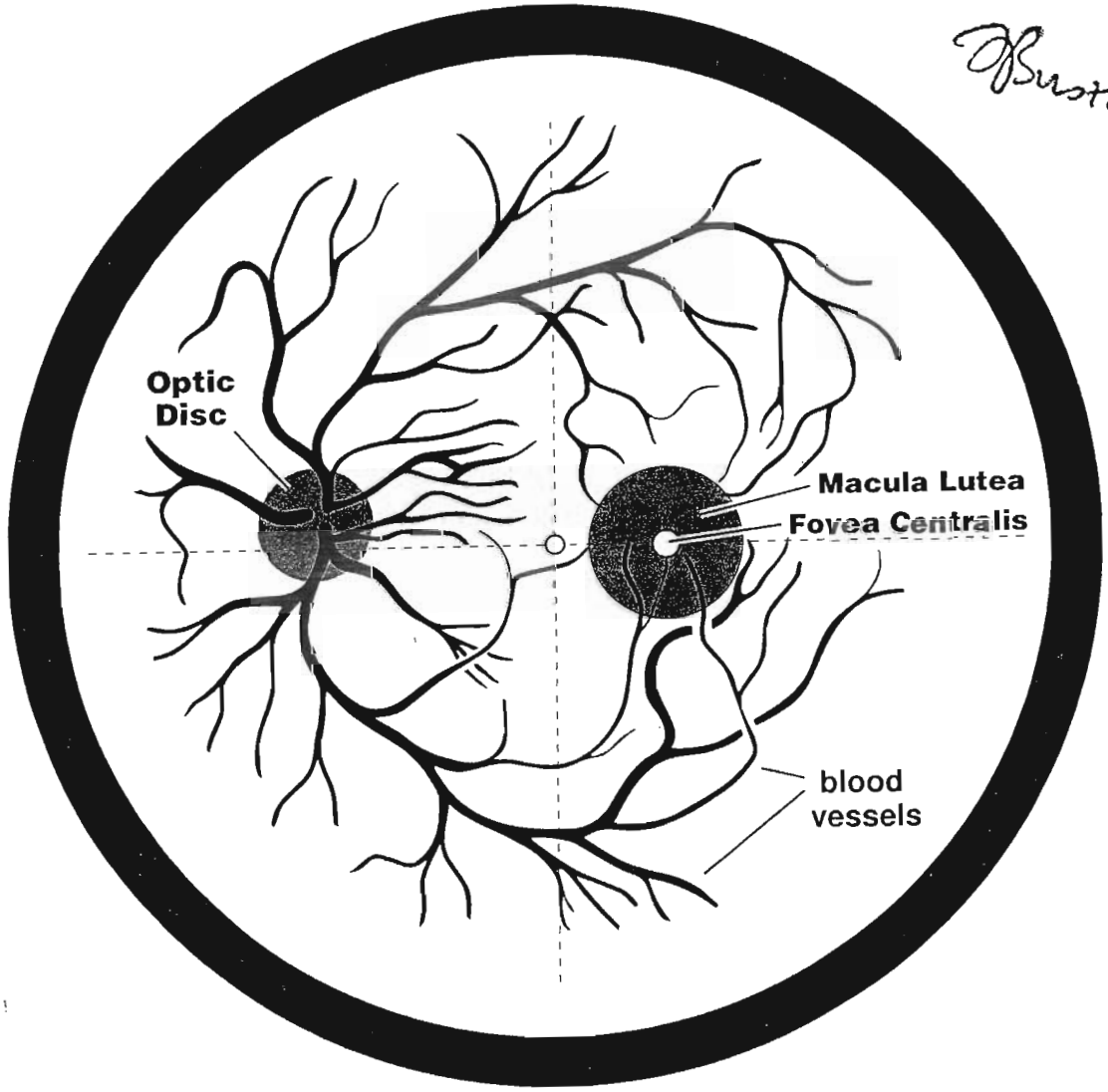

The most common cause of papilledema is a tumor of the brain compressing some part of the ventricular system. Tumors far removed from the ventricles may not produce obstruction until they reach very large size. A tumor of the cerebellum generally exerts pressure on the roof of the fourth ventricle, and, since it is confined within the posterior fossa by the semi-rigid tentorium cerebelli with little room for expansion, it is likely to cause early obstruction to the flow of cerebrospinal fluid through the fourth ventricle. Tumors near the orbital surface of one frontal lobe may compress the optic nerve and produce optic atrophy in that eye, while the other eye develops papilledema from generalized elevation of pressure as the tumor expands in size, the Foster Kennedy syndrome. Other cardinal signs of brain tumor in addition to papilledema are persistent headache and vomiting. The headache is probably caused from the stretching of nerve endings in the dura mater. Irritation of the vagal nuclei in the floor of the fourth ventricle accounts for nausea and vomiting.

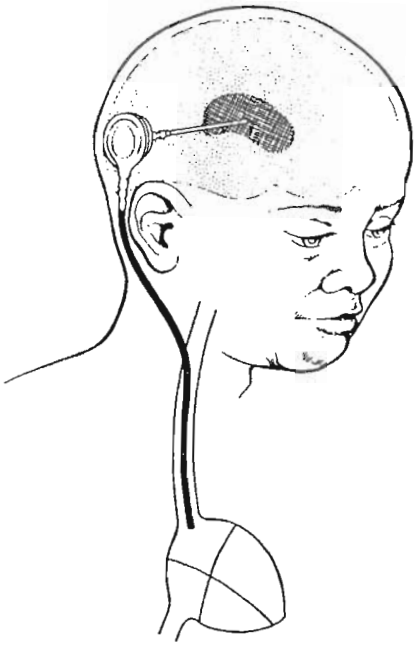

FUNCTIONS OF THE CEREBROSPINAL FLUID

The cerebrospinal fluid serves as a protective cushion between the central nervous system and the surrounding bones. The close relationship of the fluid to the nervous tissue and the blood enables it to serve as a reservoir and assist in the regulation of the contents of the skull. The cerebrospinal fluid is an ideal physiological substrate and probably plays an active part in the nourishment of the nervous tissue; it almost certainly assists in the removal of products of neuronal metabolism. The secretions of the pineal gland possibly influence the activities of the pituitary gland by circulating through the cerebrospinal fluid in the third ventricle.

HYDROCEPHALUS

Hydrocephalus is an abnormal increase in the volume of the cerebrospinal fluid within the skull. If the hydrocephalus is accompanied by a raised cerebrospinal fluid pressure, then it is due to either (1) an abnormal increase in the formation of the fluid, (2) a blockage of the circulation of the fluid, or (3) a diminished absorption of the fluid. Rarely, hydrocephalus occurs with a normal cerebrospinal fluid pressure and in these patients there is a compensatory hypoplasia or atrophy of the brain substance.

BLOOD-BRAIN BARRIER

The blood-brain barrier protects the brain from toxic compounds. In the newborn child or premature infant, where these barriers are not fully developed, toxic substances such as bilirubin can readily enter the central nervous system and produce yellowing of the brain and **kernicterus.**

In certain situations, however, it is important that the nerve cells be exposed without a barrier to the circulating blood. This enables neuronal receptors to sample the plasma directly and to respond and maintain the normal internal environment of the body within very fine limits. There is no blood-brain barrier in the pineal gland, the hypothalamus, the posterior lobe of the pituitary, the tuber cinereum, the wall of the optic recess, and the area postrema at the lower end of the fourth ventricle.

The blood-brain barrier is formed by the tight junctions between the endothelial cells of the blood capillaries. In those areas where the blood-brain barrier is absent, the capillary endothelium contains fenestrations across which proteins and small organic molecules may pass from the blood to the nervous tissue.

Basal ganglia & Thalamus

Bustami

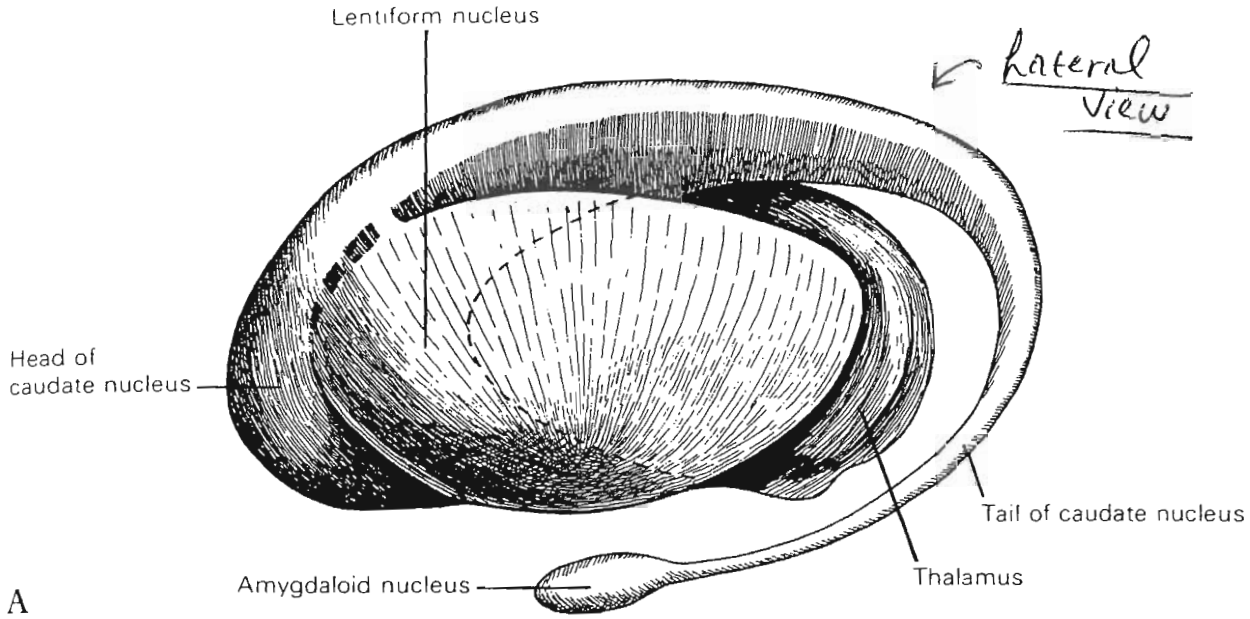

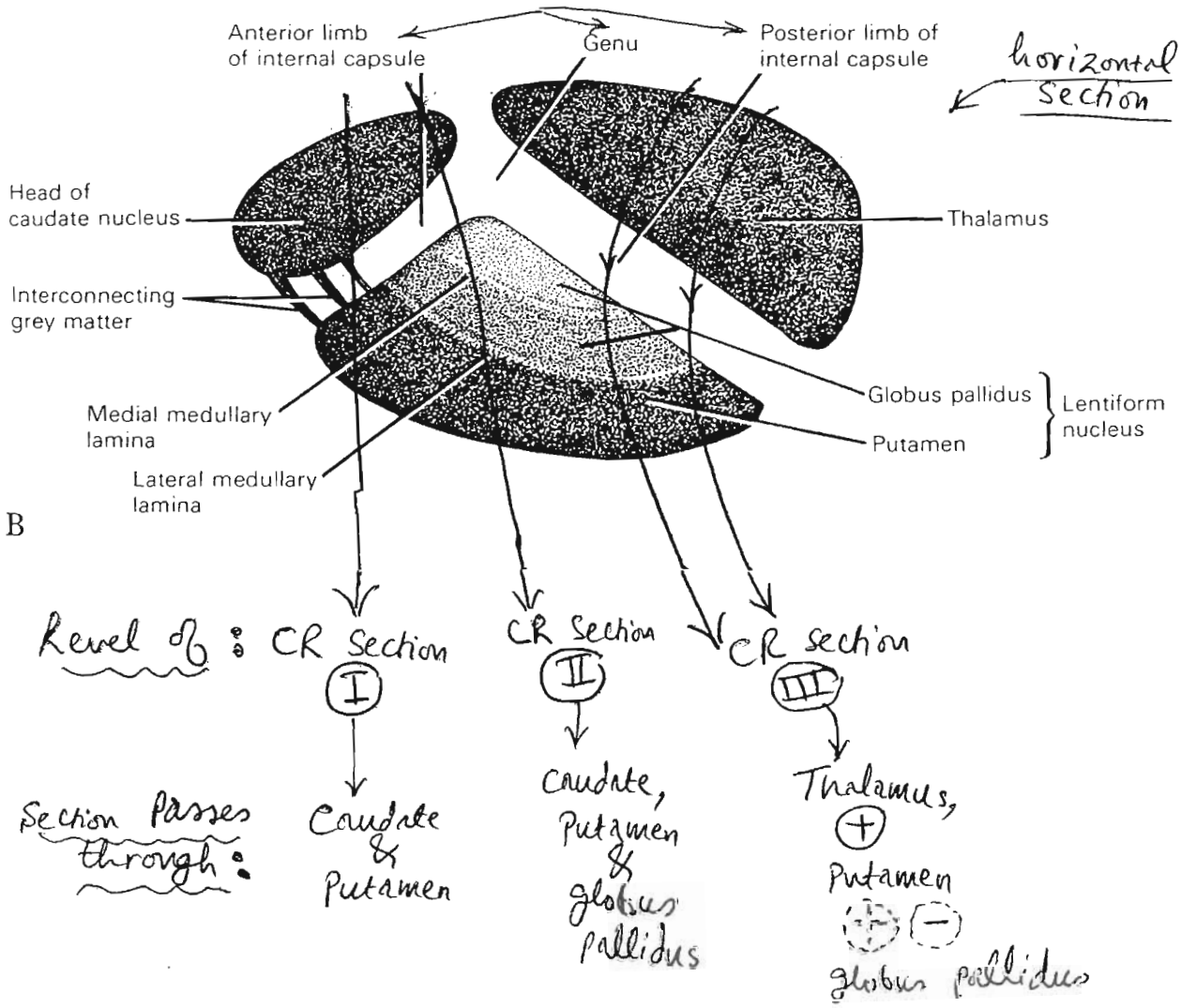

Lateral Ventricle

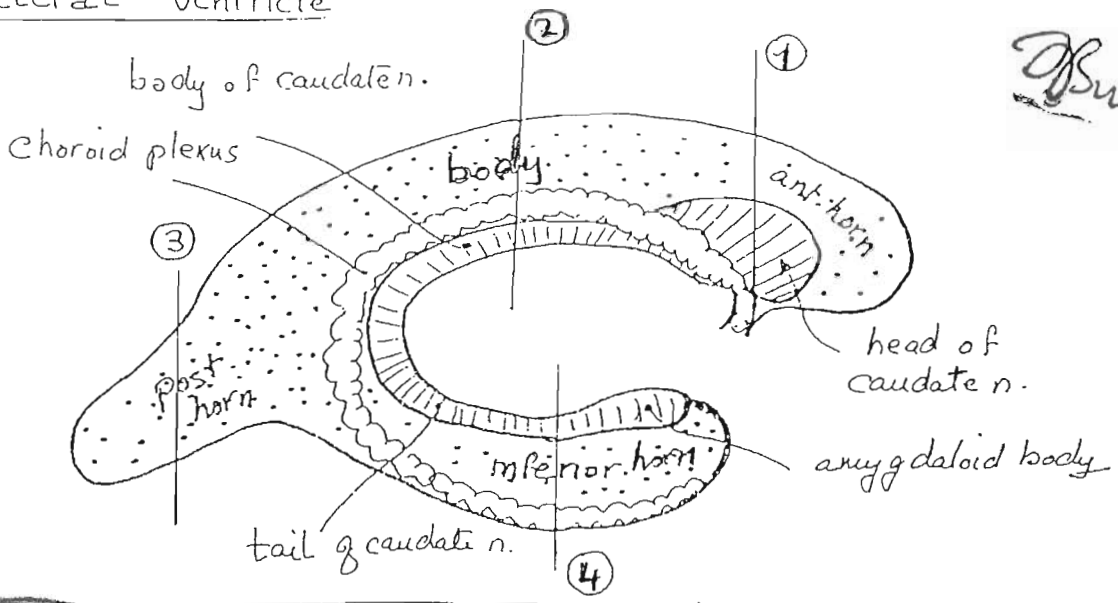

Dr Surtani

① **Ant. horn** Boundaries
- Sup.: genu of corpus C.
- med: Septum pellucidum and fornix.
- lat: head of caudate and choroid plexus

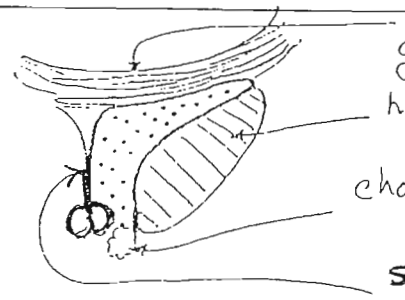

② **Body**: Boundaries
- sup: body of corpus c.
- med: fornix
- floor: - body of caudate
  - Thalamus

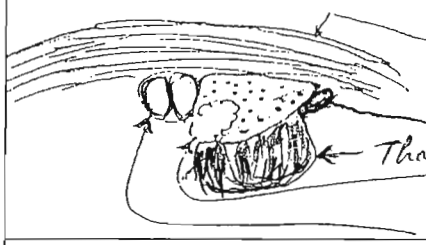

③ **Posterior horn**: Boundaries
- Sup & lateral: tapetum
- medial: bulb and calcar avis

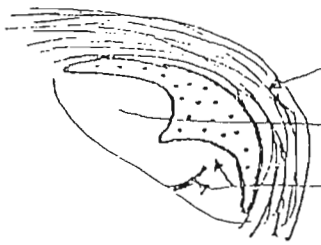

④ **Inferior horn**: Bound:
- Sup: tail of caudate n. and amygdaloid body
- medial: choroid fissure and plexus
- Lateral: tapetum

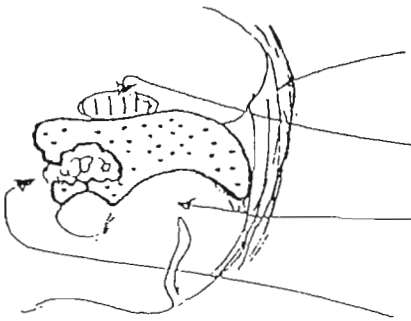

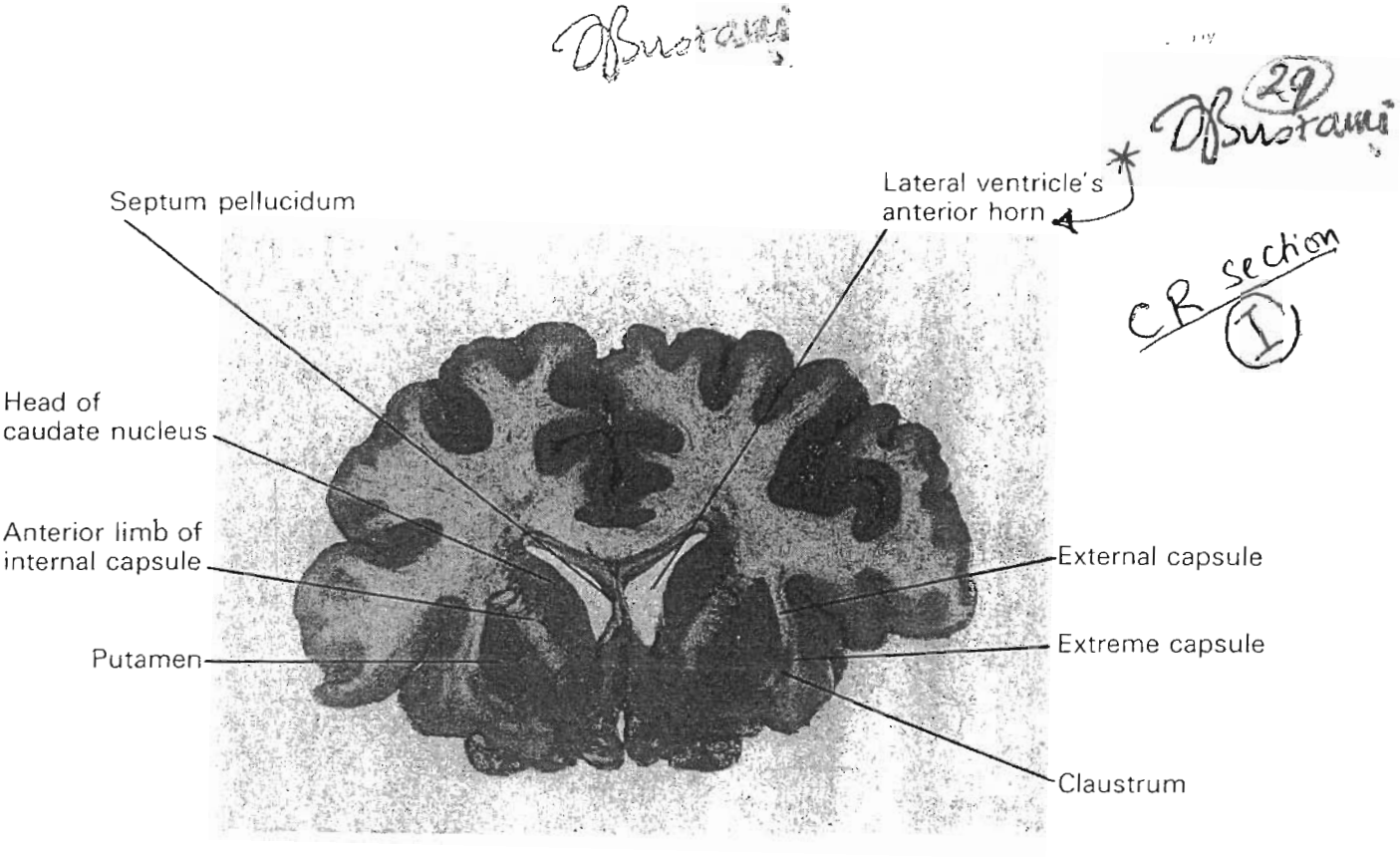

Fig. 9.3 Coronal section of the cerebrum through the anterior horns of the lateral ventricles. (Mulligan's stain, 0.6 natural size.)

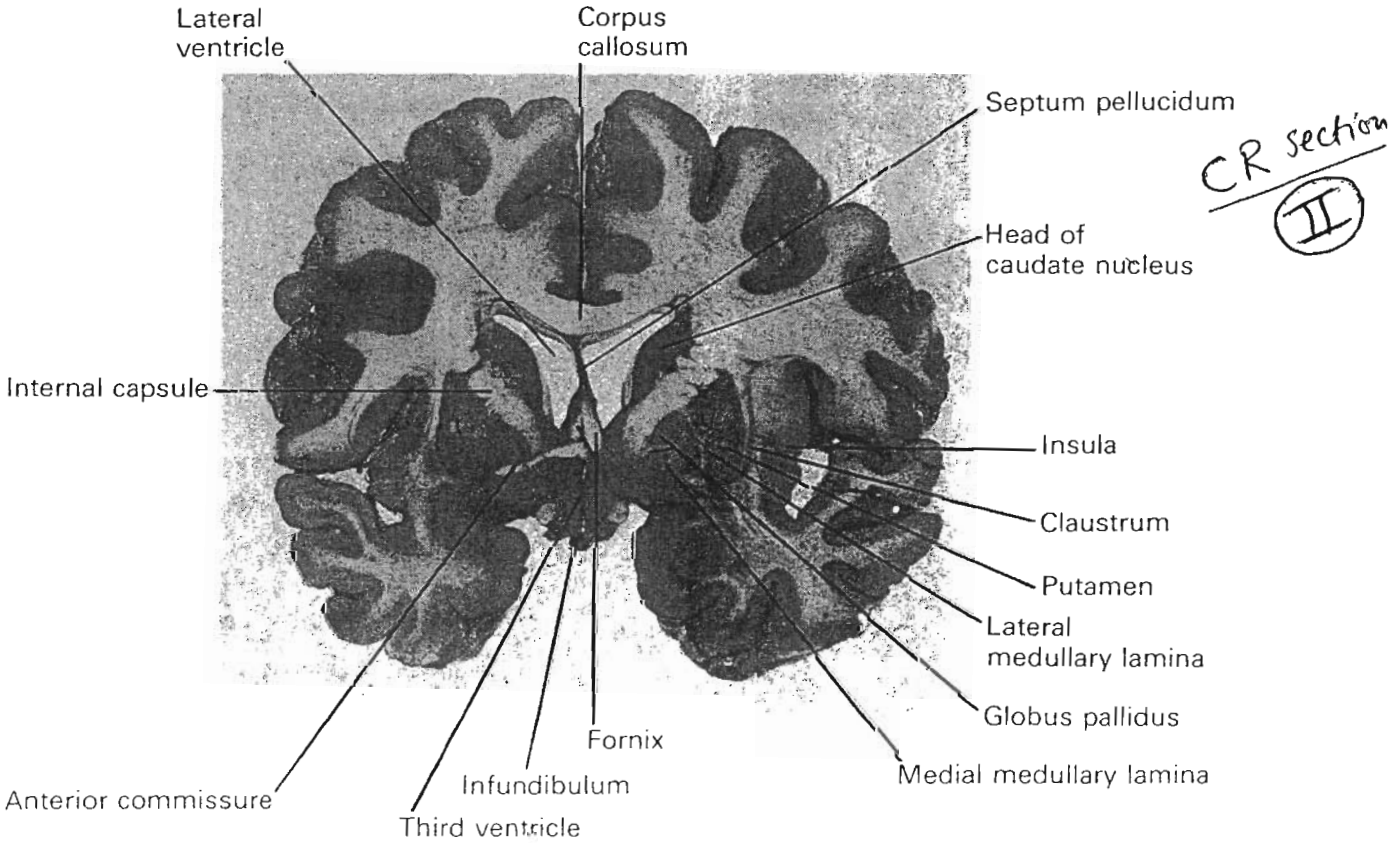

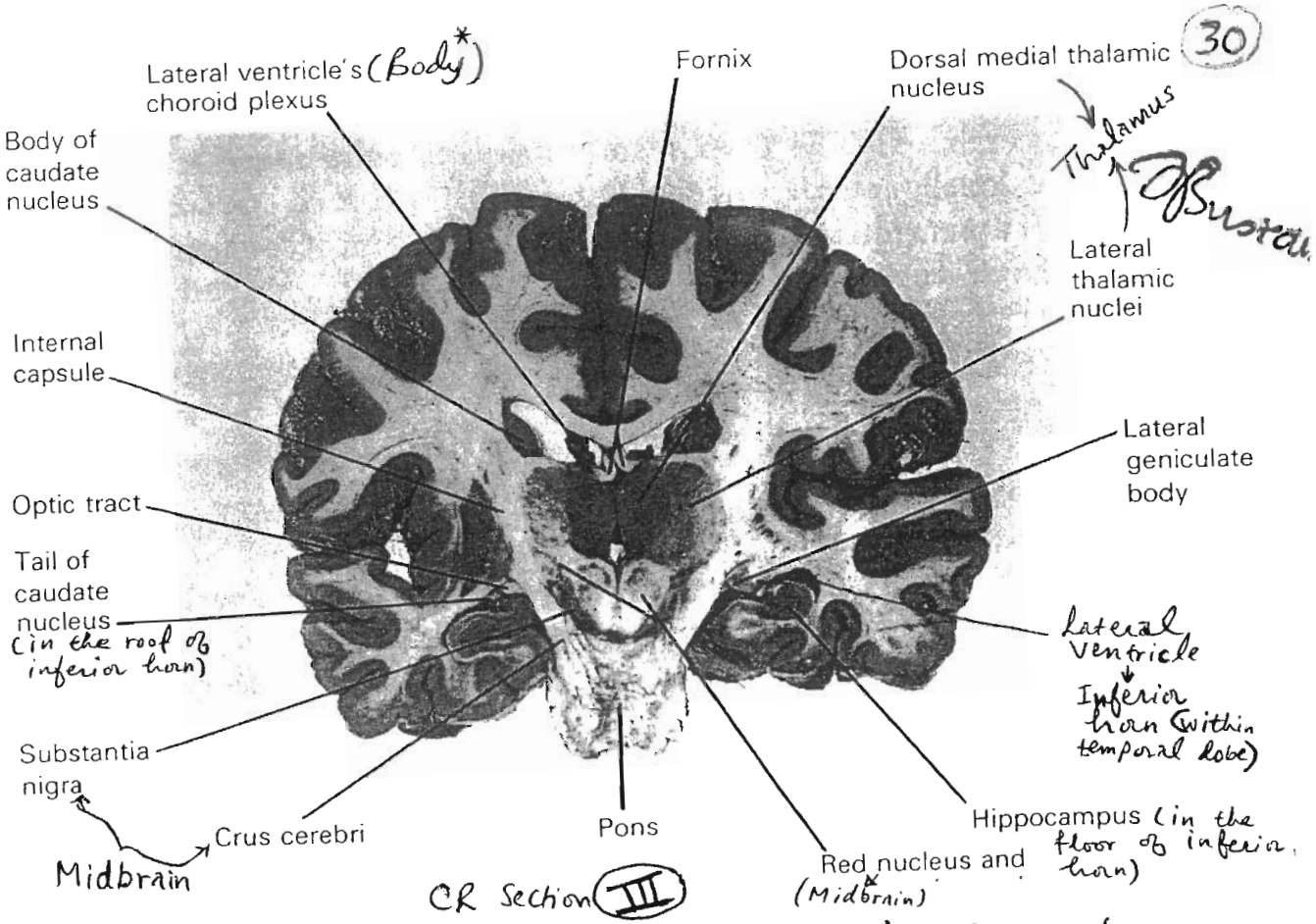

CR Section III

CORONAL SECTION of the BRAIN passing through cerebrum, brainstem and 2 parts of the lateral ventricle (body and inferior horn)

↓

Notice that the CRUS CEREBRI of midbrain is continuous Rostrally (superiorly) with the internal capsule (motor part) and caudally with the basilar part of Pons → Remember that the crus cerebri contains Pyramidal fibres (corticospinal & corticobulbar) as well as CORTICO-PONTINE fibres (from cerebral cortex to pontine nuclei)

- What are the structures present at the floor of the body of lateral ventricle? → body of caudate n. / thalamus

- Functions of hypothalamus?

↓

HOMEOSTASIS

Coronal section through the brain passing through the brainstem –

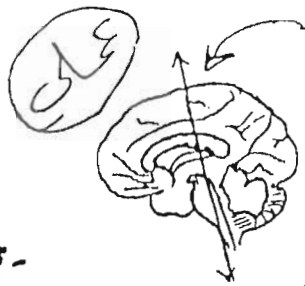

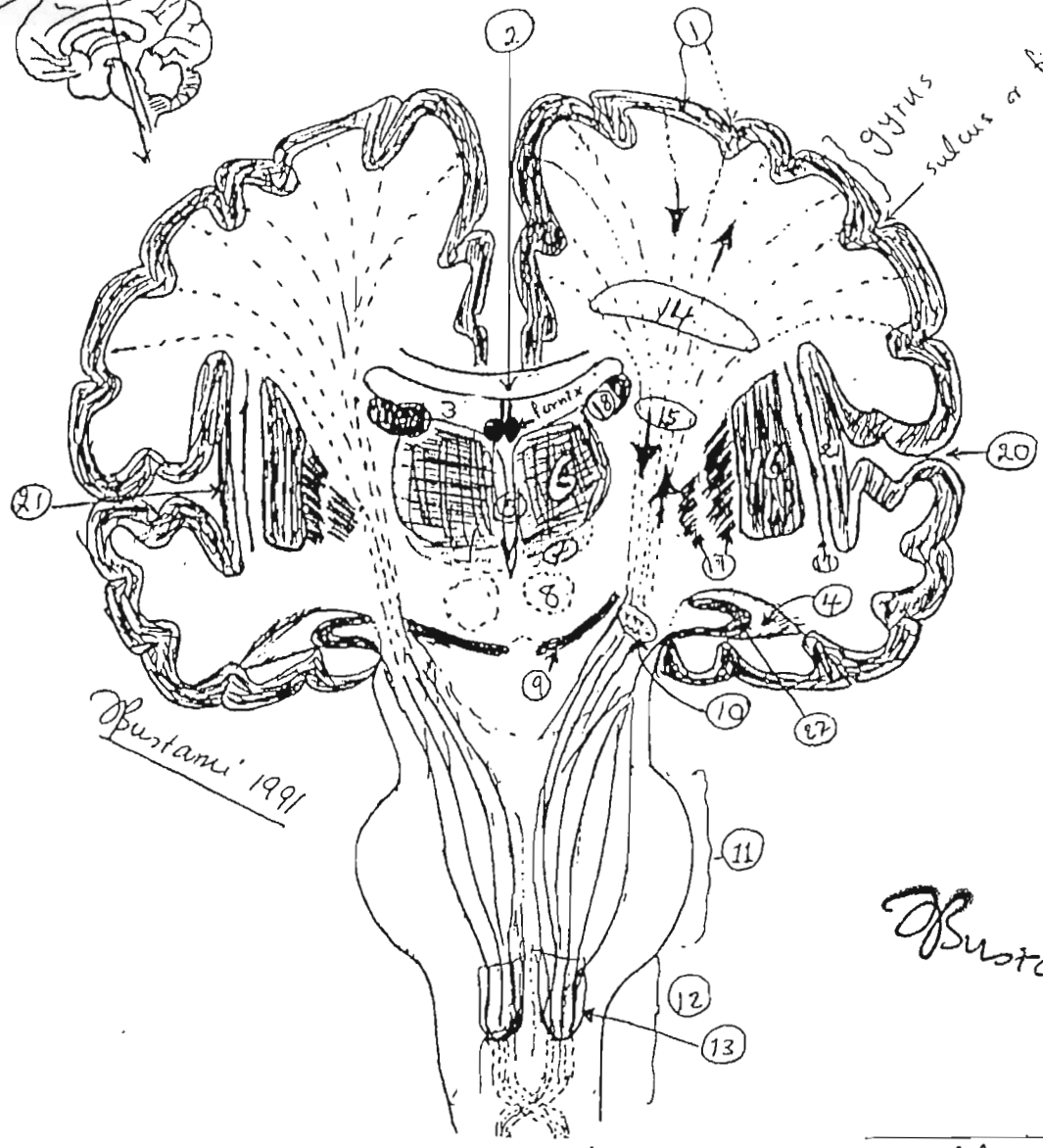

(1) Cerebral cortex (sulci & gyri) (2) corpus callosum e.g of commissural fibres connecting the 2 cerebral hemispheres (3) body of lateral ventricle (4) inferior horn of lateral ventricle (5) third ventricle (between the 2 thalami) (6) thalamus (7) hypothalamus (8) Red nucleus (in midbrain) (9) substantia nigra (in midbrain) (10) crus cerebri (basis pedunculi) of midbrain → continuous rostrally with motor part of internal capsule (12) medulla oblongata (11) pons (13) pyramid (within medulla) (14) corona radiata (15) internal capsule (16) putamen (17) globus pallidus N.B 16 + 17 = Lenticular nucleus (18) Caudate nucleus (19) claustrum (20) lateral fissure (21) insula

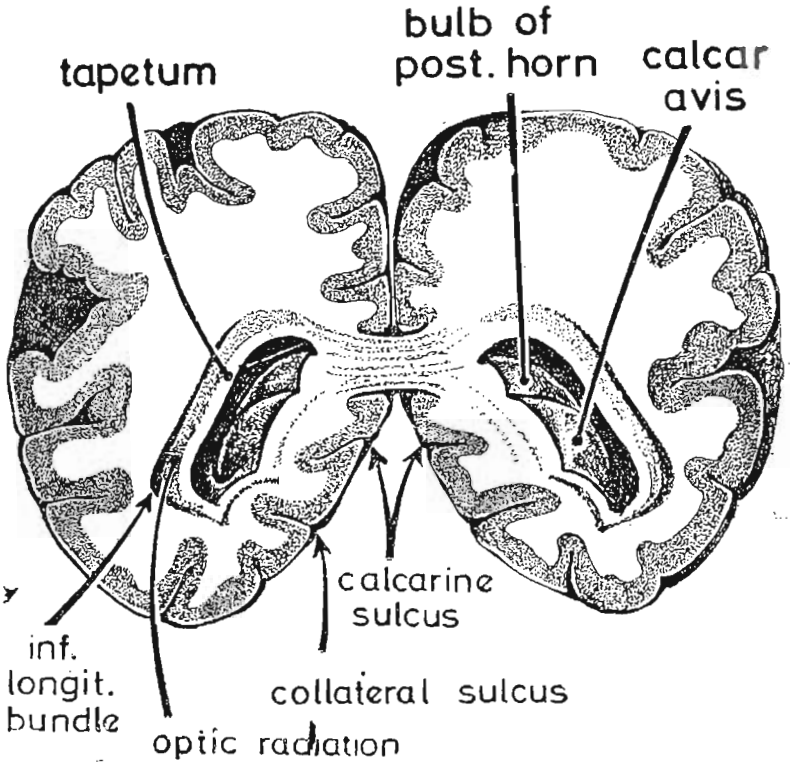

Fig. 73

Cross section through the post. horns of the lateral ventricle

Notice → Roof and lateral wall of the Posterior horn are formed by the tapetum (extension from corpus callosum) however, lateral to this there is part of the Retrolentiform part of internal capsule which contains the fibres of optic radiation

→ Medial wall is formed by:

bulb → extension from splenium

Calcar avis → formed by calcarine fissure

D Bustami

Fourth ventricle :

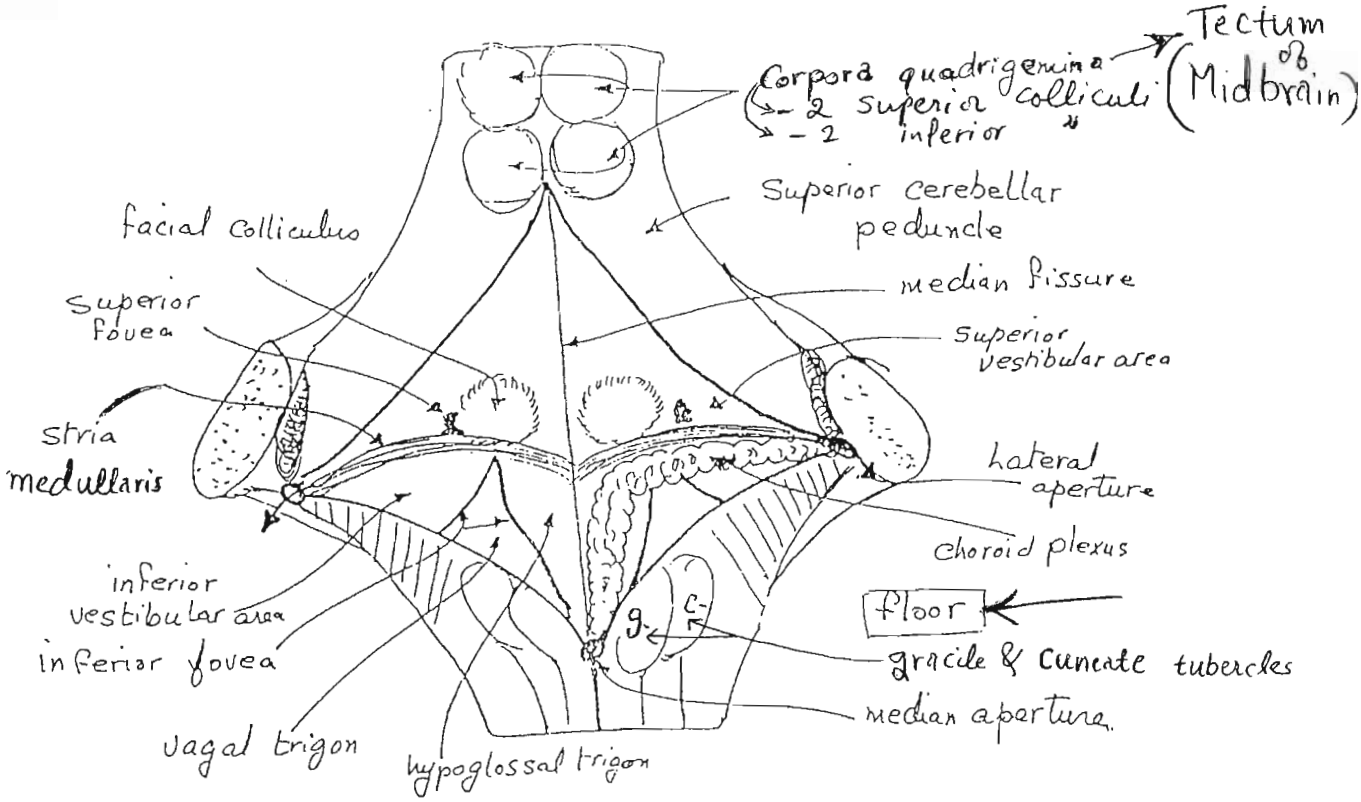

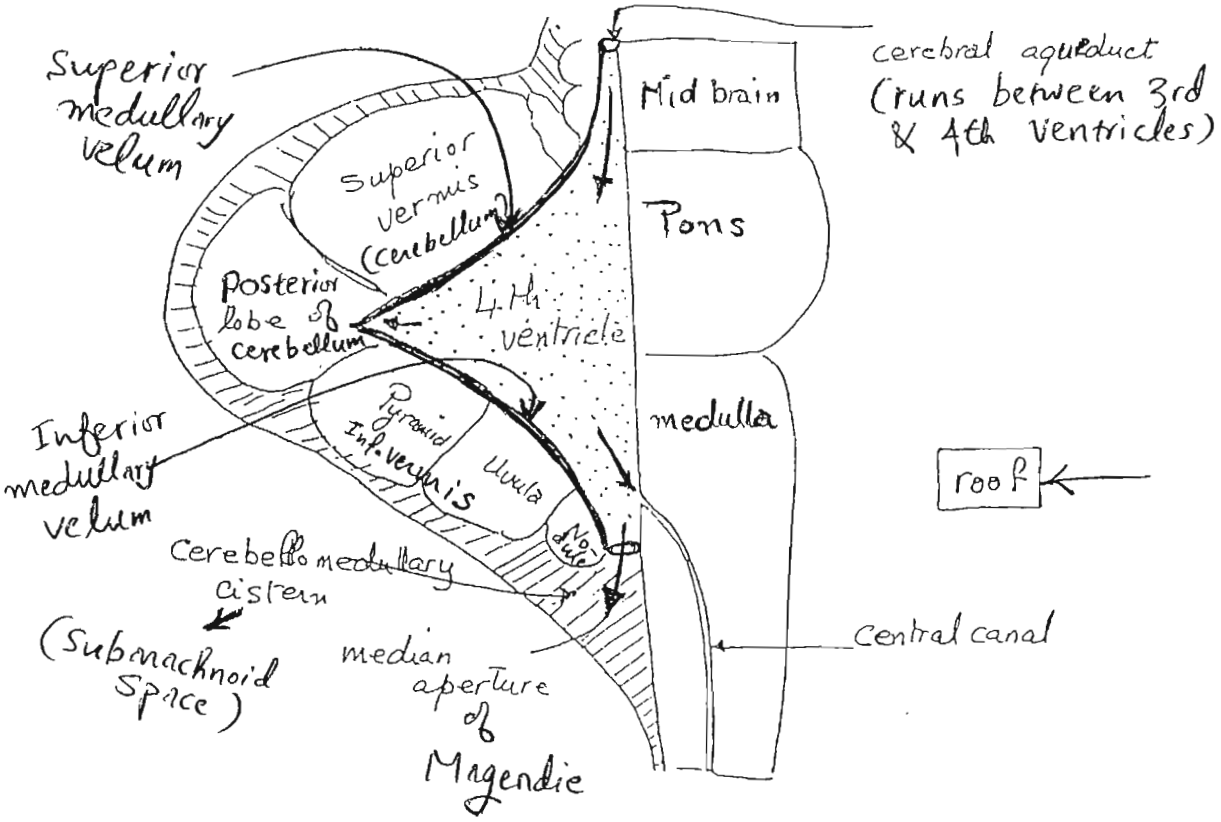

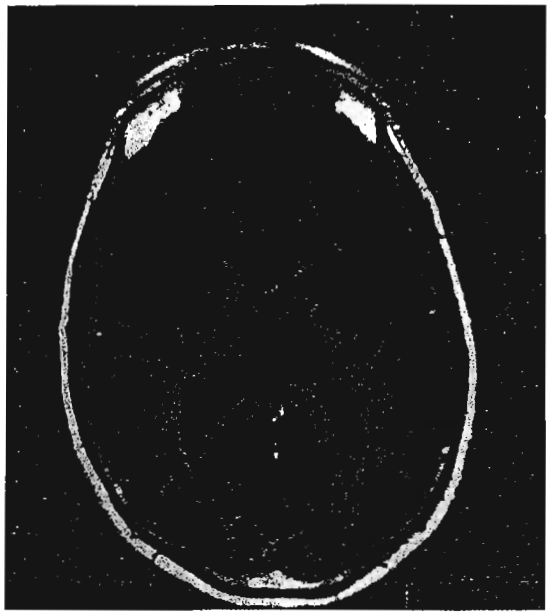

Fig. 10.13 **Horizontal (axial) magnetic resonance image of the living brain.**
(Courtesy of Dr. A. Jackson, Department of Diagnostic Radiology, University of Manchester.)

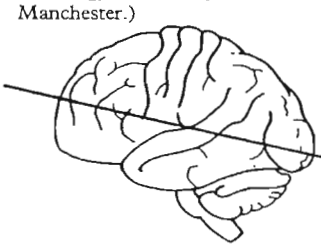

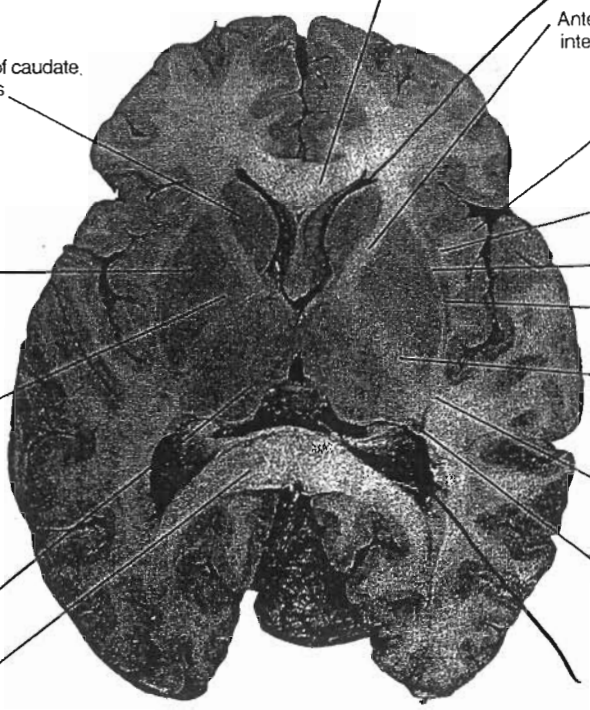

Fig. 10.14 Angled Horizontal section of the brain.

Angeled horizontal section of Brain passing through CEREBRUM, basal ganglia, thalami, 2 parts of lateral ventricle (ant. & post. horns), 2 parts of corpus callosum (genu & splenium)

Median Sagittal section of the brain showing the medial surface of the cerebral hemisphere

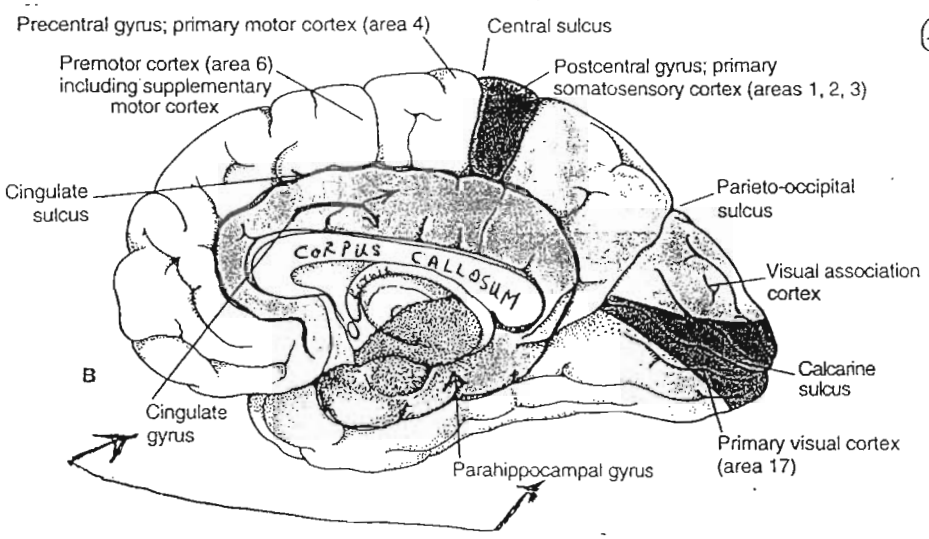

⊛ Notice the continuity between the cingulate gyrus and the parahippocampal gyrus.

The major afferent connection of the hypothalamus is the *fornix*, a conspicuous tract ending in the *mammillary nuclei*. The fornix arises from the *hippocampus*, which is formed by an infolding of the inferior surface of the temporal lobe along the line of the hippocampal fissure. Fibers of the fornix proceed backward on the ventricular surface of the hippocampus, then arch forward under the corpus callosum. The fornix completes its nearly ring-shaped course by turning downward and back to reach the mammillary body (Fig. 40). The efferent connection of the mammillary body is the *mammillothalamic tract*, a prominent bundle of fibers passing directly to the

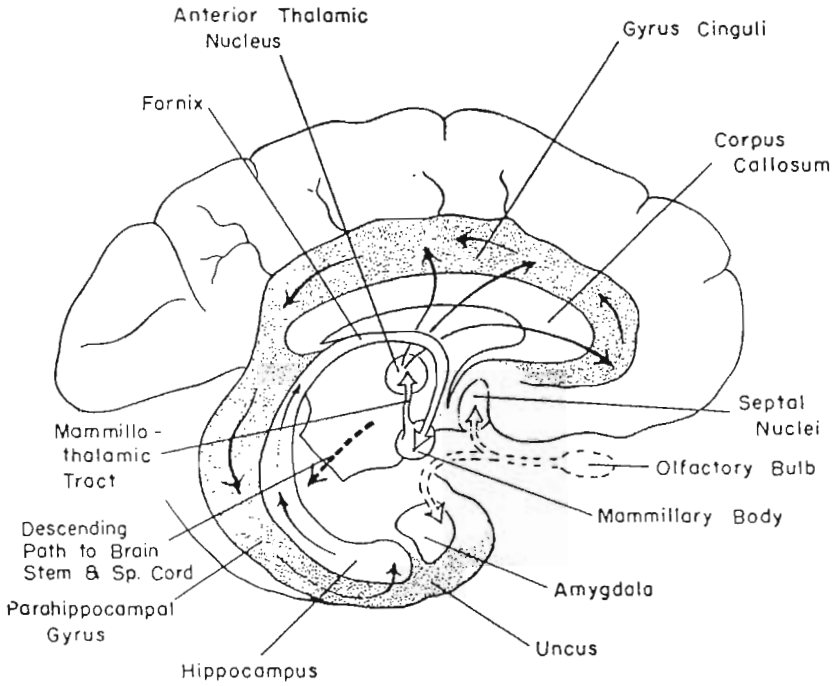

anterior nucleus of the thalamus. The anterior thalamic nucleus sends fibers to the *cingulate gyrus*, which is the long gyrus next to the corpus callosum on the medial aspect of the cerebrum. The cingulate gyrus encircles the corpus callosum and, in its posterior part, is continuous through a narrowed strip (the isthmus) with the *parahippocampal gyrus*, the most medial convolution of the temporal lobe. Together the cingulate gyrus, isthmus, parahippocampal gyrus, and the uncus, an eminence near the front of the hippocampal gyrus form a ring of cortex known as the *limbic lobe* of the brain (see Fig.