

**Dr.Asem**

Q1: what is the following agar ( عينة بتشبه الصورة الي بالجنب ) :

- a) SIM agar
- b) Citrate
- c) Urease
- d)
- e)



Q2:What is the organism cultured in the blood agar ( هاد السؤال تم الاختلاف فيه ) :

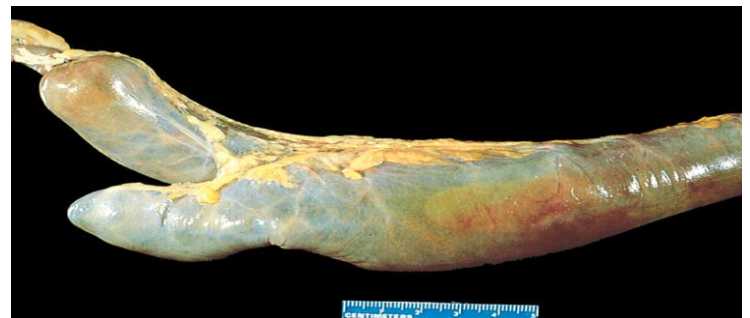- a) E.coli
- b) اول مرة بتسمع فيها في اللاب
- c) اول مرة بتسمع فيها
- d) اول مرة بتسمع فيها
- e) None of the above



**Dr.Maha:**

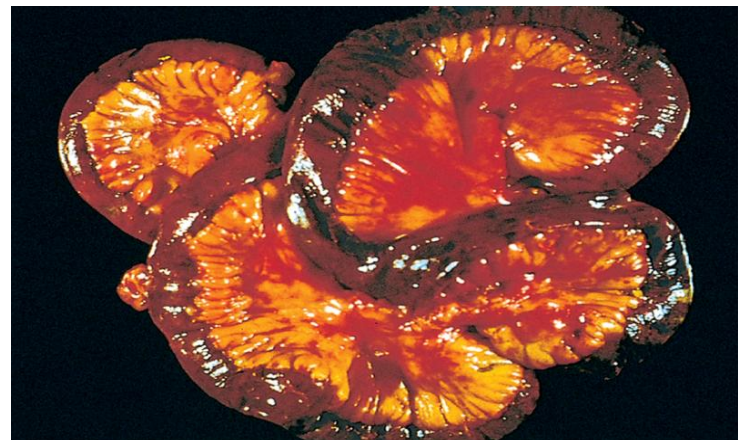
Q1:The pouch which marked by the arrow known as :

**Meckel diverticulum**



Q2:The following structure represent a :

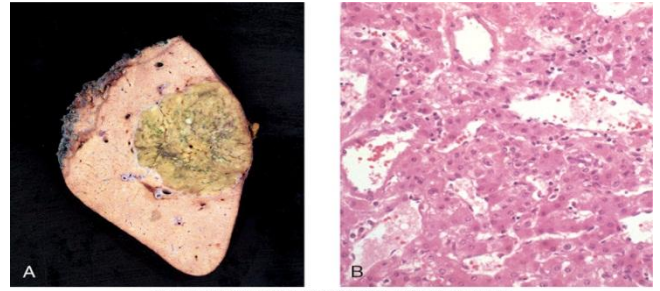
**Transmural infraction**



Lab Exam GIS 18 may 2013

Q3: The following represent a: (السؤال بالامتحان كان غلط)

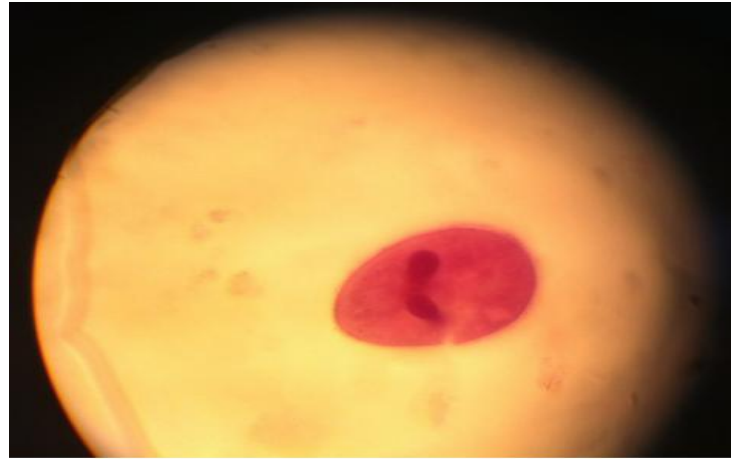
Hepatic adenoma



Dr. Hasasn:

Q1: the following is associated with: (الصورة مش متأكد منها)

- a) Reservoir
- b) Eggs
- c) D



Q2: The following organism is associated with how many proglottids: (الصورة مش لاقيةها)

- a) 3
- b) 200
- c) 2000
- d) 1000
- e) 3000

Dr. Mhoammad :

Q1: metabolic rate is measured by indirect way by measuring:

- a) amount of oxygen consumed
- b) Using RQ
- c) Amount of Co<sub>2</sub> produced

Q2: Adding acetylcholine to the gastrointestinal tract .... (مش متأكد من صيغ السؤال)

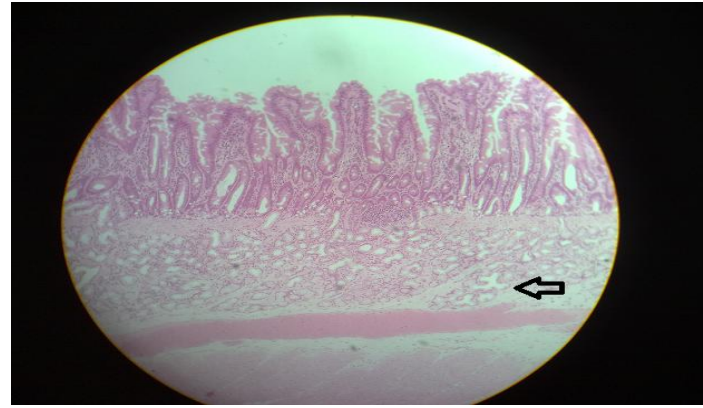
- a) Increase tonic contraction
- b) Increase rate of شبي
- c) More one of the above

Lab Exam GIS 18 may 2013

Dr. Mohtaseb:

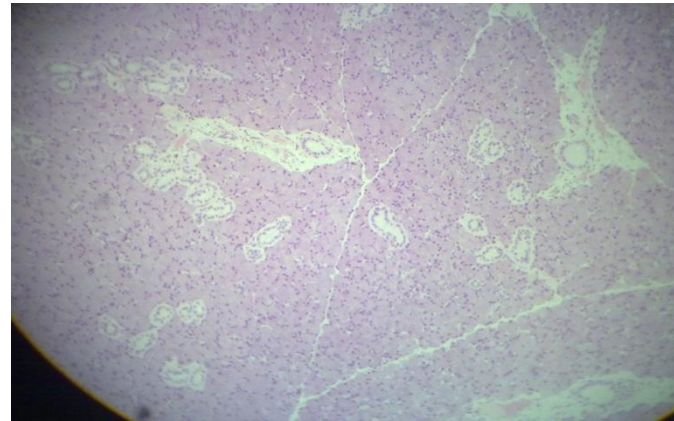
Q1: Identify the following:

- a) parotid gland
- b) submandibular gland
- c) pancreas
- d) Sublingual gland



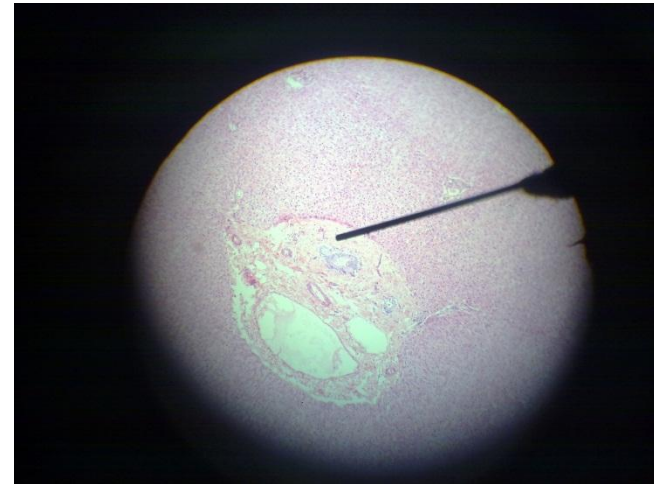
Q2: All the following is related to the pointed area except:

- a) Hepatic artery
- b) Portal vein
- c) Bile duct
- d) Blood sinusoids
- e) Reticular fibers



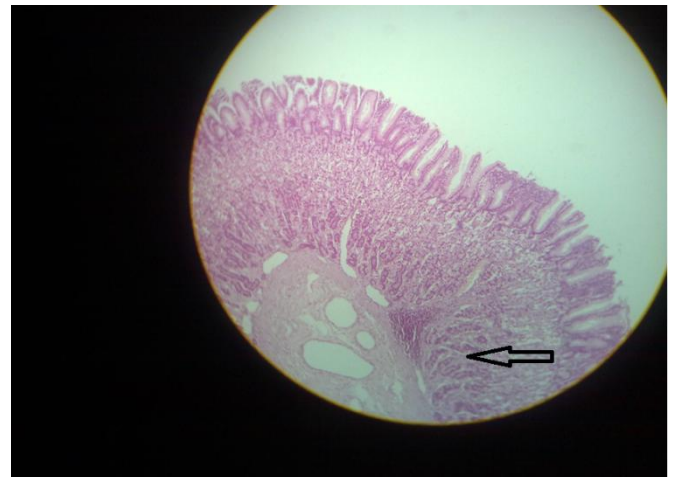
Q3: The pointed structure is:

- a) Parietal cell
- b) Chief cell
- c) Goblet cell



Q4: The pointed structure is: (not sure about the picture)

- a) Crypts of Lieberkühn
- b) Goblet cell
- c) Brunner's gland
- d) cardiac gland



Q5: identify the following structure : Colon مش لافي الصورة

**anatomy**

Q6: about the liver he pointed at gastric impression and ligamentum teres and asked to identify the pointed structures

Q7: X-ray picture: barium meal duodenal cap

Q8: pointed at a structure on your cheeks and asked to identify it : it was hypoglossal nerve

Q9: pointed at a notch in the mandible and asked : the structure related to pointed area is a branch from : maxillary artery (مش متأكد من السؤال)

Q10: pointed to the appendix and asked : all the following regarding the pointed structure is true except:

- a) antimesenteric
- b) contain tenia coli
- c) supplied by a branch from posterior cecal artery
- d)

Q11: pointed to the jugular foramen in the skull and asked: which ganglion pass from here :

- a) Ciliary ganglion
- b) Otic ganglion
- c)