(35) (Lt) Speech & Language (1)

Basically involves the Understanding of (spoken / printed) words besides the ability to express ideas in (speech / writing)

Aphasias → fluent (sensory) / non-fluent (motor)

Abnormalities of language functions that are NOT due to defects of vision or hearing or to motor paralysis → They are caused by lesions in the categorical hemisphere.

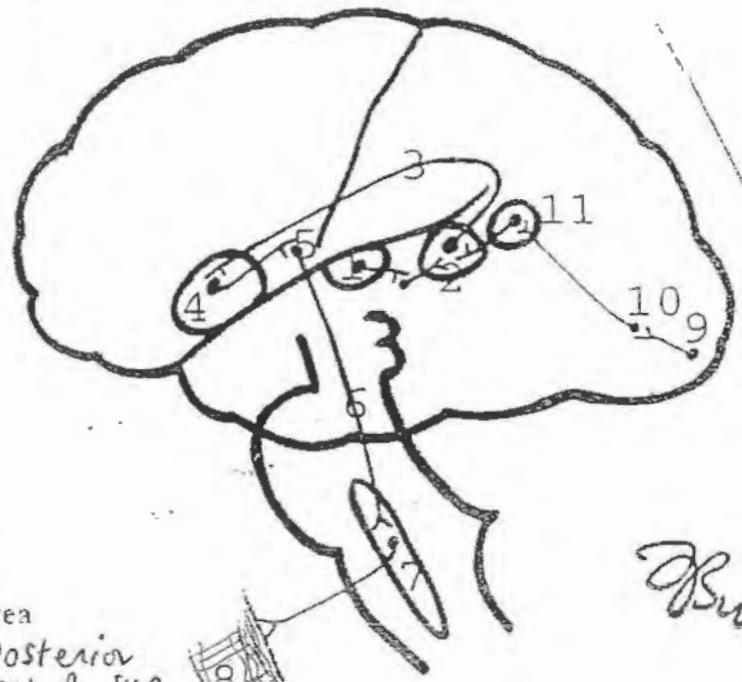

1-Primary auditory area
2-Associated auditory area and Wernick's area (posterior part of sup. temporal gyrus)
3-Arcuate bundle
4-Broca's area (inf. frontal gyrus)
5-Motor area
6-Corticobulbar tract
7-Nucleus ambiguus, hypoglossal nucleus and other cranial nuclei that supply speech muscles
8-Speech muscles (larynx, palate, tongue, lips)
Reading:
9-Primary visual area
10-Associated visual area
11-Angular gyrus (inferior parietal lobule)

FIGURE 15-3: Cortical areas and pathways that are probably mediate spoken language (communication) and written language (reading).

Speech & Language

In 95% of people → the LEFT cerebral hemisphere contains the centres for language & comprehension

⇓

< Dominant Hemisphere >

Normal communication between people by spoken language needs at least 4 cortical areas

- Primary auditory area (41, 42)
- Wernick's area (post. part of area 22)
- Broca's area (44, 45) inferior frontal gyrus)
- Premotor & motor areas (6, 4)

Bustami

* Wernick's area — Sensory speech area

important to understand the spoken words that reach the primary auditory area from the ears ⟹ Send the necessary information about speech to Broca's area

↓

send the necessary information to Motor & premotor areas

send motor signals through the descending motor tracts to the speech muscles → larynx, tongue, lips & palate

* Written words to be spoken needs

→ visual areas in the occipital lobe ← 17, 18, 19

→ Angular gyrus (area 39)

→ Wernicks area → Broca's area → Motor area

Lesions in wernick's area → allow a person to hear differnt words perfectly But make him unable to arrange these words into a coherent thought. Likewise, the person is capable of reading but cannot understand the ideas conveyed by the read words

(3)

At one time used to be called general interpretative area → Receive impulses from ← somatic, visual, auditory } association areas

Wernick's area

A centre in the mind for interpreting sensory experiences (relates them to past experience)

↓

for formation of thought in response to that interpretation

↓

for choice of words to express thoughts

Projects via the ARCUATE FASCICULUS

To [1] Broca's area of the dominant hemisphere if speech is involved

or to [2] area of hand skills in Premotor area 6 if writing is involved

Broca's area

Processes the information received from wernick's area into coordinated pattern of vocalization & project that pattern to the motor cortex → initiate movement of muscles of speech in the tongue, lips & larynx via the corticobulbar fibres of the pyramidal tract.

If writing is concerned

→ the information received from wernicks area is processed in the area of hand skills → (4)

The result is a coordinated pattern of muscle movements projected to arm and hand region of the motor cortex which initiate the necessary muscle movements in the hand & arm required for writing a particular word

Broca's area (Brodmann's area 44, 45)

→ Motor speech area occupies the left inferior frontal gyrus DIRECTLY infront of the motor cortex controlling muscles of speech.

→ Stores speech programs that are used by the motor area to produce normal speech

→ It receives INPUT from the sensory speech area (wernicke's area)

→ Sends OUTPUT to the lower part of the motor area which controls the speech muscles

Dr Bustami

→ A lesion confined to Broca's area results in MOTOR (Expressive) aphasia

In this type of aphasia:

1. the patient knows what he wants to say but has great difficulty in saying it leading to SLOW POOR & Nonfluent speech. (speech muscles are Not paralyzed)
   → Non-fluent aphasia
2. The patient understands spoken & written words but has trouble in speech & finds writing difficult or impossible
3. In severe cases, the patient may be limited to 2-3 words with which to express a whole range of emotions

Wernicke's area → Post. part of area 22 is the sensory speech centre

↓ lesion

Severe disturbances of speech content

Although hearing + vision are normal → individuals with this disability show an essentially → TOTAL FAILURE TO COMPREHEND EITHER THE SPOKEN and/or WRITTEN LANGUAGE

* Their speech is FLUENT but MEANINGLESS (Key words are omitted) → (fluent aphasia)
* The patient is unaware of his errors
* Wernicks area receives inputs from → auditory association cortex, angular gyrus
  projects to → Broca's area (via the arcuate fasciculus), Premotor cortex (hand skill area)

... Fluency is quite normal, but three kinds of abnormality occur in the use of nouns:

1 Circumlocution. Instead of 'I use a knife', 'I use the thing you cut with'. الدوران حول المعنى

2 Verbal paraphrasia (the use of words of allied meaning). Instead of 'I cut with a knife', 'I cut with a fork'.

3 Phonemic paraphrasia (the use of made-up words having appropriate sounds. Instead of 'knife and fork', 'bife and dork'.

Table 25-1 Comparison of Broca's and Wernicke's aphasia

	Aphasia	
	Broca's	*Wernicke's*
Articulation	Slurred	Normal
Speed	Halting	Rapid
Comprehension	Good	Poor
Awareness	Yes	No

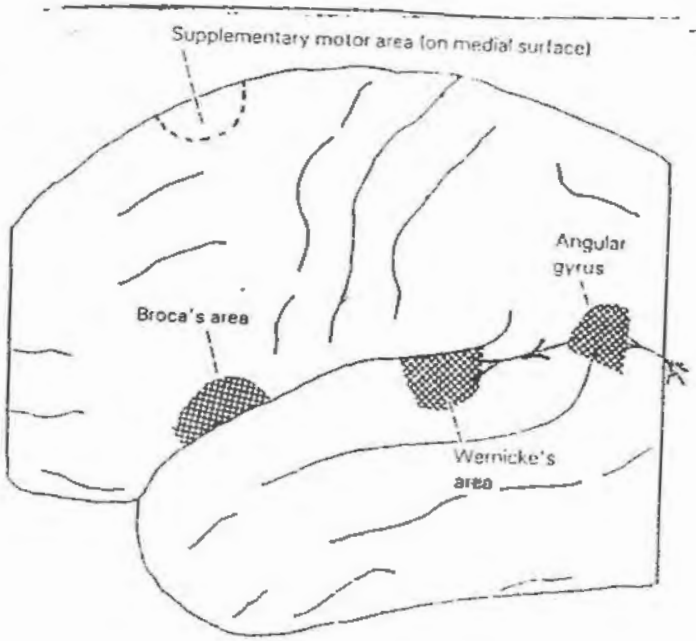

Angular gyrus

- it is area 39 which caps the superior temporal sulcus
- the left angular gyrus is the VISUAL-AUDITORY CONVERSION AREA
- receives from → visual association cortex on its own side; its partner opposite through the corpus callosum
- projects to → Wernicke's area

THE LEFT ANGULAR GYRUS is ESSENTIAL FOR THE CONVERSION OF THE WRITTEN WORD TO ITS AUDITORY EQUIVALENT (FROM GRAPHEMES TO PHONEMES)

→ A lesion here causes written words to become meaningless hieroglyphics → A L E X I A → This because we need to hear the written word while reading. (NO difficulty in speech or understanding of auditory informations)

anomic aphasia !!!

Reading aloud

The anatomic pathway for reading aloud is as follows (commissural connections between the two angular gyri have been omitted) (Fig. 25-3).

1 Retinogeniculate tracts.
2 Geniculocalcarine tracts.
3 Transfer to visual association cortex.
4 Transfer from right to left hemisphere via splenium of corpus callosum.
5 Composite visual picture passed to angular gyrus for auditory transformation.
6 Transfer from angular gyrus to Wernicke's area, for comprehension.
7 Transfer to Broca's area via arcuate fasciculus.
8 Transfer to motor cortex.

Obstruant

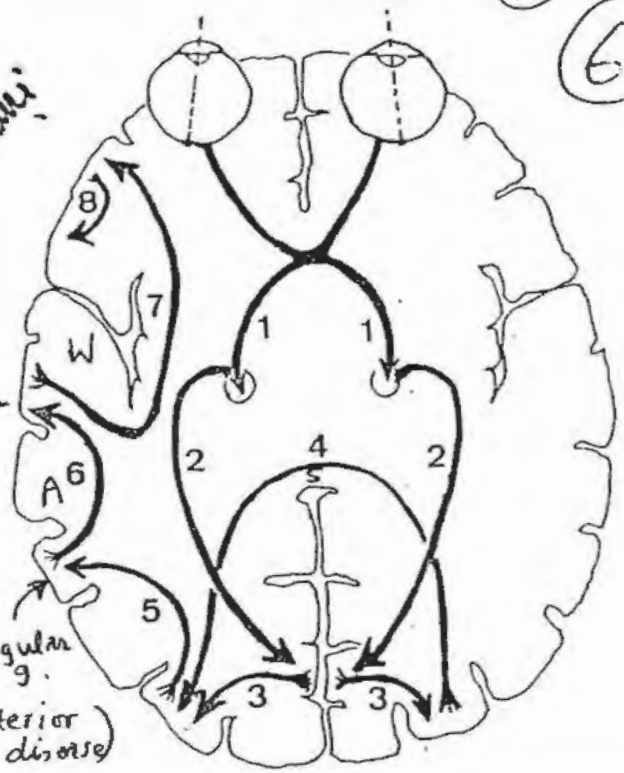

Fig. 25-3 Minimal pathway for reading aloud. For identification of numbers see text.

Extensive vascular lesion involving the angular gyrus on the dominant side → A L E X I A

(+) Gerstman syndrome (left posterior parietal disease)

1. Agraphia (inability to write)
2. Acalculia (inability to do simple sums)
3. difficulty in distinguishing right from left
4. finger agnosia (inability to tell how many of the examiner's fingers are held up for inspection)

* Patients with angular gyrus syndrome (posterior parietal disease) may be thought to have Alzheimers disease.

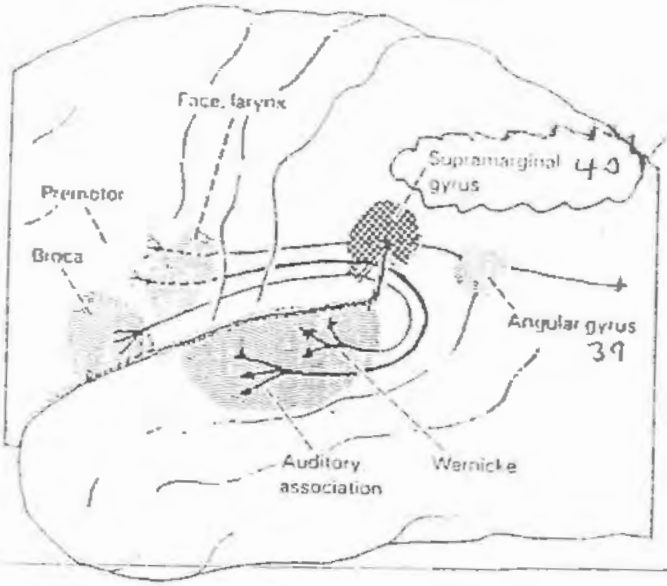

Fig. 25-5 Three sets of long association fibers underlie the supramarginal gyrus.

Supramarginal gyrus (area 40)

↓

Surrounds the upturned posterior end of the lateral sulcus

↓

lesion here which include the underlying white matter may result in

- Conductive aphasia *
- Facial apraxia *

Conductive aphasia → interrupted conduction in the arcuate fasciculus deep to the gyrus

↓

Symptoms → those of Wernickes aphasia (but can comprehend)

inability to REPEAT even the simplest phrases spoken by the examiner

Facial apraxia

Apraxia denotes the inability to perform a given movement on request in the presence of normal cerebration & motor power

↓

Attributed to interruption of long association fibres paring from

- visual association area
- auditory association area

} To premotor cortex → To lower end of area 4

→ If the visual connections alone are lost → the patient cannot mimic facial movement carried out by the examiner (pursing the lips, squeezing the eyes) but can respond to A SPOKEN REQUEST for such a movement

→ If the auditory connections are also lost → the spoken request is ineffective

Observation

Facial apraxia or upper limb apraxia may occur in association & Motor aphasia if the lesion is large enough to affect the premotor cortex

Global aphasia → is seen with large lesions affecting both wernicke's & broca's areas.

→ Marked hemiparesis occurs ⊕ inability to comprehend & to speak

→ Seen with large infarcts in the middle cerebral artery territory (often due to occlusion of the left internal carotid artery or trunk of middle cerebral artery).

Examination of the aphasic patient

1) Listen to speech output → Is it fluent or nonfluent? if fluent the lesion is posterior, if nonfluent, it usually is posterior
2) Can the patient READ & WRITE with no errors? If So → aphasia is not present
3) Is there HEMIPARESIS? If So, the lesion is anterior involving motor area
4) In fluent aphasia → Check whether the patient can: Repeat, Comprehend, name?

→ a) In Wernick's (sensory) aphasia → pt. cannot Repeat or Comprehend, names poorly

→ b) conduction aphasia → cannot repeat but can comprehend, names poorly

→ c) Anomic → can both repeat & comprehend but has trouble with naming

Bustami

Callosal syndrome

Disconnection of Rt. from lt. hemisphere by lesion in the corpus callosum

Dr Bustami

↓

isolation of each hemisphere in such a way that each has its own learning processes & memories that are inaccessible to the other hemisphere

↓

Visual Effects → Each hemisphere Retain its own Visual images & memories

↓

only the lt. hemisphere is able to communicate through Speech or Writing !! because of callosal disconnection

Hemialexia = patients are unable to read material presented in the left hemifield

This occurs when the splenium of the corpus callosum is involved in the lesion ⇒ such visually presented material reaches the Right visual cortex but CANNOT BE COMPREHENDED because the splenic lesion interferes with transmission of the visual impulses to the left angular gyrus

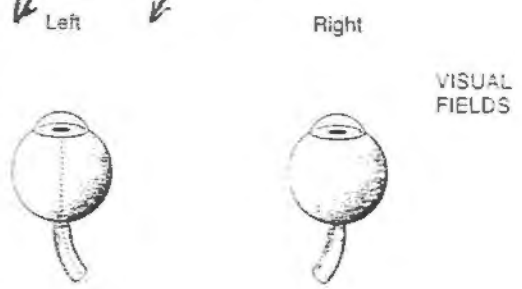

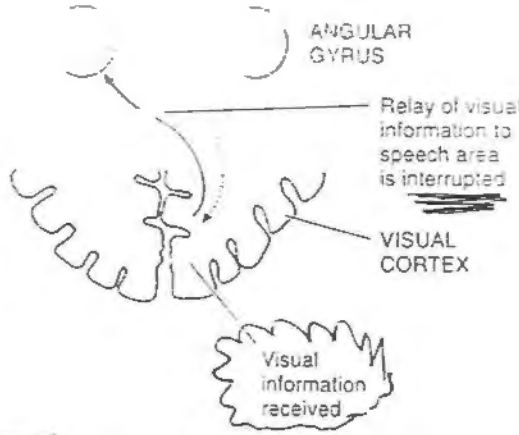

Unilateral (left) tactile Anomia

patients with callosal disconnection are unable with eyes closed to name or describe an object placed in the left hand although they readily name the same object in the right hand !!

⇩

The object placed in the left hand is perceived correctly in the Right Somatosensory cortex but cannot be identified because the callosal lesion that disconnects the right parietal cortex from the left (dominant) hemisphere

Control of Bladder function

↓

By integration of < sensory, motor, visceral } functions

↓

Sense { pain, temperature

* Somatic afferents → Sense
* Visceral afferents → Sense [bladder fullness]

* External Urethral Sphincter → controlled by Somatic motor efferents
* internal Urethral Sphincter → controlled by Sympathetic efferents
* Detrusor muscle → controlled by Parasympath. efferents

All these functions must be coordinated and monitored by central nuclei localized both in the PONS & cerebral cortex

* [Fullness] of the bladder
  - sensed by mechanoreceptors in the bladder wall
    ↓
  - Information is relayed to the sacral parasympathetic neurons at $S_2 - S_4$ as well as to the CORTEX via the spinothalamic tract

* [Innervation] of the urethral sphincters:
  (1) internal urethral sphincter at the neck of the bladder supplied by sympathetic fibres from lateral horn $T_{12} - L_2$

2) The External urethral sphincter

- is striated skeletal muscle
- supplied by the pudendal nerve ($S_{2,3,4}$)
- $S_{2,3,4}$ → Onuf nucleus
- Under TONIC STIMULATION

only inhibition of Onuf nucleus from the Pons will relax this muscle

Osman 16

* innervation of the detrusor muscle → Smooth muscle
  - by parasympathetic nerves that originate from the lateral horn at $S_{2,3,4}$
  - Relaxation of the detrusor muscle is through inhibitory sympathetic fibres

Central control of micturition

- central (higher) centres
  - frontal lobe of the cerebral cortex (paracentral lobule)
  - PONS

→ The periaqueductal grey (PAG) → acts as a relay centre between inputs from both the cortex and the spinal cord → To the Pons

→ In the Pons → Pontine micturition centre (PMC) will Activate neurons that facilitate voiding (detrusor muscle via sacral parasympathetics) & Inhibit neurons that would facilitate urine storage. (urethral sphincters via Onuf nucleus & thoracolumbar sympathetic).

- A pontine storage centre (PSC) coordinates the storage of urine in the bladder & facilitates the contraction of the urethral sphincters as well as the relaxation of the detrusor muscle

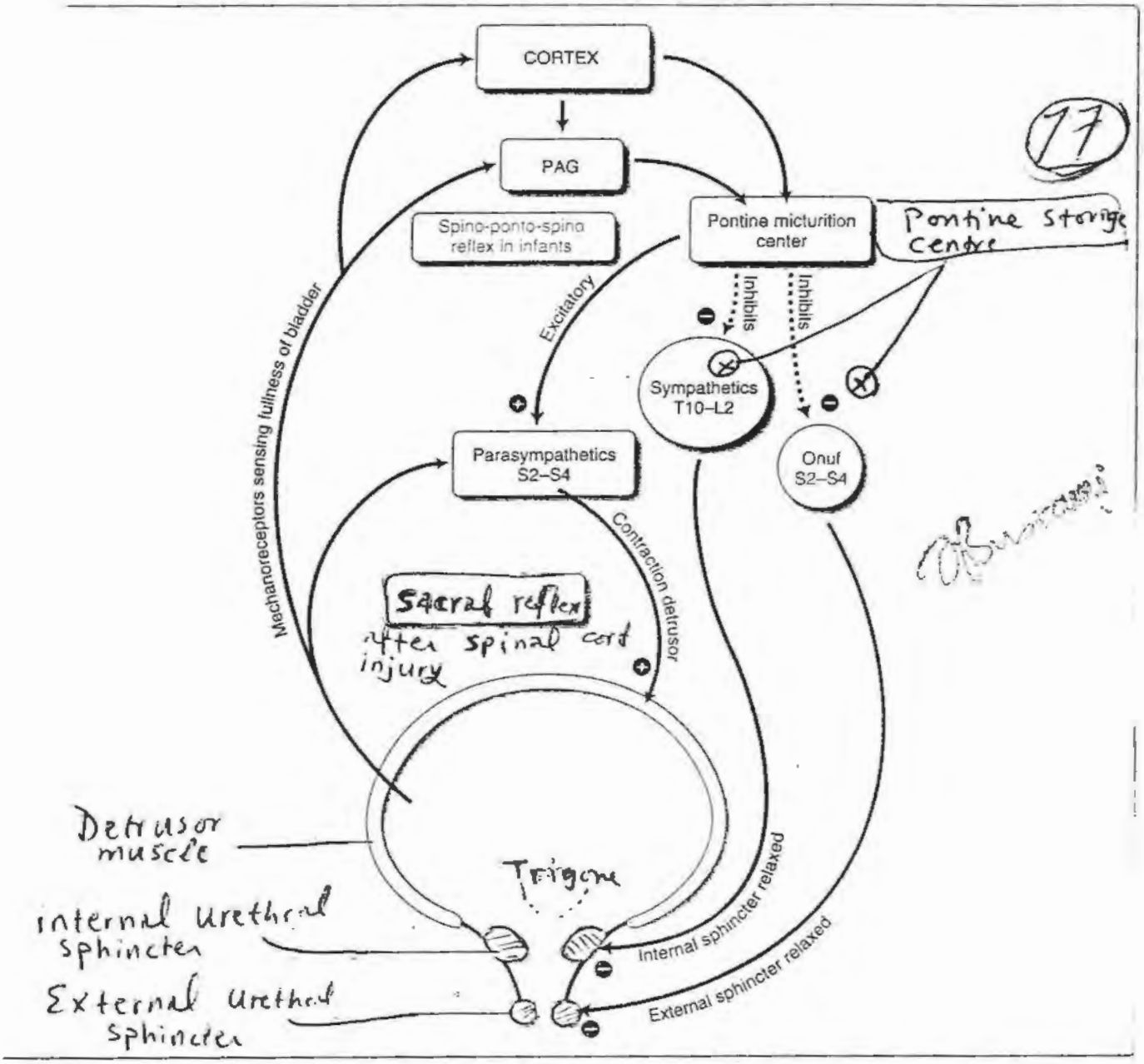

Figure 4.11
The control of micturition. PAG = periaqueductal gray.

Bladder control after spinal cord injury: In spinal cord injury rostral to the lumbosacral levels, voluntary influences from the cortex and the pons to the spinal cord are eliminated. At first, the bladder is **areflexic** with complete urinary retention, which requires catheterization. The next step is **automatic micturition** via the spinal reflex pathway (see Figure 4.18), where mechanoreceptors sensing the fullness of the bladder directly activate sacral parasympathetics causing detrusor contraction. Because the influence of the PMC is gone, the external urethral sphincter is not relaxed during contraction of the detrusor. This leads to incomplete emptying of the bladder due to **detrusor-sphincter-dyssynergia**. Patients will require daily catheterization to ensure complete emptying of the bladder.

The importance of defining the aphasia !!

1. The definition of the aphasia (Localizes) the level of the nervous system lesion.

{If (aphasia is present) → the lesion is usually in the left cerebral cortex}

Bustami

A patient with Paresis of the Right hand (U.L) and a mild aphasia has a lesion in the cerebral cortex but not a brachial plexus lesion (LMNL)

2. Aphasia implies dysfunction of the middle cerebral artery territory & is often caused by disease of the internal carotid artery in the neck → Marked stenosis of the internal carotid may be surgically correctable → if recognized & treated → a mild transient aphasia may be prevented from becoming global

3. The sudden onset of (fluent aphasia) without hemiparesis → often means an embolus to the posterior branch of the middle cerebral artery → Look for an embolic focus in the heart or in the carotid artery (If the heart is the source anticoagulation should be considered)

Remember the clinical rule → the sudden onset of aphasia without hemiparesis suggests embolus

Remember:
1. patients with global aphasia have a poor prognosis & almost never recover completely
2. patients with anomic & conduction aphasias have good prognosis & complete recovery occurs frequently
3. Broca's and Wernicks aphasia patients have an intermediate prognosis & show wide range of outcom
4. In general patient with traumatic case of aphasia do better than those in whome stroke is the cause

Alexia (Dyslexia)

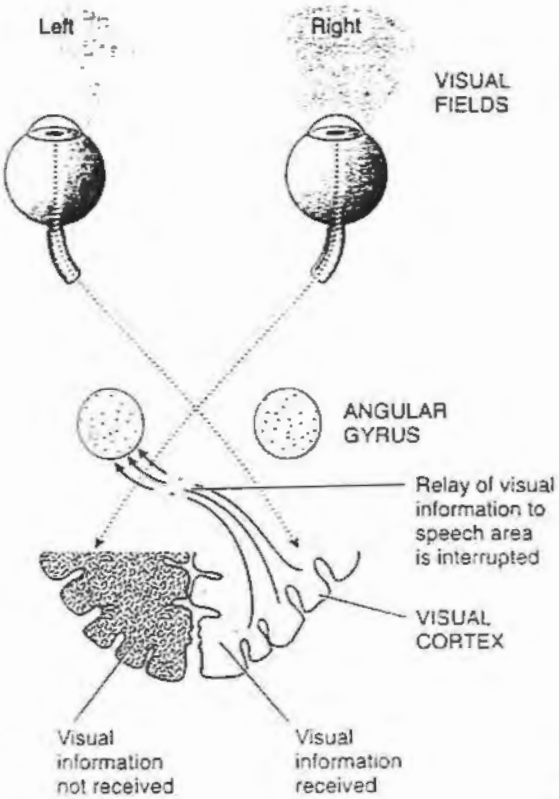

Inability to comprehend written language (Reading disability)

- acquired (in stroke patient) 1
- developmental 2 → (inability to learn to read normally from childhood)

- Acquired alexia
  - (A) Pure alexia (without agraphia) → Pure word blindness
  - (B) alexia with agraphia (parietal alexia)

(pure alexia without agraphia) → the defect in comprehension may manifest as an inability to read letters or words or both → (the lesion) → in the LEFT primary visual area coupled with another lesion in the splenium of corpus callosum

① The lesion in the left visual area prevents visual stimuli entering the left hemisphere from reaching the left (dominant) angular gyrus which is necessary for comprehension of written language ② The lesion in the splenium of the corpus callosum prevents visual stimuli entering the intact right visual area from reaching the left angular gyrus

Writing is normal but the patient cannot read what he or she writes

* Pure alexia without a splenic lesion ? deep lesion in the occipitotemporal region that isolates both visual cortices from left angular gyrus !!
* In (alexia with agraphia) → there is a defect in both reading comprehension & writing → lesion in the dominant angular gyrus hence the name parietal alexia

Voiding

In infants → No voluntary control of bladder function

voiding is coordinated via Spino-Ponto-spinal reflex mechanism

mechanoreceptors in the bladder wall sense bladder fullnes → send impulses to the pontine micturition Centre (PMC) → the PMC INHIBITS sympathetic at T10-L2 level & Onuf nucleus → causing relaxation of the internal & external sphincters.

In addition excitatory input to the sacral parasympathetics results in contraction of the detrusor muscle & → voiding....

⇓

Around the age of 3 years

↓

Voluntary control of bladder function becomes possible through the cortical areas

↓

These cortical areas (in the frontal lobe) asses whether or not it is acceptable to void & will then influence the PMC & PSC through PAG.

The Atonic bladder = Detrusor areflexia or hyporeflexia

L.M.N bladder

autonomous bladder

Caused by → tabes dorsalis
→ crushing injuries to sacral region of spinal cord

destruction of the sensory nerve fibres from the bladder to the spinal cord → prevents transmission of stretch signals from the bladder → prevents micturition reflex contractions

- Despite intact efferent fibres from the cord to the bladder
  intact neurogenic connections with the brain

} the person LOSES ALL BLADDER CONTROL

- Loss of sensation associated with bladder destinsion

the bladder becomes extremely disiended

overflows a few drops at a time

outflow incontinence = overflow dribbling

TR. of detrusor hyporeflexia
- → Cholinergic agents → bethanecol (Urecholine)
- → alpha adrenergic blockers → Phenoxybenzamine

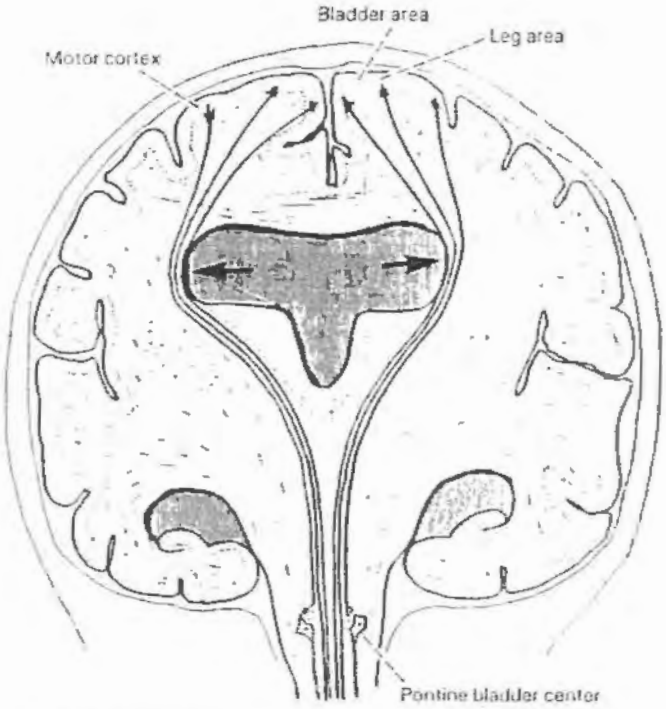

Fig. 40-7 Normotensive hydrocephalus. Expansion of the lateral ventricles (arrows) stretches corticospinal fibers supplying leg motoneurons and corticopontine fibers controlling the bladder.

interruption of loop ① (cortico-reticular loop)

⇓

In adults, loop ① may be interrupted BILATERALLY by

(A) enlargement of the lateral ventricles associated with internal hydrocephalus

(B) disease of the anterior cerebral artery (the arteries supply the pelvic and lower limb areas of the sensorimotor cortex)

(C) meningioma of the falx cerebri

⇓

Such patients have FREQUENT SPONTANEOUS EMPTYING of the bladder i.e a reversion to infantile behaviour

Remember ⟹ cortical control of the detrusor centre is not established until early in the second postnatal year ⟹ until then, the detrusor centre empties the bladder every 2-4 hours, as the bladder fills.

Urge incontinence ? → A variety of neurological disorders having in common a FREQUENT DESIRE TO MICTURATE including:

- → Multiple sclerosis
- → Parkinson's disease
- → diseases of the frontal lobes of the brain

} → hyperactivity of the detrusor centre in these patients implying that the frontal cortex, basal ganglia & cerebellum normally exert an inhibitory control

Normotensive hydrocephalus

→ occasionally occurs in men some weeks or months after a head injury → The patients develop a triad of symptoms

intellectual deterioration → Spastic gait → urinary incontinence

The symptoms are caused by expansion of the lat. ventricles → atrophy of frontal cortex ⊕ compression of corticospinal & corticopontine fibres skirting the ventricles

Ussrani

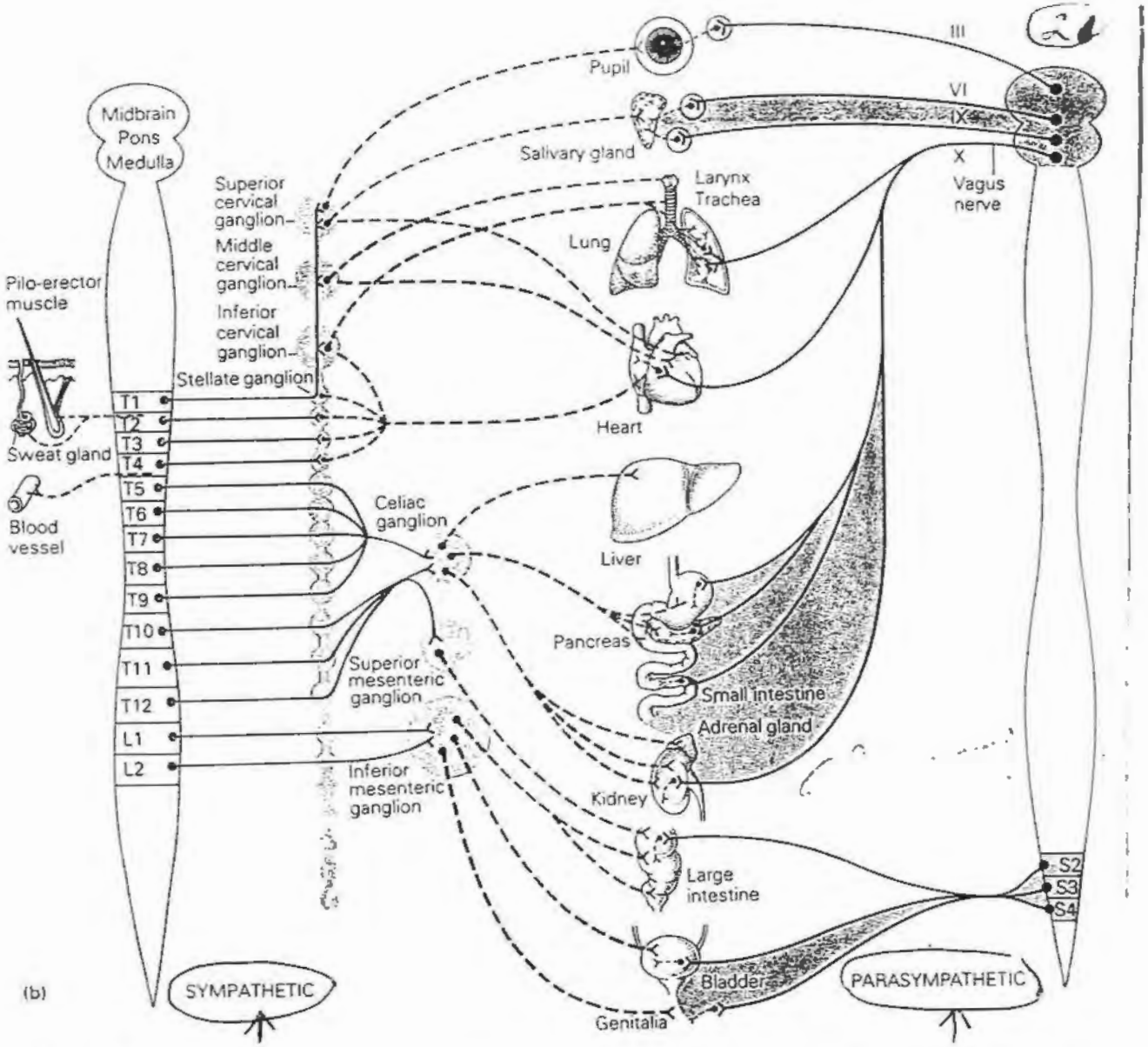

→ the sympathetic & parasympathetic nervous system have distinct anatomical differences & also release different neurotransmitters at their target sites

→ sympathetic forms THORACOLUMBAR OUTFLOW !!
i.e the preganglionic sympathetic neurons are present within the intermedio-lateral horn of all thoracic ($T_1 - T_{12}$) segments and upper two lumbar (L_1 & L_2) segments

→ parasympathetic .... forms CRANIOSACRAL OUTFLOW !!
i.e the preganglionic parasympathetic neurons are present within the brainstem & sacral region of spinal cord ⇒ In the brainstem the axons of the parasympathetic neurons RUN ALONG CERTAIN CRANIAL NERVES (3, 7, 9, 10) while in the sacral region of spinal cord they run along $S_{2,3}$ or $S_{3,4}$ spinal nerves

→ The Sympathetic nervous system Simultaneously activates MORE ORGAN SYSTEMS than the parasympathetic N.S

- During stress responses it increases
  - heart rate
  - blood pressure
  - rate of Respiration

- In parasympathetic responses different organ systems are activated separately

Bustrami

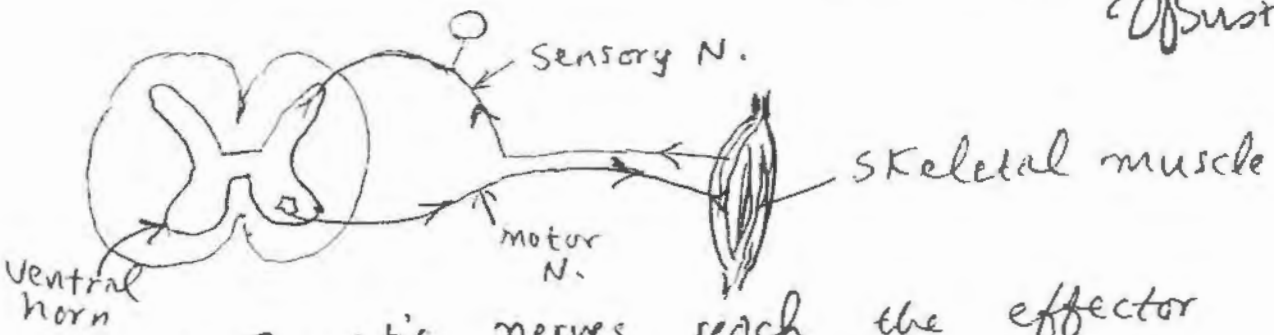

1- Somatic nerves reach the effector organ → (Skeletal muscle) DIRECTLY

2- cell body (perikaryon) of the somatic motor nerve are present within the ventral horn of spinal cord (alpha + gamma motoneurons)

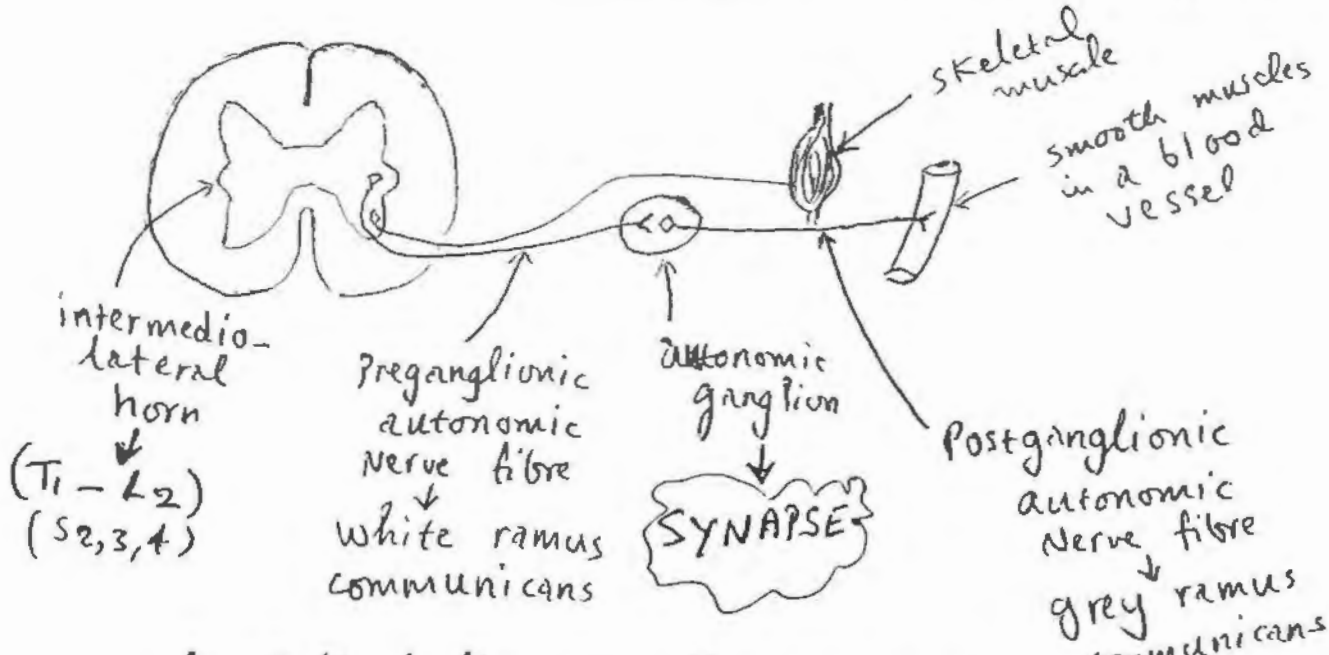

1. Cell bodies of the Preganglionic autonomic nerves are within the intermediolateral horn of spinal cord

2. Befor reaching the effector organs (smooth muscles, cardiac muscles, glands) the preganglionic nerve should synapse with neurons within an autonomic ganglion → Postganglionic fibres → effector organ

How each spinal nerve acquires a Post-ganglionic (grey-ramus communican) sympathetic fibre ??

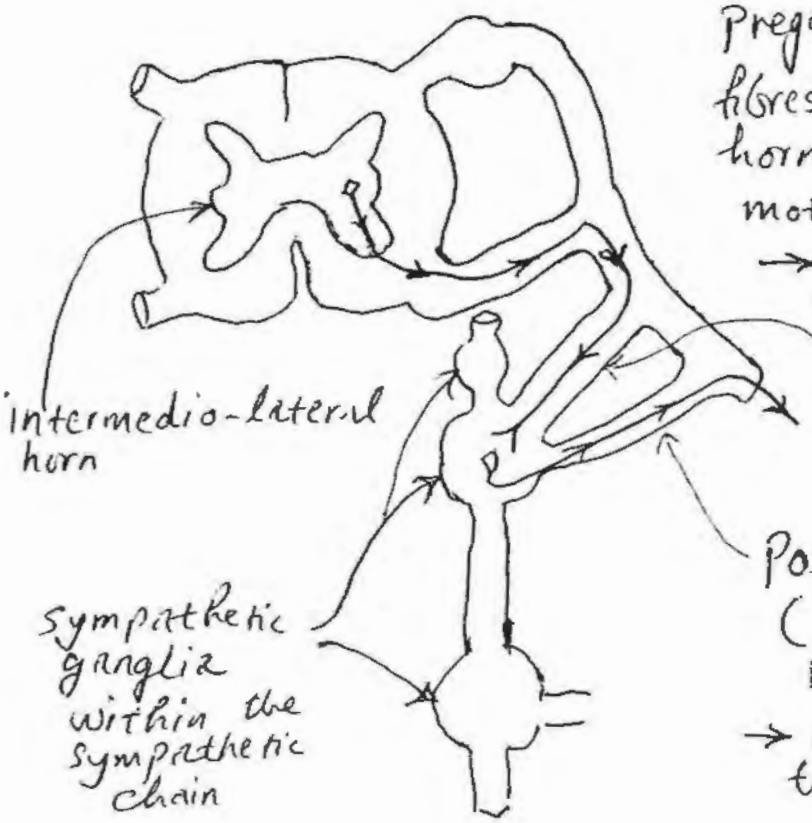

(1)

Preganglionic sympathetic nerve fibres leave the intermediolateral horn → run along the ventral motor root of a spinal nerve → leave the spinal nerve & run along the preganglionic white ramus communican → Synapse within a sympathetic ganglion

Postganglionic sympathetic (grey ramus communicans) Run along a spinal nerve → reach effector organs in the body wall & limbs

- sweat glands
- smooth muscles in the wall of blood vessels
- arrector pilae muscles

Bustami

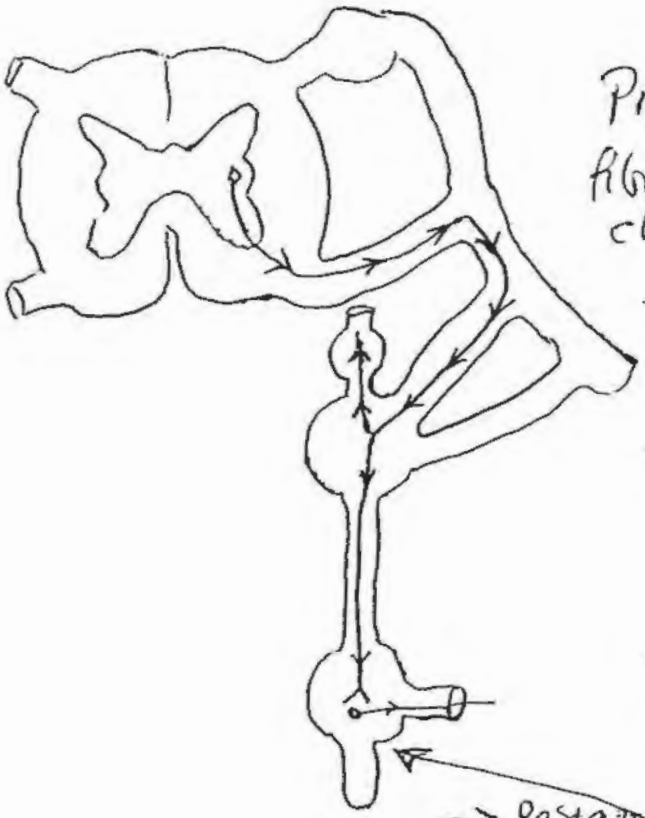

(2)

Preganglionic sympathetic fibres enter the sympathetic chain & DO NOT SYNAPSE → ASCEND OR DESEND within the sympathetic chain ←

→ Ascend into the cervical region or descend into the Lower lumbar region (below L_2) where there is NO intermediolateral horn in the spinal cord i.e NO Preganglionic sympathetic fibres → (synapse within ganglia in cervical & lumbar regions)

→ Postganglionic to effector organs

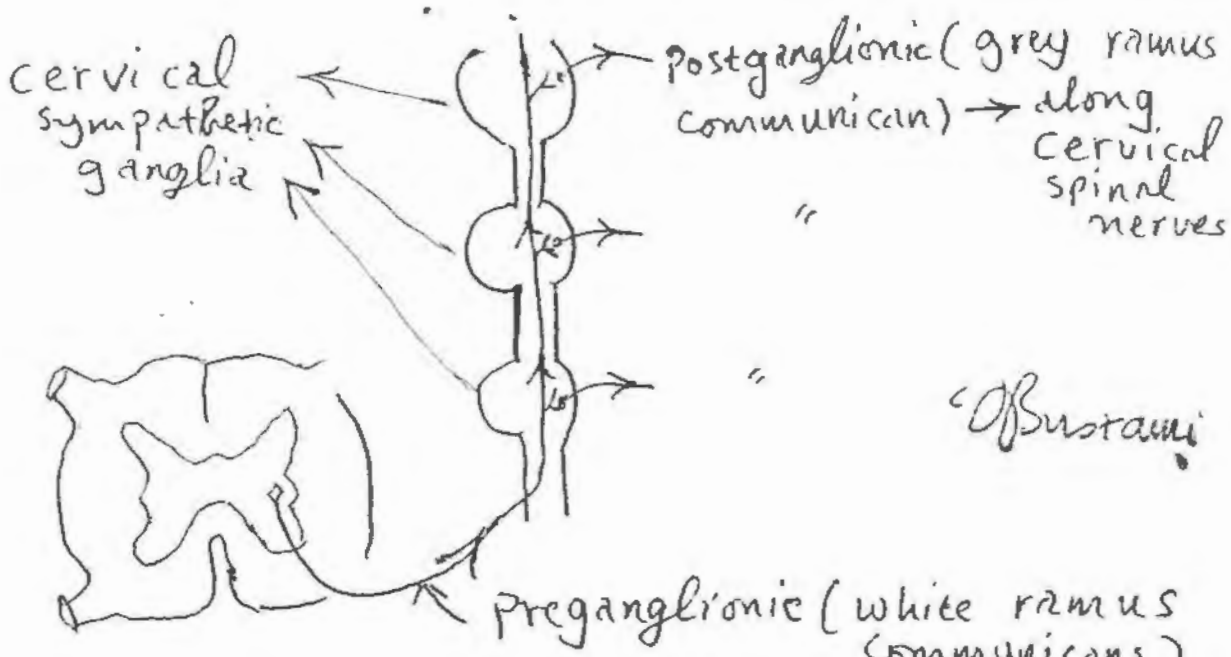

'Obustami

FROM T_1 & T_2

→ interruption of the Sympathetic chain opposite the neck of 1st Rib (cancer apex of lung)
→ No Sympathetic supply to head & Neck
→ HORNER SYNDROME
- Ptosis (Paralysis of the smooth part of Levator palpebrae muscle)
- miosis
- anhydrosis

→ Miosis !! constriction of pupil (Sympathetic dilate pupil !!)
↓
interruption of Sympathetic → the constrictor parasympath will take over

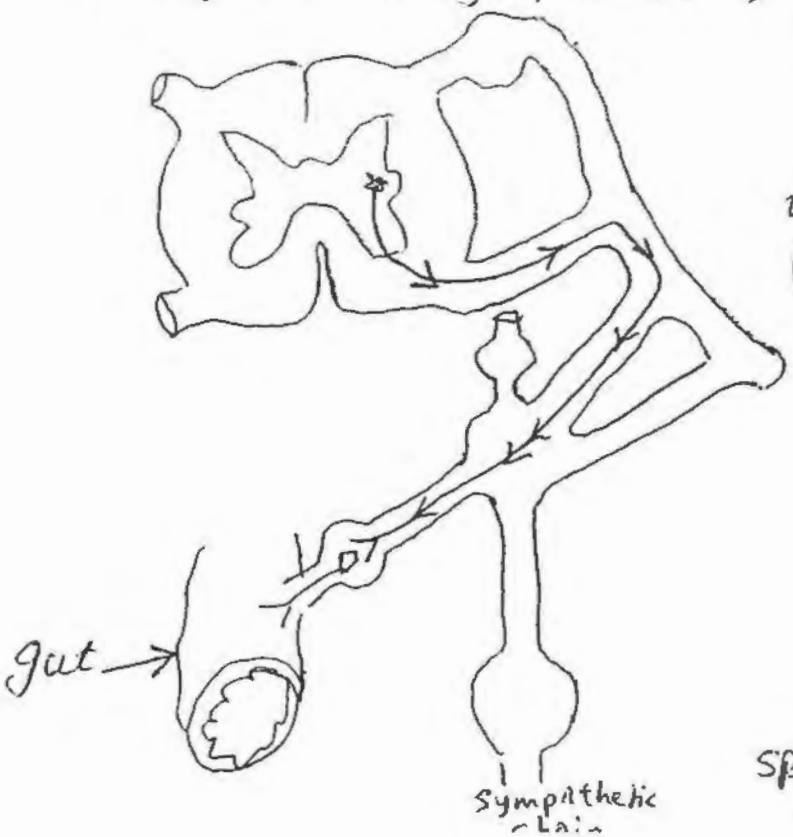

3

the preganglionic Sympathe fibres enter the sympather chain → DO NOT SYNAPSE
→ LEAVE THE CHAIN AS PREGANGLIONIC
⇓
Synapse on collateral ganglia present in the abdomen (after piercing diaphragm)
↓
splanchnic (visceral) part of Sympathetic