

Sporozoa: Plasmodium.

Coccidian. Asexual division in Man (Schizogony), sexual division in the mosquito (sporogony).

Plasmodium vivax > *P. falciparum* > *P. malariae* > *P. ovale* as a cause of malaria.

P. knowlesi (SE Asia) infects monkeys, occasionally Man. Similar morphology to *P. malariae*. Erythrocytic cycle 24 hours.

Vivax and *ovale* infect young RBC, *P. malariae* infects old RBC, while *P. falciparum* affects all cells.

The merozoite has a ' receptor ' on the RBC for entry, this is the Duffy group antigen in the case of *P. vivax*.

Erythrocytic cycle is 48 hours for *P. vivax*, *ovale* (benign tertian malaria), and *falciparum* (malignant tertian), 72 hours for *P. malariae* (quartan malaria).

Sporozoite enters blood stream after bite, invades hepatocytes in which it is called a schizont that divides actively, this is the extra-Erythrocytic (EE) stage which lasts about 2 weeks (incubation period). The resulting merozoites are discharged into the blood stream and invade the RBC's . There they develop into the trophozoite which grows and feeds on the Hb of the RBC (producing pigment, haemozoin), then it becomes a Schizont that divides eventually giving rise to merozoites that rupture the RBC and invade fresh ones. Some trophozoites do not undergo schizogony, instead they develop into male or female gametocytes, that are sucked by a mosquito in which fusion of two (after further development) gives rise to a zygote which eventually gives rise to many sporozoites that migrate to the salivary glands ready to be passed onto a new host.

In the case of *P. vivax* and *ovale* a dormant form may develop in the liver cell called a hypnozoite which may be responsible for relapses.

Highest parasitaemia is produced by *P. falciparum* 10-40 % of RBC's may be affected. Black water fever from excessive haemolysis, thromboses leading to cerebral malaria coma and death. Also I. C. nephritis especially with *P. malariae*.

Causes 1-3 million deaths a year. It remains a major burden in tropical countries.

Malaria means mal air near swamps.

Bite of the female anopheles, sporozoites travel to the liver cells.

CSP (circumsporozoite protein) binds exclusively to hepatocytes.

Eventually the hepatocyte ruptures releasing thousands of merozoites, this corresponds to the beginning of symptoms.

In *P. vivax* and *ovale* some sporozoites do not divide immediately (hypnozoites) but remain dormant for months before dividing, causing relapses.

P. vivax merozoite has Duffy group as receptor.

P. falciparum : sialoglycoproteins on RBC.

P. falciparum invades all stages of RBC, *vivax* reticulocytes, *ovale* and *malariae* invade older RBC's.

The sporozoite degrades the haemoglobin and parasite molecules appear on the surface of the RBC.

In *falciparum* these are responsible for adhesion to endothelial cells and hence sequestration in vital organs away from being cleared by the spleen, also to other RBC forming rosettes which also interfere with the microcirculation and hence the complications of infection in the brain cerebral malaria.

Sickle cell anaemia, thalassaemia and G6PD deficiency have similar distribution to malaria world wide and probably confer some immunity against malaria in the heterozygous (mechanism not understood).

Clinical symptoms :

Fever : rigors (synchronization is not common). Malaise.

Cerebral signs in falciparum, no meningitis.

Hypoglycaemia : infection of hepatocytes, use by parasite and patient, usually a bad prognosis.

Renal symptoms : blocking of microcirculation. Resembles acute tubular necrosis.

Chronic infection (*P. malariae*) may lead to nephritis Immune-complex disease.

Anaemia , with falciparum extensive haemolysis leads to haemoglobinuria and black water fever (black urine). Icterus may occur.

Diagnosis : Blood smear with Giemsa stain.

Features for diagnosis :

P. vivax : large RBC (probably because it infects reticulocytes), Schuffner granules, variable shapes of trophozoite (amoeboid), 16 merozoites.

P. malariae : band form, rosette (8) schizont, small RBC (not enlarged)(old).

P. falciparum : double infection, double dots on ring form, schizonts not seen in peripheral blood, banana shaped gametocytes, Maurer (comma shaped) dots.

P. ovale : distorted RBC (oval), irregular edges, Schuffner granules

Management :

1)- prevention : Insecticides (resistance).

Bed nets. Insect repellent.

2)- chemoprophylaxis : not 100% effective.

Chloroquine is the drug of choice : 1 week before, during and 4 weeks after exposure.

Alternative for resistant falciparum : mefloquine and doxycycline.

Treatment :

Chloroquine of choice + primaquine for eradication of hypnozoites.

In resistant strains : quinidine or quinine (toxic side effects).

Sickle cell trait :

1)- Infection causes sickling, thus quickly removed by spleen.

2)- Toxic oxygen produced by sickle cells killing parasite.

3)- Prevention of expression of parasite molecules on surface sparing cerebral malaria.

Babesiosis :

Disease of animals, transmitted by ticks, sporozoite infects RBC and resembles plasmodium morphologically, hence diagnostic problem.

No pigment in RBC. No schizont (binary fission).

Maltese cross triads in RBCs

Can be associated with lyme disease, same vector.

May be mild to fatal according to species.

Pentamidine, chloroquine or clindamycin.

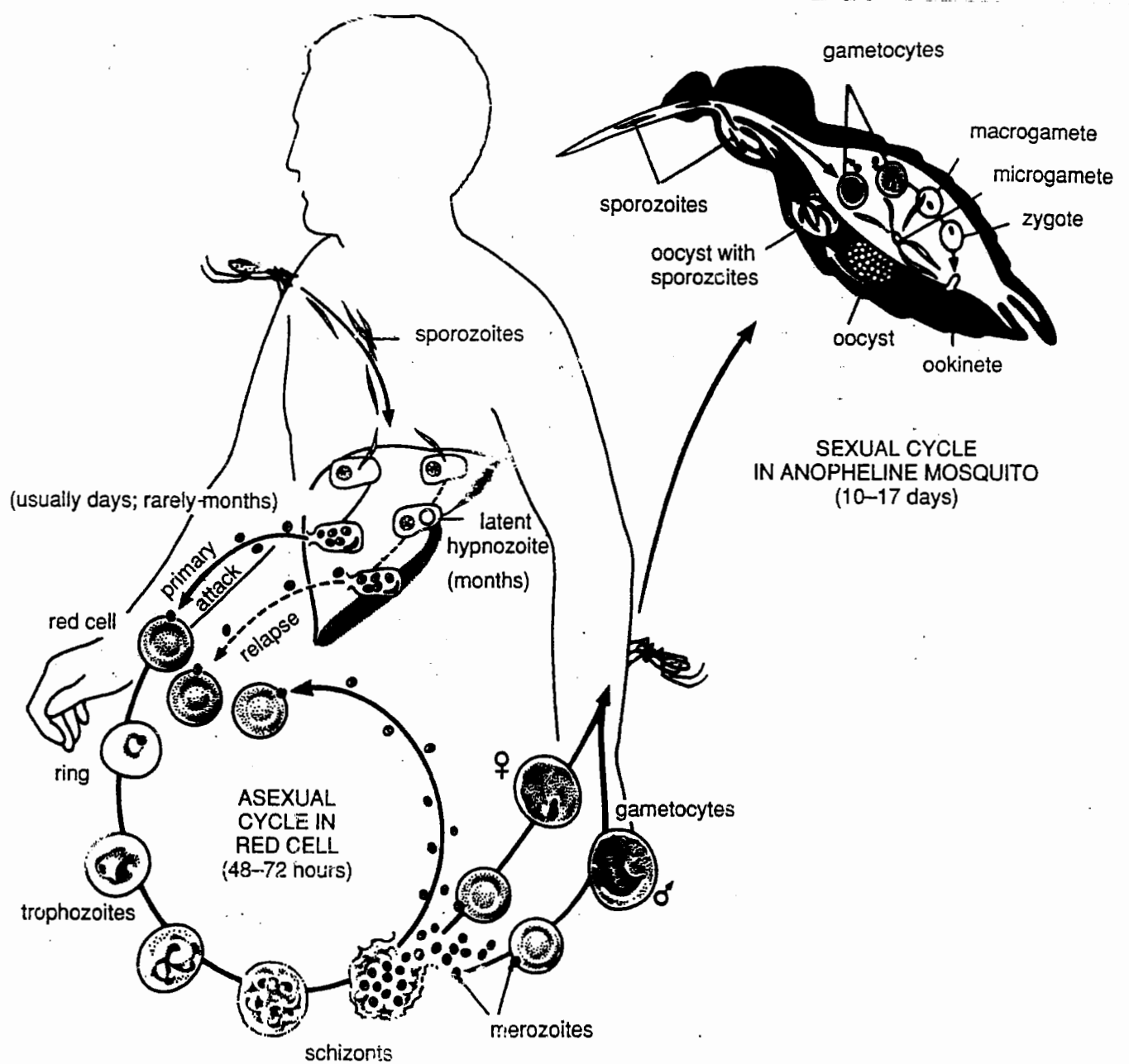


Figure 4–15. Life cycle of human malaria parasites.

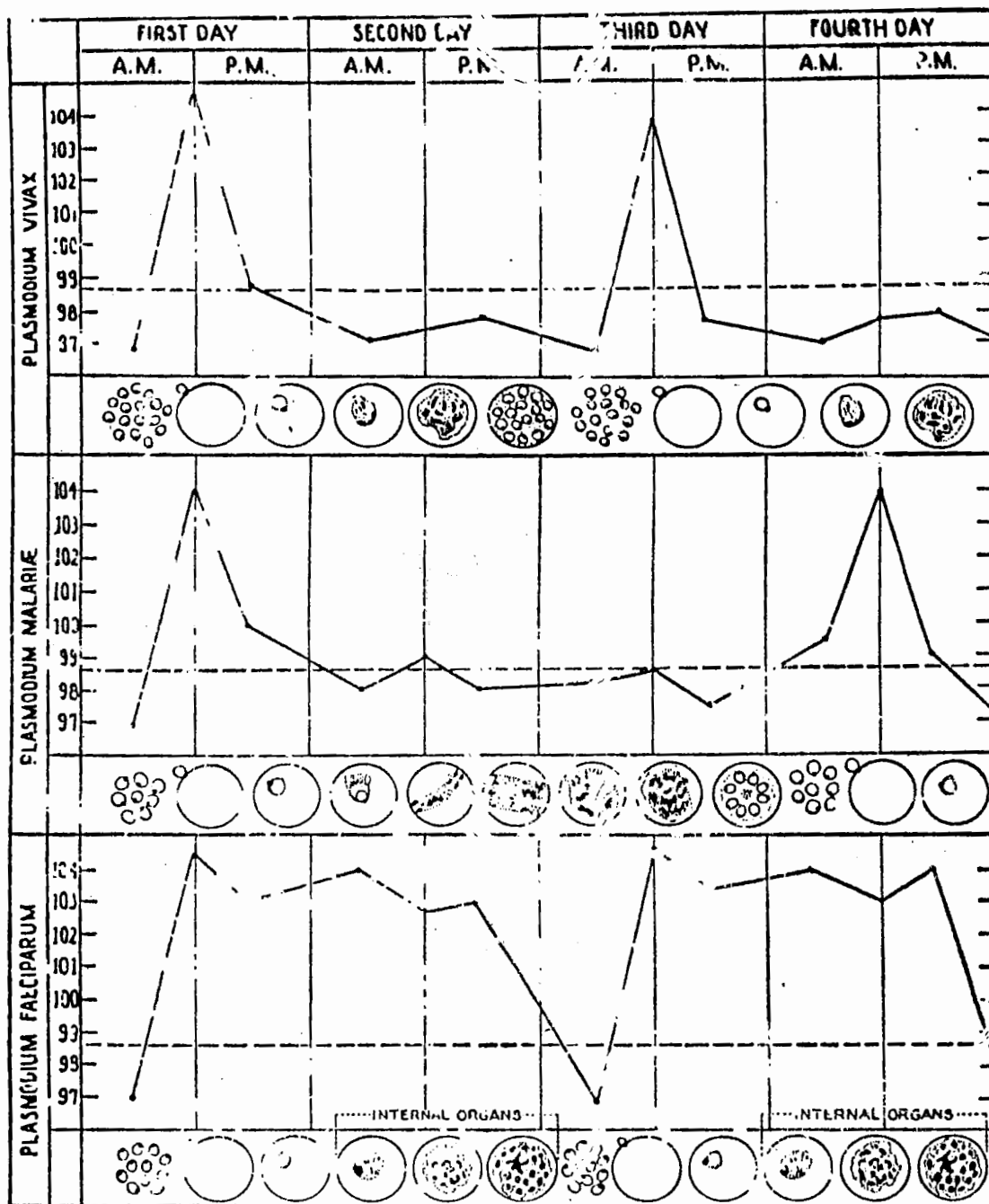


Figure 1-19. Temperature curves in malaria showing relation to growth and schizogony of malarial parasites.




Trophozoites; ring forms, basophilic stippling.




Ameboid trophozoites; enlarged red cells; Schüffner's granules.



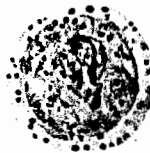Older trophozoites; note pigment and double infection.



Late trophozoites and 1 early schizont.



Schizonts; young to mature.



Developing gametocytes; mature macrogametocyte.



Trophozoites; ring forms; 1 applique form.



Young trophozoites; double chromatin dots; multiple infection.



Maturing trophozoites; note Maurer's dots. (Note, common)



Young to mature trophozoites. Early schizont.



Schizonts; rarely found in peripheral blood.




Developing gametocytes.



Immature, mature macrogametocytes; immature, mature microgametocytes.

Plasmodium falciparum



Ring-shaped trophozoites, some with Schüffner's granules.



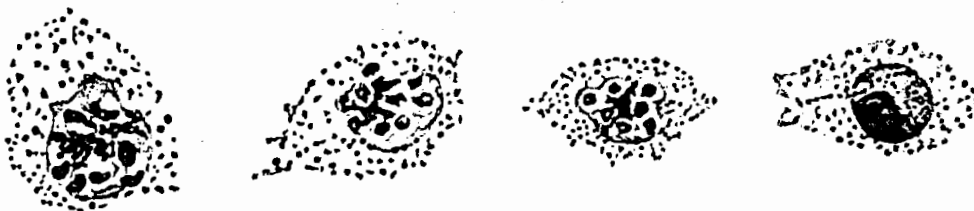
Older amoeboid trophozoites, with enlarged RBC's and all with Schüffner's granules.



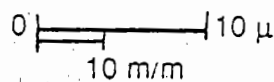
Doubly-infected cells; trophozoites. Second from left is doubly-infected cell with young gametocytes.



Progressive stages of schizonts.



Schizonts of *P. ovale*; last on right is a mature gametocyte.



Plasmodium ovale



Trophozoites; ring forms.



Young trophozoites; red collar not enlarged.



Older trophozoites; band form.



Mature trophozoites and early schizonts.



Schizonts; young to mature rosette form.



Immature gametocytes; micro- and macrogametocytes.

Plasmodium malariae