Slide #2 (Ovary)

- On the surface of ovary, we can recognize germinal epithelium (A)
- Simple cuboidal epithelium.
- It is modified peritoneum.
- It is not germinal; thus the name is a misnomer.
- Deep to the germinal epithelium is tunica albuginea; a much thinner layer than the one in testes. (B)

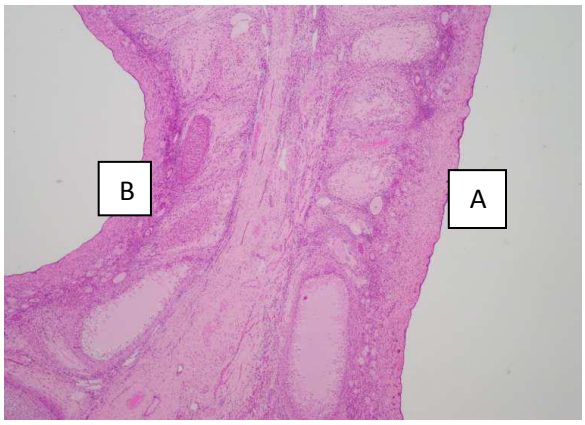

Slide #3 (Ovary)

- The outer part of the ovary is the cortex, while the inner small part is the medulla.
- Looking at the section, one can distinguish we follicles at different stages of maturation
- In this section, most of the follicles are **atretic follicles.** An atretic follicle is the remnants of a follicle that started its maturation but was not able to complete it.
- Atretic follicles do not have ova or granular cells.
- The cortex is full of these follicles. Some follicles undergo atrophy at an early stage; others atrophy at a later stage of development.
- It is not uncommon to find these follicles.

Slide#4 (Ovary)

The **mesovarium** is the mesentry of the ovary along which a branch of the ovarian

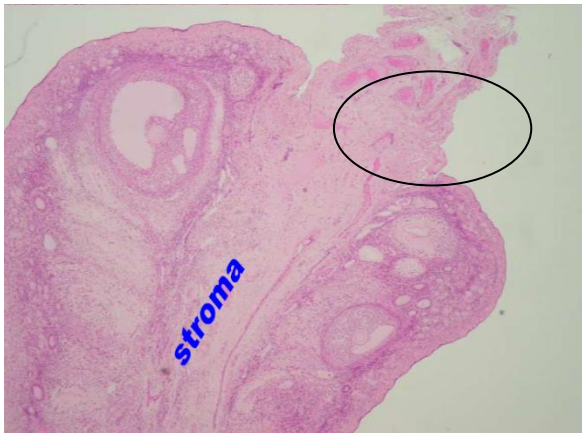

artery enters (the ovarian artery enters through the suspensory ligament).

- If you want to resect the ovary, you simply clamp the mesovarium.
- The follicle here is **<u>NOT</u>** a **mature Graafian** follicle. Although the ovum lies on the periphery, this section shows a follicle with multiple cavities. A mature Graafian follicle consists of a single cavity. As long as you see multiple cavities, it is called a **secondary follicle**. The stage that precedes this stage is the **primary multilaminar** stage. To transform from the previous stage to this one, FSH is needed. The stage that follows is the **Graafian follicle (vesicular ovarian follicle)**; FSH is transformation to this stage, as well.

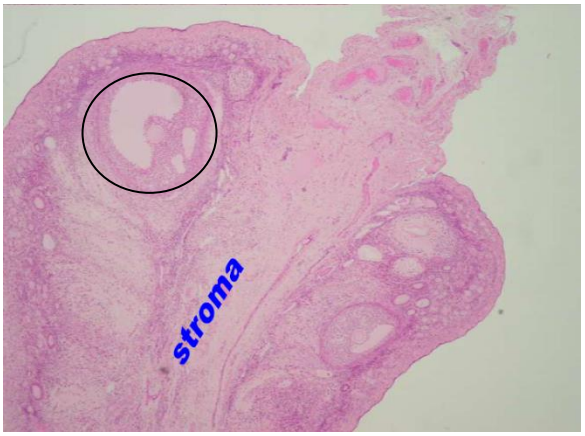

- This secondary follicle produces estrogen, stores it, then releases it into the blood. What made this follicle grow is FSH. Due to its importance, FSH needs to be regulated. This happens through a feedback mechanism.
- The secondary and mature follicles produce:
    - Inhibin: inhibits FSH
    - Activin: activates FSH
    - Follistatin: inhibits activin

<u>Slide#5 (Ovary)</u>

- In the stroma of the cortex, we see **a primordial follicle,** where flattened (squamous epithelium) surrounds the ovum.
- These primordial follicles were oogonia which were primordial germ cells.
- They come from the yolk sack
- The primordial follicle consists of an ovum inside. The ovum here is a **primary oocyte** suspended in the prophase of the first mitotic division.
- What prevents the mitotic division from being completed are the secretions of the surrounding granular cells which secrete **oocyte maturation inhibitory factor**.
- Its chromosomal pattern is **46, 4n (double);** just like the spermatocyte.

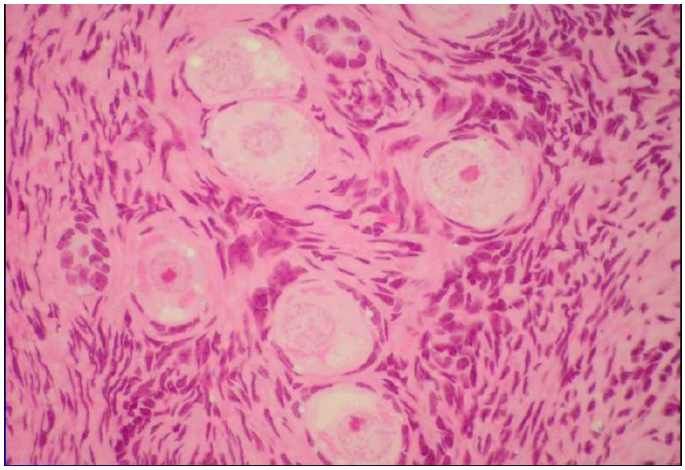

- The following stage of development is the primary unilaminar follicle.
- The cells transform from flattened to cuboidal cells.
- The ovum has not changed yet.
- This transformation does not require FSH.

Slide#6 + 7 (Ovary)

Slide 6

- Here, we see both primordial and primary unilaminar cells.

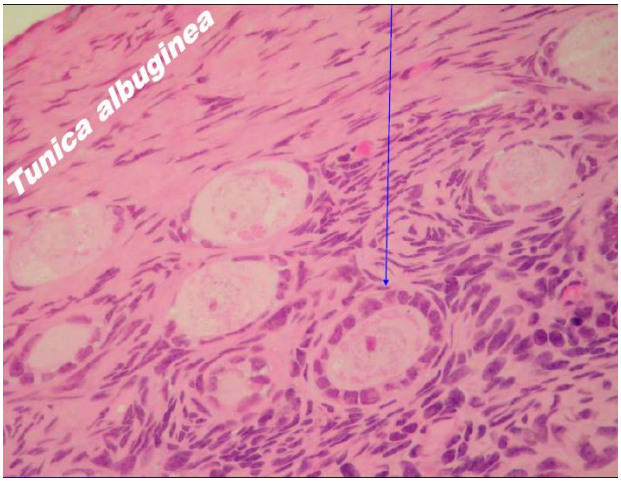

Slide#8 (Primary unilaminar cell)

- It is a magnified primary unilaminar cell.
- We can see the nucleus and the nucleolus.
- You can also notice that outside of the follicle, the theca interna and externa are starting to form.
- The follicle produces estrogen (17-β-estradiol, the most important estrogen).
- Theca interna, under the effect of LH, produces two androgens; a weak androgen

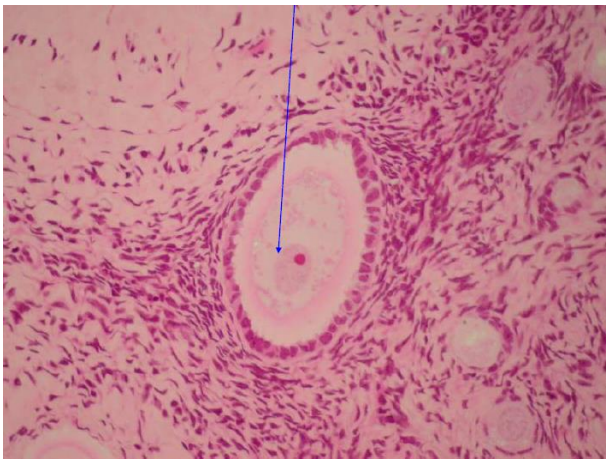

called androstenedione, and a strong androgen called testosterone.

- These androgens are absorbed by the follicular cells (granular cells) to be transformed into estrogen under the effect of aromatase, an enzyme induced by FSH.

Slide#9-11 (Primary multilaminar)

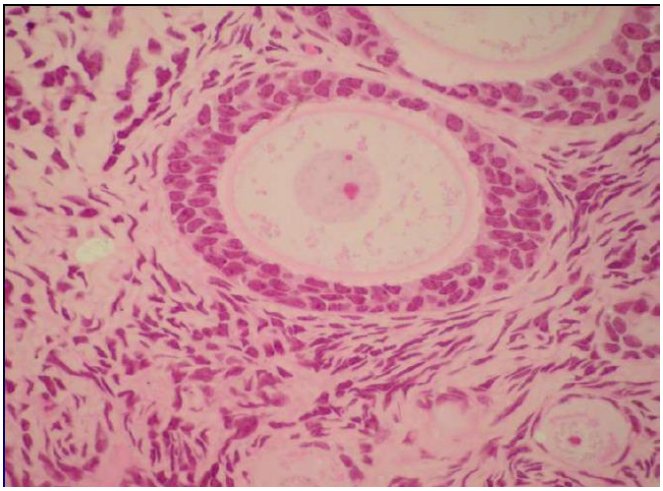

- Here we moved from a primary unilaminar follicle to a primary multillaminar follicle.
- Here we can notice the zona pellucida around. The zona pelucida is a barrier that the sperm needs to penetrate during the time of fertilization.
- FSH is not needed to complete this transformation.
- Because activin stimulates this transformation, it is said that it replaces FSH here.
- The ovum has not changed yet (still a primary oocyte)

Slide#12-17 (Secondary follicle)

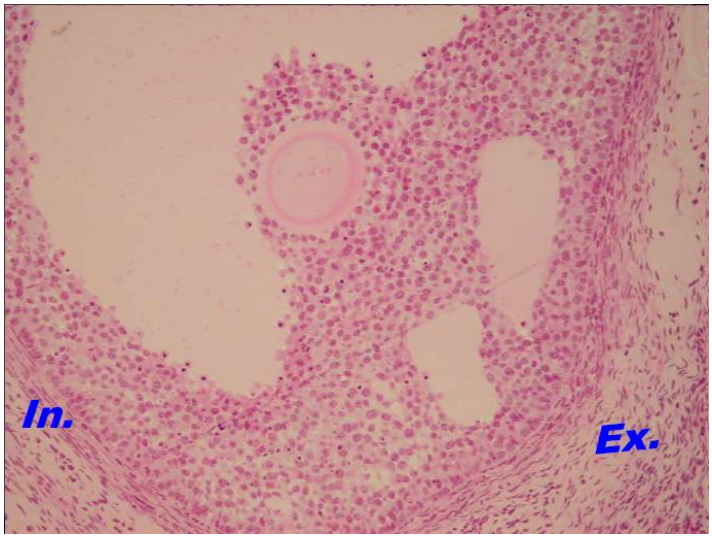

- These slides show the different parts of a secondary follicle at different magnifications.
- Although the ovum is approaching towards the periphery, we cannot say that the follicle is a mature follicle. Multiple cavities are present
- Theca are prominent as well.
- The ovum is still a primary oocyte.

- To transform the follicle from a primary multilaminar into a secondary follicle, we need FSH. Since this process is FSH induced, FSH needs to be regulated according to the aforementioned mechanism (inihibin, activin, and follistatin)
- The granular cells need to form receptors for LH as well as FSH.
- After ovulation, the remnants of the follicle give corpus luteum, and corpus luteum produces estrogen and progesterone. The receptors are formed on the surface of the granular cells under the effect of estrogen and FSH. After ovulation, and transformation into corpus luteum, LH works on both follicular and thecal cells transforming them into granulosal lutein cells and thecal luteine cells respectively (both of the newly formed cells produce estrogen and progesterone)

Slide#18 (Graafian follicle)

- This slide shows one cavity.
- Although the ovum does not lie on the periphery, we can consider it mature.

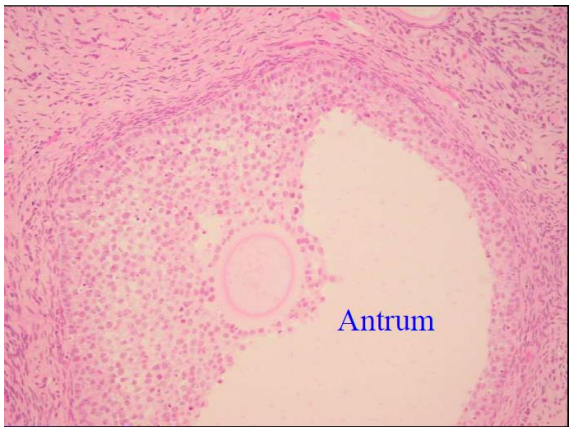

Slide#19-21 (Mature follicle)

- More typical, the ovum is on the periphery.
- The surrounding cells are called corona radiate; a barrier that prevents entrance of sperms.
- The cells that connect the ovum to the all of the follicle are called comulu ooforus
- This cavity is a single antrum full of liquor folliculi (follicular fluid).
- The cells on the wall are called membrana granulose (arrow).
- You cannot easily determine whether the oocyte is primary or secondary. This depends

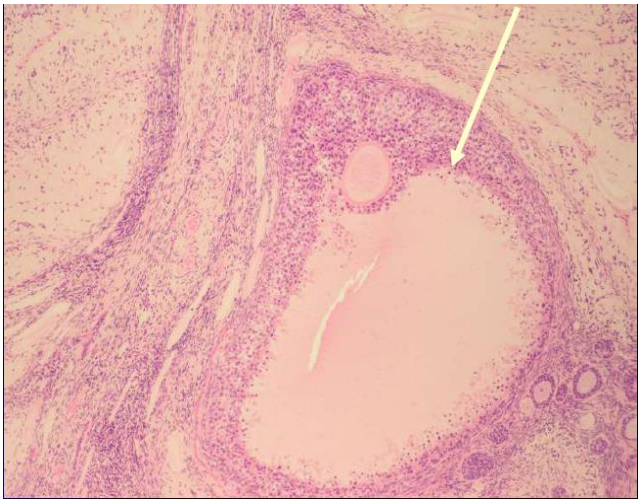

on whether it is an early or late follicle. If it is an early mature follicle, then it is a primary oocyte. If it is late (a few hours before ovulation), then it is a secondary oocyte suspended in the metaphase of the second mitotic division.

- The hormone responsible for completing the first mitotic division is LH.
- LH's most important function is the completion of the first mitotic division transforming the primary oocyte into a secondary oocyte. The rest of the stages are completed after fertilization.
- Ovulation is the release of a secondary oocyte from the late Graafian follicle.
- This growing follicle produces more and more estrogen, and estrogen is responsible for the proliferative phase of the menstrual cycle. It increases the size and number of glands. Estrogen is responsible for repair and regeneration of the endometrium during the first half of the menstrual cycle. At this stage, the endometrium is proliferating.
- How does ovulation take place?
    - It happens due to estrogen induced LH surge. During the first half of the cycle, estrogen used to exert a negative feedback action decreasing the release of FSH and LH. In the second half of the cycle, progesterone is responsible for this effect. However, in the middle of the cycle, the increase in estrogen production leads to an LH surge which stimulates ovulation.
    - LH + progesterone cause hyperemia (increase of blood flow by increasing the vascularity of the wall) and an increase in prostaglandins secretion. Prostaglandins increase the permeability allowing plasma to enter forming liquor. The collection of the fluid inside, makes the wall thinner. The thin wall, aided by collagenase (proteolytic enzyme) produced by theca externa, degenerate the wall at a very thin area called the stigma.
    - Ovulation occurs 14 days before the shedding of blood.

Slide#20 (typical mature follicle)

- Typical mature Graafian follicle.
- Secondary oocyte surrouned by theca interna

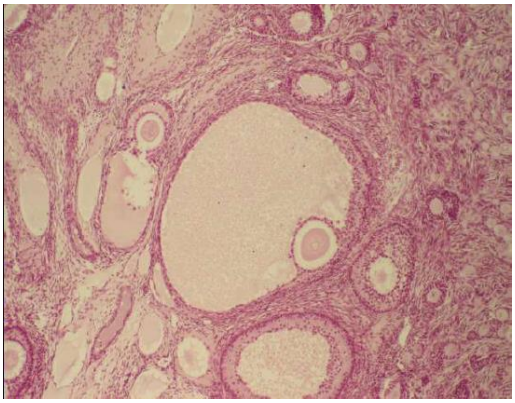

Slide#21 (Mature follicle, magnified)

- Corona radiate
- Zona Pellucida
- Comulu oophorus (thin arrow)
- Corona radiate(thick arrow)

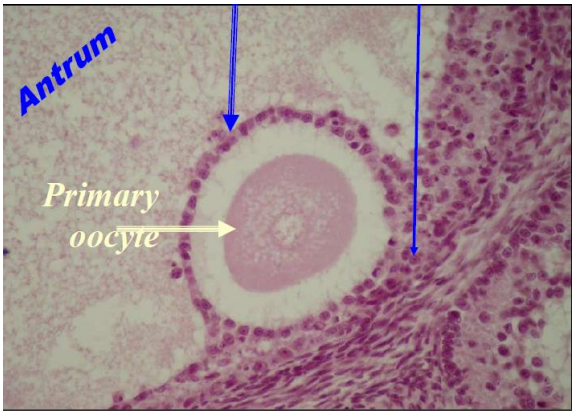

Slide#22 (Atretic follicles)

- Degeneration of granular cells and shrinking and disappearance of ovum.
- To distinguish between late and early atresia, we look at the follicle. A late atretic follicle will have the following features: the basement membrane between granular cells and theca interna persists for a long time forming a ring called the glassy membrane (circle)

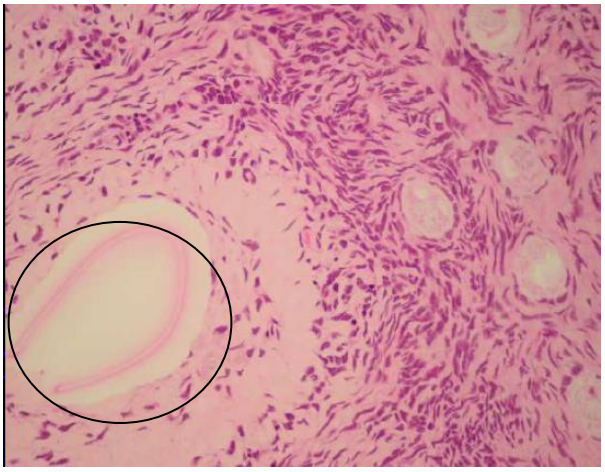

Slide#23

- Corpus luteum is formed after ovulation from the remnants of the Graafian follicle.

Slide#24

- Here, we can see granulosa cells surrounded by theca interna. Under the effect of LH, they become granulose lutein and theca lutein.

Slide#25 (Magnification of 24)

- Granulosa lutein cells are big cells with cavities.
- These cells store lipid; lipid is the base for formation of cholesterol which is the base of steroid hormones.
- These cells possess large amounts of SER and mitochondria.
- They are steroid producing cells.
- These changes enable this cell to manufacture hormones. In normal conditions, these cells would transform androgen produced by thecal cells into estrogen. This function persists, but now they become progesterone producing cells, as well.

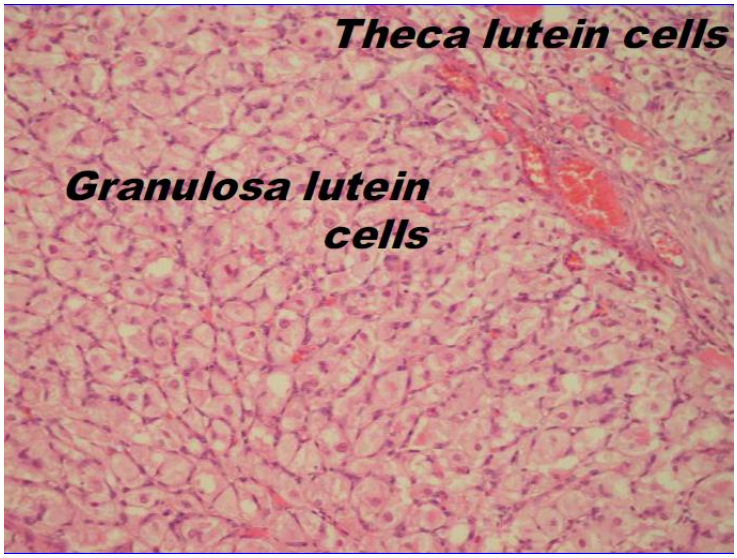

- Thecal cells used to produce androgen; now they produce androgen in addition to progesterone and estrogen.
- Overall, the corpus luteum produces progesterone and estrogen. This happens after the middle of the cycle (from day 15 up to day 25). This corpus luteum produces progesterone, estrogen, and inhibin.
- Progesterone is responsible for the secretory phase. The changes during the secretory phase are many. These changes include edema, increased vascularity, and storage of glycogen. Corpus luteum survives for 14 days; if pregnancy does not happen, it regresses and corpus albicans forms.
- Pregnancy is the easiest way to prolong corpus luteum's survival. Pregnancy increases LH. During pregnancy, corpus luteum lives for three months under the

effect of another hormone called hCG (human chorionic gonadotrophine) produced by the placenta. After three months, corpus luteum is replaced by the placenta.

- Corpus luteum is needed during the first three months of pregrnancy; after three months, the placenta takes over the job of producing estrogen and progesterone in addition to hCG. It also produces relaxin which distends the cervix during delivery. It also produces a hormone that initiates the process of delivery called corticotropine releasing factor. This hormone increases cortisol's secretion form the adrenal cortex.

Slide#26 (Corpus luteum)

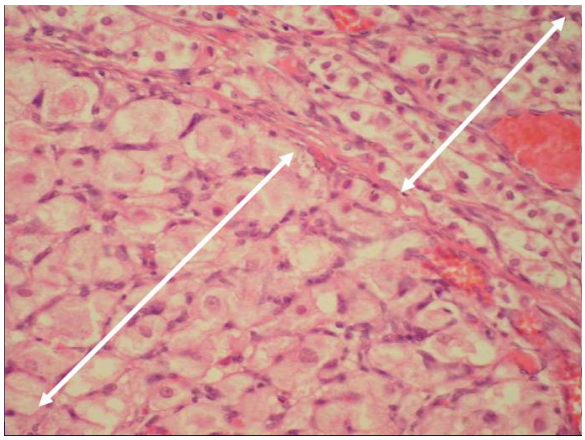

- The granular cells are larger than the thecal cells in the corpus luteum; thus, they produce more estrogen and progesterone.

Slide#27(Corpus albicans)

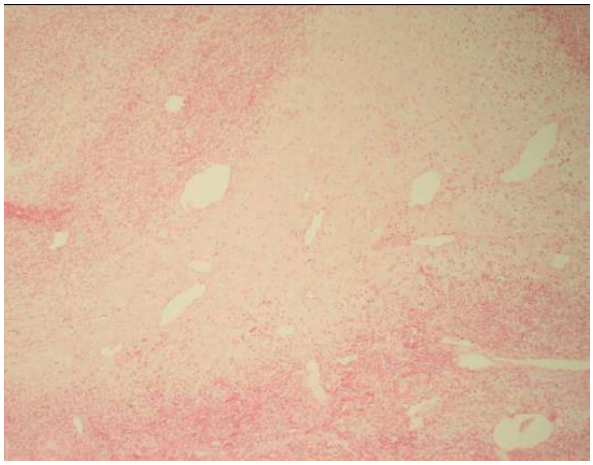

- Cells of corpus luteum die and are replaced by collagen type 1 produced by fibroblasts. Collagen type 1 is a scar on the surface of the ovary.
- The human ovary has multiple corpora albicans due to the production of a new corpus luteum every month.
- Corpus albicans is a feature of the human ovary

Slide#29 (Uterine tube)

- It is formed of three layers (inside out):
    - Mucosa
    - Muscularis
    - Serosa or Peritoneum
- The mucus membrane here forms many folds which is a feature of this area.
- These folds are primary, secondary, or tertiary.
- The presence of a complexity of folds decreases the size of the already narrow lumen.
- Outside the mucosa we the muscular layer which is formed of an inner circular and an outer longitudinal layer.

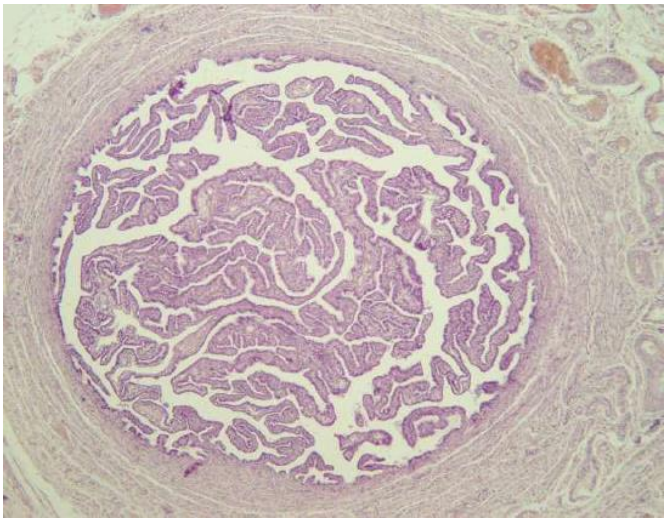

- The uterine tube is inside the broad ligament which has peritoneum surrounding it.

Slide#30

- Shows the muscular layer and the mucosa (folds)

Slide#31+32 (uterine tube epithelium)

- This epithelium is simple columnar epithelium, partially ciliated and non ciliated
- We can notice many folds filling the lumen
- The picture on the right is slide#32, a magnified image.

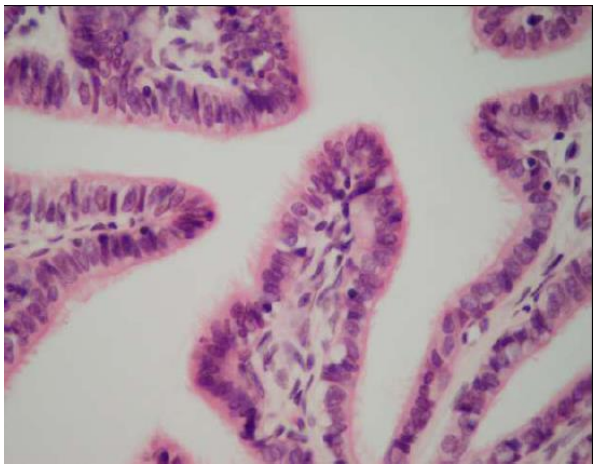

Slide#33 (low magnification uterine tube)

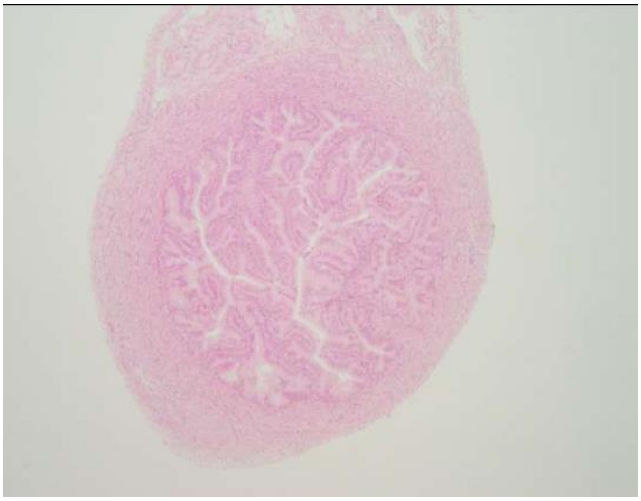

- Layers from outside in:
  - Serosa
  - Muscularis
  - Mucosa
- This picture is important because it reminds of the fact that the lumen is narrow and can be easily obstructed by any infection (Especially with highly virulent bacteria, like gonorrhea)

Slide#34 (uterine tube cilia)

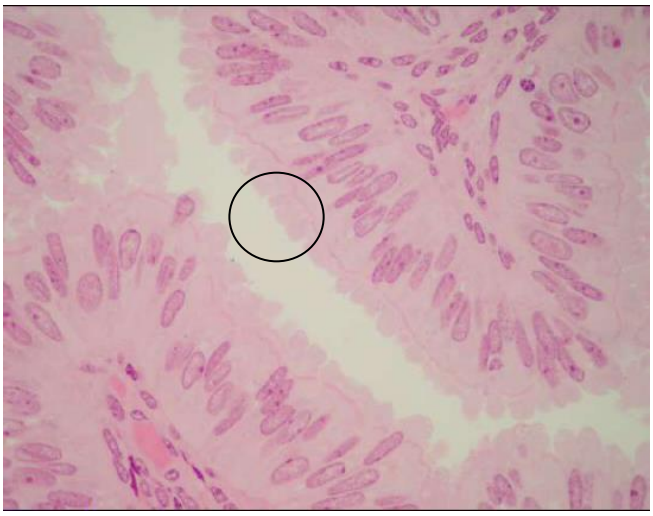

- This layer is fused cilia.
- Cilia, when treated with chemicals, fuse together.
- This section reminds us that cells in the uterine tube are partially ciliated and partially non-ciliated secretory cells.

Slide#35 (Muscular layer of uterine tube)

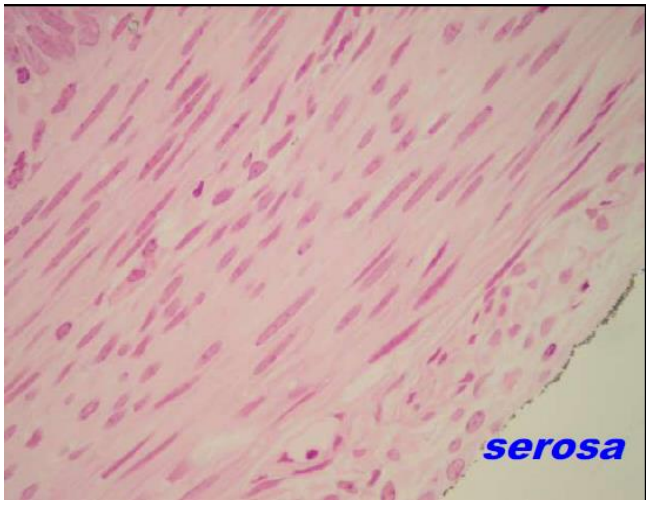

- Muscles form an inner circular and an outer longitudinal layer.
- The presence of muscles signifies ability of peristalsis.

- The ovum is pushed out of the ovary; then, the ovum is moved by the cilia towards the uterine tube.
- Once the ovum reaches the uterine tube, and gets fertilized by a sperm, an embryo starts to form. The newly formed embryo needs to be moved towards the uterus to get implanted. The peristalsis helps this.

Slide#37 (Uterus, proliferative phase)

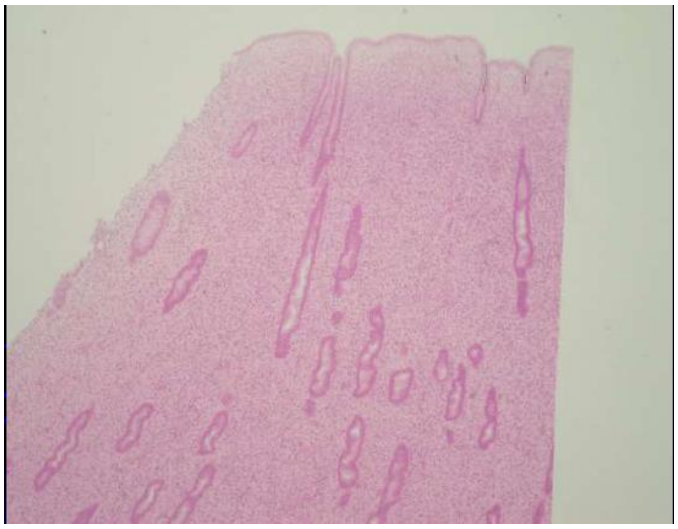

- Lining epithelium is simple columnar, ciliated and non ciliated.
- Epithelium, pushed inside, makes glands that are simple tubular glands.
- The glands are surrounded by the stroma of uterus (lamina propria).
- Lamina propria does not contain submucosa; muscles lie directly underneath.

Slide#38 (Glands and stroma)

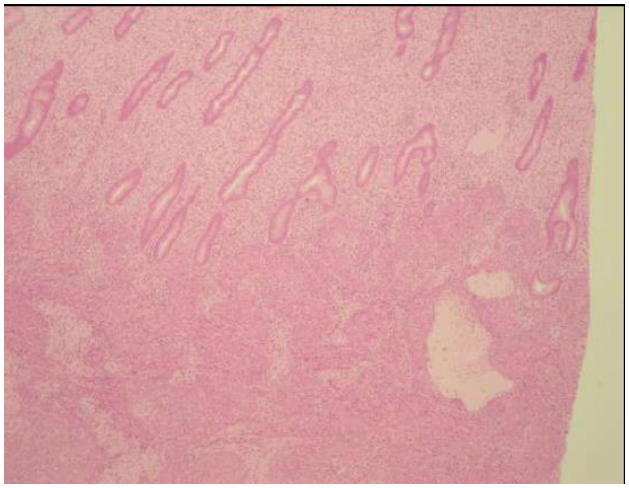

- The glands are surrounded by stroma.
- As long as the glands are simple tubular glands, this means that this section was taken during the proliferative phase.
- This stage is corresponds to high levels of estrogen production in the ovary
- Estrogen builds the wall of the endometrium.

Slide#39 (Glands and stroma)

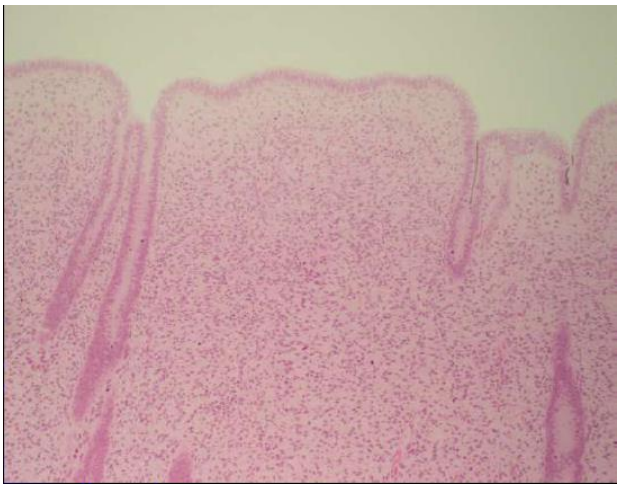

- Here, the glands are simple tubular and surrounded by the stroma of the ovary.
- This means that we are in the proliferative phase and the ovary is responsible for the growth of these glands (number wise and size wise).

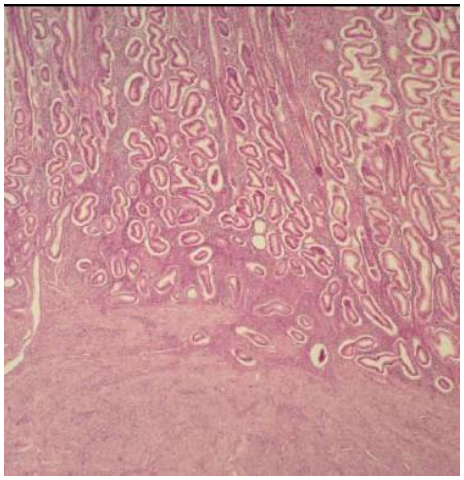

Slide#40 (Secretory phase)

- The glands here are full of secretions and are tortuous.
- This is highly suggestive of secretory phase.

Slide#41 (High magnification secretory phase)

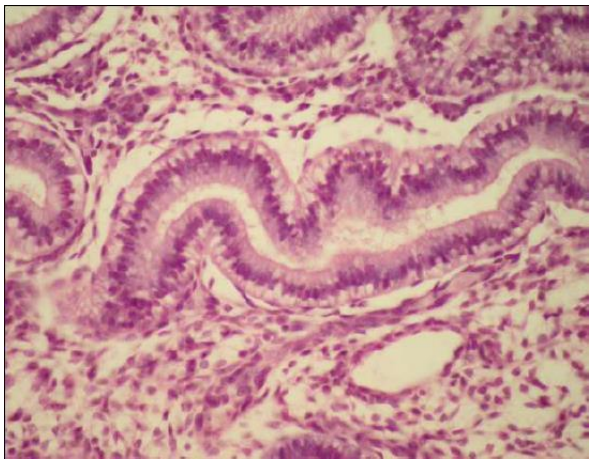

- These glands are endometrial glands that are tortuous and full of secretions.
- It is also called the luteal phase and is governed by corpus luteum which secretes progesterone and estrogen.
- This phase in the endometrium corresponds to corpus luteum in the ovary.

Slide#42 (Menstrual phase)

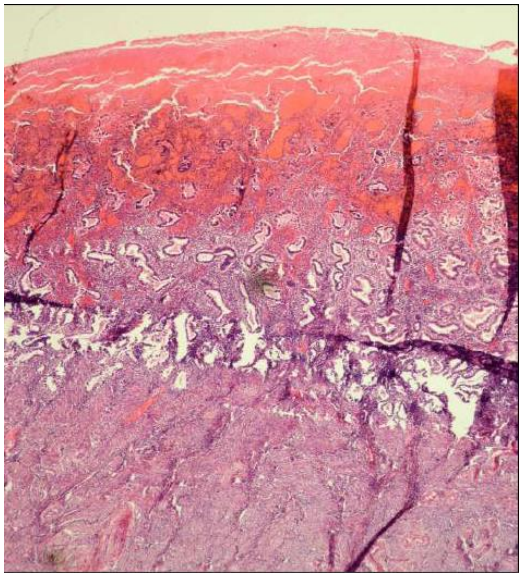

- Blood is collected under the mucosa.
- During the first 4-5 days of the menstrual phase, the endometrium (the functional layer), will go through ischemia, necrosis and shedding.
- Ischemia is caused by vasoconstriction of the spiral arterioles. This vasoconstriction is first intermittent then continuous.

Slide#43 (Menstrual phase, high magnification)

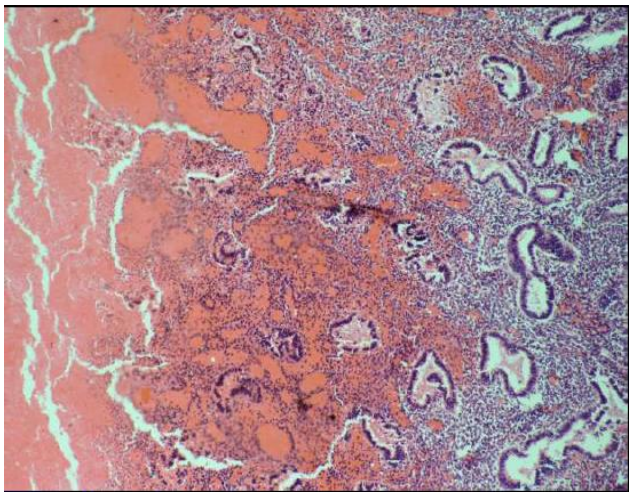

- Ischemia does not only involve the glands, it also involves the arteries.
- The superficial arch of the artery explodes releasing blood which collects under the mucosa and helps in shedding.
- The menstrual flow (blood) is a mixture of arterial and venous blood in addition to shed epithelium and some secretions.

Slide#45 (Vagina)

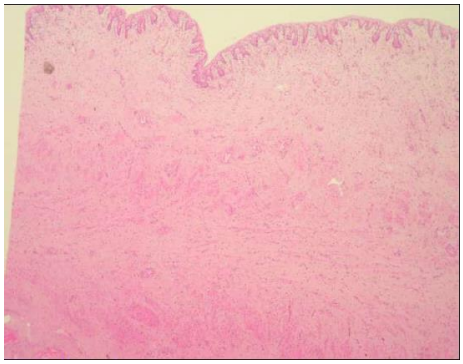

- Mucosa
- Muscularis
- Adventetia

Slide#46 (Vagina, magnified)

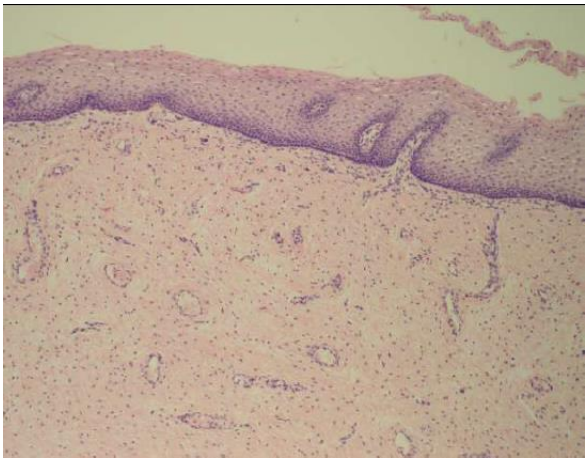

- Mucosa is lined by stratified squamous epithelium, non-keratinized.
- Underneath we find lamina propria.

Slide#47 (Vagina, magnified)

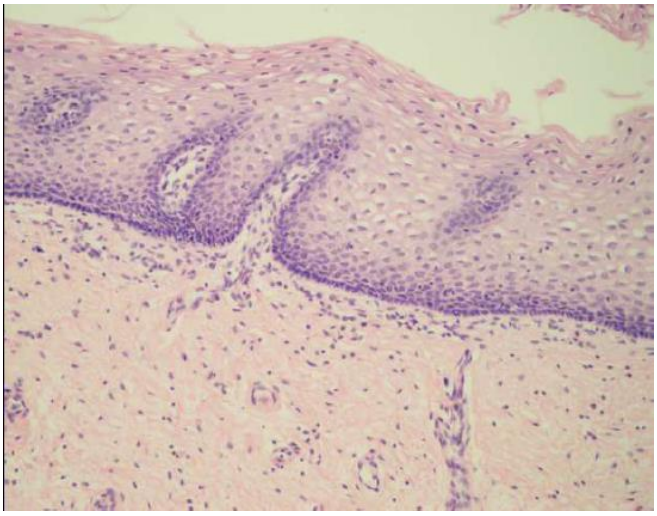

- Here we see that the cells are vacuolated.
- These vacuoles contained glycogen. These cells used to store glycogen. The superficial cells will desquamate with their glycogen. They fall into the lumen of the vagina.
- There, lactobacilli cause fermentation in glycogen forming lactic acid. This increases the acidity of the vagina protecting the vagina from invading bacteria.
- If we look at the wall of the vagina, we have lamina propria and dense connective tissue.
- We do not have any glands.
- The secretions in the vagina come from the cervix.
- We have a lot of elastic tissue. If we used a special stain, we can see many elastic fibers.

Slide#49 (Cervix; look at the right portion of the picture)

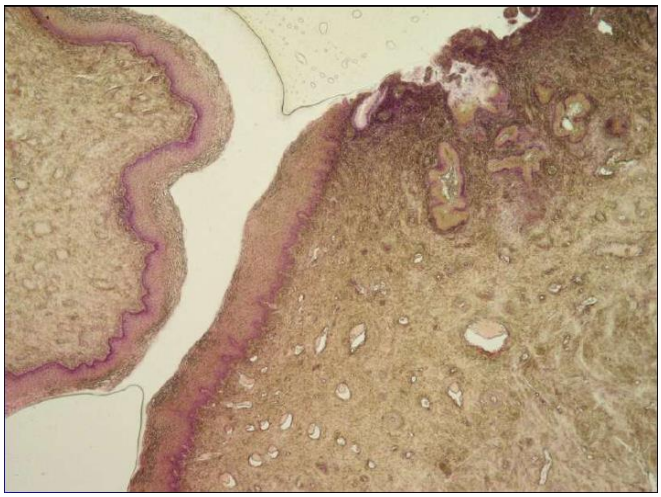

- The intravaginal part of the cervix is covered by stratified squamous epithelium exteriorly.
- Inside the cervix, we can find the cervical canal.
- The cervical canal is lined by simple columnar epithelium.

Slide#50 (Cervical external os area)

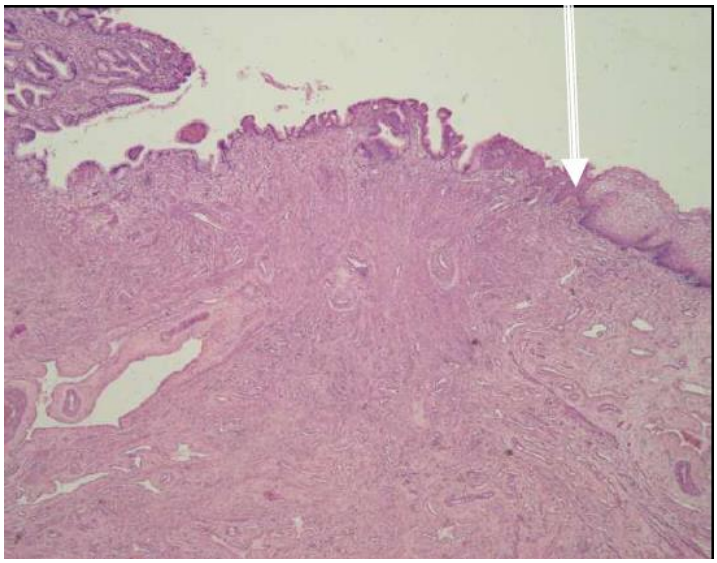

- Here, we notice that the lining epithelium is stratified squamous exteriorly and simple columnar interiorly.
- The transitional area is just inside the external os. This transitional area is believed to be the starting site of cervical carcinoma.
- The external os (the arrow)

Slide#51 (Cervical gands)

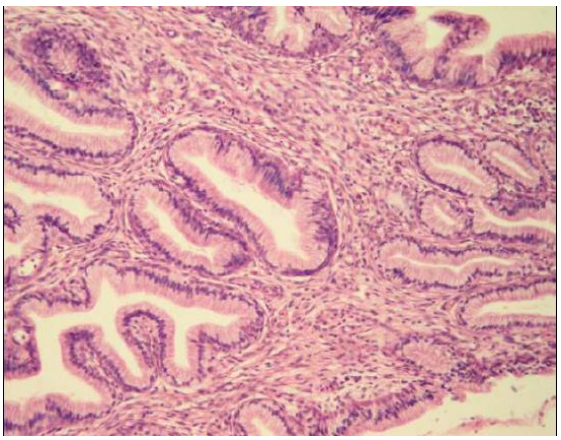

- The cervical wall is full of glands that secrete mucus.
- If the duct of the gland was blocked, the gland turns into a cyst called the Nabothian cyst or follicle.

Slide#52 (Dense connective tissue + smooth muscle of the cervix)

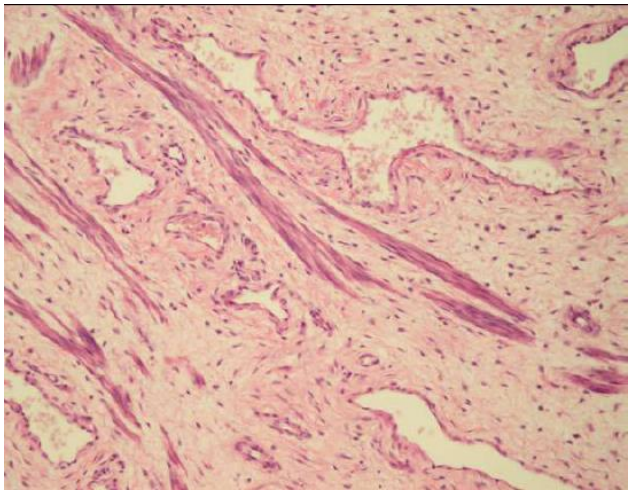

- The wall of cervix contains very few smooth muscles and is full of dense fibrous tissue.
- However, it can dialate during labor.
- In clinical practice, to test for the stages of labor, we use the diameter of the cervix as a measure.
- You are first able to insert one finger into the vagina. With time, you are able to insert an increasing number of fingers. When you are able to insert 5 fingers, it is called a fully dialated cervix indicating a very close birth. This happens under the effect of relaxin secreted by the placenta.

Slide#54 (Resting breast)

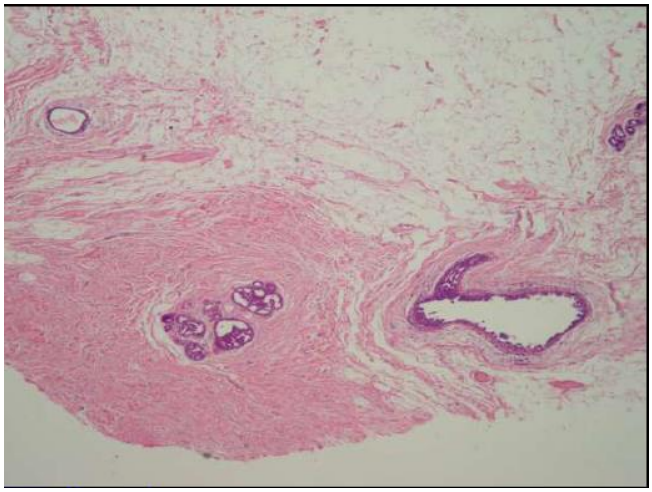

- The resting breast is a non lactating breast.
- Any female who has reached puberty and is not lactating or pregnant is said to have a resting breast.
- The resting breast is largely formed of adipose tissue (white areas in the slide, due to disappearance of adipose tissue).
- Then, we have lobules which are only formed of ducts which might be single layered cuboidal epithelium or double layered ducts.
- Alveoli are rarely present in a resting breast

Slide#55 (lactiferous sinus)

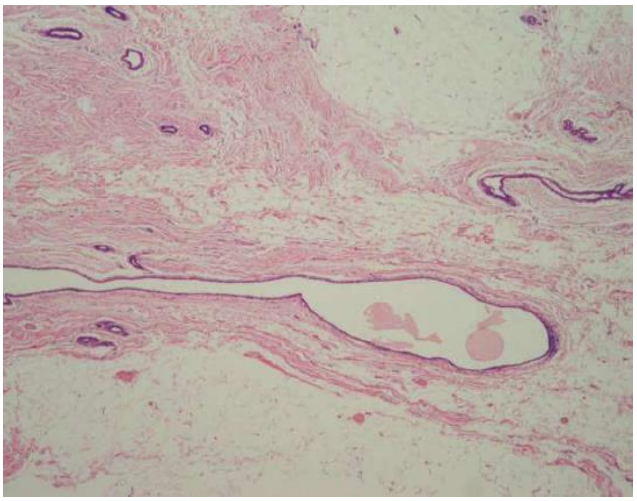

- From every lobule emerge some ducts.
- When they approach the nipple, they form the lactiferous sinuses.

Slide#56-58 (Breast during pregnancy)

- Growth of alveoli
- How do we differentiate the alveoli of the pregnant breast from the thyroid gland?
    - The presence of ducts indicates that this section was taken in a breast.

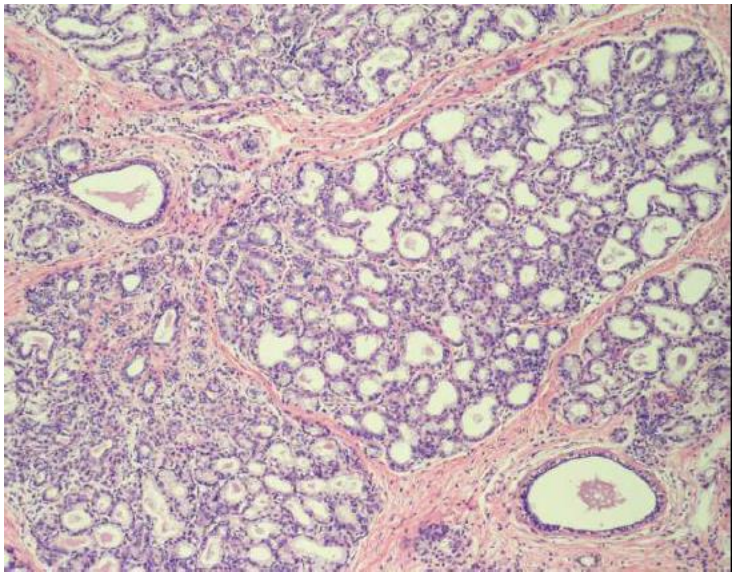

- Alveoli branch; Most alveoli are empty during the first six months of pregnancy.
- The secretions start to form during the third trimester (last three months of pregnancy).
- The secretions formed there are called colostrum. This colostrum is full antibodies; antibodies provide passive immunity.
- A woman is advised to nurse her baby as soon as the baby is born. Suckling might cause some abdominal discomfort. This is due to secretion of oxytocin (stimulated by suckling). Oxytocin causes milk ejection and causes uteral contractions. This contraction is beneficial as it helps getting rid of any unwanted materials in the uterus.
- Suckling stimulates prolactin secretion, as well.

Slide#59 (Alveoli)

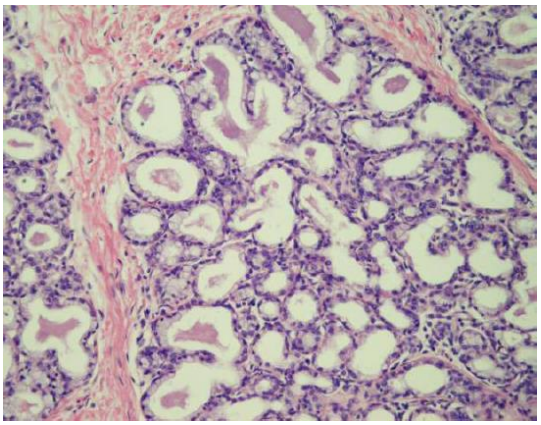

- Alveoli are not all full at the same time.

- Some alveoli are full of secretions, while others are empty.
- The walls of the non-secreting alveoli contain simple columnar epithelium.
- Alveoli alternate in milk production

Slide#60 + 61 (Lactating breast)

- Alveoli are full of milk.
- What produces milk is prolactin. Prolactin, although present during pregnancy, is ineffective; this is due to the presence of estrogen.
- Postpartum, the placenta is gone; the source of estrogen is gone. Prolactin increases causing milk production.
- Proper lactation is never associated with pregnancy. As long as there is proper lactation, there will be a block to GnRH. As long as there is no GnRH, there will be no FSH or LH. This means that there will be no ovulation; thus, no pregnancy.
- High doses of estrogen can stop lactation by blocking the action of prolactin.
- Nothing can replace the mother's milk. If the mother works (absence of regular lactation), this will cease the production of milk. Lactation needs suckling.

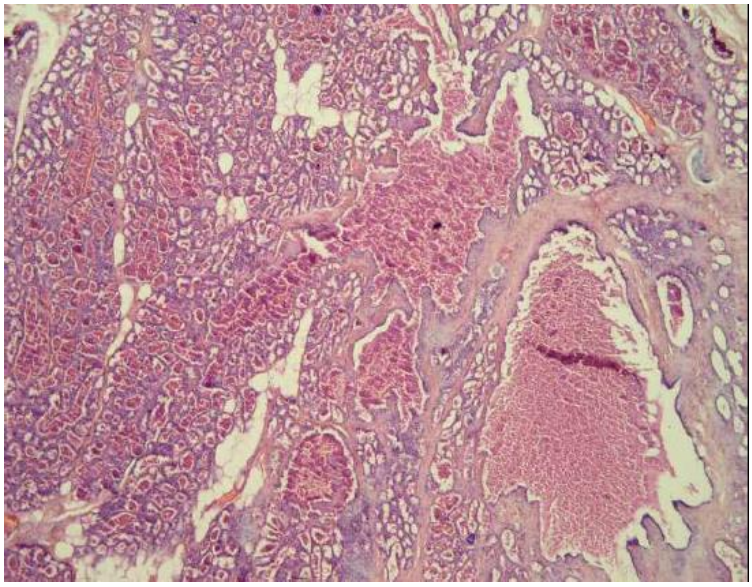

- Breastfeeding is a natural contraceptive, and boosts the immunity of the neonate.
- Slide#61 contains alveoli.

Slide#62 (Lactiferous sinuses in the nipple)

- Exteriorly, the nipple is covered by keratinized stratified squamous epithelium.
- Around the nipple is areola.

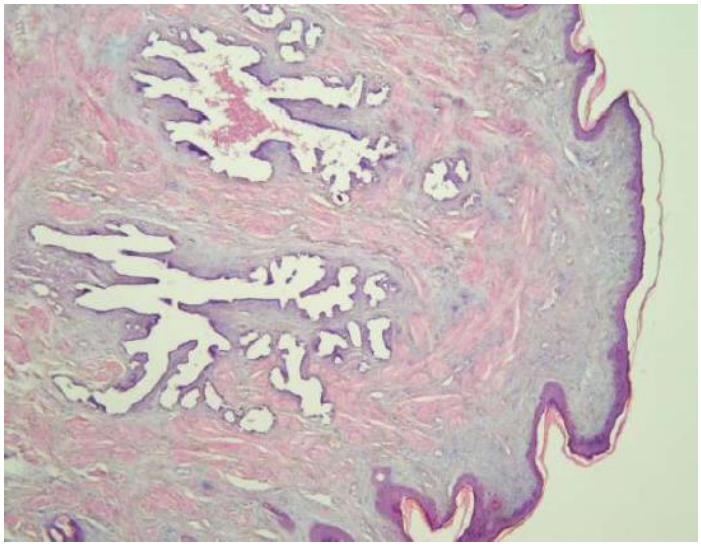

- Deep to the nipple and areola there is no fatty tissue.
- There are a lot of sensory nerve endings. These nerve endings are responsible for the suckling reflex. Signals from there are sent to the hypothalamus. The hypothalamus sends signals to the posterior pituitary to secrete oxytocin, and to the anterior pituitary to secrete prolactin stimulating milk production.
- The end of the duct is called the lactiferous sinus where milk is collected before release.
- There are many sebaceous glands at the nipple; however, sweat glands and hair follicles are absent.
- At the areola, we can find both sweat glands and hair follicles.

Slide#63 (Montgomory glands)

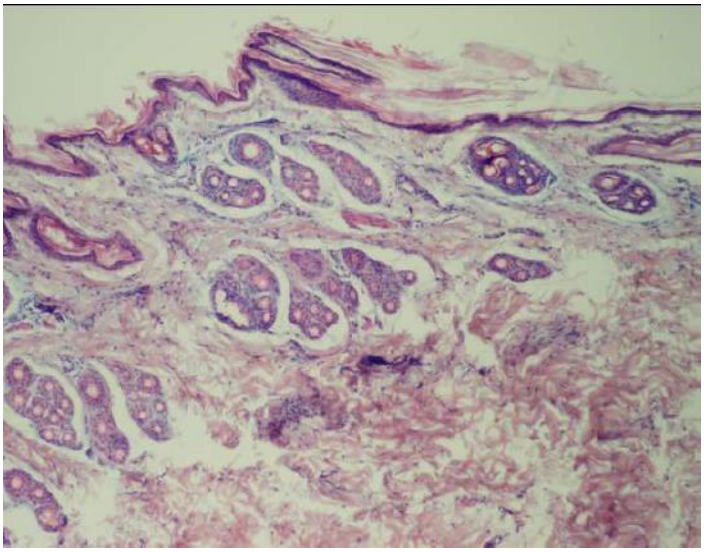

- Deep to the areola are modified sebaceous glands called Montgomry glands.
- They grow during pregnancy secreting oily secretions to prevent lacerations of the areola and nipples.
- In the areola, there are sweat glands, hair follicles, sebaceous glands, and modified sebaceous glands.
- The color of the areola is an indication of pregnancy. Now, we use the hCG levels to detect that.
- During pregnancy, areola transform from a light pink to a dark brown color.
- This change happens during early pregnancy; it happens through an unknown mechanism.
- Pregnancy increases the size of the breast
- Pregnancy causes secondary amenorrhea

X-rays:

X-ray#1

- Here, we see two ureters and two calices.
- This is called duplication.
- Duplication can assume different forms:
    - Double kidney, double ureter.
    - Double kidney, single ureter
    - Double ureter, a single kidney, and two caliceal systems (the most common)
- Here, we also see a distended bladder.
- With a normally functioning kidney, the patient would live normally.

X-ray#2

- Duplication
- 2 ureters
- 2 calices
- Single kidney

X-ray#3

- A female pelvis.
- We can easily tell without seeing the subpubic angle due to the presence of an intrauterine device (IUD).
- Here, we also see a distended bladder.