Histology

Enjoy studying hard, but don't forget to get enough sleep :)

Shapes of Skeletal Muscles:

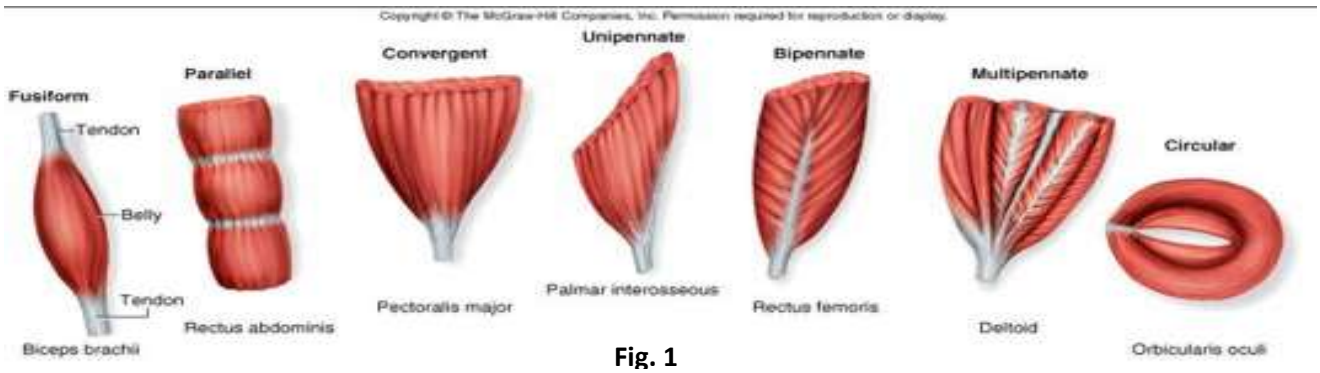

Fig. 1

- **Circular muscles**: Muscles mainly found in the face to control sphincters, e.g. Orbicularis oris, constrictor and dilator muscles of the nose (which are accessory-like in humans)
- **Convergent muscles**: Muscles with wide (and could be multiple) origin, but insert into a narrow area (they converge). e.g. Pectoralis Major, Infraspinatus muscles
- **Parallel Muscles**: Long thin muscles with their fibers along the axis of line of action of muscle, e.g. Sartorius
- **Fusiform**: Spindle-shaped muscles (length also greater than width) that have large bellies but taper (thins) at their insertions and origins, e.g. Biceps brachii
  -Note: short head of biceps is fleshy while the long head is tendon at its origin, also the biceptal aponeurosis insert beneath skin while the biceptal tendon inserts to posterior radial tuberosity to allow supination
- **Pennate Muscles**: These muscles have their fibers are oblique to axis of action of the muscle and inserted to a tendon usually:
  - **A.** Unipennate: All fibers insert in the same single oblique direction having one angle, e.g. extensor digitorum longus
  - **B.** Bipennate: 2 sets of fibers insert in two different oblique directions to a tendon, e.g. rectus femoris
  - **C.** Multipennate: 3 or more sets of fibers inserting in different oblique directions, e.g. deltoid (ant, post, and middle fibers)

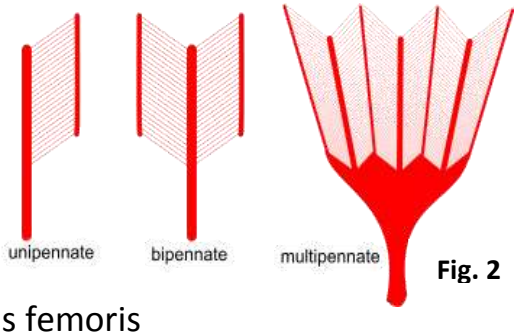

Fig. 2

Origin: Certain mesodermal cells in the embryo named myoblasts fuse together to create long multinucleated muscle fibers (each fiber is one considered one cell)

Morphology of a muscle fiber (cell):

- Nuclei and mitochondria are peripheral and under the sacrolemma (plasma membrane) as the cell is filled with contractile elements (mainly actin and myosin)
- The mitochondria appear as light structures peripherally in the classical stains
- 10-100 micrometer in diameter, varied length up to whole muscle
- Covered with external lamina: sometimes contain an undifferentiated cell called **satellite cell** which can differentiate into muscle fiber in case of injury. No satellite cell around the damaged muscle fiber ⟶ No regeneration
  (In slides, the satellite cell is between the external lamina and the muscle cell)
- Myosin filaments are thicker than actin filaments (hence myosin: thick filaments and actin: thin filaments)
- Longitudinal myofibrils (mainly actin and myosin) fill the entire cell length which are acidophilic (also large number of mitochondria which are also acidophilic), and their regular arrangement is responsible in cross-striations (dark and light bands) in the muscle fiber

Stages of a cell life:

1. **Mitotic cell**: Continuously dividing, if transformed to cancer, then chemotherapy
2. **Post-mitotic**: Normally doesn't divide if not stimulated, if transformed to cancer, then radiotherapy
3. **Differentiating cell**: After mitosis, the cell starts to specialize, if cancer transformed, then radiotherapy
4. **Differentiated (specialized) cell**: Cells that have specific metabolic function, and don't divide and don't heal if injured, if cancer transformed, then only surgical procedure

Striation of the muscle:

- Striation due to **myofilaments** arangement in a muscle fiber and **myofibril arrangement**

-Isotropy: ability of a tissue to refract a polarized light

-An **isotropic** area is an area that will appear light, while an **An-isotropic** area will appear dark

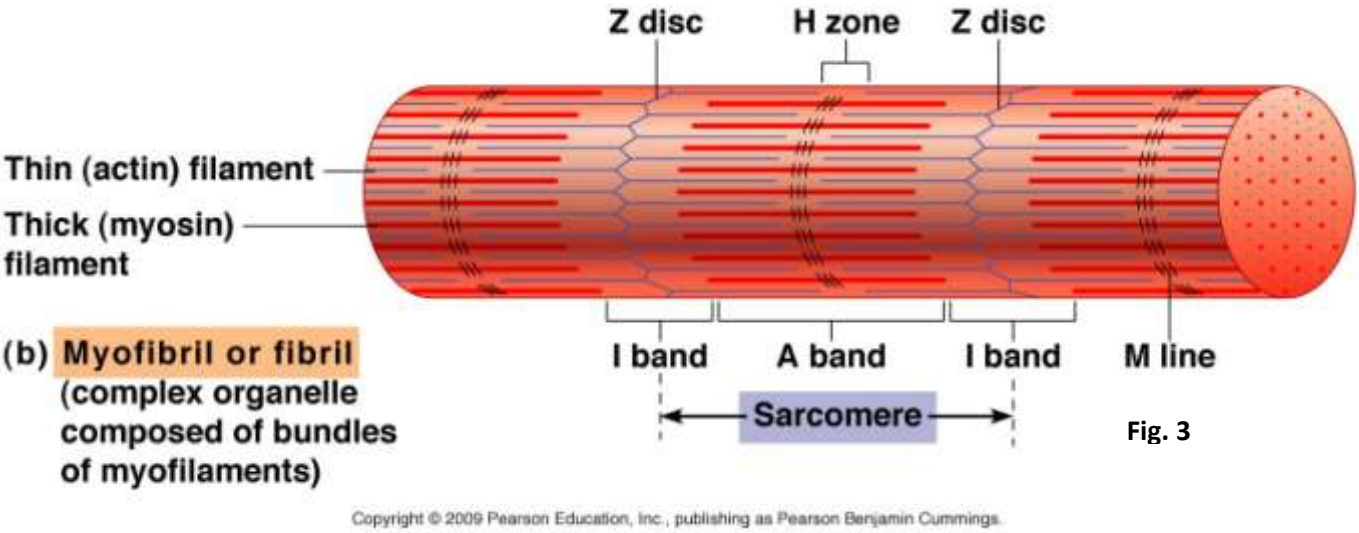

Fig. 3

-As you can see from fig.3 , the striations are in the form of alternating **I-bands** (Isotropic bands) and **A-bands** (An-isotropic bands)

-In the center of the light I-band, there is a dark line called the **Z-disc** or **Z-line,** this is a complex of many proteins, one of which is actin

-In the center of the dark A-band, there is a light area called **H-band** or **H-zone** , and in the center of the H-band there is a dark line called **M-line**

-The sacromere (region between two Z-lines) is the contractile unit of a skeletal muscle

Explanation of the Striation:

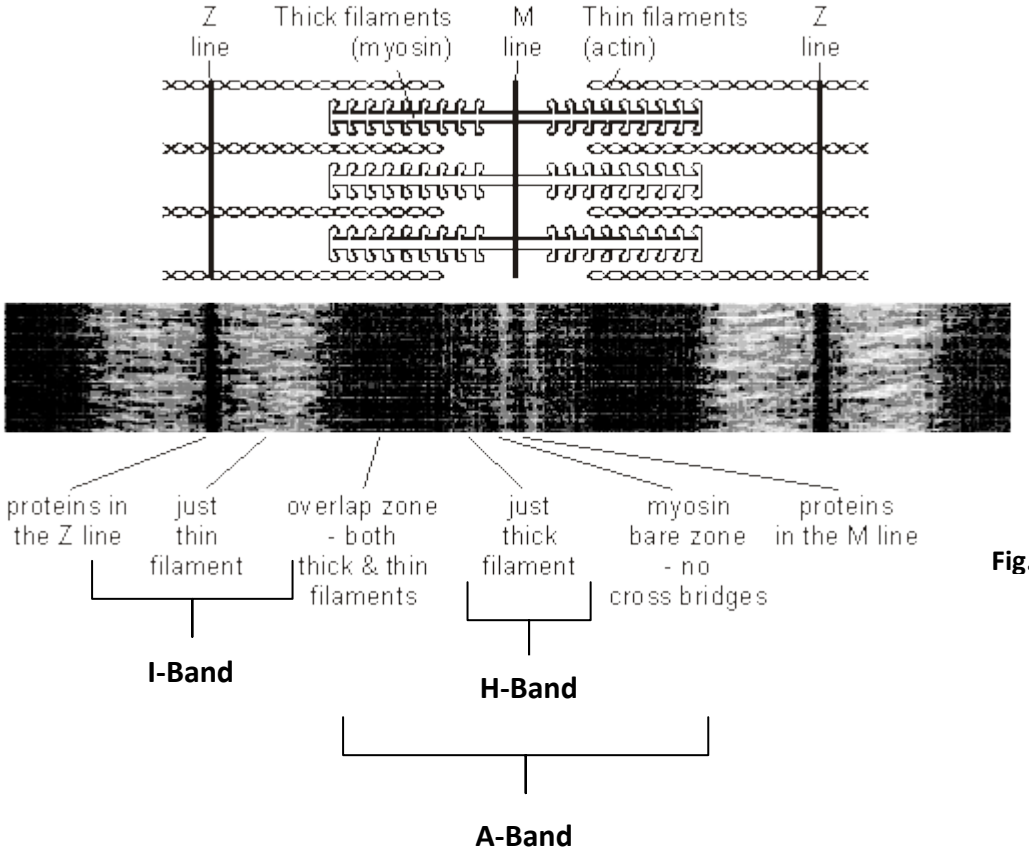

Fig. 4

-In the I-Band, there is **only actin filaments** which don't obstruct light much, hence appear light

-The Z-line appear dark as it is made of actin **and many different proteins,** e.g. actinin which binds the actin filaments to other proteins in the Z-line

- The A-band appears dark due to:

- Presence of thicker myosin filaments
- Overlap of myosin and actin

- The H-Band in the middle appears lighter than A-band, as no actin filaments in it (hence no overlap), only myosin

-The M-line appears dark, as it consists of proteins that link myosin filaments' tails end together

*Note: Myosin is present only in the A-band, but actin is always present except in **H-band** (and M-line of course)

Ultra-structure and T-tubule

-Intermediate filaments **Desmin** and **Vimentin** mainly form a scaffold around Z-line and links myofibrils laterally to the Z-line and to each other keeping myofibrils together

-Between the I-band and A-Band a junction exists to be called **A-I junction** (this is a description from the Dr.)

- At level of A-I junction, the sacrolemma (plasma membrane) invaginates downward to form T-tubules that run between myofibrils and can anastomose and branch

-SR surrounds myofibril **Fig. 5**

- Two dilated (to intercommunicate) Sacroplasmic reticulum (SR) structures surround each T-tubule to form a **Triade** (SR-T-SR) (Triade means three)

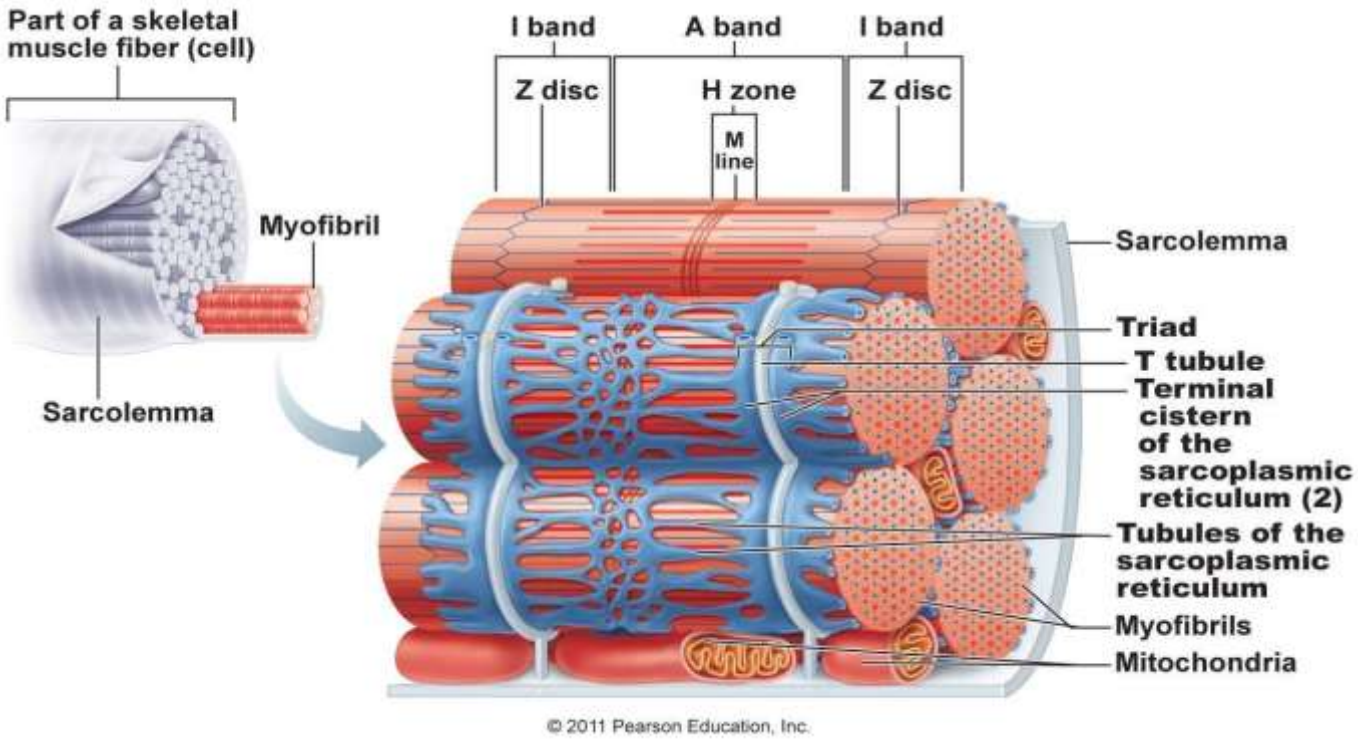

-In **each sacromere**, there is two half I-bands surrounding one A-band, so there is two A-I junctions and hence two sets of T-tubules and two triads

**Notice:* Look how the cristae of the mitochondria are very interlocking in different regions

Contraction (Sliding Filament Theory)

Fig.5 is a close-up on the interaction between myosin and actin

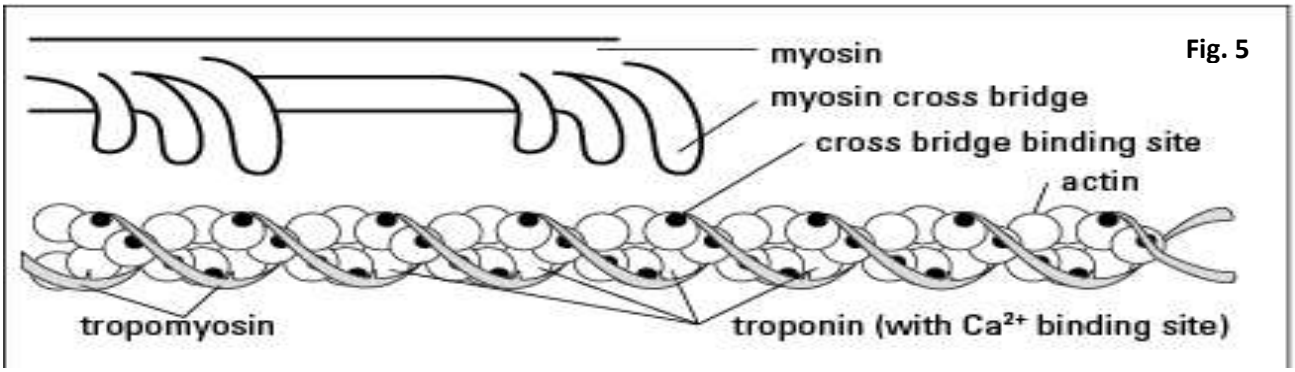

Fig. 5

-The thin filament is actually composed of two actin filaments intertwined together

- A protein called tropomyosin binds to the binding sites of actin preventing myosin heads to bind actin filaments. There is a protein called troponin as well

-The myosin heads (which are motor proteins) normally bind ATP

-When Ca^{2+} increases in cytoplasm, it binds to troponin which then causes tropomyosin to unbind from its sites, allowing myosin heads to hydrolyze ATP to ADP and P_i to bind to the actin filament and forming **cross-bridges,** ADP and P_i are then released from the head and the myosin heads moves the actin filament in same direction (contraction stage or cross-bridge swinging)

-Greater overlap of myosin and actin leads to greater contraction (can lead to pain and fatigue or tetany (especially if no warm up for optimization of function))

-ATP now rebinds to the myosin head, removing it from its binding site on actin

-Relaxation occurs when Ca^{2+}concentration decreases and tropomyosin restores its position

Results during contraction: -Thin filaments slide over thick filaments

- Z-discs are brought closer to each other (as actin filaments are moved), and H-band length is reduced or (in great overlapping) disappears

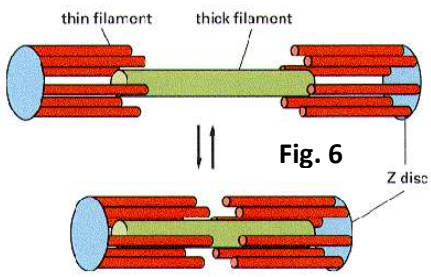

Fig. 6

-The A-Band length **doesn't** change (myosin filaments didn't move)

- The filaments DON'T shorten, it is like pulling a rope by your hands (the rope length itself didn't shorten)

Stimulation of Contraction

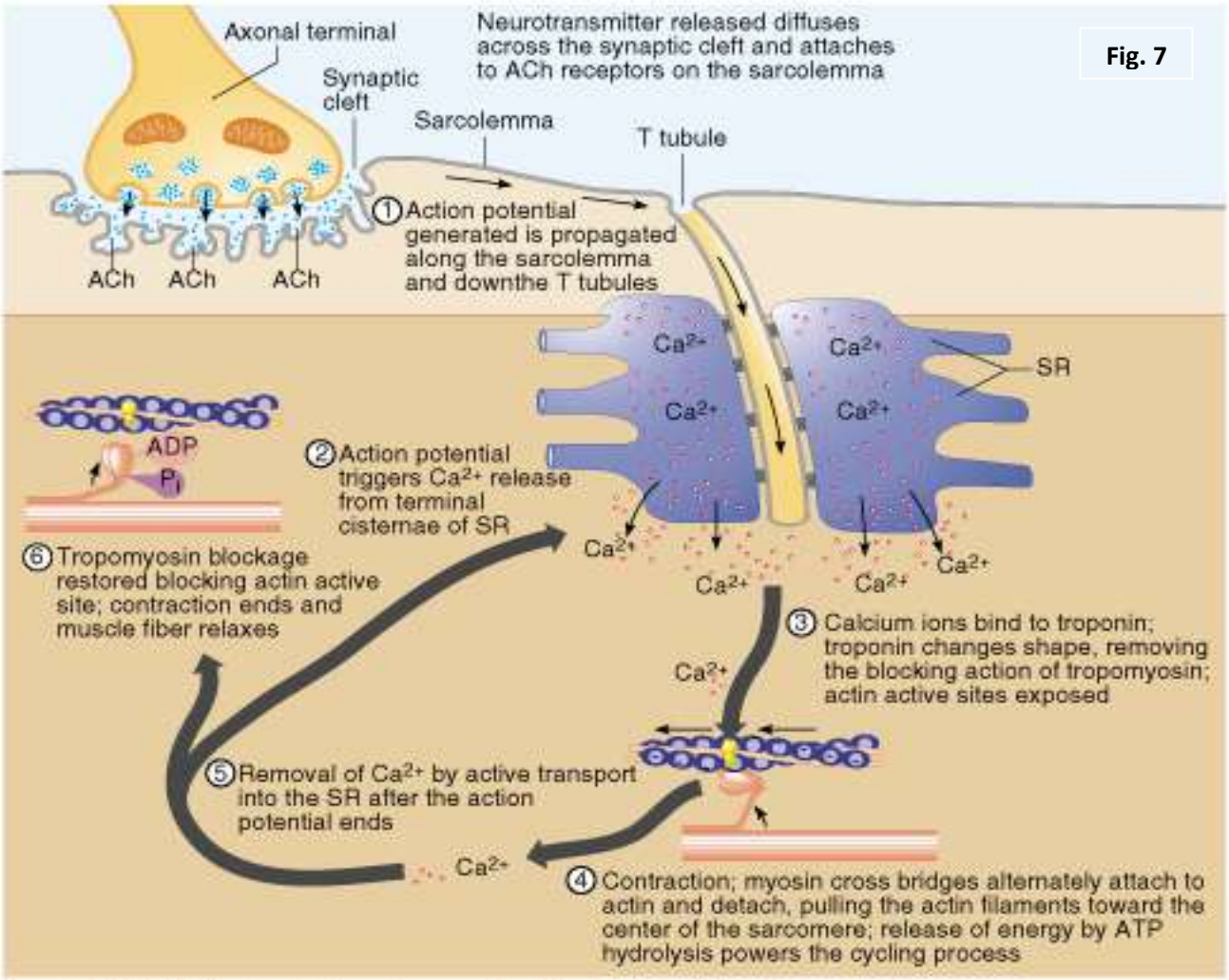

-Axon terminal junction in a muscle is called neuromuscular junction or motor-end plate

-Action potential (AP) reaching the axon terminal (full of mitochondria) stimulates ACh (Acetylcholine) vesicles in the synaptic cleft release due to influx of Ca^{2+}

-The ACh binds to receptors (AChR) on sacrolemma exciting the muscle fiber by causing an AP which propagates to T-tubule reaching the SR dilated **voltage gated** end called **terminal cisternae** which stores Ca^{2+} causing its release

-Ca^{2+}increases in cytoplasm, so contraction occurs

-Active uptake by SR helps reduce and restore Ca^{2+} for relaxation

**Note*: Acetylcholine esterase enzyme breaks down ACh on the sacrolemma

Remember for skeletal muscle:

- A **fascicle** is a group of muscle fibers
- A **muscle fiber** is one cell (but very long)
- A **myofibril** is the structures in a muscle fiber responsible for contraction
- A **sacromere** is the repetitive unit in a myofibril
- **Myofilaments (actin and myosin)** are what mainly makes up a sacromere

Smaller

Types of Muscle fibers:

Characteristics	Red Fibres	White Fibres
Vascularization	Rich	Poorer
Innervation	Small nerve fibres	Larger nerve fibres
Fibre Diameter	Smaller	Larger
Contraction	Slow, repetitive, weak (soleus, muscles of the back)	Fast, strong (gasrocnemius, extra-ocular muscles)
Fatiguability	Difficult	easy
Sarcoplasmic reticulum	Not extensive	Extensive
Mitochondria	Rich	Few
Myoglobin	Rich	Poor
Enzymes	Rich in oxidative enzymes. Poor in ATPase	Poor in oxidative enzymes. Rich in ATPase

- White fibers are for fast twitching, but red fibers for slower more repetitive and weaker

-Human muscles contain red and white fibers, however the most abundant are intermediate ones

-Some muscles can be considered more red (e.g. Soleus) while others more white (e.g. Gastrocnemius)