Lecture #: 7

Medical Committee
The University of Jordan

GIS | Gastrointestinal System

Subject: Amoeba

Doctor: Hassan Abu Al Ragheb #1

Date: 28/4/2013

[Microbiology]

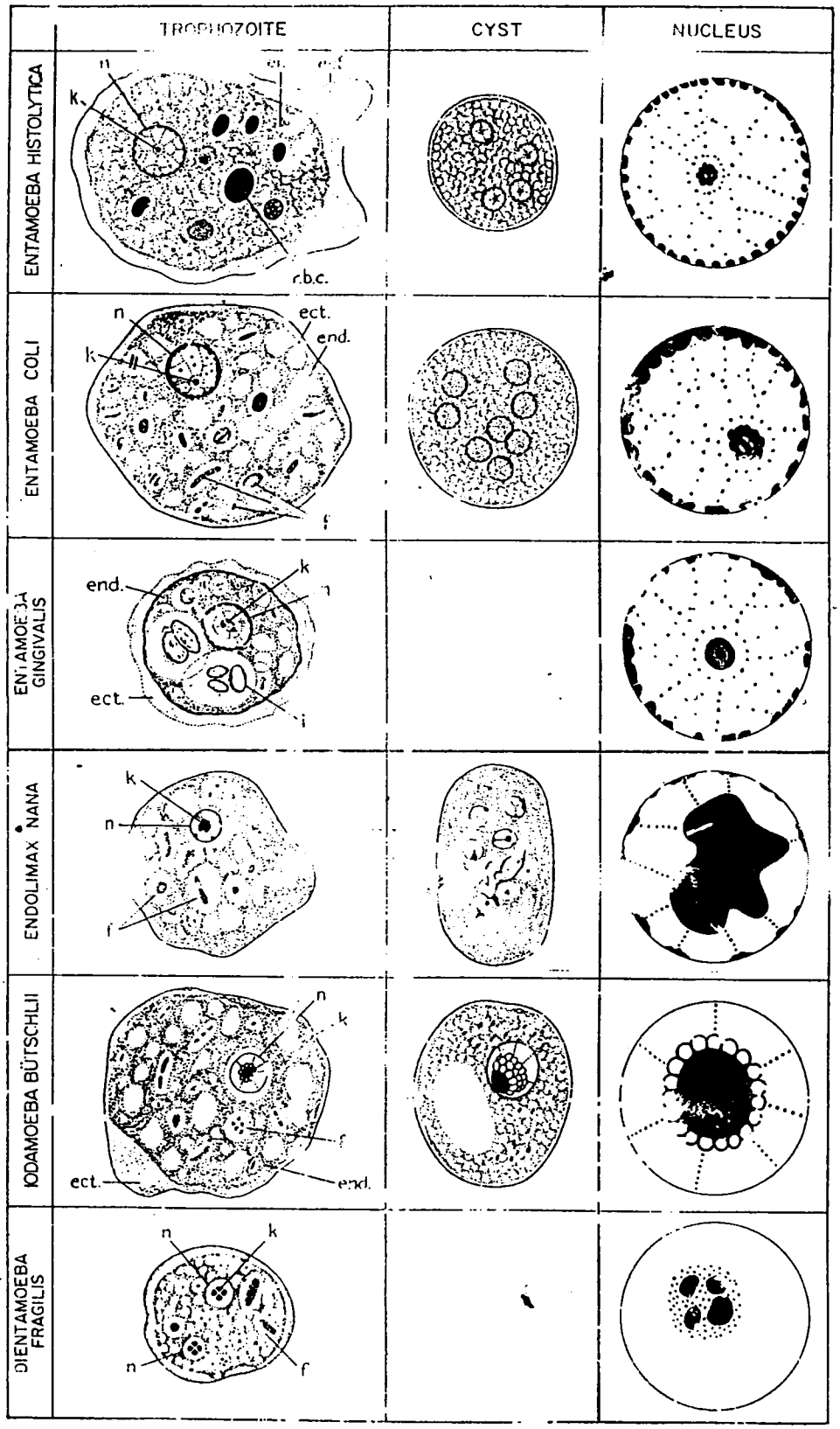

Figure 3–1. Comparative morphology of the amebas of man and schematic representation of their nuclei. Trophozoites and cysts of *Entamoeba histolytica, E. coli,* and *E. gingivalis* and of *Endolimax nana, Iodamoeba bütschlii,* and *Dientamoeba fragilis.* ect. = ectoplasm; end. = endoplasm; f = food vacuoles; i = inclusion nuclei; k = karyosome; n = nucleus; r.b.c. = red blood cells.

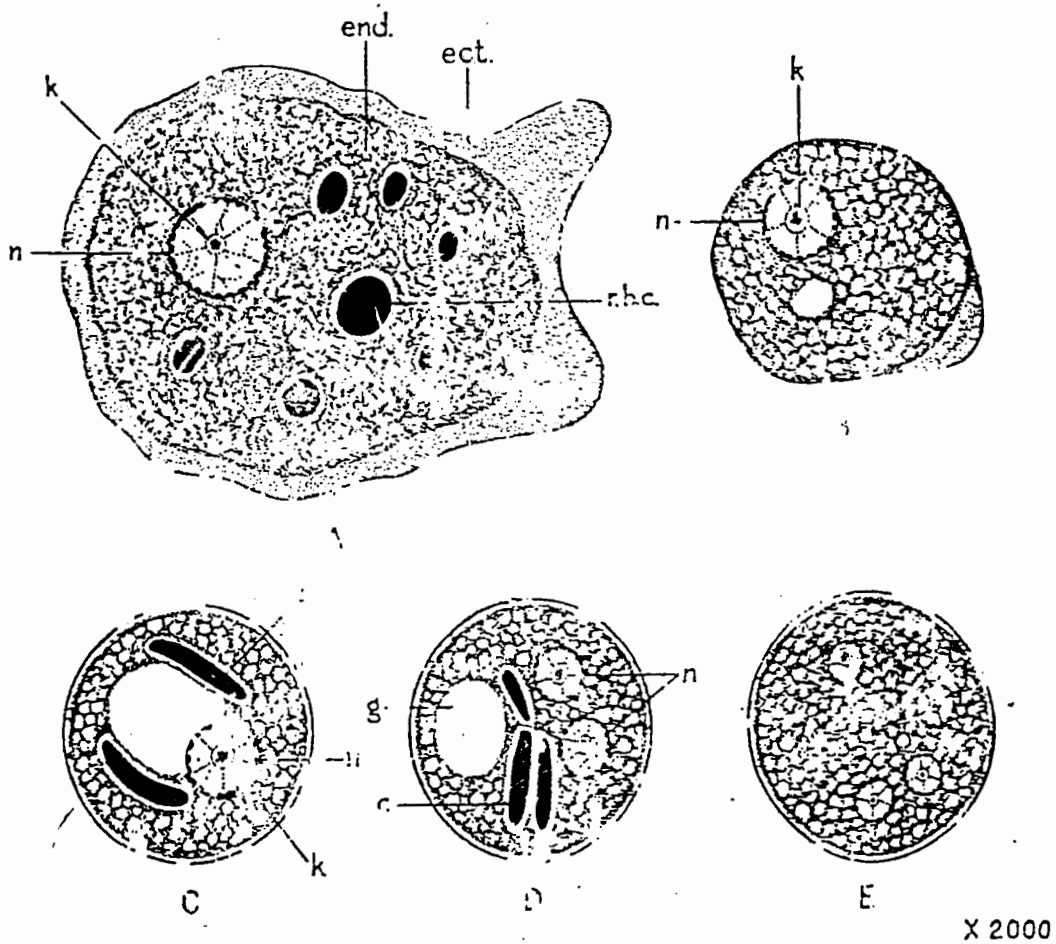

Figure 3-[illegible]. Schematic representation of *Entamoeba histolytica*. **A.** Trophozoite containing red blood cells undergoing digestion. **B.** Precystic ameba devoid of cytoplasmic inclusions. **C.** Young uninucleate cyst. **D.** Binucleate cyst. **E.** Mature quadrinucleate cyst. c = chromatoid bodies; ect. = ectoplasm; end. = endoplasm; g = glycogen vacuole; k = karyosome; n = nucleus; r.b.c. = red blood cells.

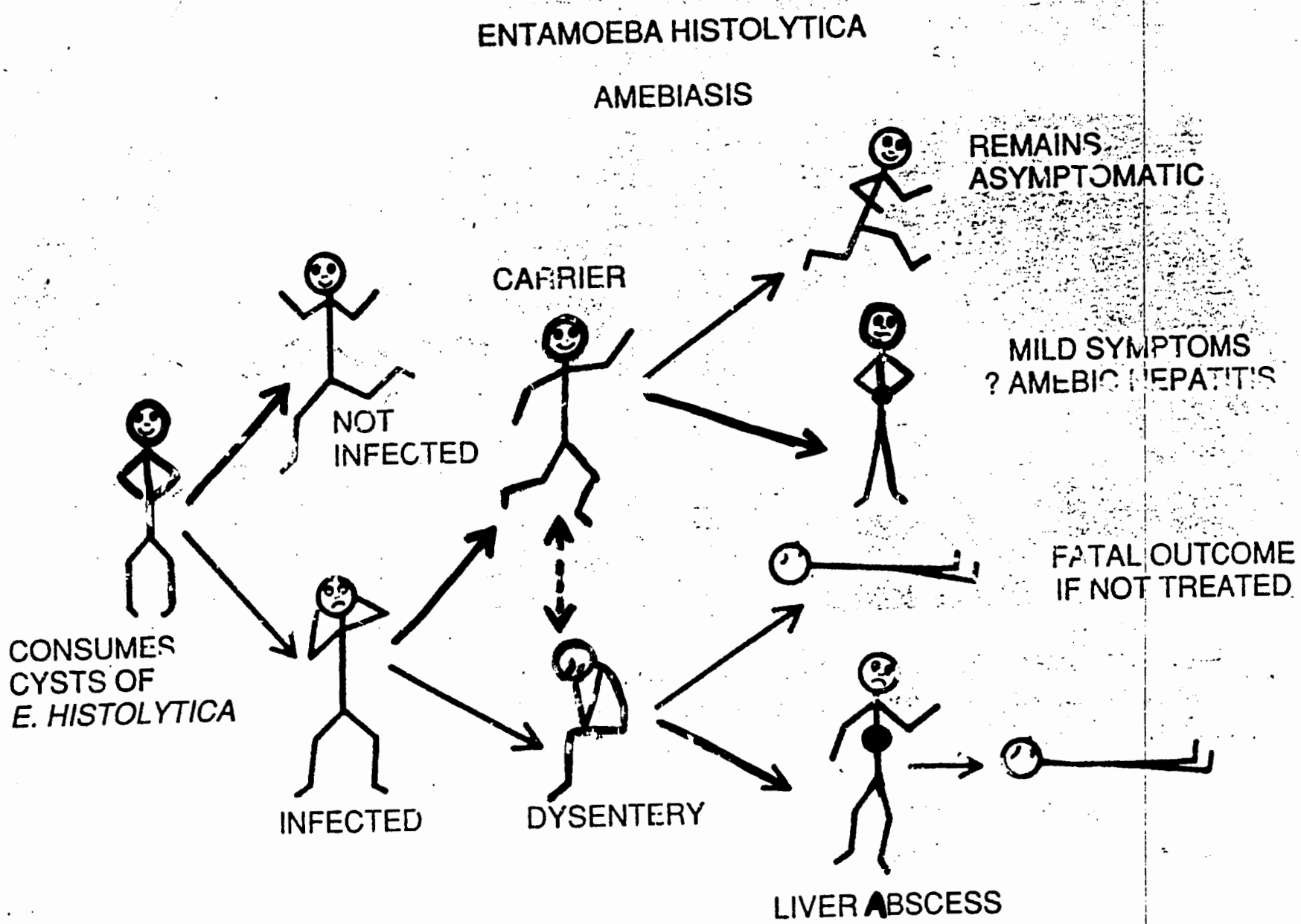

Figure 3–7. Amebiasis, with different possible courses of infection.

Entamoeba histolytica :

Rhizopoda family. E. histolytica is pathogenic, others are commensals, free living amoebae may cause disease e.g. Naegleria and Acanthamoeba.
Trophozoite and cyst.
Differentiate Ent. coli from Ent. histolytica :
E. coli has :
1- narrower less differentiated ectoplasm.
2- more granular endoplasm containing bacteria but not RBC.
3- broader and blunter pseudopodia.
4- more sluggish movements.
5- large eccentric karyosome in nucleus.
6- larger cyst with slender chromatoidal bodies (RNA and DNA), and up to 8 nuclei.

E. histolytica has RBC, no bacteria, scanty vacuoles.
Dientamoeba fragilis may cause diarrhoea in some patients : two nuclei, no cyst, rapid pseudopodia formation and movement. (disintegrates easily hence name).

E. gengivalis : present in mouth, 95% of people with caries and gengival disease.

Pathogenecity is determined by many factors such as bacterial flora, diet and virulence of the strain. Bacteria are required for the culture of amoeba in vitro.
Trophozoites are present in liquid stools when symptoms are apparent, cysts are passed by carriers in formed stools.

Disease: asymptomatic carriage is commonest, dysentery, appendicitis, intestinal perforation, granuloma formation (amoeboma), hepatitis and hepatic abscess, lung abscess and rarely in other sites.

Diagnosis:
Stool examination for trophozoites and cysts, fresh mount and iodine stain (kills the trophozoite but highlights the cysts), sigmoidoscopy appearance with sample examined also microscopically. Aspiration of an abscess especially the wall for the parasite.

Treatment:
Metronidazole, tetracycline, emetine, iodoquinol.

Naegleria fowleri and Acanthamoeba can cause fatal meningitis and eye infections (keratitis, with bad prognosis), usually acquired from swimming in ponds.

90 % of infections are asymptomatic.
10 % of the world population are infected with E. histolytica, death from this infection ranks third after Schistosoma and malaria (amongst parasitic diseases).
Clinical disease is determined by the virulence of the strain, virulent strains are distinct and produce extracellular proteinases and are resistant to complement lysis, and hence cause invasive disease. Invasiveness is also determined by host factors.

Dysentery : blood, mucus, shreds of mucosa, abdominal pain and tenderness, fever, dehydration may occur.
Pathology :

Microulcerations of colonic mucosa with intervening areas being normal. Deeper ulcers are flask shaped. Perforation may occur.
Mass formation : amoeboma (NB differentiate from cancer).
Dysentery frequent stools with little faecal material but with mucus and blood, fever occurs in 40%.
Chronic amoebiasis may be confused with inflammatory bowel disease (importance in diagnosis in order to avoid steroids).
Liver abscess : febrile. S.O.L. in liver. It may rupture into peritoneum, pleura and pericardium.

Diagnosis : cyst or trophozoite in stools.
Serology is helpful, positive serology suggests active disease, serology becomes negative after eradication.

Treatment : luminal drugs e.g. iodoquinol for eradication of carrier stage.
Metronidazole for invasive disease.
Emetine and chloroquine as second line treatment (side effects and relapse).

Free living amoebae :
These may be responsible for persistence of Legionella, the amoeba is chronically infected with the bacteria.

Naegleria fowleri : meningitis, olfactory neuroepithelium, usually fatal purulent meningitis.

Acanthamoeba : in debilitated patients, blood spread from a focus e.g. skin. Usually fatal.
It can also cause keratitis from swimming, contact lens associated (swimming with contact lenses on), home made saline, poor sterilization. Therapy is disappointing.