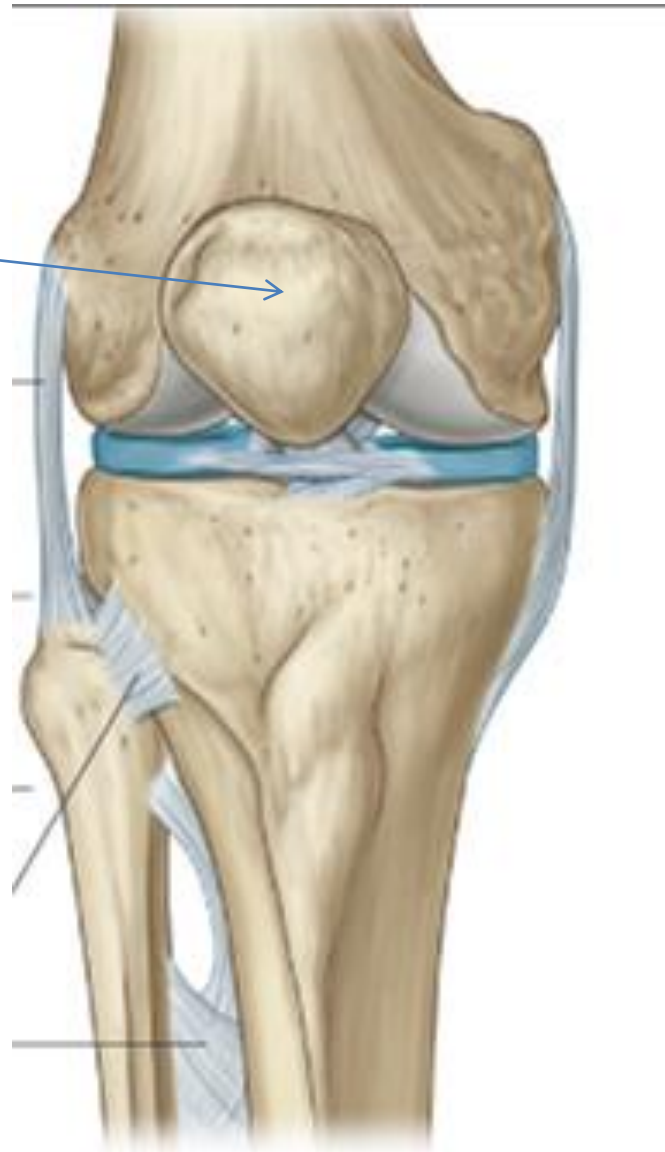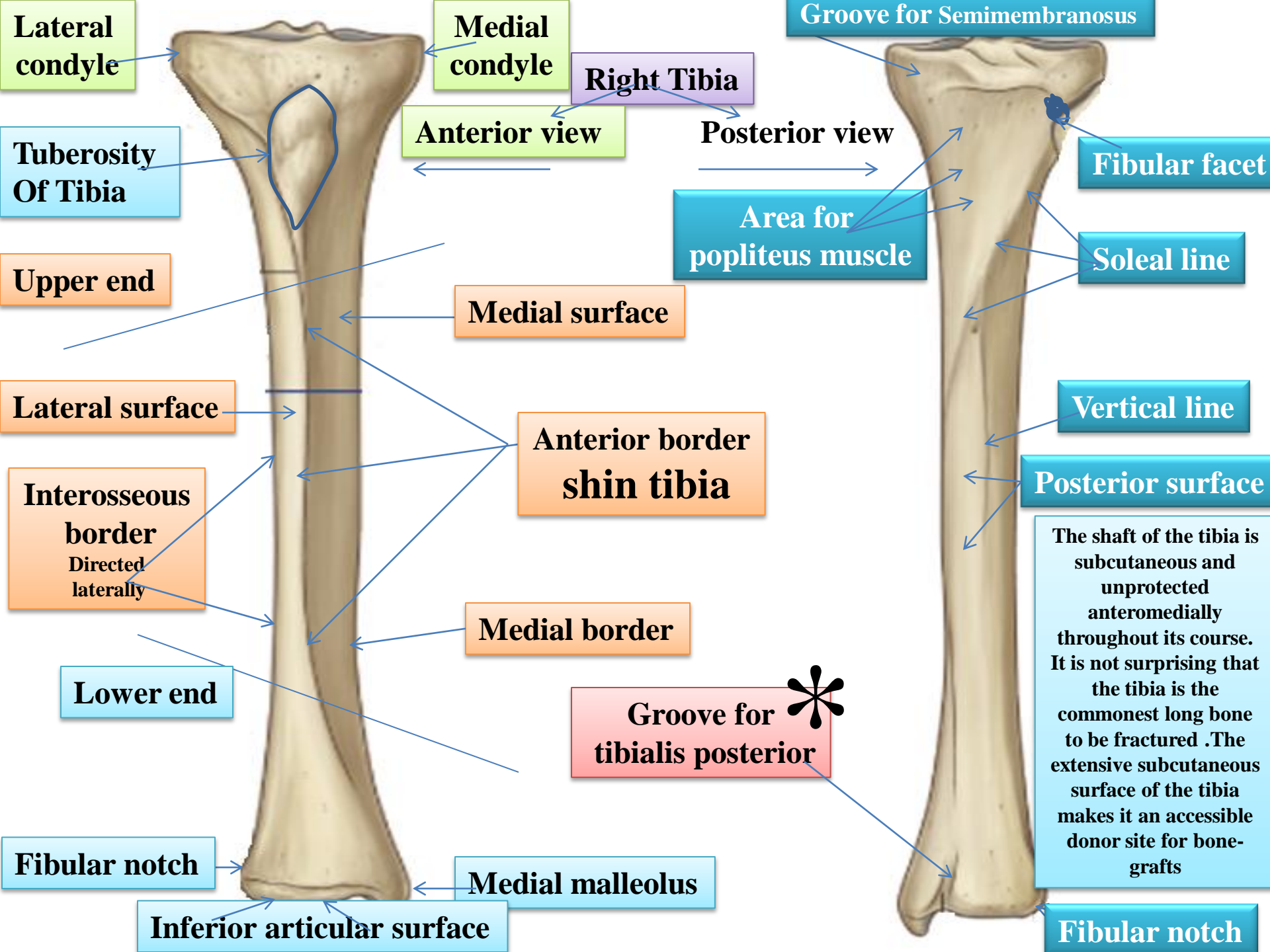


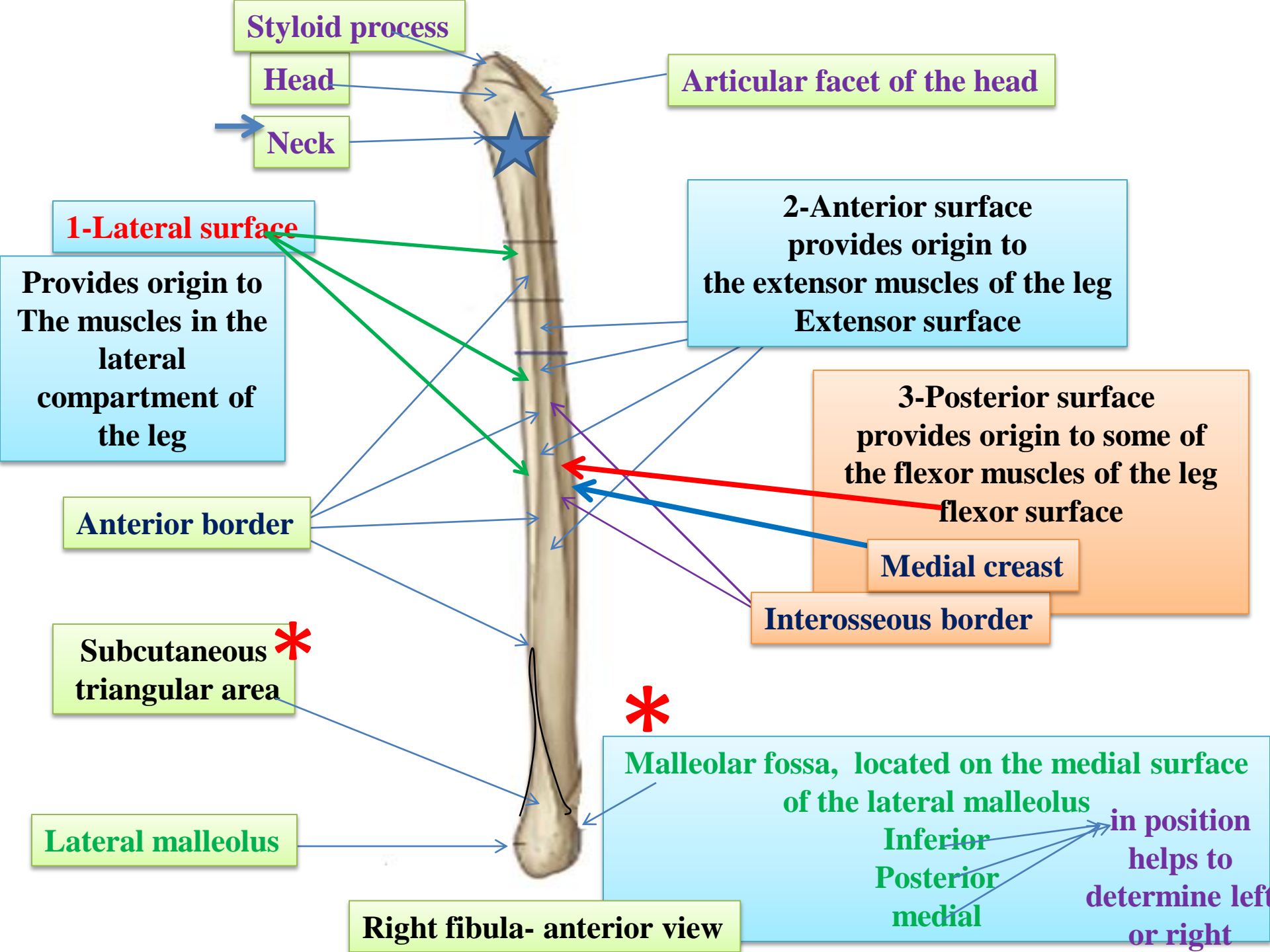
Patella

Triangular sesamoid bone

Contained within patellar ligament



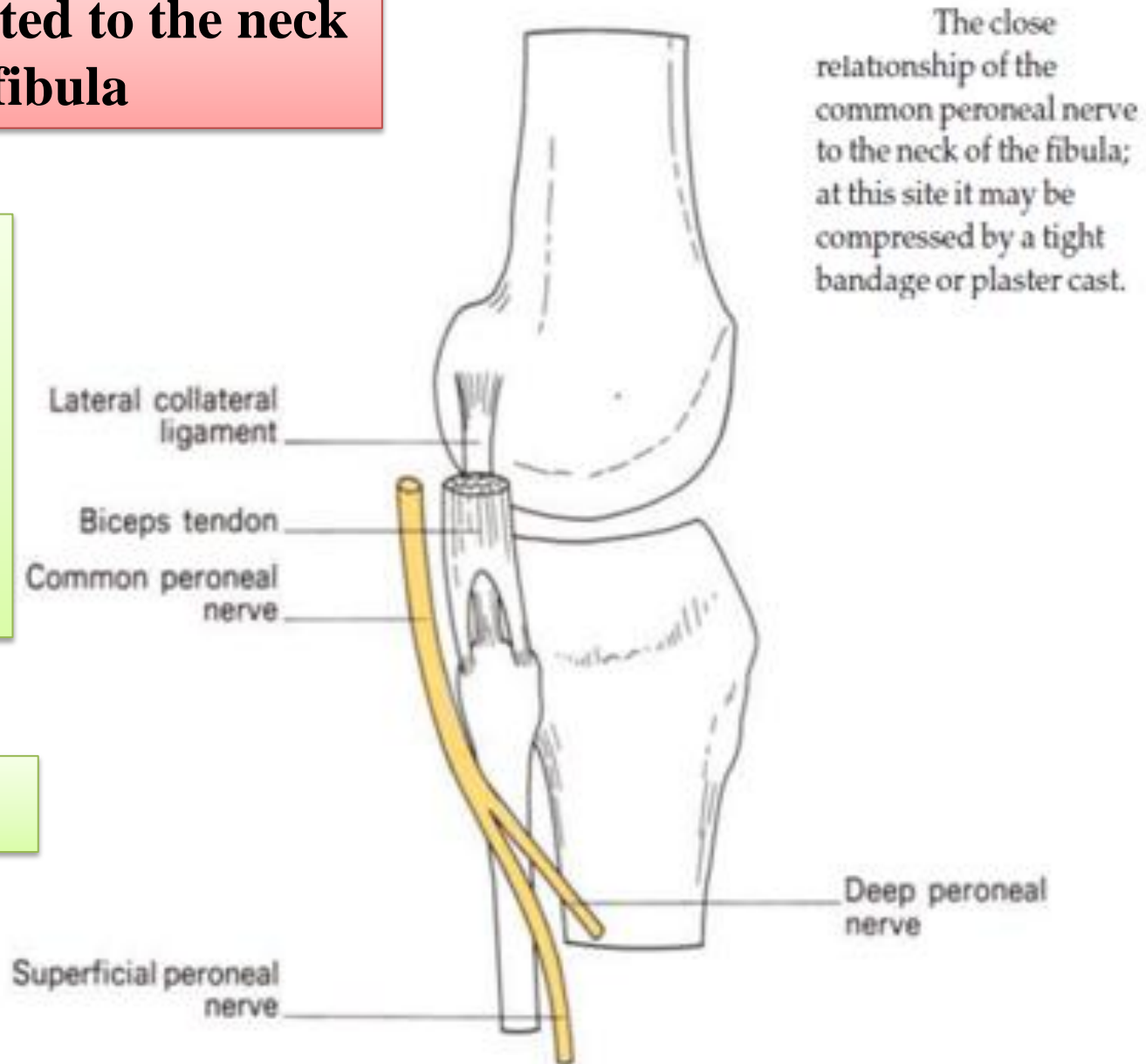


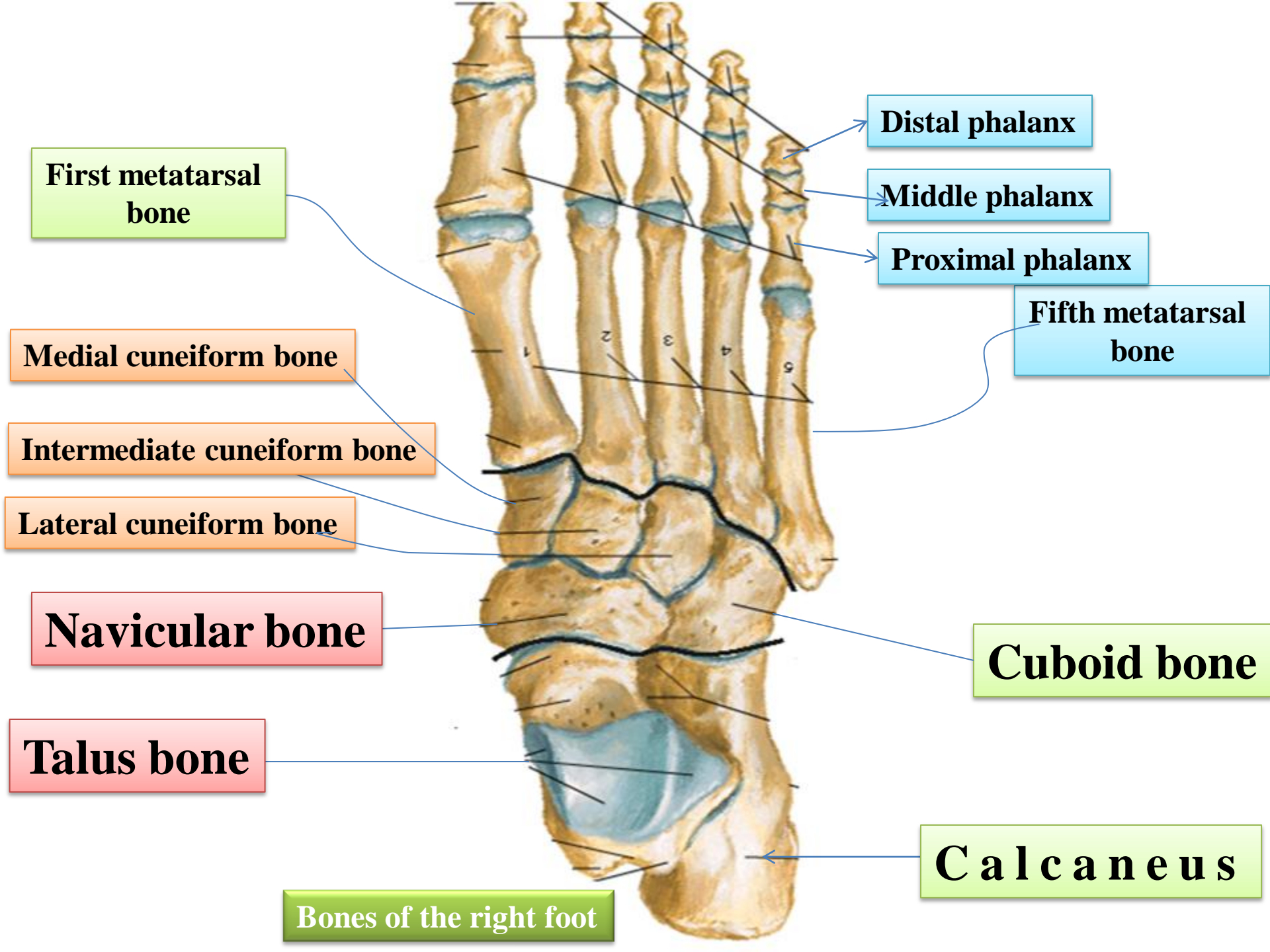


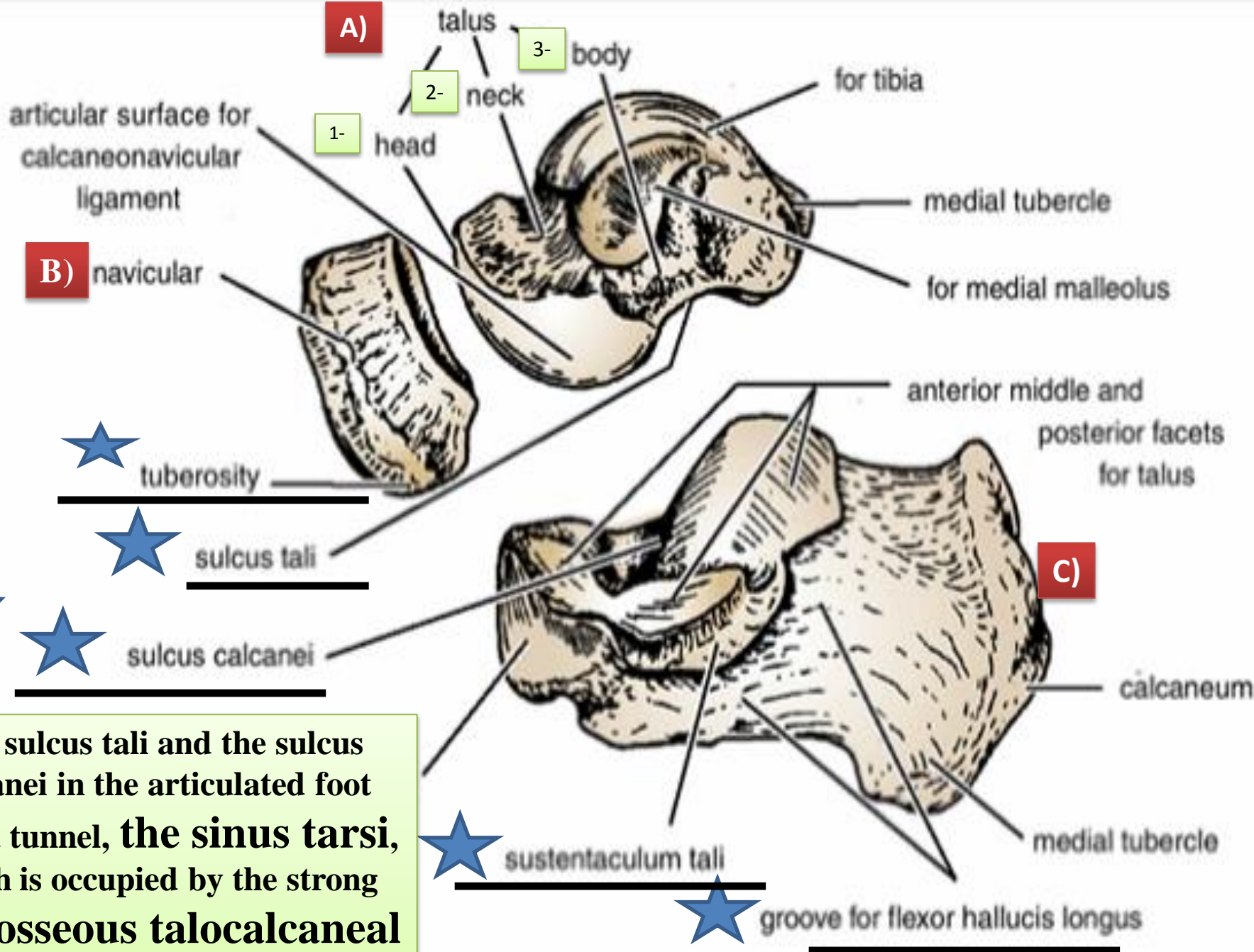
The common peroneal nerve is related to the neck of fibula

The common peroneal nerve in this area is covered by skin and fascia only therefore it is exposed to injuries

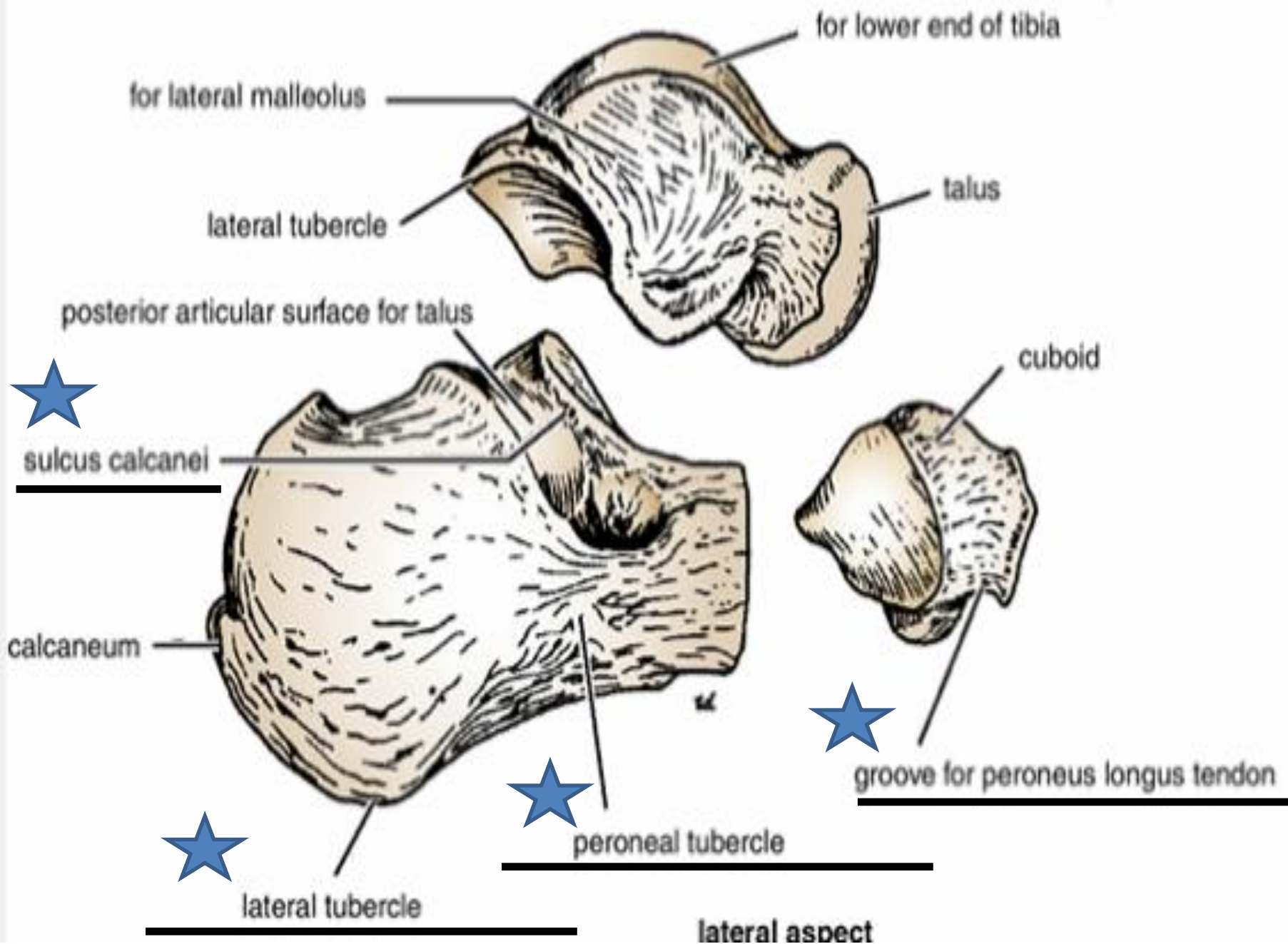
Foot drop







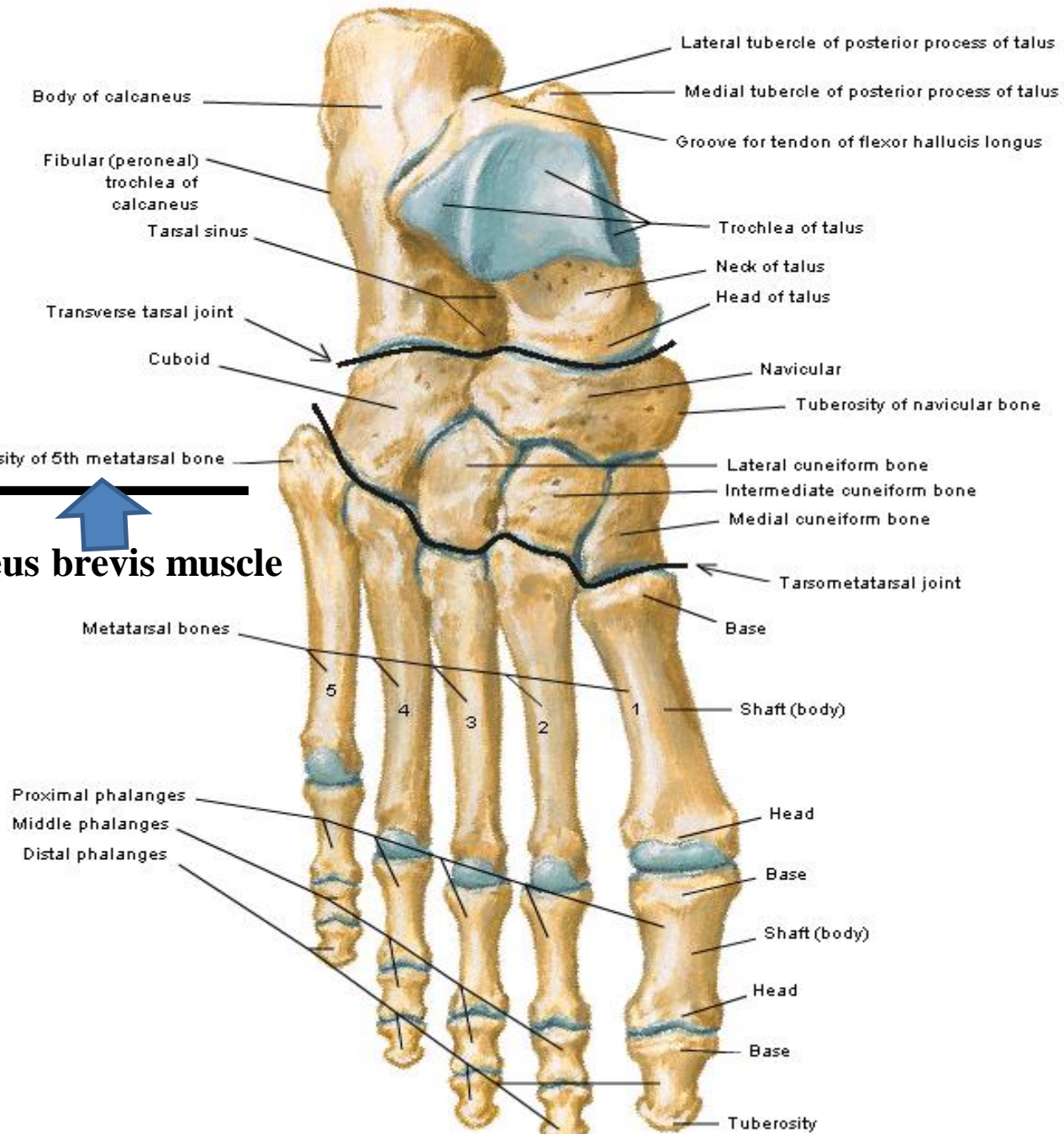
The sulcus tali and the sulcus calcanei in the articulated foot form a tunnel, **the sinus tarsi**, which is occupied by the strong **interosseous talocalcaneal ligament**.



Bones of Foot

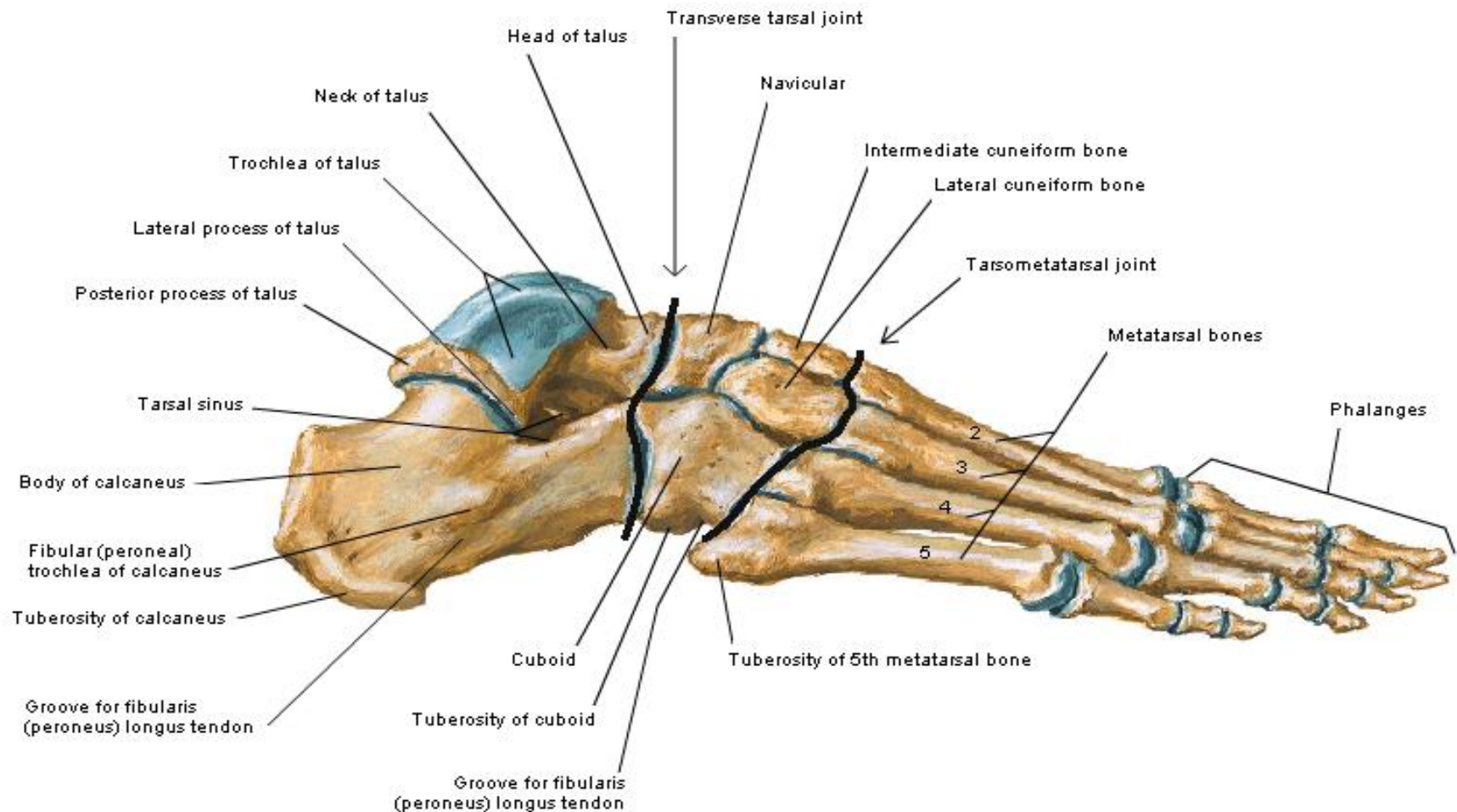
Dorsal View

Insertion of peroneus brevis muscle



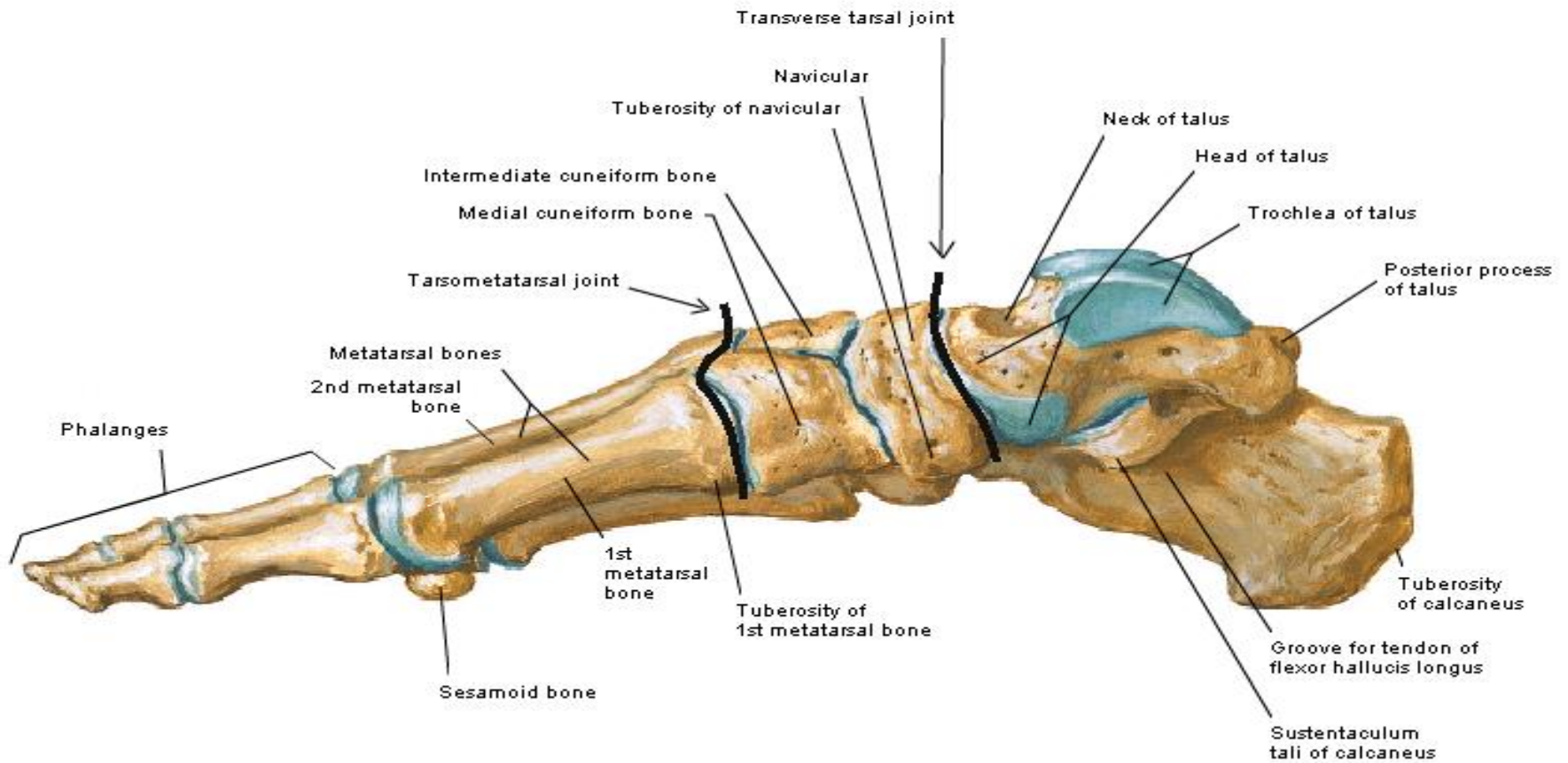
Bones of Foot

Lateral View



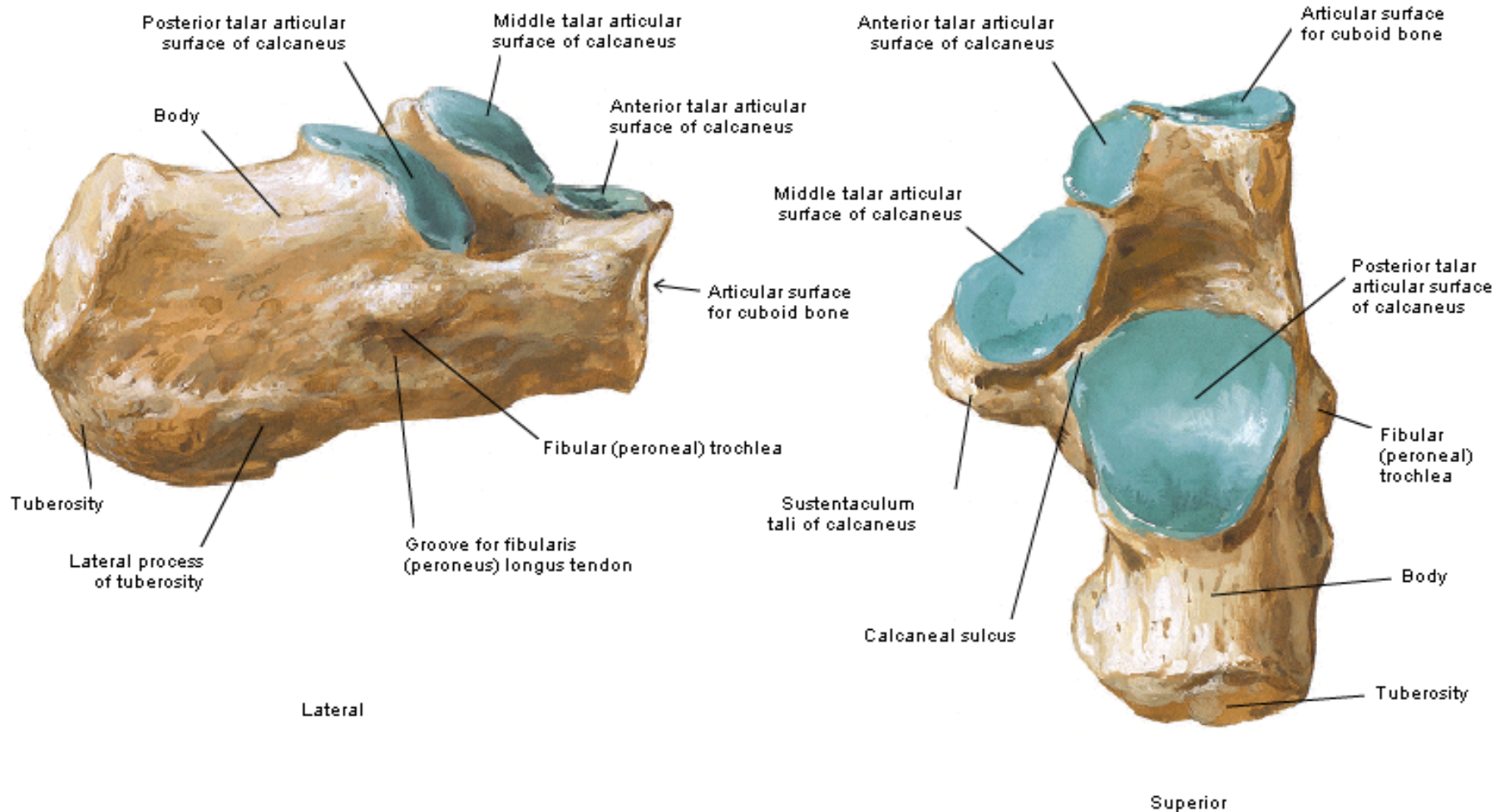
Bones of Foot

Medial View



Calcaneus of Right Foot

Lateral and Superior Views



Calcaneus of Right Foot

Medial and Posterior Views

