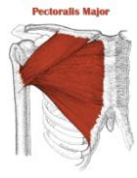


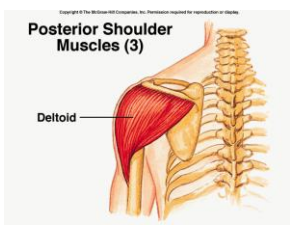
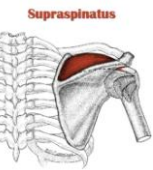
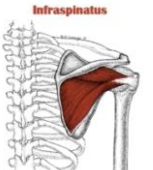
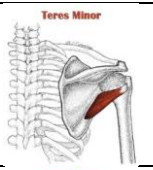
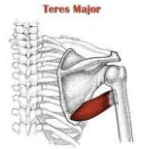
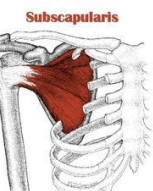
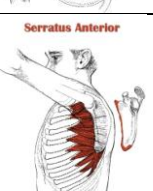


Notes	Muscle	Picture	Location	Origin	Insertion	Nerve Supply	Action
Muscles Of The Pectoral Region	Pectoralis Major		Under The Deep Fascia in The Pectoral Region	Sternum & Clavicle	Lateral Lip of The Intertubercular Groove	Medial & Lateral Pectoral Nerves	Adduction Medial Rotation
	Pectoralis Minor		Below Pectoralis Major	3rd, 4th & 5th Ribs	Coracoid Process	Medial Pectoral Nerve	Draws The Scapula Inferior & Medial
	Subclavius		Below Clavicle	1st Rib	Inferior Surface of Clavicle	Nerve To Subclavius	Acts As Cushion To Protect Underlying Structures
Muscles Connecting The Upper Limb To The Scapula	Deltoid			Spine of Scapula (Posterior) Acromion (Laterally) Clavicle (Anterior)	Deltoid Tuberosity	Axillary Nerve	Abduction (15 -90)
	Supraspinatus			Supraspinatus Fossa	Greater Tubercle	Suprascapular Nerve	Initiation of Abduction (0 - 15)
	Infraspinatus		Under The Spine	Infraspinous Fossa	Greater Tubercle	Suprascapular Nerve	Lateral Rotation of The Arm
	Teres Minor			The Upper 2/3 of The Lateral Border of The Scapula	Greater Tubercle	Axillary Nerve	Lateral Rotation of The Arm
	Teres Major			Lateral Border of The Scapula	Medial Lip of The Intertubercular Groove	Lower Subscapular Nerve	Medial Rotation Adduction
	Subscapularis		Anterior Side of The Scapula	Subscapular Fossa	Lesser Tubercle	Upper & Lower Subscapular Nerves	Medial Rotation
	Serratus Anterior			Upper 8 Limbs	Medial Border of Scapula	Long Thoracic Nerve	Protraction

