Nerve Tissue

Development of Nerve Tissue

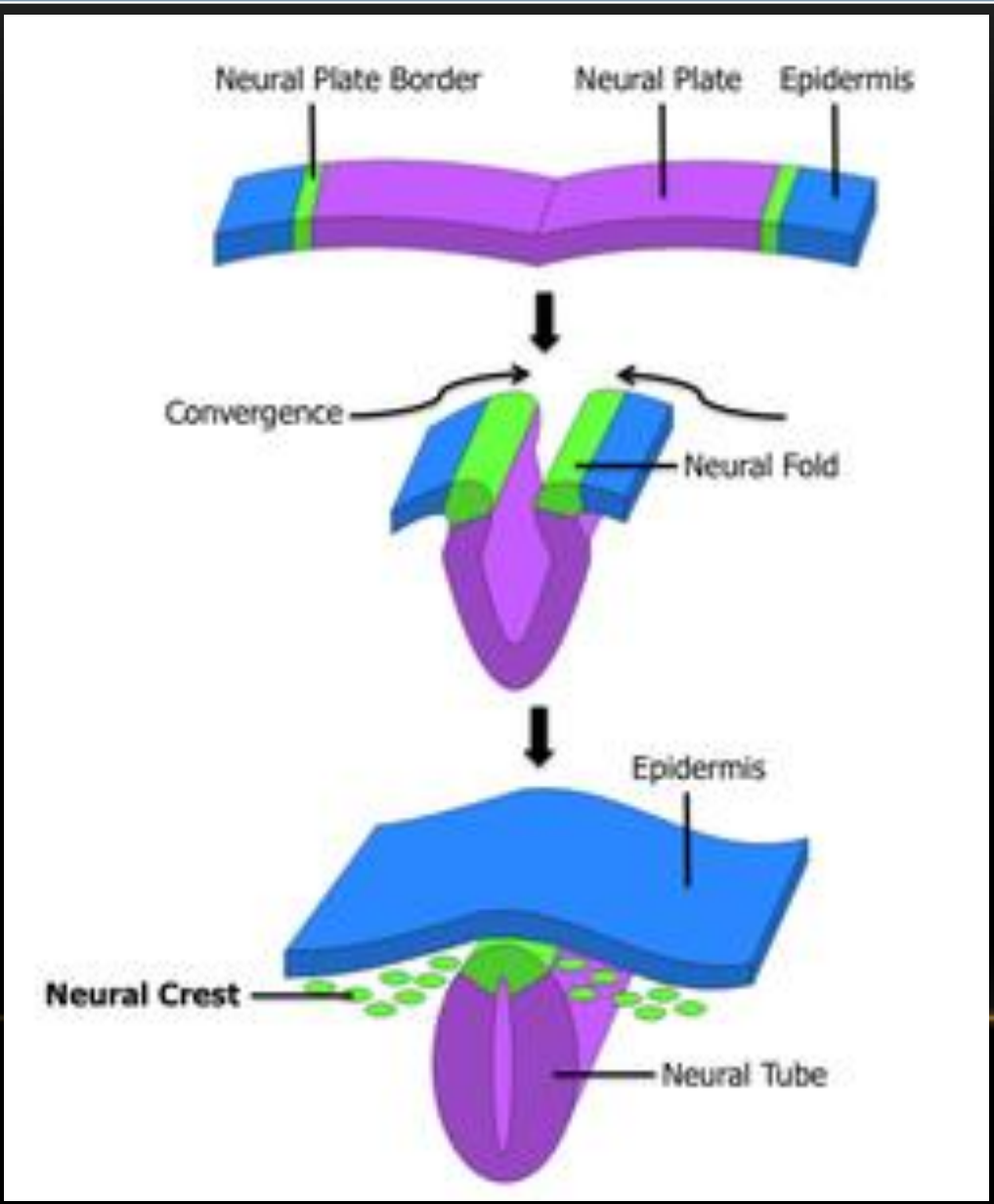

Subdivisions of Nervous System

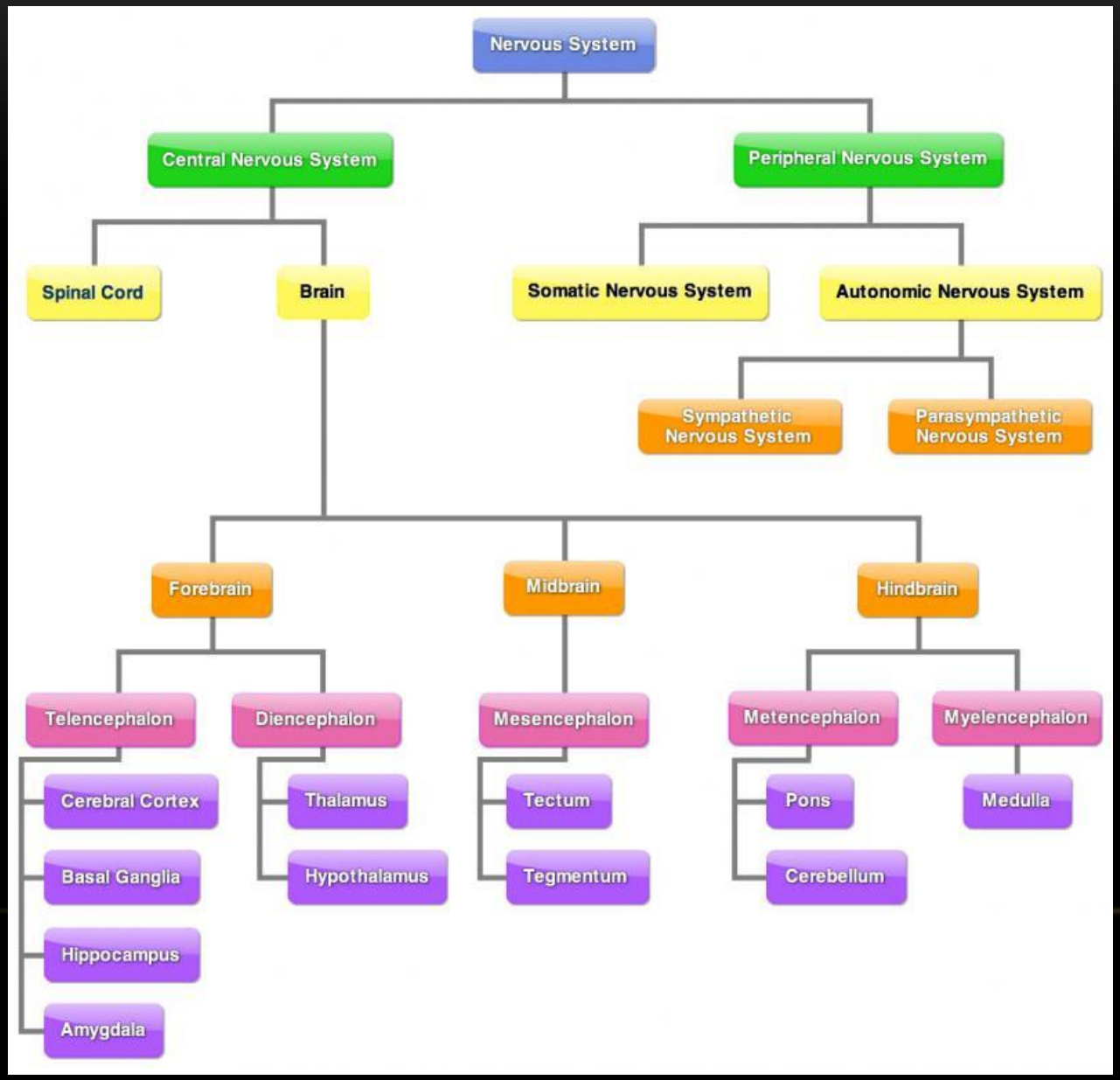

Properties of Neurons

Excitability (irritability): ability to respond to environmental changes or stimuli.

Conductivity: respond to stimuli by initiating electrical signals that travel quickly to other cells at distant locations.

Secretion: Upon arrival of the impulse at a location the neuron usually secretes a neurotransmitter at a synapse that crosses the synaptic gap and stimulates the next cell.

Functional Classes of Neurons

Sensory (afferent) neurons – afferent neurons are specialized to detect stimuli and transmit the information to CNS. They begin in any organ in the body, but end in the brain or spinal cord.

Interneuron (association neurons): lie entirely in the CNS. They receive signals from many different neurons and perform an integrative function "decision making" to respond to the different stimuli.

Motor (efferent) neurons – efferent neurons transmit the appropriate response from the interneuron to an end organ (muscle and gland cells) to carry out the body's response to the stimuli.

Functional Classification of Neurons

Based on the direction of conduction

- Sensory or afferent conduct toward the CNS
- Motor or efferent conduct away from the CNS
- Interneuron interposed between sensory and motor

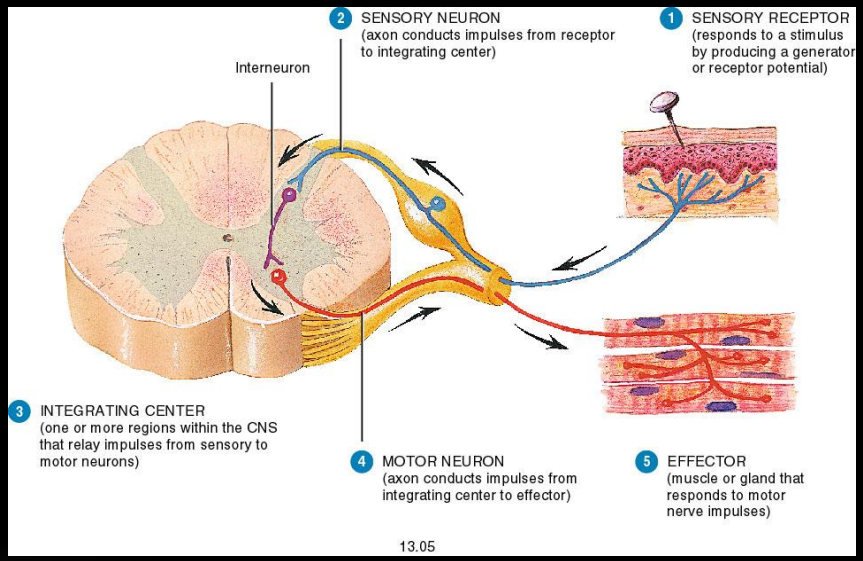

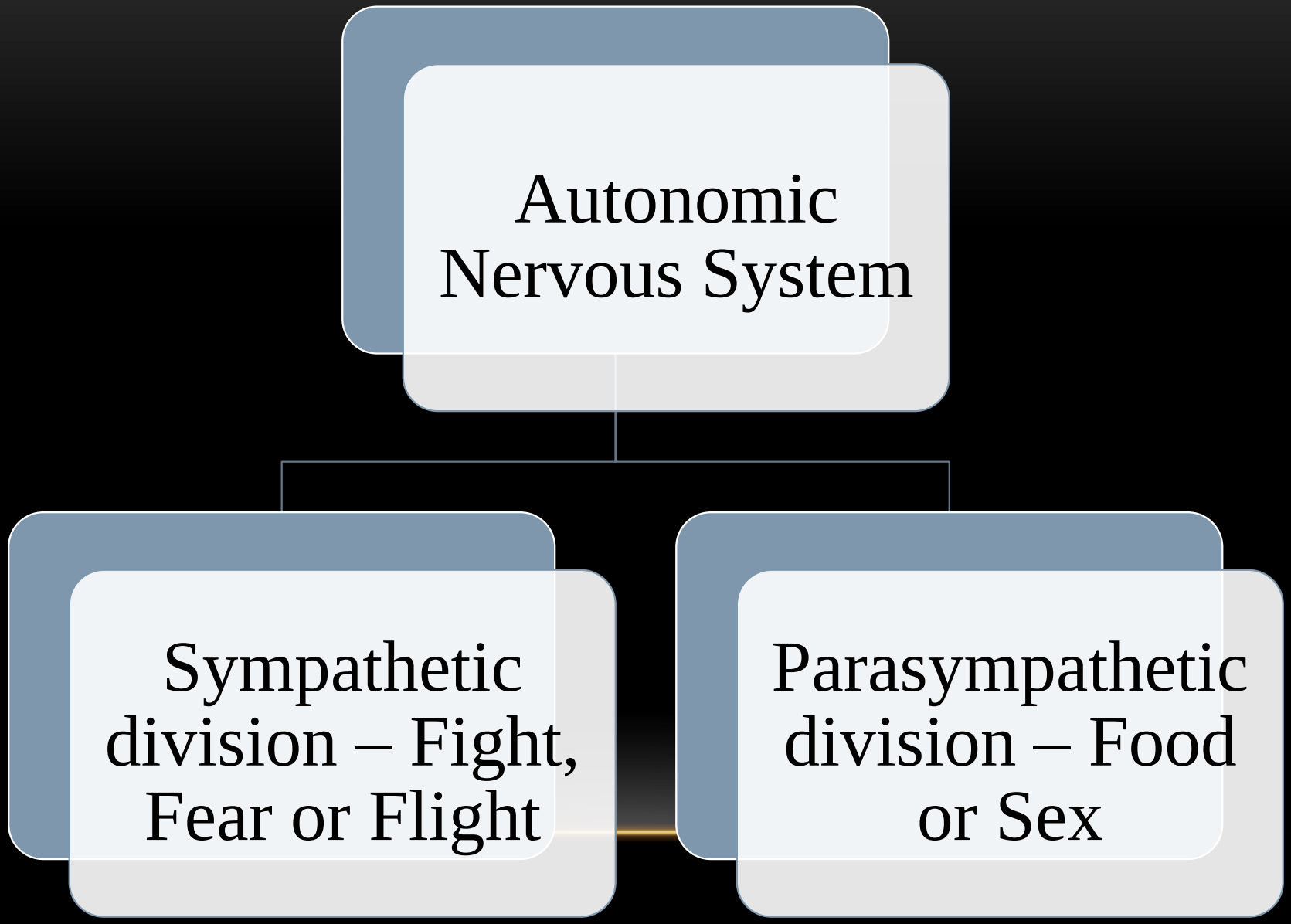
Autonomic Nervous System
Sympathetic division – Fight, Fear or Flight
Parasympathetic division – Food or Sex

CNS/PNS summary

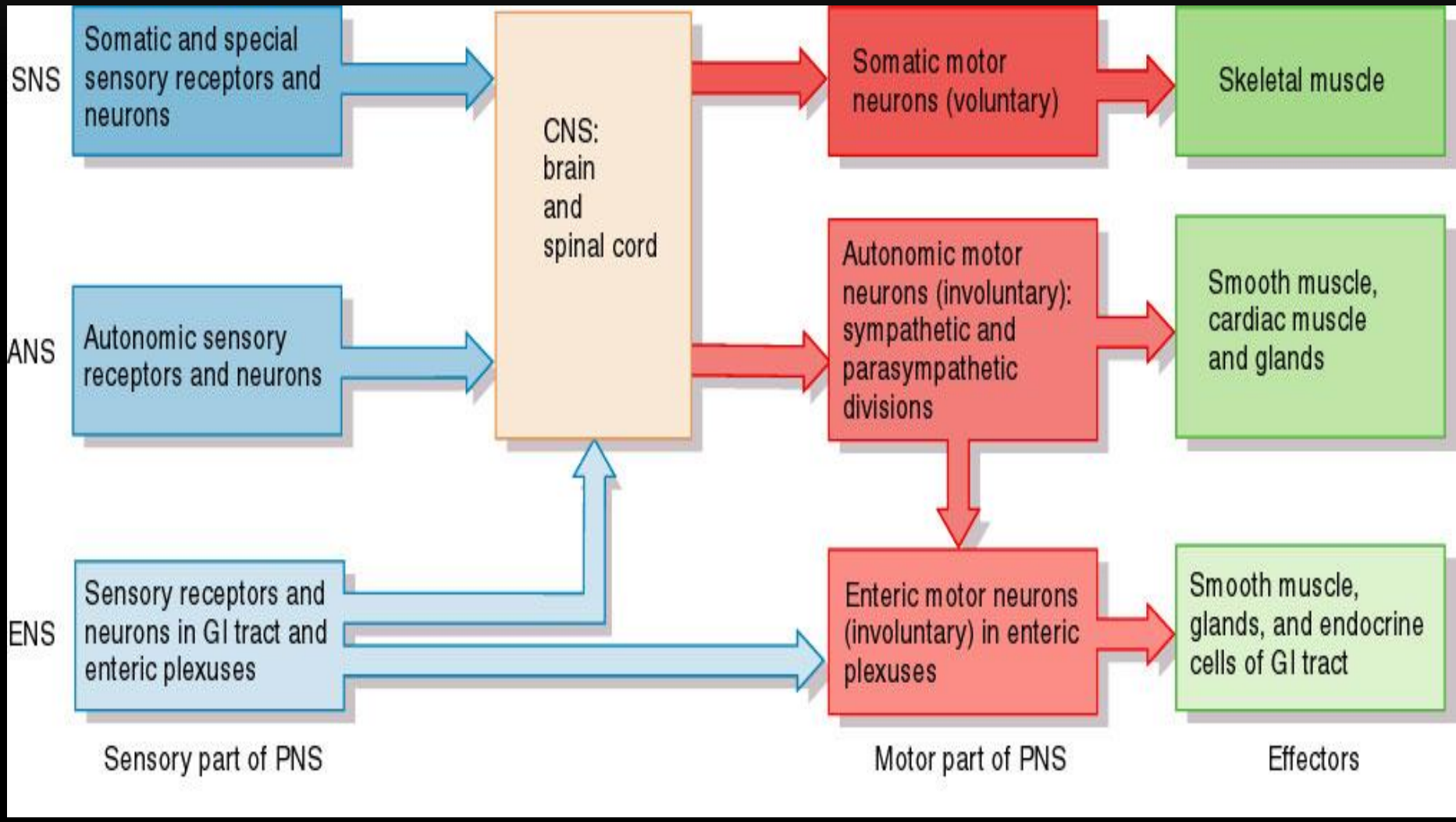

Neurons

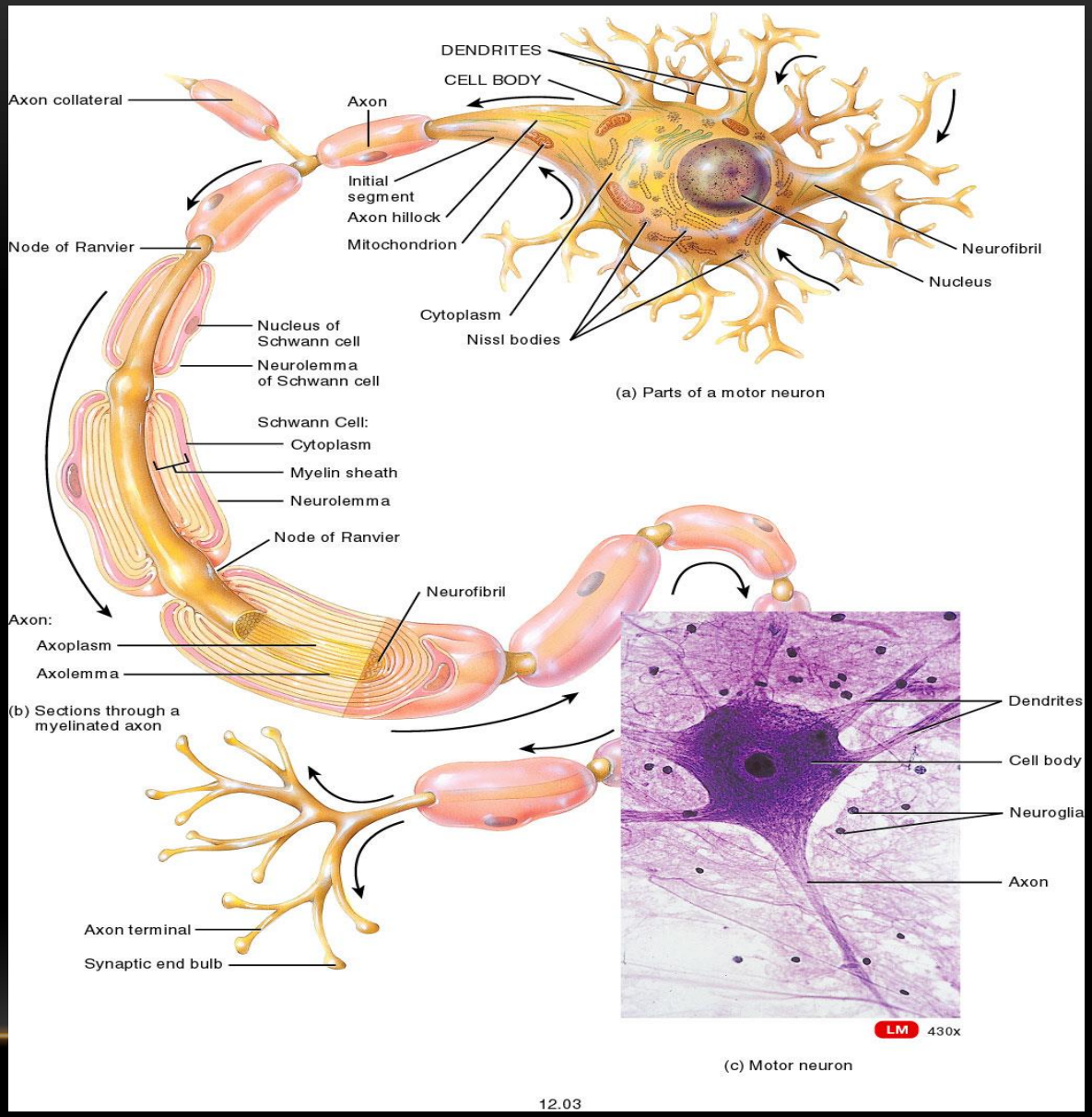
DENDRITES
CELL BODY
Axon collateral
Axon
Initial segment
Axon hillock
Mitochondrion
Node of Ranvier
Neurofibril
Nucleus
Cytoplasm
Nissl bodies
Nucleus of Schwann cell
Neurolemma of Schwann cell
(a) Parts of a motor neuron
Schwann Cell:
Cytoplasm
Myelin sheath
Neurolemma
Node of Ranvier
Neurofibril
Axon:
Axoplasm
Axolemma
(b) Sections through a myelinated axon
Dendrites
Cell body
Neuroglia
Axon
Axon terminal
Synaptic end bulb
LM 430x
(c) Motor neuron
12.03

Structural Classification of Neurons ..1

- Neurons may be: Multipolar, Bipolar or Unipolar
- Determined by the number of processes attached to the cell body

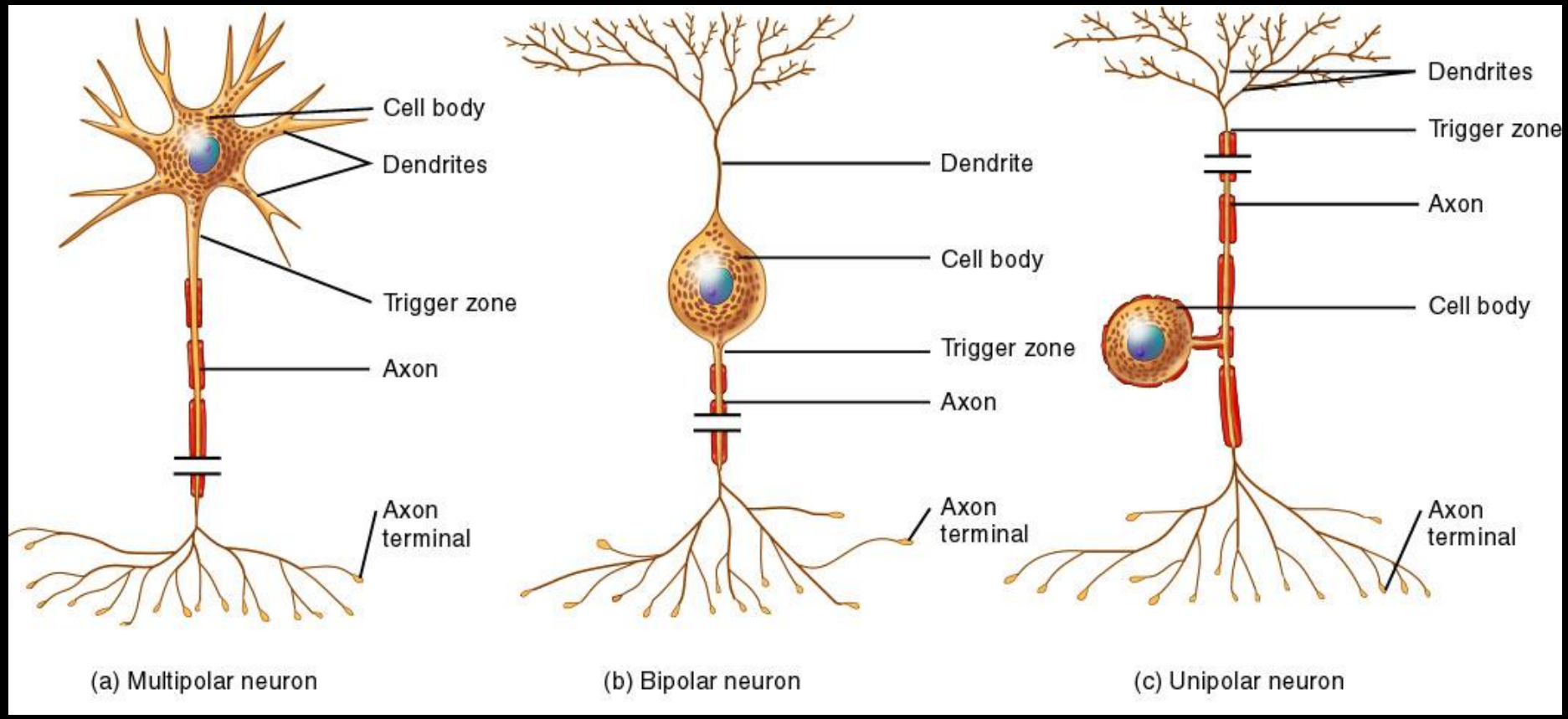

Structural Classification of Neurons ..2

Multipolar Neurons

- One axon and two or more dendrites
- Most neurons are multipolar

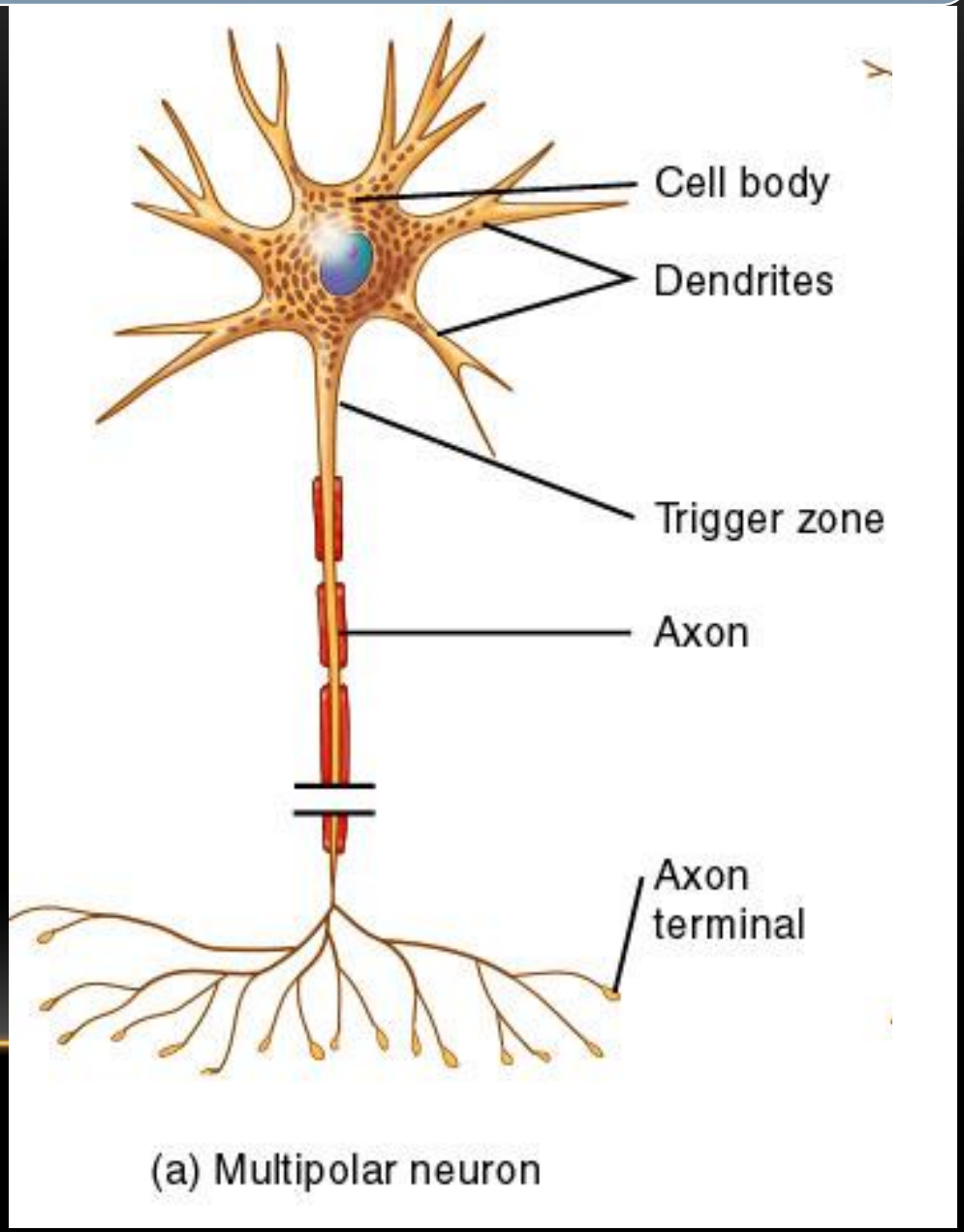

Structural Classification of Neurons ..3

Bipolar neurons:

- One dendrite and one axon
- Found in the retina, olfactory epithelium, and the inner ear.

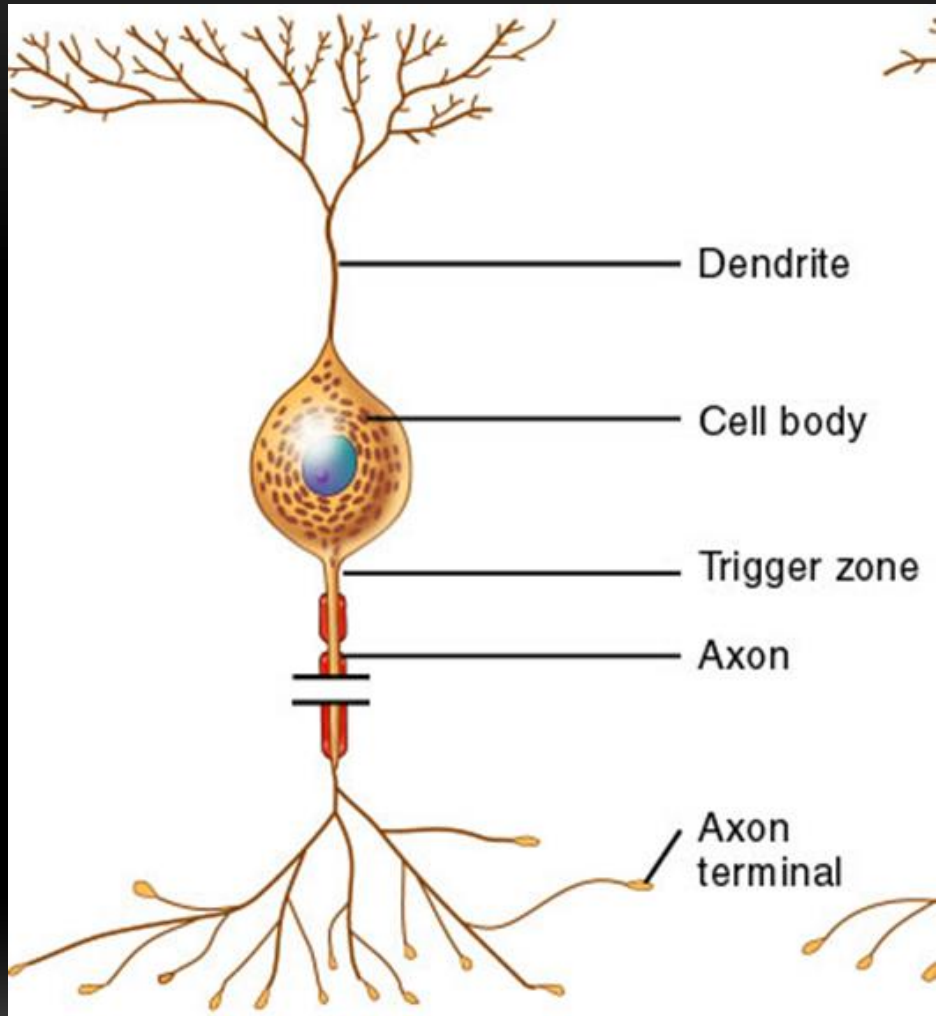

(b) Bipolar neuron

Structural Classification of Neurons ..4

Unipolar neurons (pseudounipolar) :

- Have a single process that divides into axon and dendrites
- Found in spinal ganglia

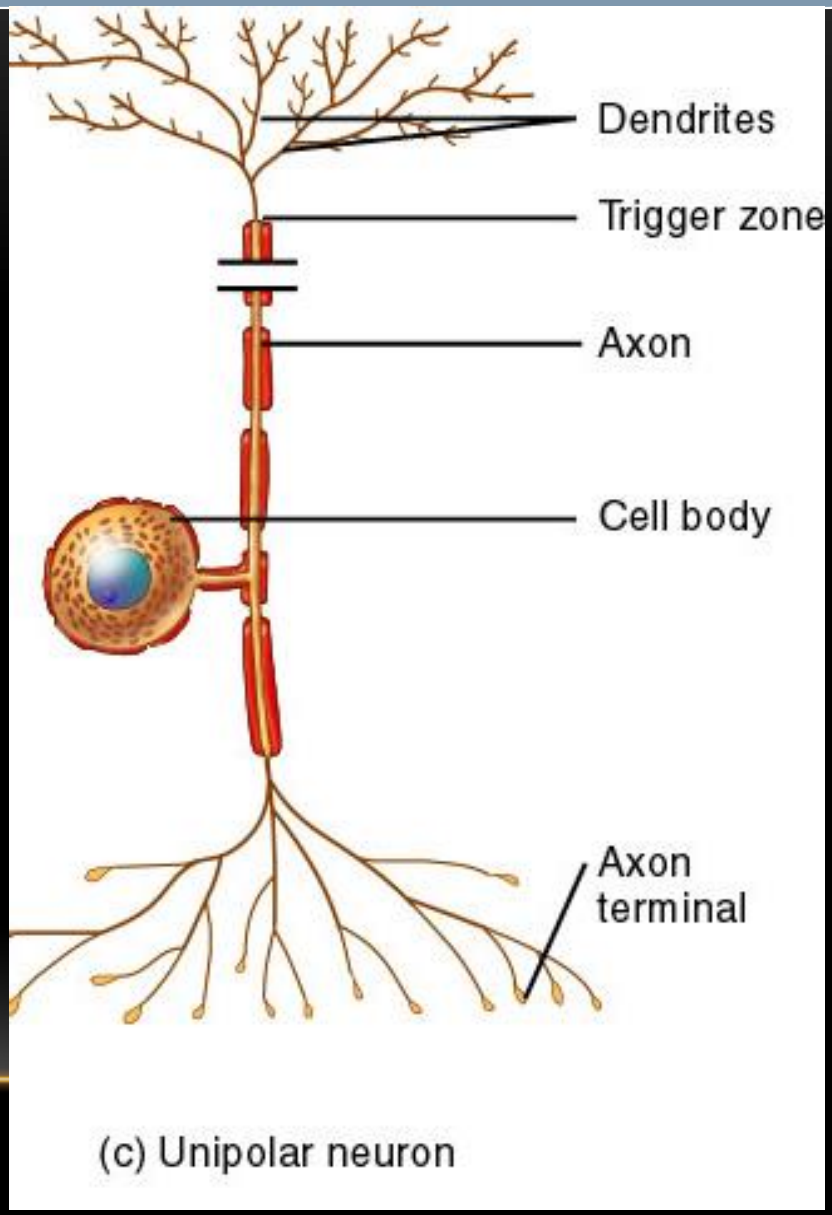

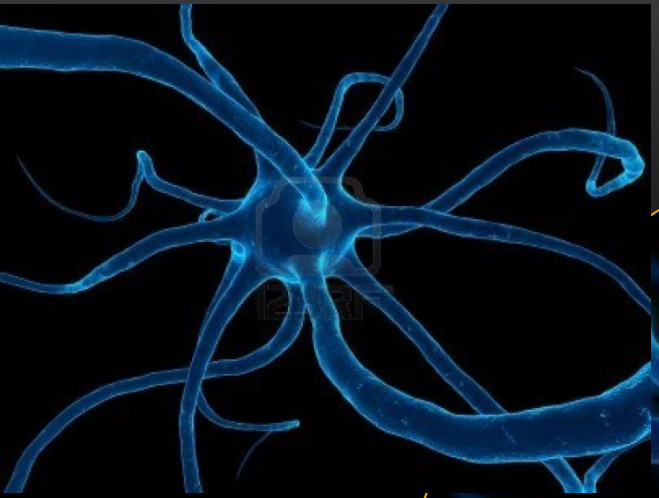

Cell Body

Structure of the Neuron ..

(1/4) cell body

Cell body = Soma = Perikaryon

- Always present in the central nervous system or ganglia associated with the central nervous system.
- It is the trophic center of the nerve.
- It may act as a receptor as well.

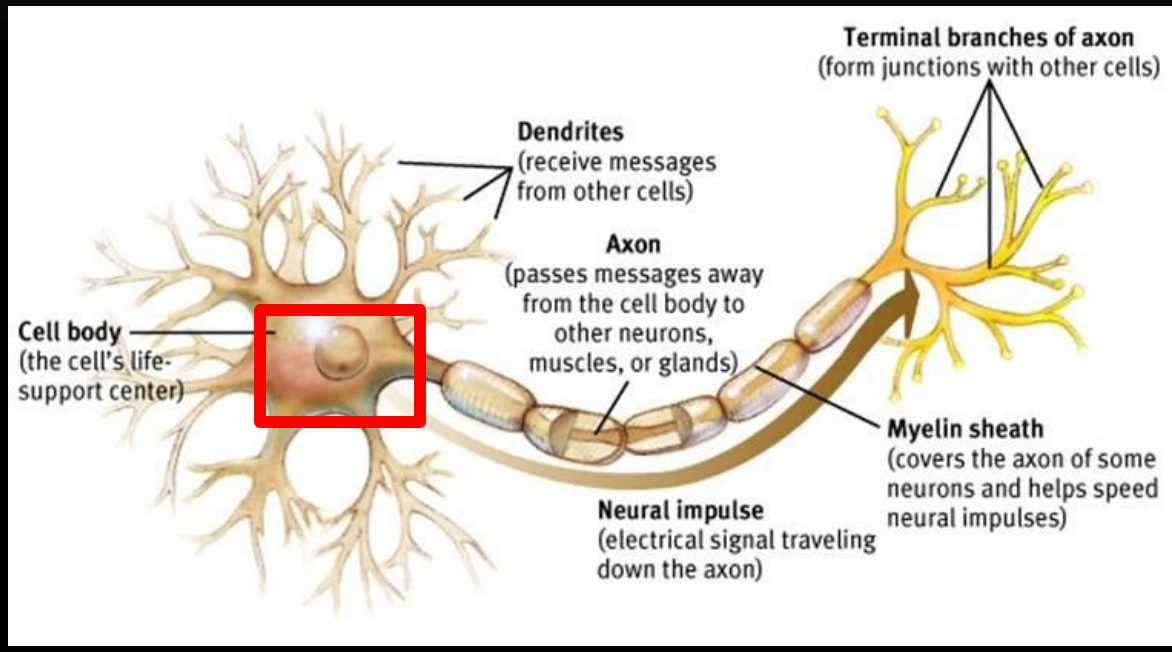

Structure of the Neuron ..
(2/4) cell body

Nucleus:

- Spherical and large.
- Has a prominent nucleolus.
- Chromatin is finely dispersed.
- Binulceated nerves are common special in sensory and sympathetic nerves.

Structure of the Neuron ..

(3/4) cell body

Rough Endoplasmic reticulum (rER):

- Highly developed
- Form aggregates
- Their cisterns are parallel
- Cisterns are separated by ribosomes.
- Aggregates of rER and ribosomes appear as ***Nissl Bodies*** which are large in motor neurons.

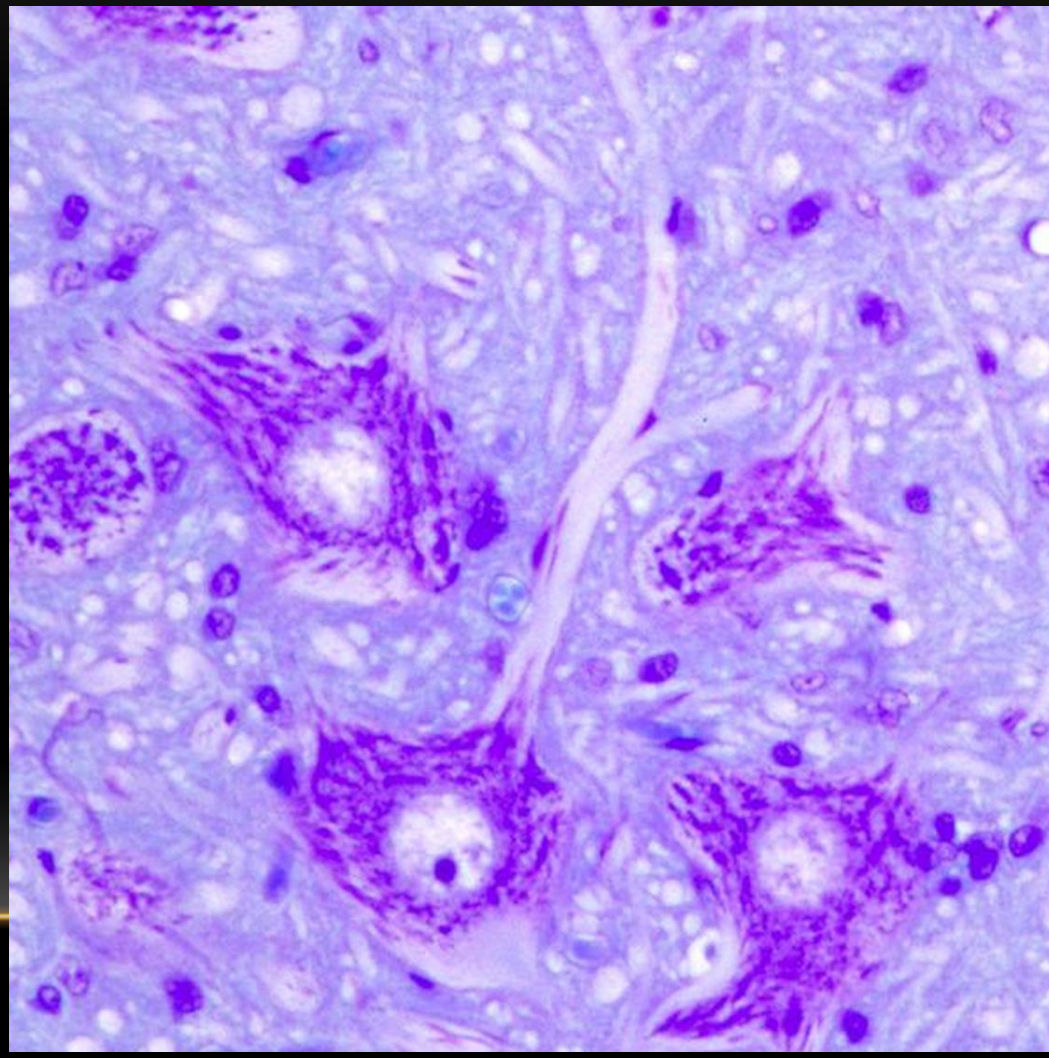

Structure of the Neuron ..
(4/4) cell body

- Golgi apparatus is only seen in the cell body.
- Mitochondria are seen in all parts of the nerve.
- Neurofilaments are seen in all parts.
- Microtubules are frequent.
- Residual bodies (lipofuscin) can be occasionally seen

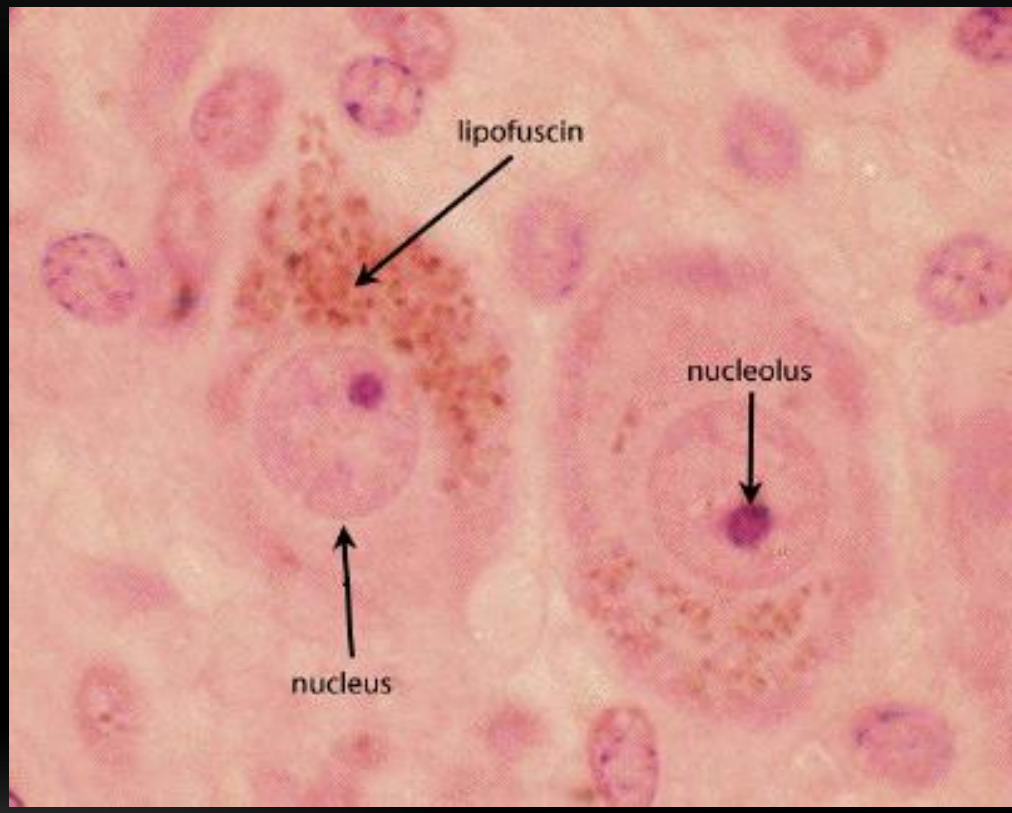

Dendrites

- Short and divide repeatedly.
- Covered my may synapses.
- Their diameters decreases as they branch.
- Cell organelles are seen close to the origin of the dendrite except Golgi apparatus.
- At the site of synapse, there is a dendritic spine, it contains actin filaments.

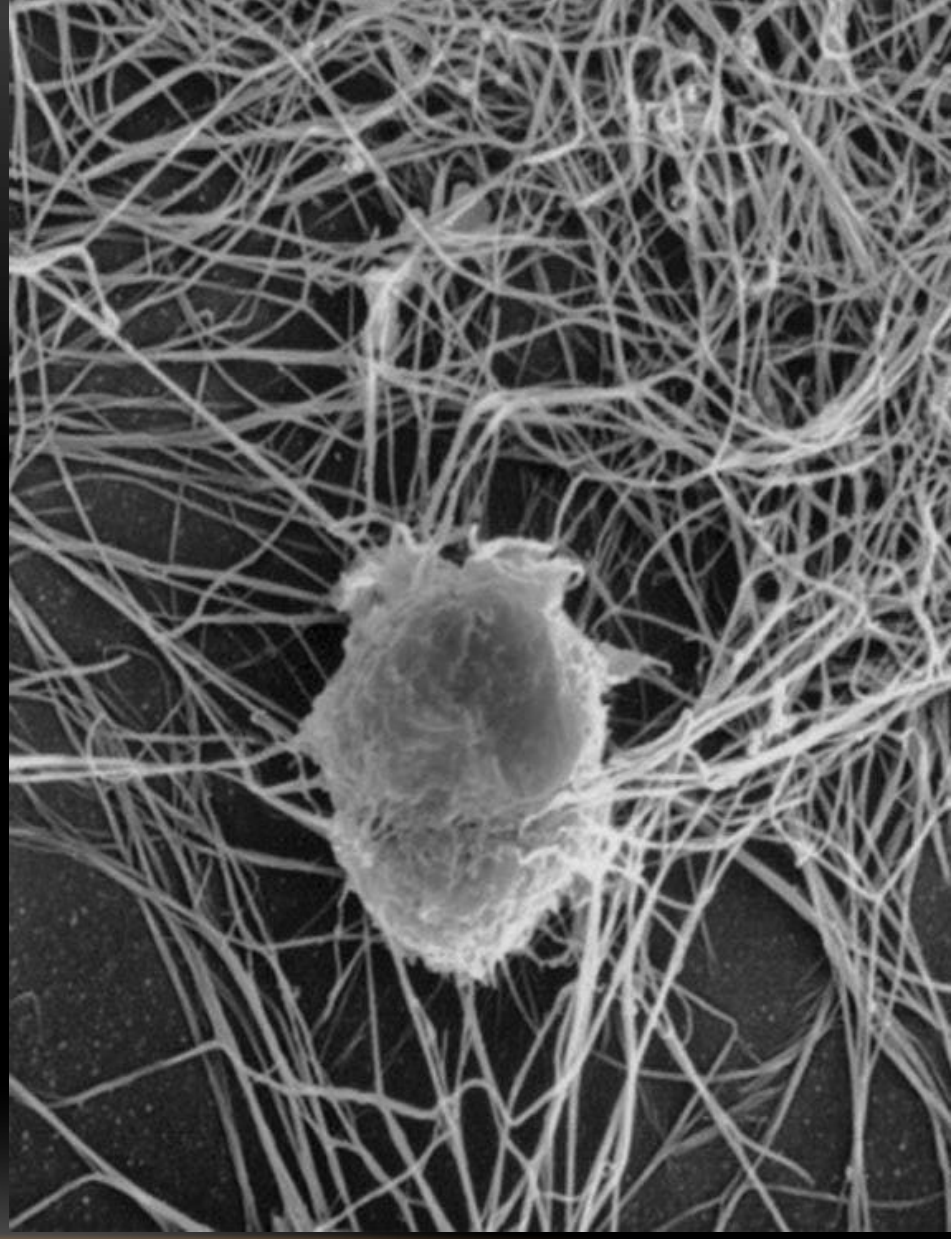

Axon 1/5

Varies in length and diameter according to the type of neuron. Axons are usually very long processes.

All axons originate from a pyramid-shaped region, the **axon hillock,** arising from the perikaryon.

The plasma membrane of the axon is called the **axolemma** and its contents are known as **axoplasm.**

Just beyond the axon hillock, at an area called the **initial segment**, is the site where various excitatory and inhibitory stimuli are algebraically summed.

Axon 2/5

- Several types of ion channels are localized in the initial segment and these channels are important in generating the action potential.
- Axons have a constant diameter and do not branch profusely.
- Axons may give rise to a branch that returns to the area of the nerve cell body.

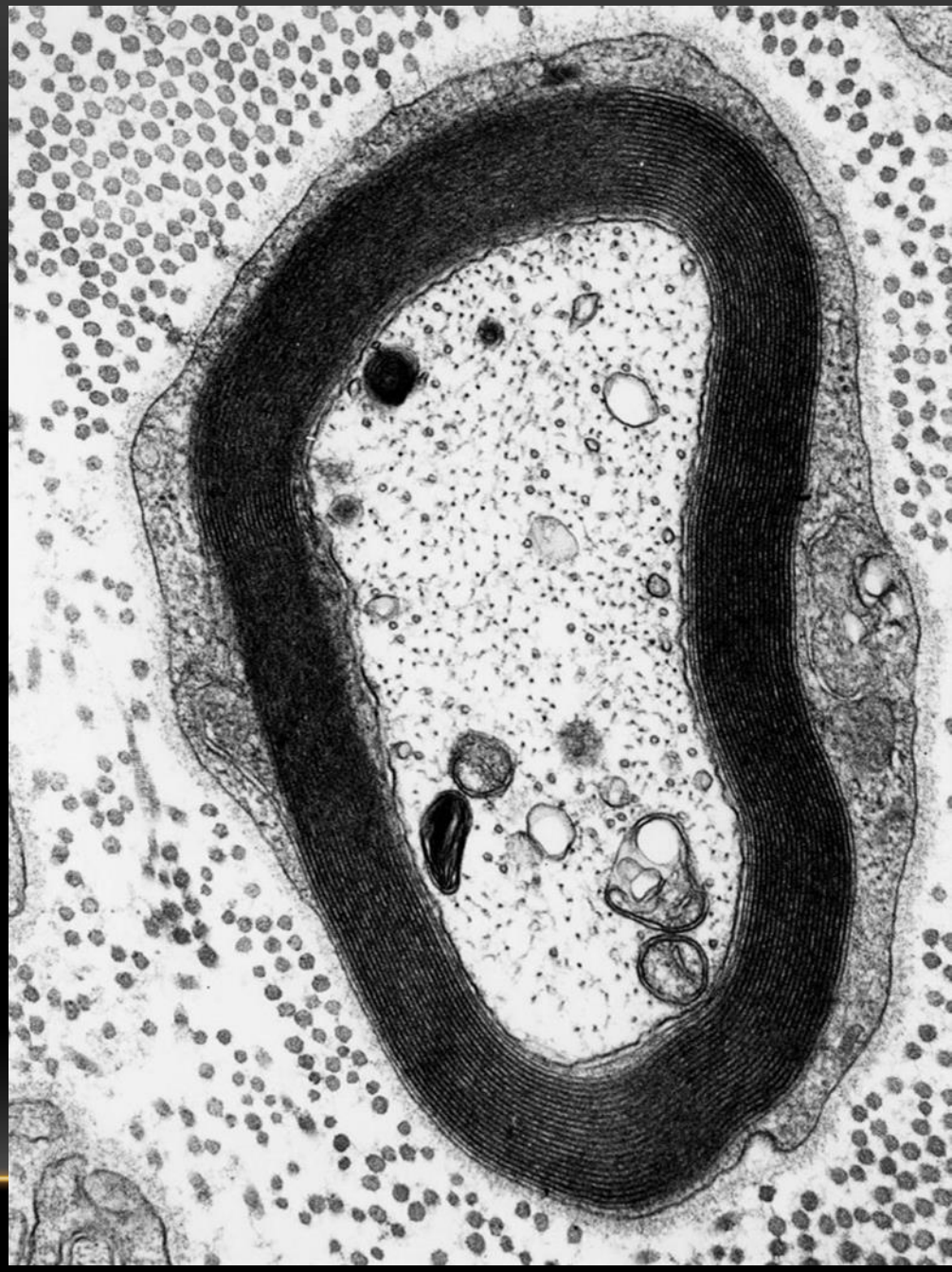

Axon 3/5

Axoplasm contains mitochondria, microtubules, neurofilaments, and some cisternae of smooth ER.

The absence of polyribosomes and rough ER emphasizes the dependence of the axon on the perikaryon for its maintenance.

If an axon is cut, its peripheral parts quickly degenerate.

Small and large molecules are transported along the axon in both directions.

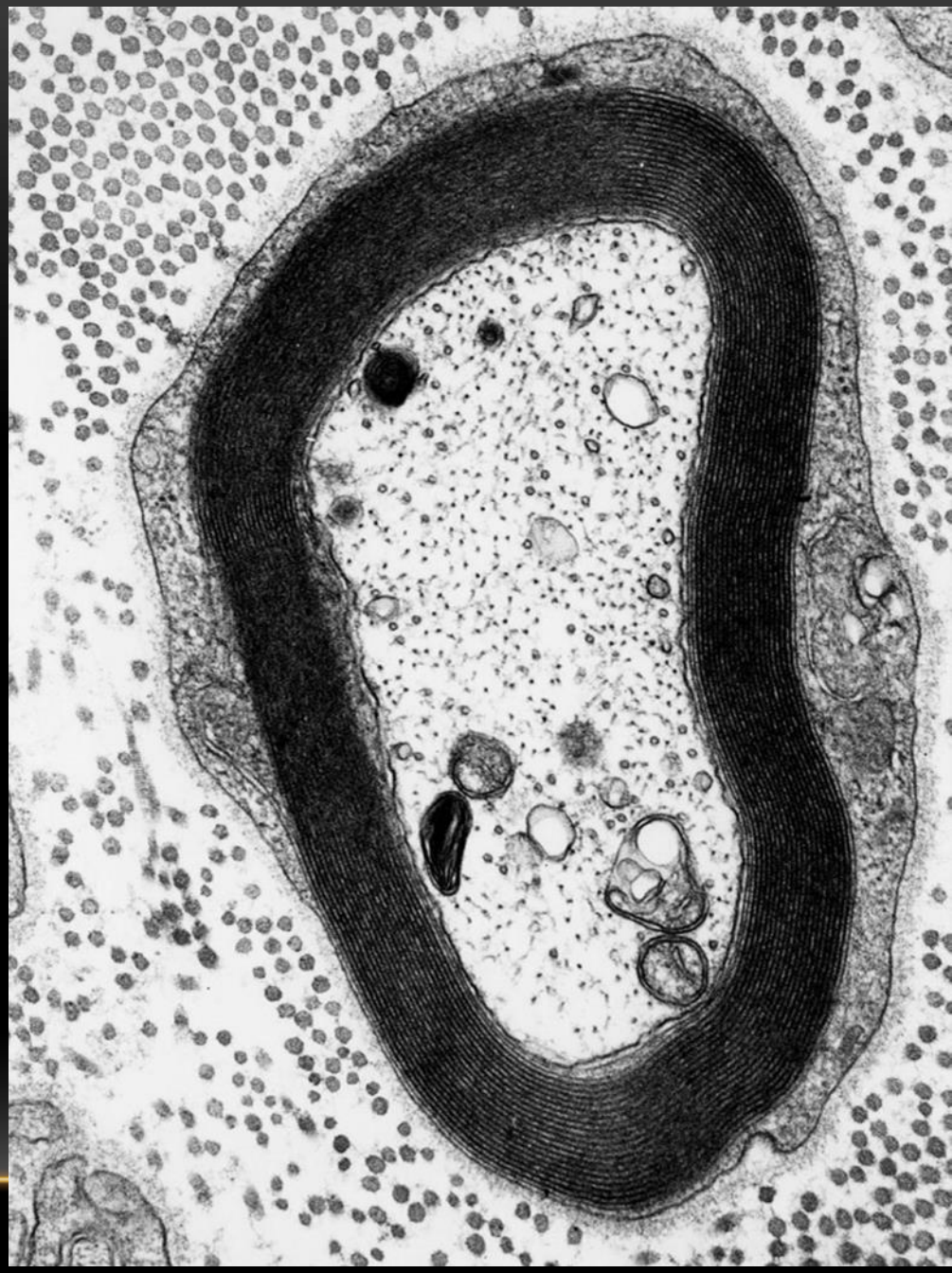

Axon 4/5

Organelles and macromolecules synthesized in the cell body move by **anterograde transport**

Retrograde transport in the opposite direction carries certain other macromolecules, such as material taken up by endocytosis

Axonal transport in both directions utilizes motor proteins attached to microtubules,

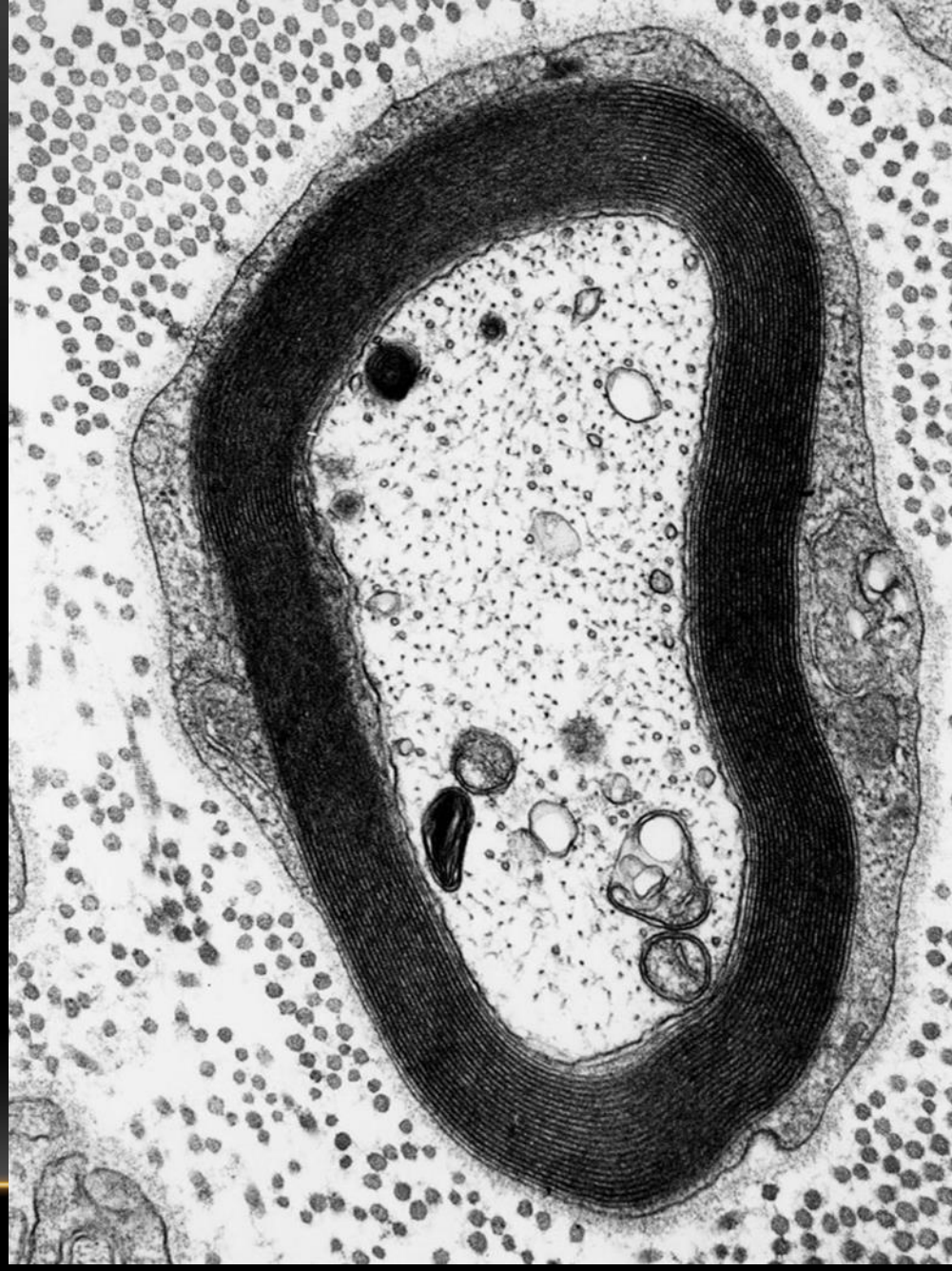

Axon 5/5

Kinesin, a microtubule-activated ATPase, attaches to vesicles and allows them to move along microtubules in axons away from the perikarya.

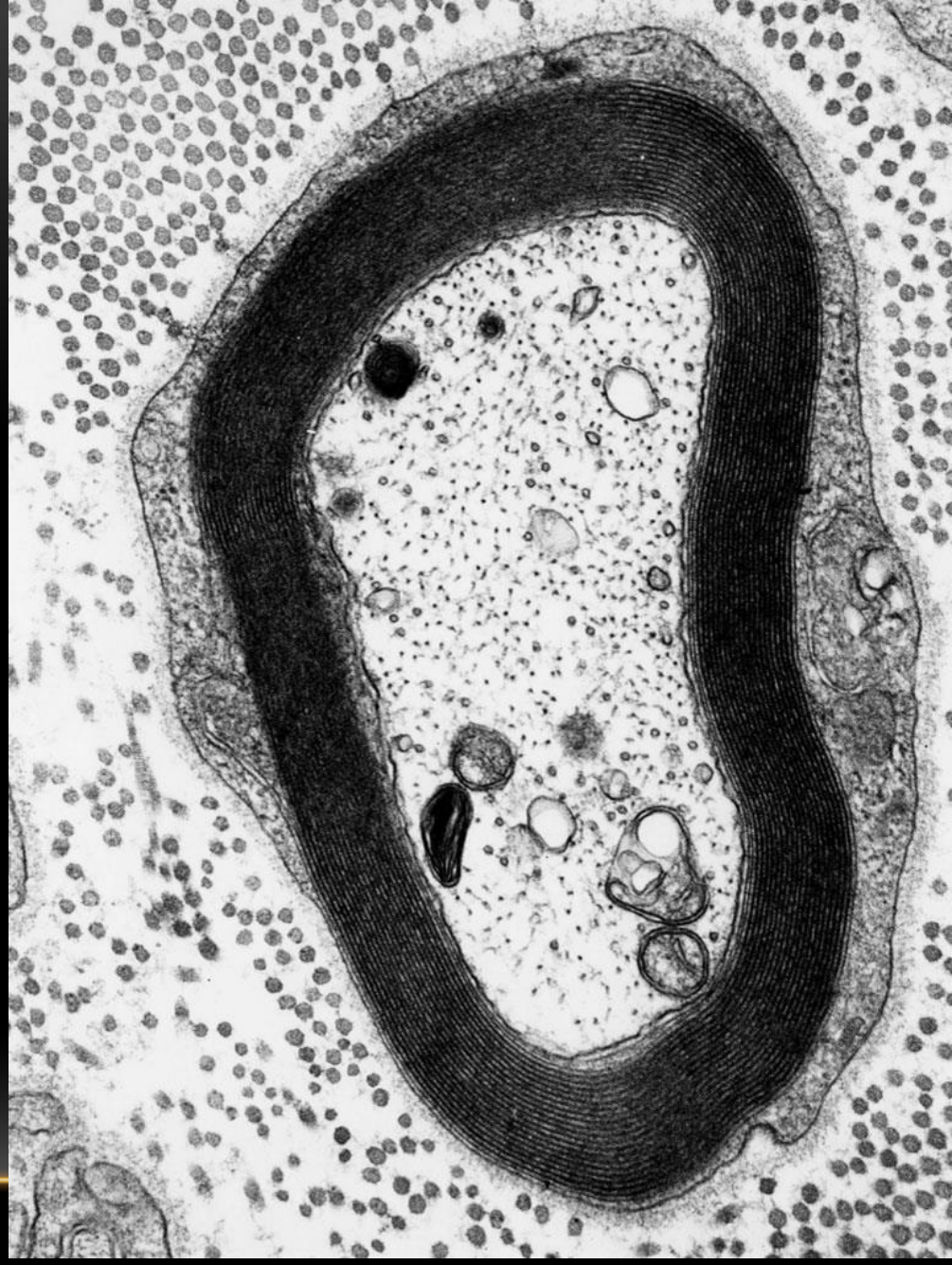

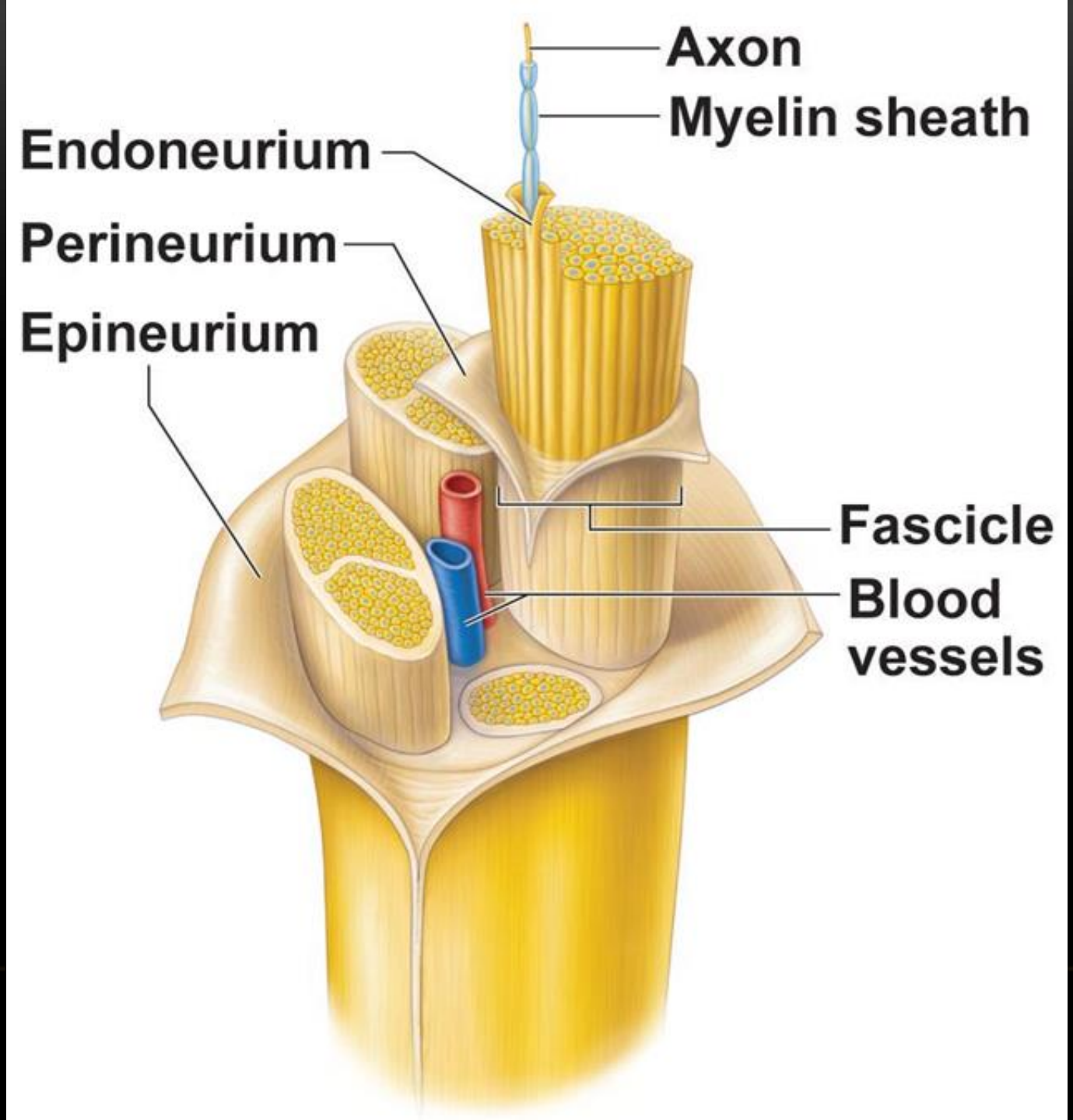
Axon
Myelin sheath
Endoneurium
Perineurium
Epineurium
Fascicle
Blood vessels

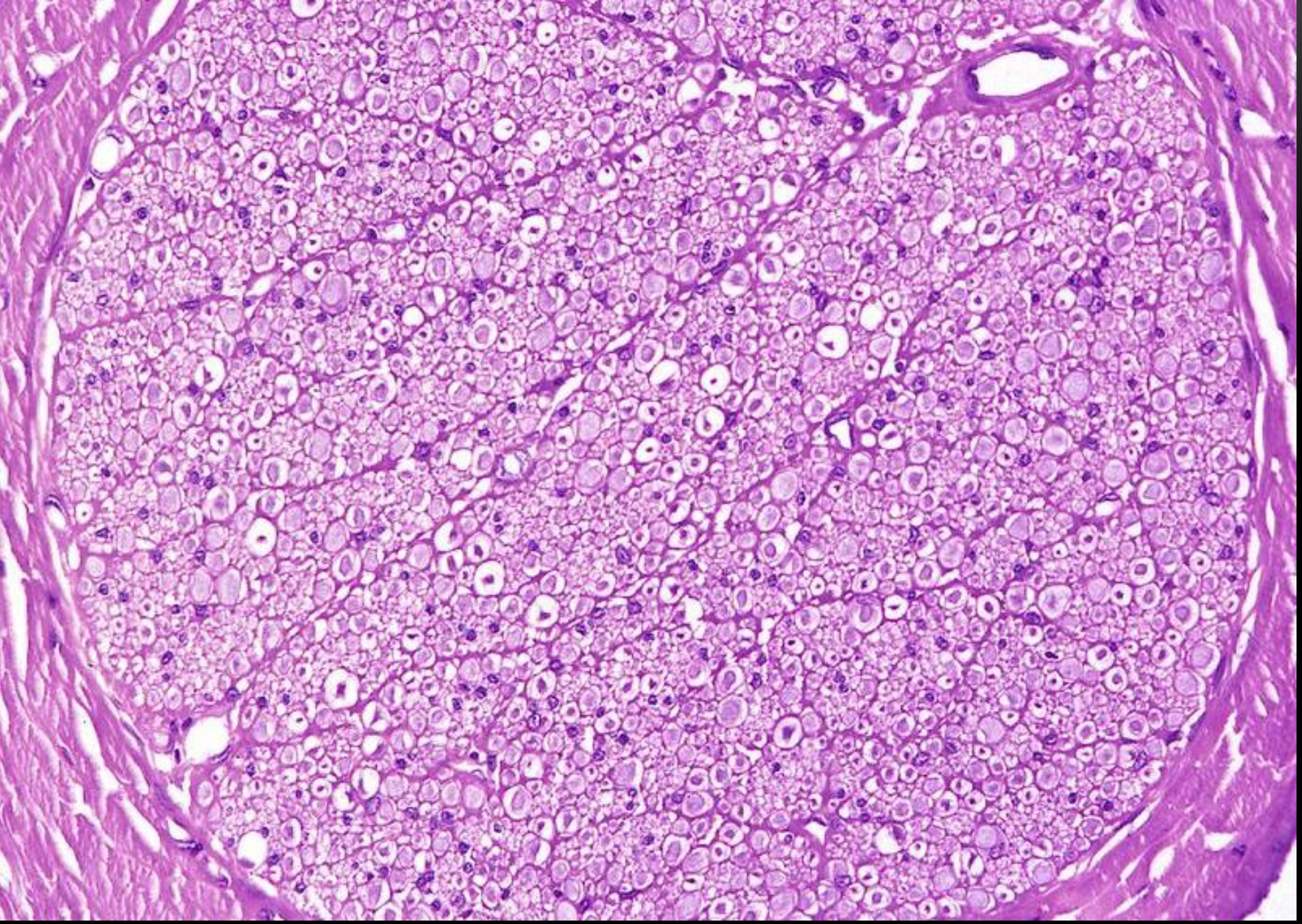

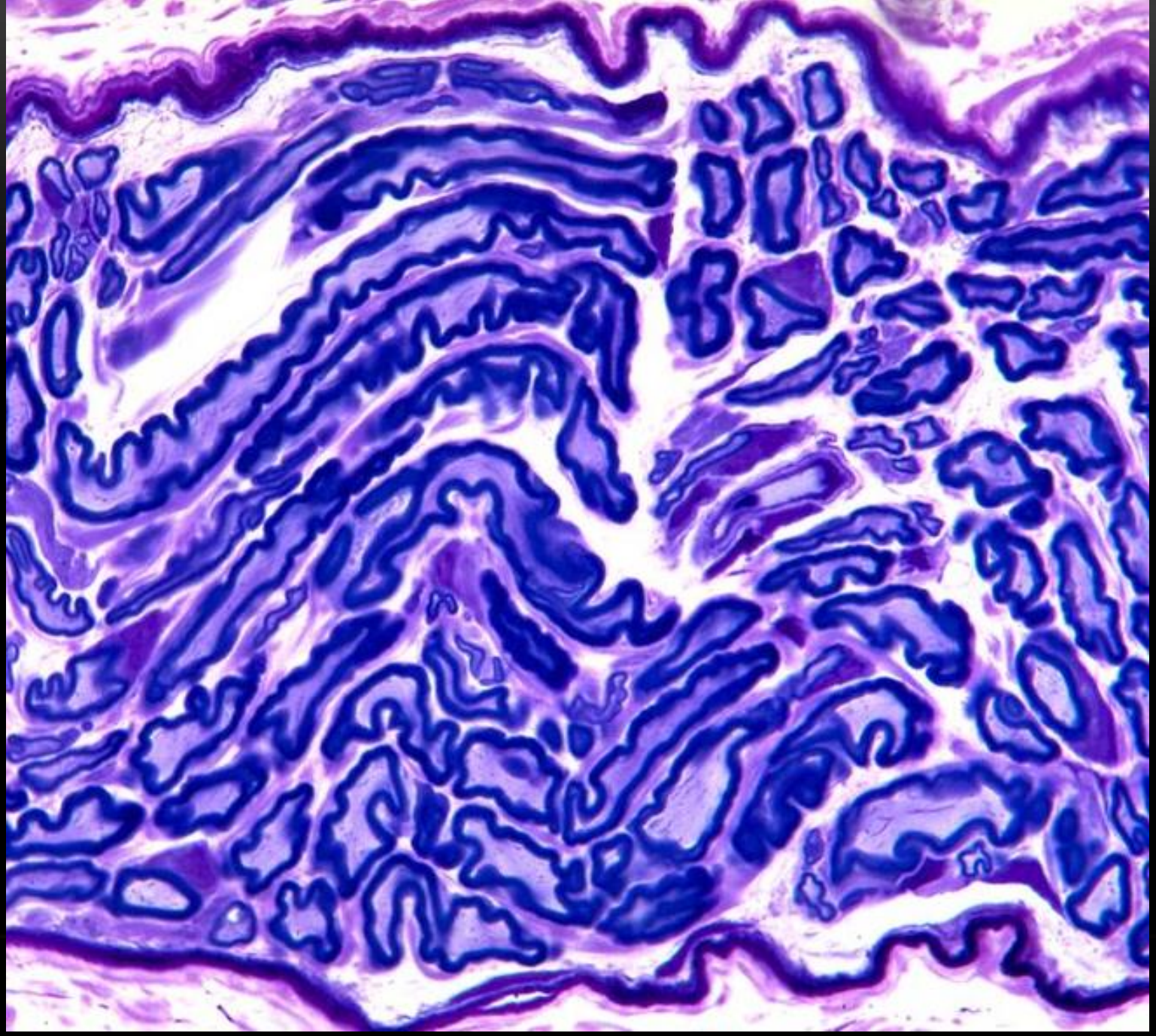

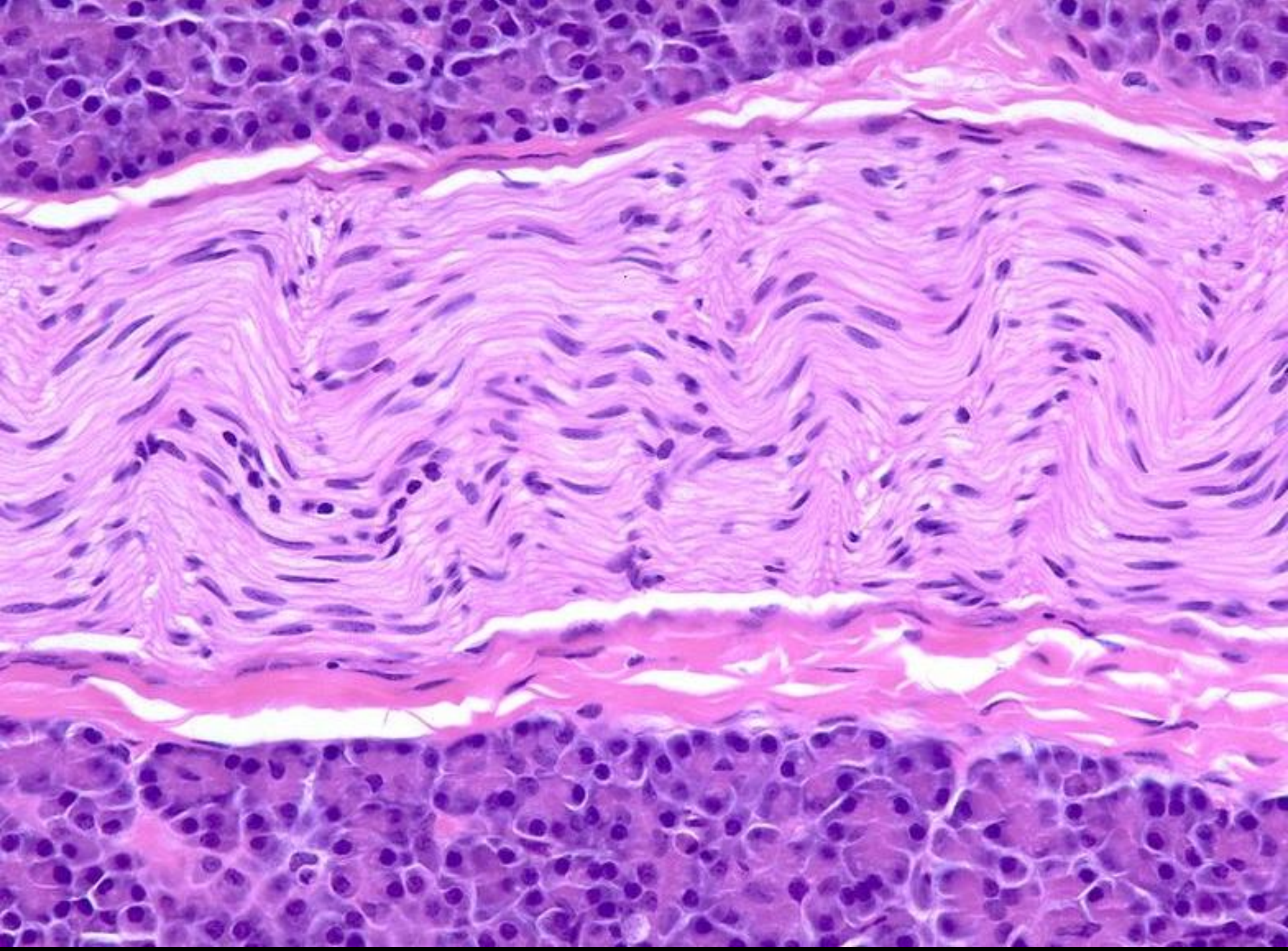

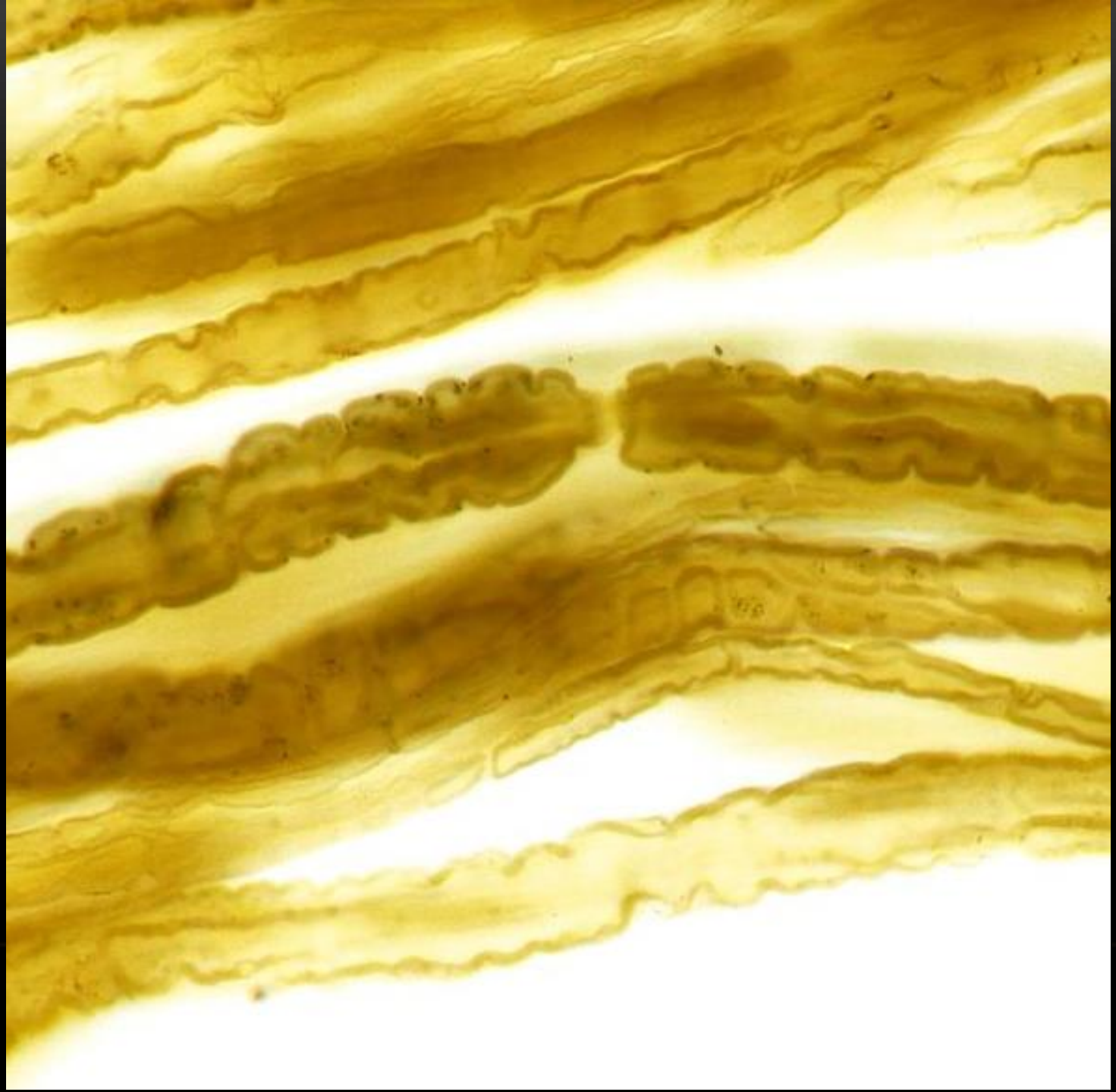

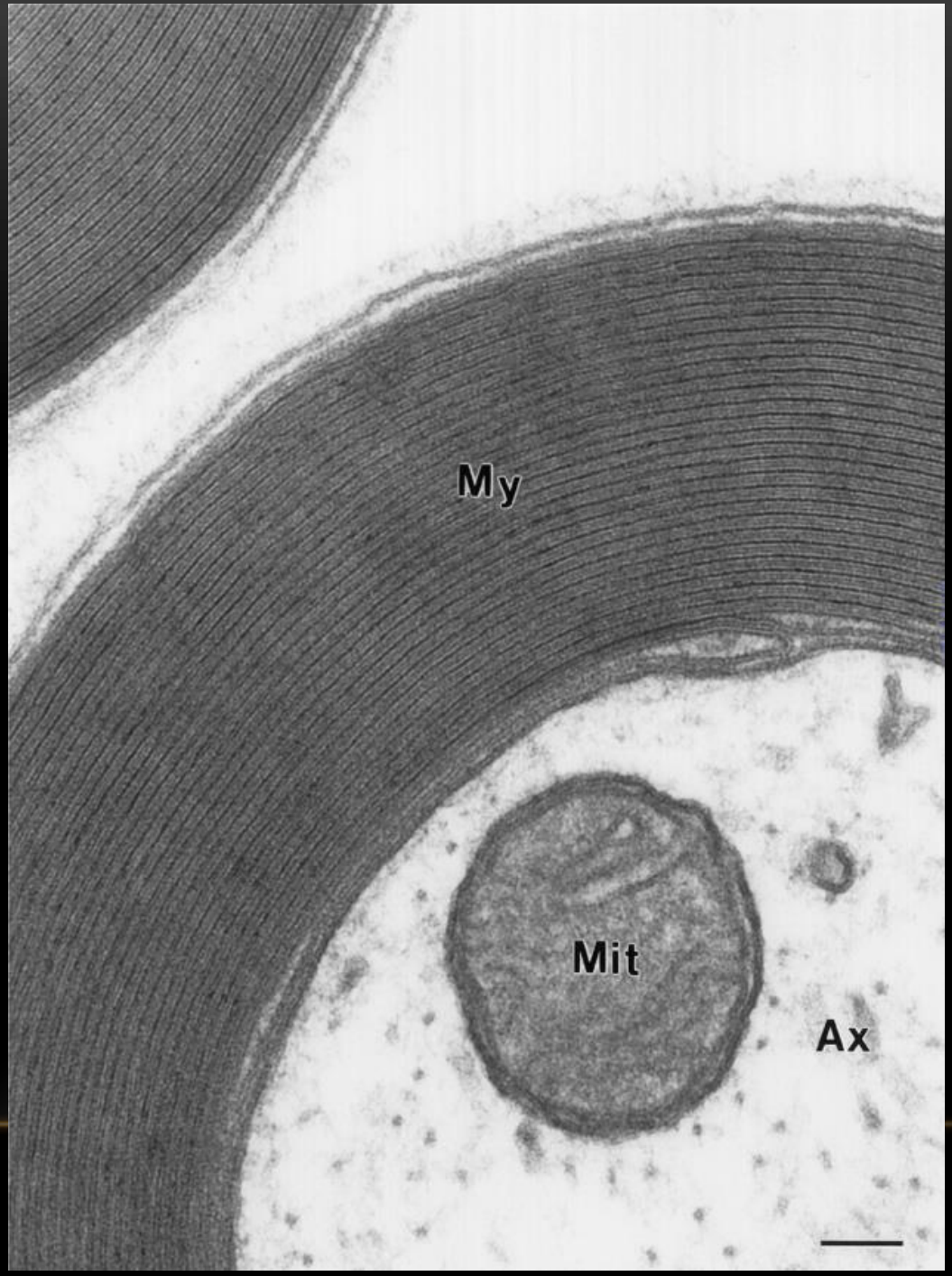
My
Mit
Ax

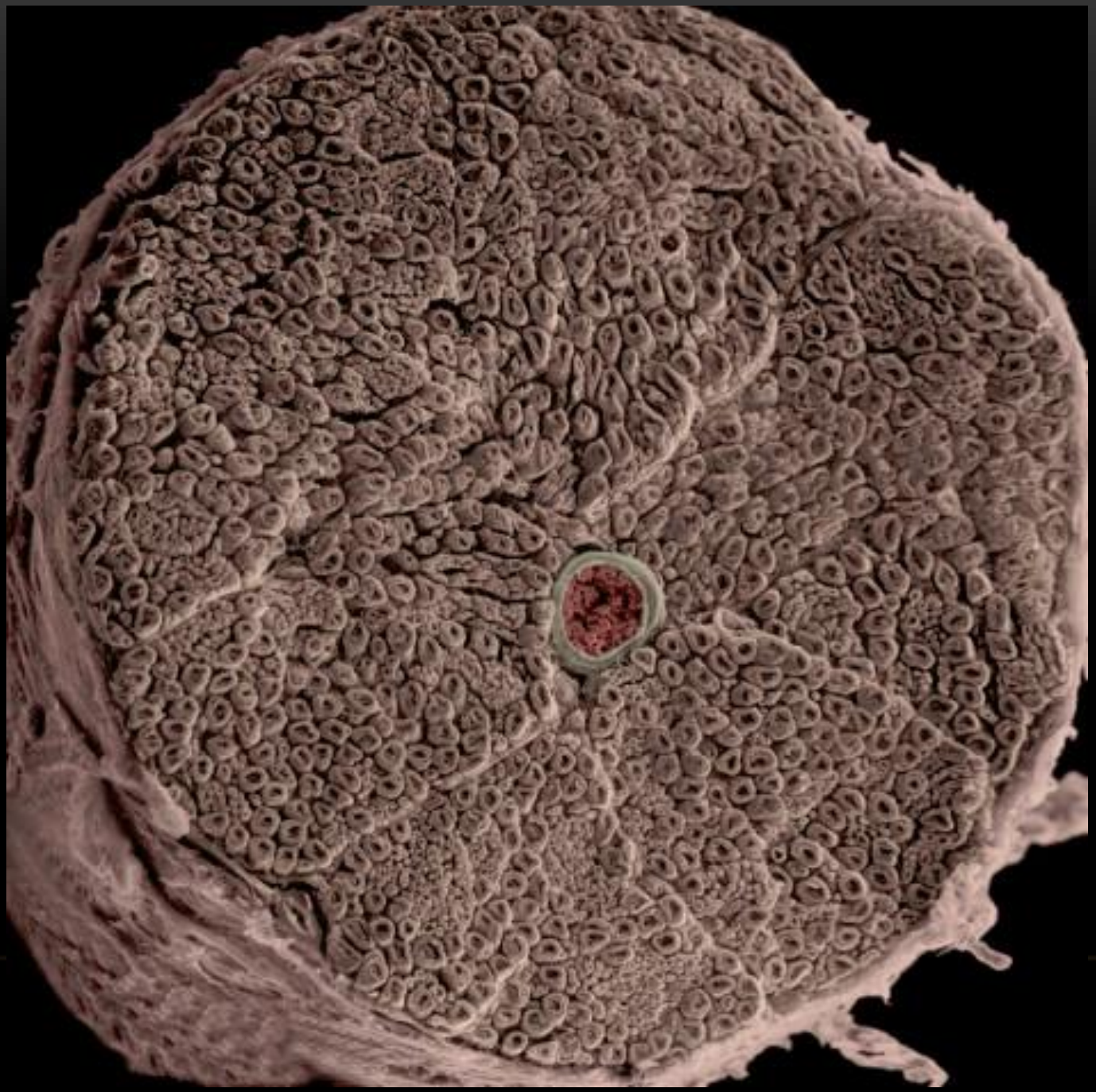

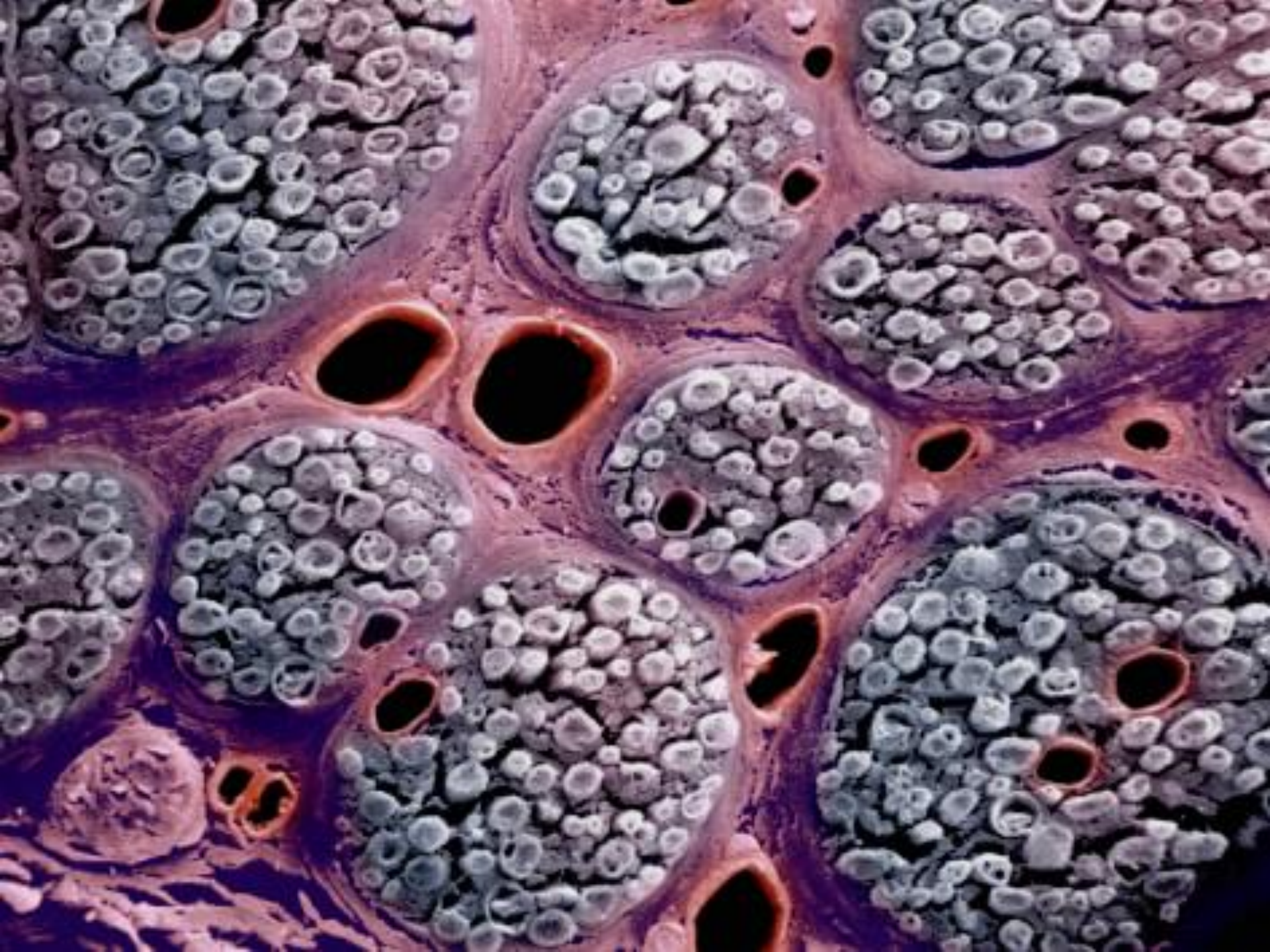

Glial Cells (Neuroglia)

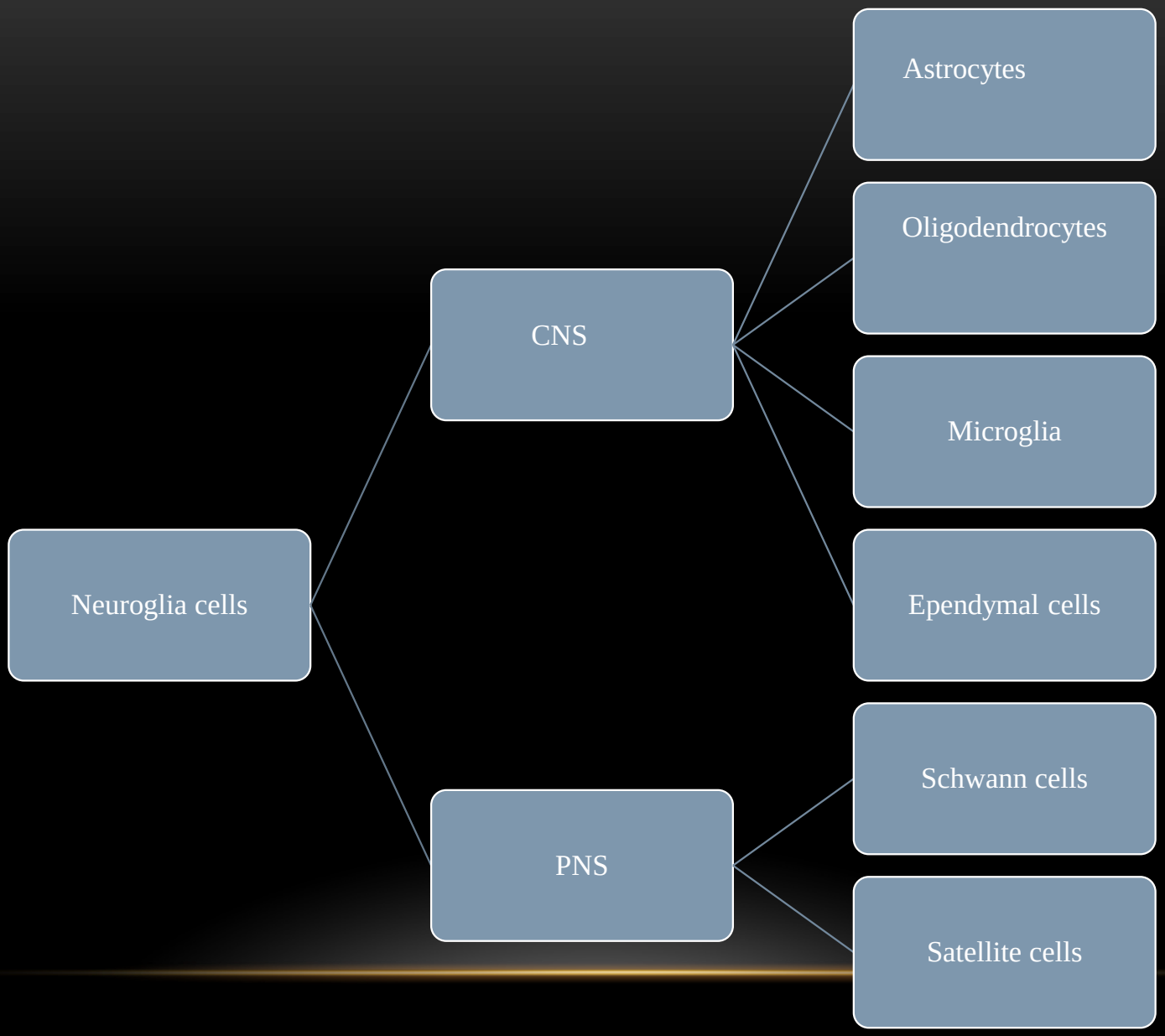
Neuroglia cells
CNS
PNS
Astrocytes
Oligodendrocytes
Microglia
Ependymal cells
Schwann cells
Satellite cells

Astrocytes 1/2

They are the most numerous cells in the grey matter.

They have a large number of radiating processes. They are of two types:

- ***Fibrous astrocytes*** with relatively few long, straight processes and are located in the white matter
- ***Protoplasmic astrocytes*,** with many short, branched processes, and are found in the gray matter.

Astrocytes have supportive roles for neurons and are very important for proper formation of the CNS during embryonic and fetal development.

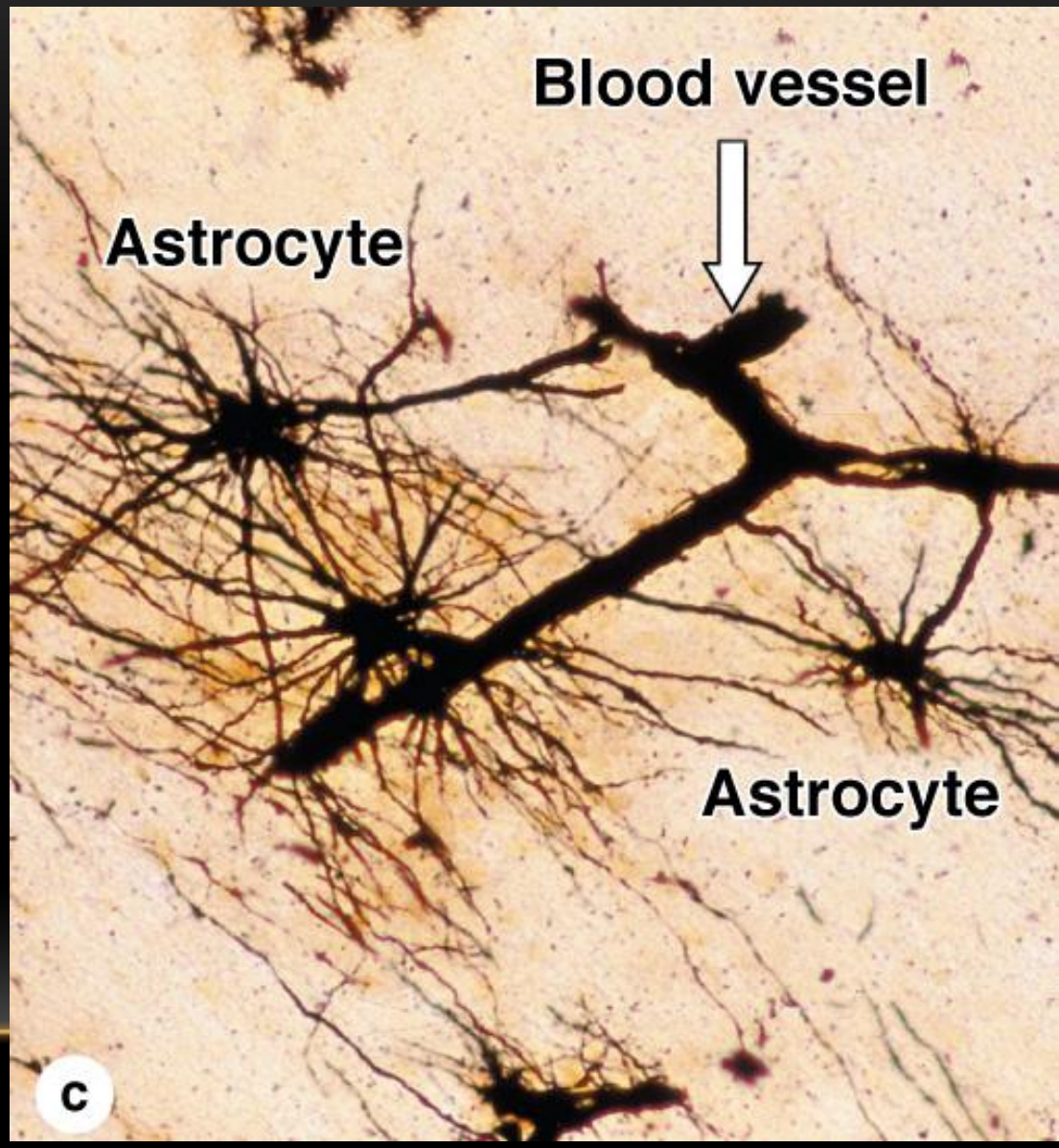

Astrocytes 2/2

They are essential for neuronal survival.

- They regulate constituents of the extracellular environment, absorb local excess of neurotransmitters, and secrete numerous metabolites and factors regulating neuronal activities.
- Astrocytes are in direct communication with one another via gap junctions, forming a network through which information can flow from one point to another, reaching distant sites.

The processes of all astrocytes are reinforced with bundles of intermediate filaments made of **glial fibrillary acid protein (GFAP)**, which serves as a unique marker for astrocytes, the most common source of brain tumors.

Oligodendrocyte

Produce the myelin sheath that provides the electrical insulation for neurons in the CNS.

They extend processes that wrap around parts of several axons, producing a myelin sheath.

They are the predominant glial cell in white matter. The processes are not visible by routine L.M staining, in which oligodendrocytes usually appear as small cells with rounded, condensed nuclei and unstained cytoplasm.

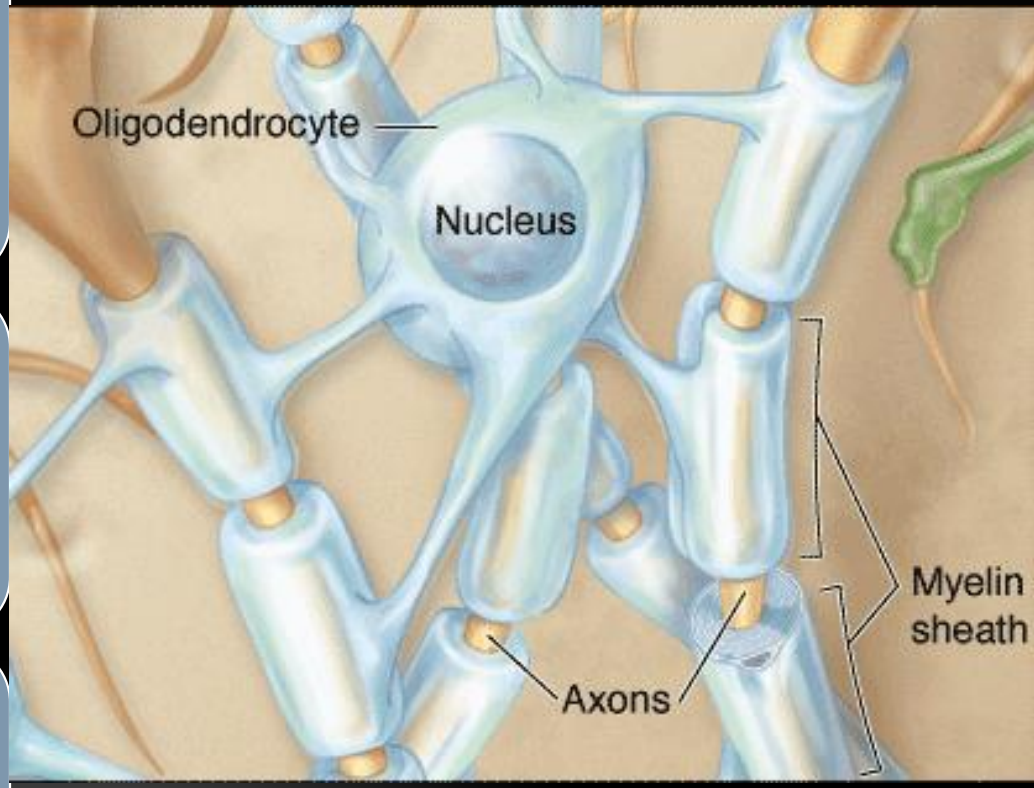

Myelin

Insulating layer around a nerve

Formed by oligodendrocytes in CNS and Schwann cells in PNS

Composed of a lipoprotein with phospholipids, glycolipids and cholesterol.

Microglia

Less numerous than oligodendrocytes or astrocytes but more evenly distributed throughout gray and white matter,

They are small cells with short irregular processes

They migrate through the neuropil, analyzing the tissue for damaged cells and invading microorganisms.

They secrete a number of immunoregulatory cytokines and constitute the major mechanism of immune defense in CNS tissues.

They originate from circulating blood monocytes, belonging to the same family as macrophages and other antigen-presenting cells.

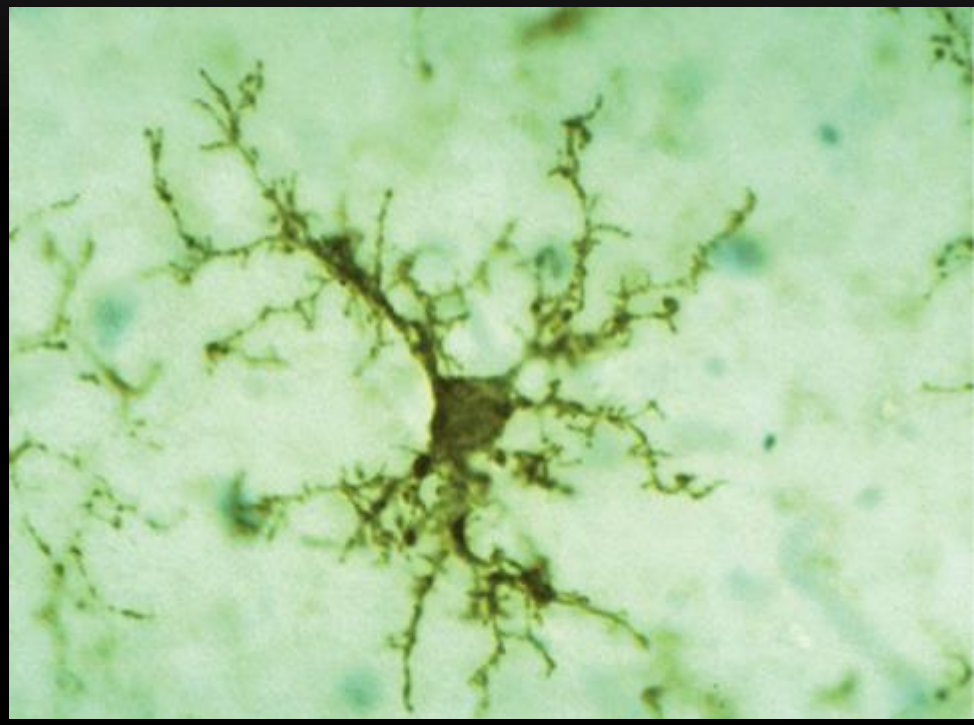

Ependymal cells

They are low columnar or cuboidal cells that line the ventricles of the brain and central canal of the spinal cord.

(In some CNS locations, the apical ends of ependymal cells have cilia, which facilitate the movement of cerebrospinal fluid (CSF), or long microvilli, which are likely involved in absorption.

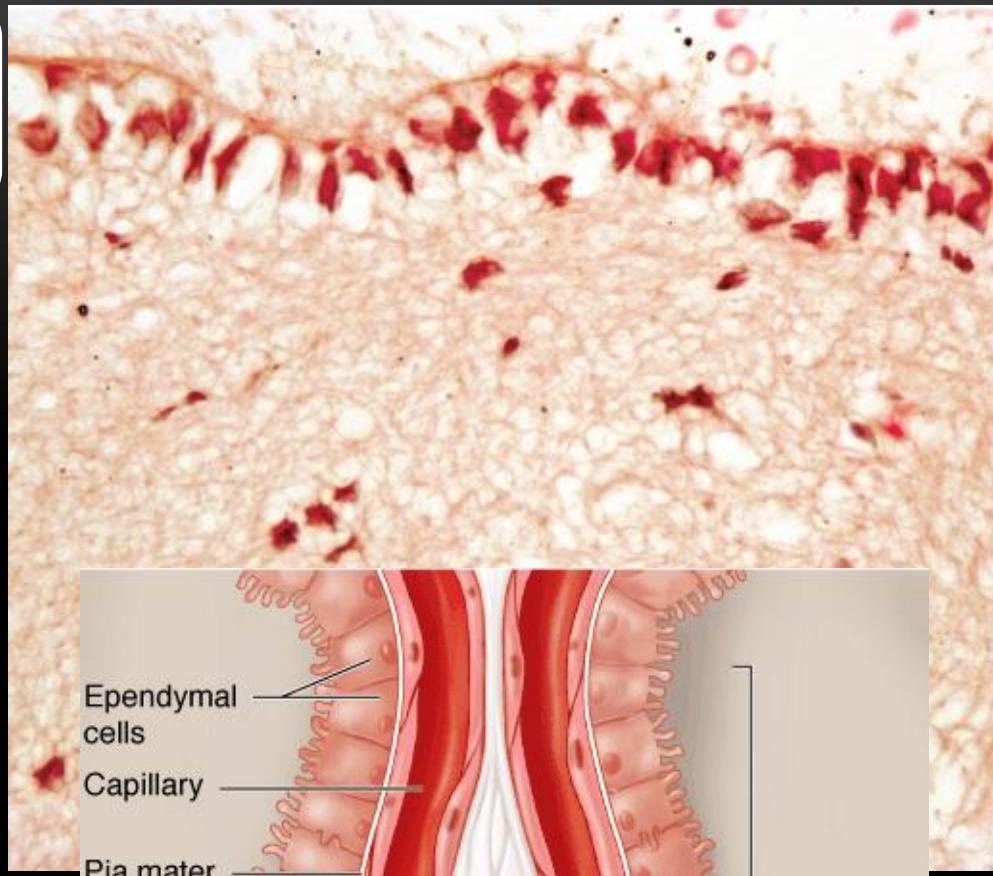

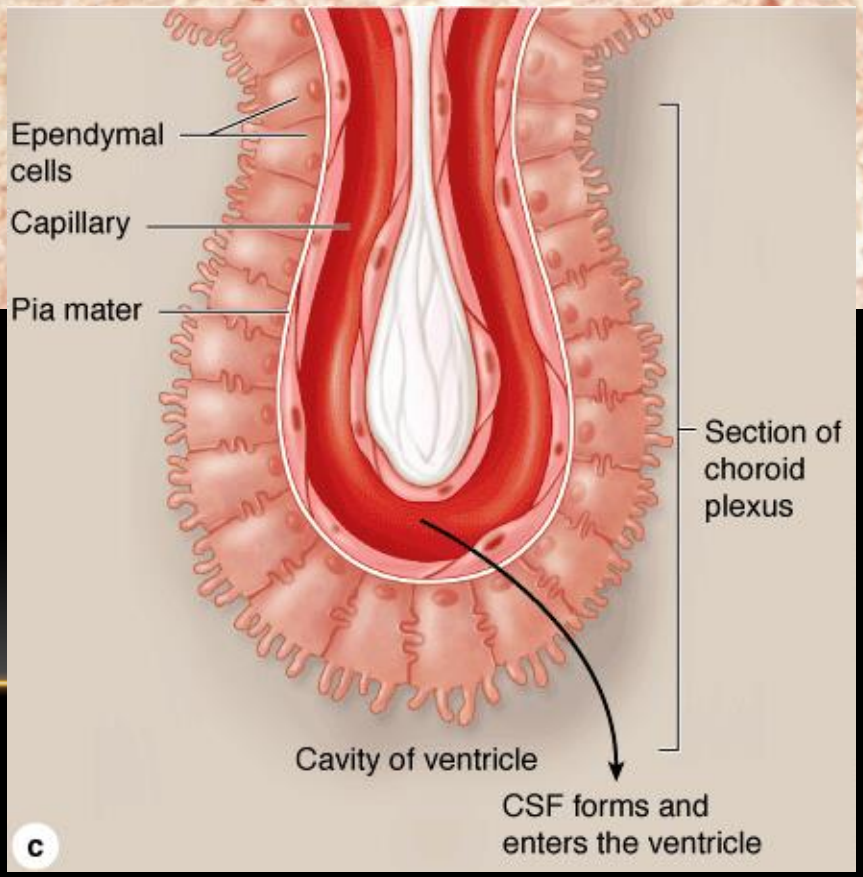

Schwann Cells (**Neurolemmocytes**)

Found only in the PNS and have trophic interactions with axons and allow for their myelination (compare with oligodendrocytes).

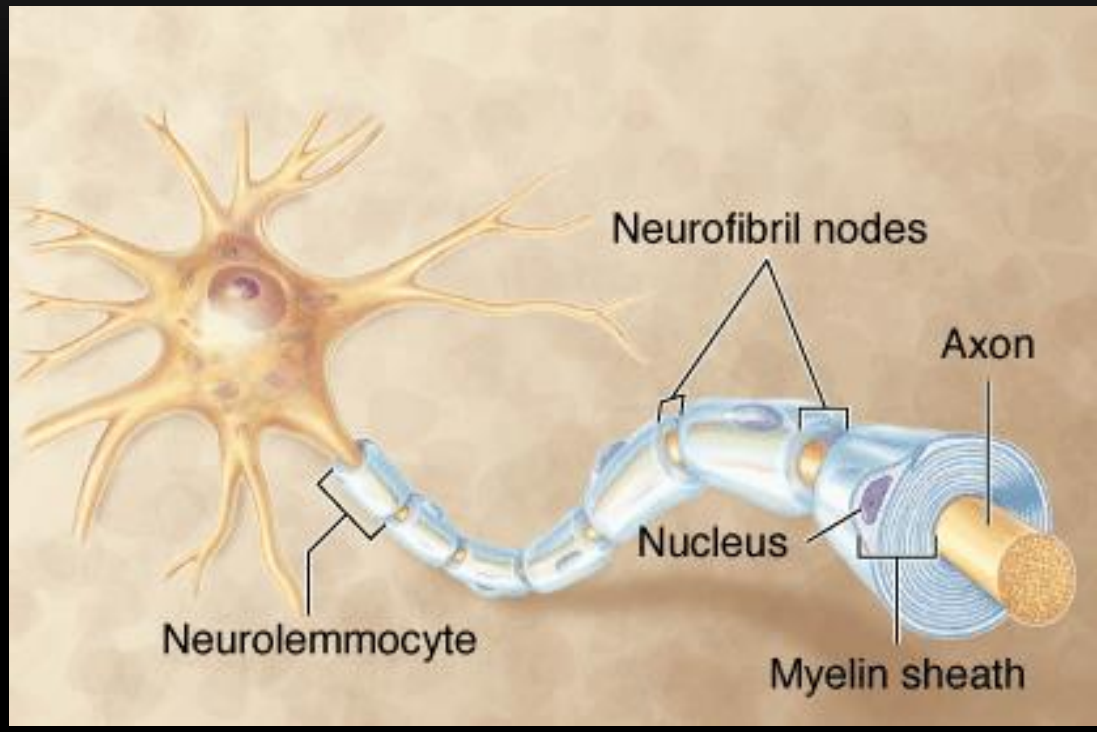

One Schwann cell forms myelin around a segment of one axon

Satellite cells

- Derived from the embryonic neural crest
- Form a covering layer over the large neuronal cell bodies in PNS ganglia.
- Closely associated with the neurons
- They exert a trophic or supportive role
- Other functions are poorly understood.

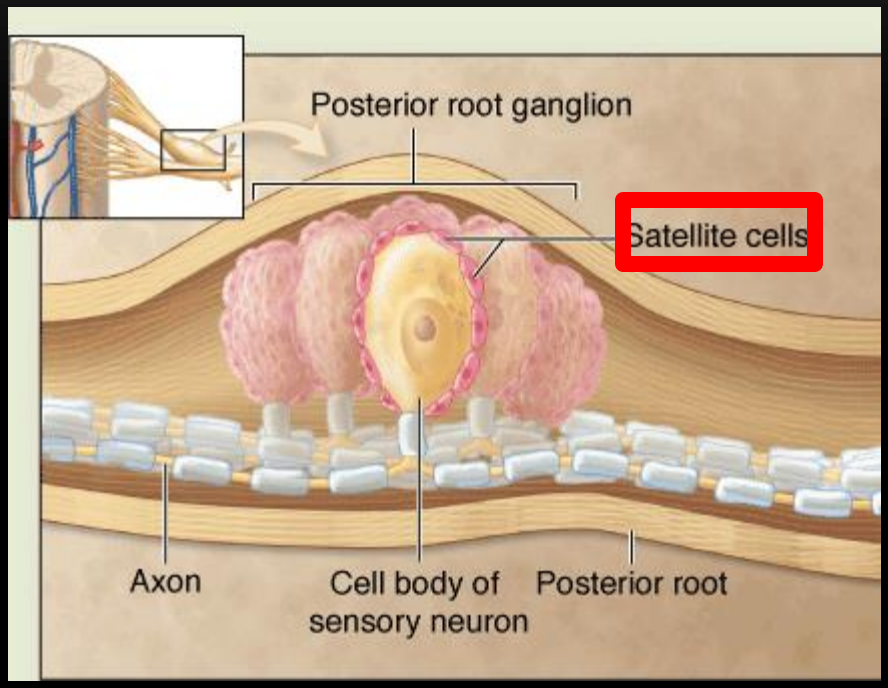

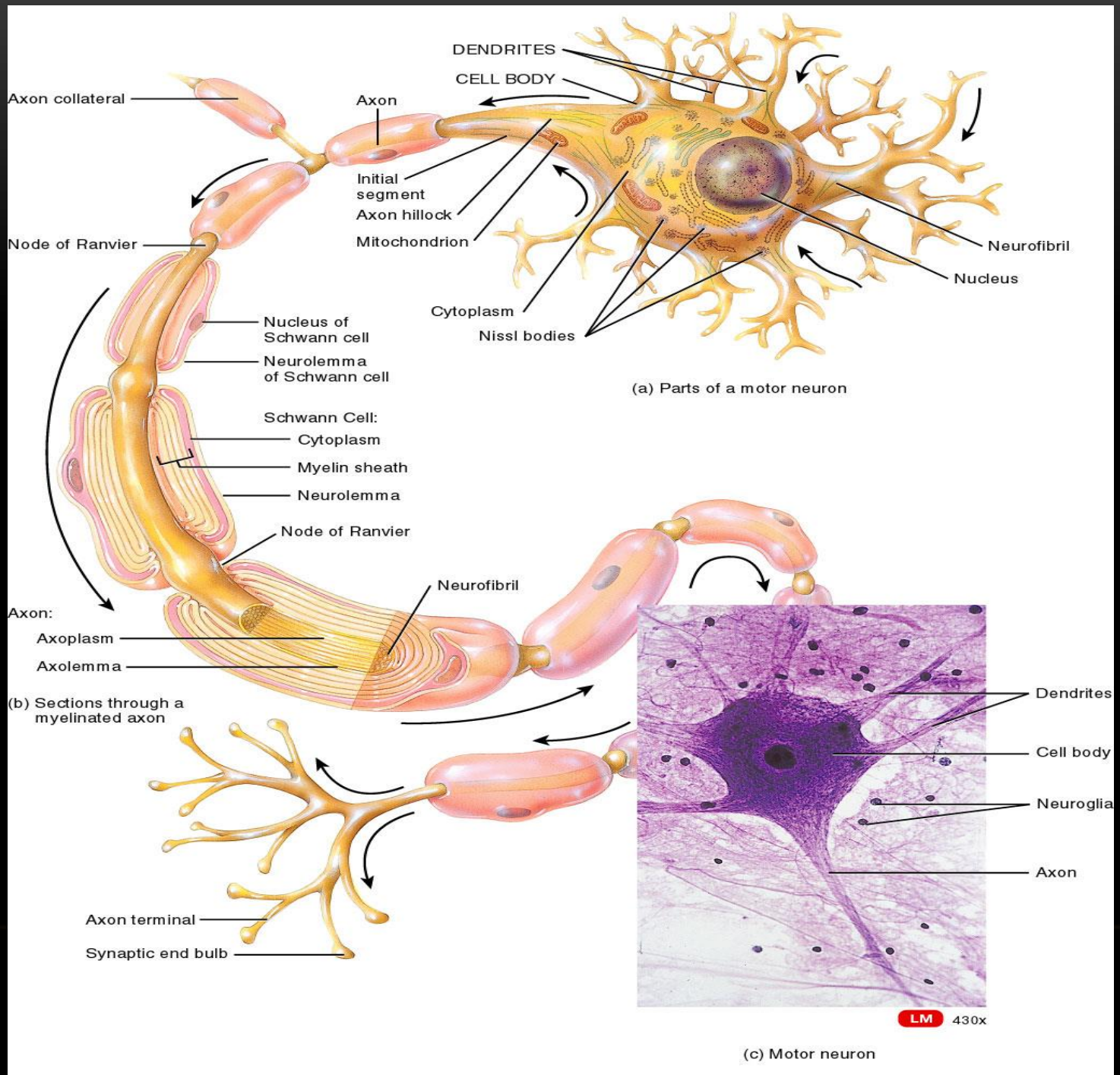
DENDRITES
CELL BODY
Axon collateral
Axon
Initial segment
Axon hillock
Mitochondrion
Neurofibril
Nucleus
Cytoplasm
Nissl bodies
(a) Parts of a motor neuron
Node of Ranvier
Nucleus of Schwann cell
Neurolemma of Schwann cell
Schwann Cell:
Cytoplasm
Myelin sheath
Neurolemma
Node of Ranvier
Neurofibril
Axon:
Axoplasm
Axolemma
(b) Sections through a myelinated axon
Axon terminal
Synaptic end bulb
Dendrites
Cell body
Neuroglia
Axon
LM 430x
(c) Motor neuron

Myelin and Unmyelinated fibers

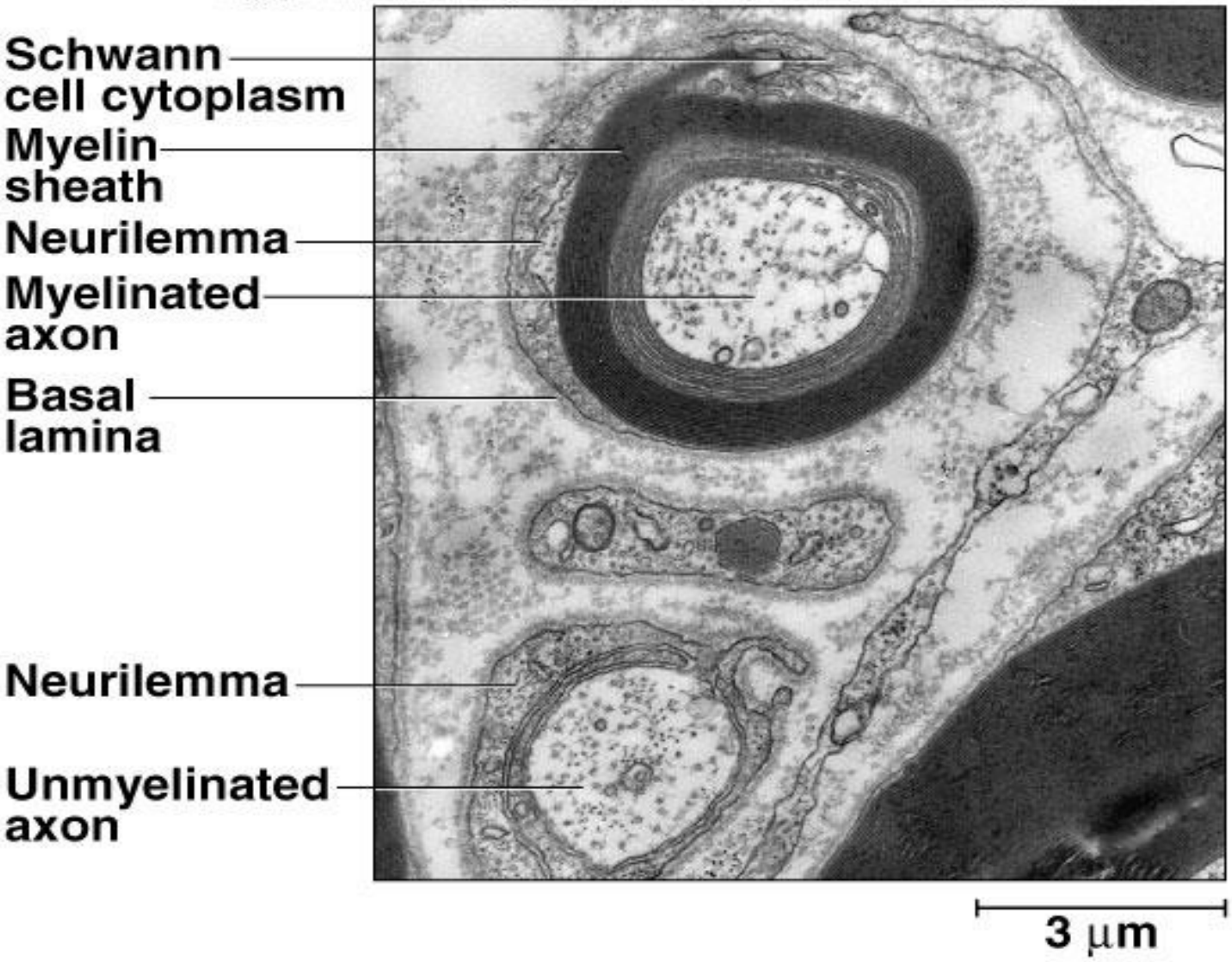

Synaptic ending

Synapse = site where two nerves communicate with each other.

Presynaptic neuron = neuron that is conducting information toward the next neuron

Postsynaptic neuron = transmits information away from synapse

Most synaptic communication is via chemical messengers (e.g. acetylcholine, serotonin, norepinephrine, dopamine, endorphins, GABA, glycine, glutamic acid, etc.)

Synaptic terminals

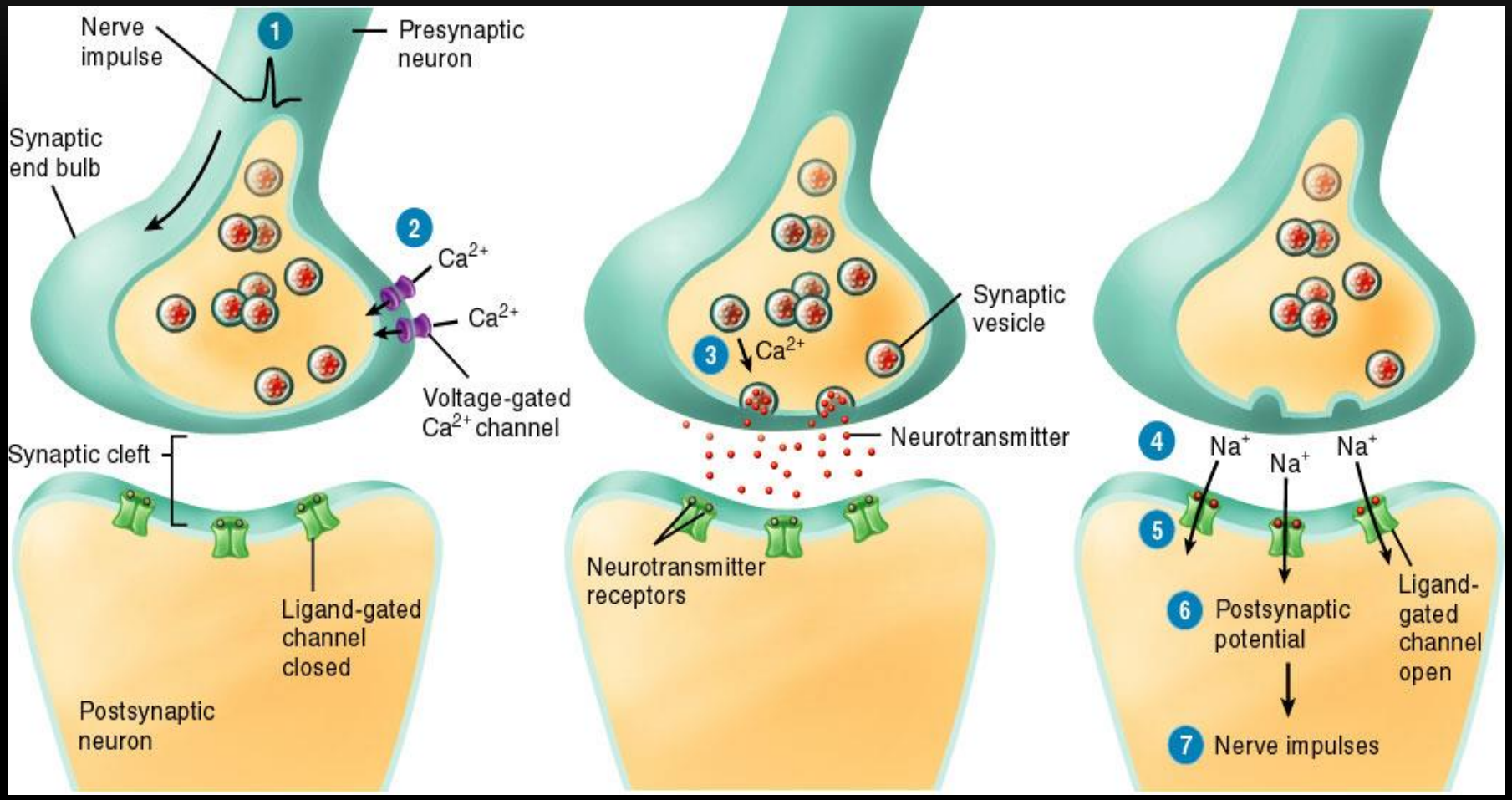

Types of synapses

- Axodendritic = axon to dendrite
- Axosomatic = axon to cell body
- Axoaxonic = axon to axon
- Dendrodendritic = dendrite to dendrite
- Dendrosomatic = dendrite to cell body

MENINGES

Lie between the bone and nervous tissue.

Formed of:

- Dura mater
- Arachnoid
- Pia mater

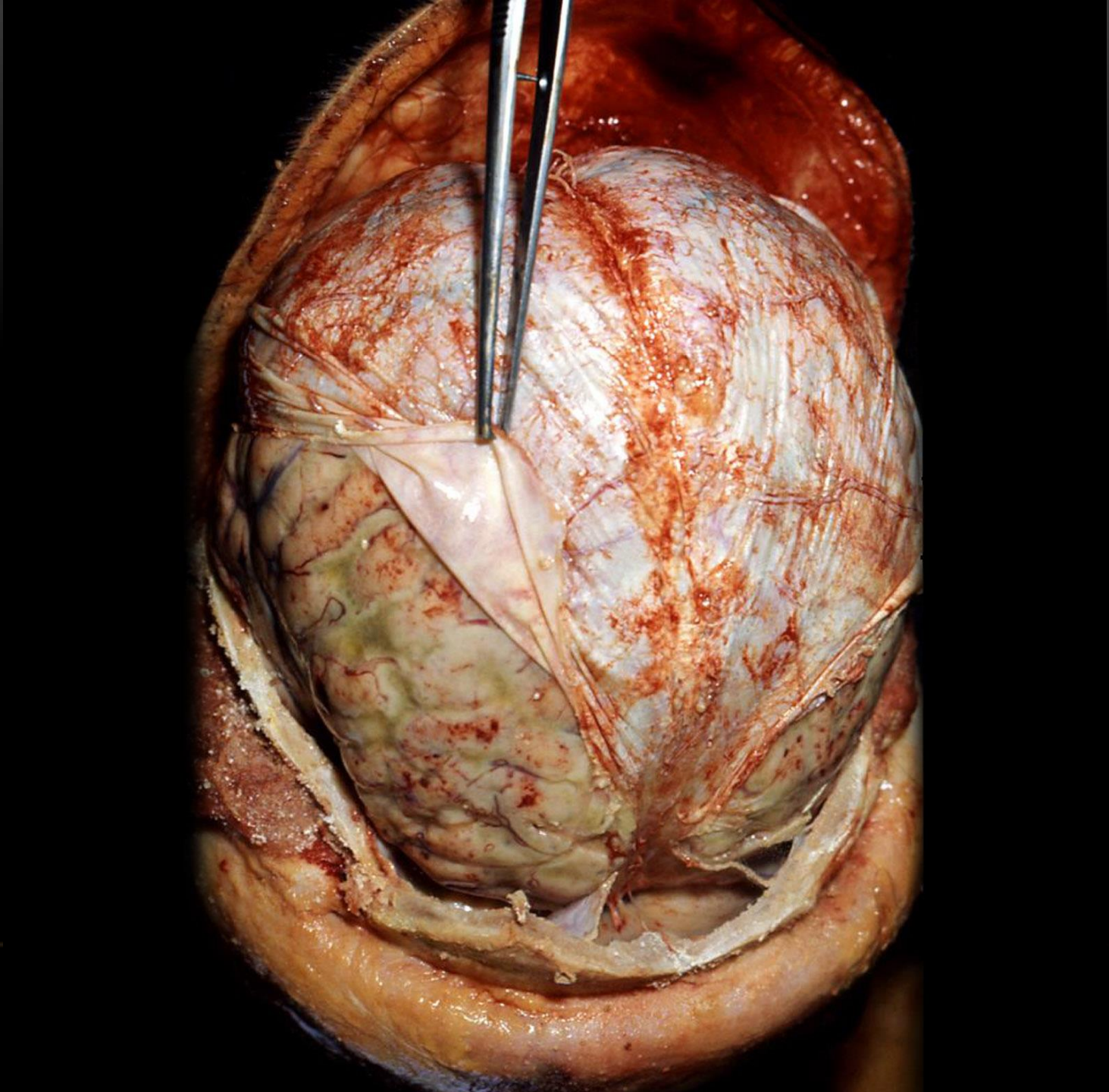

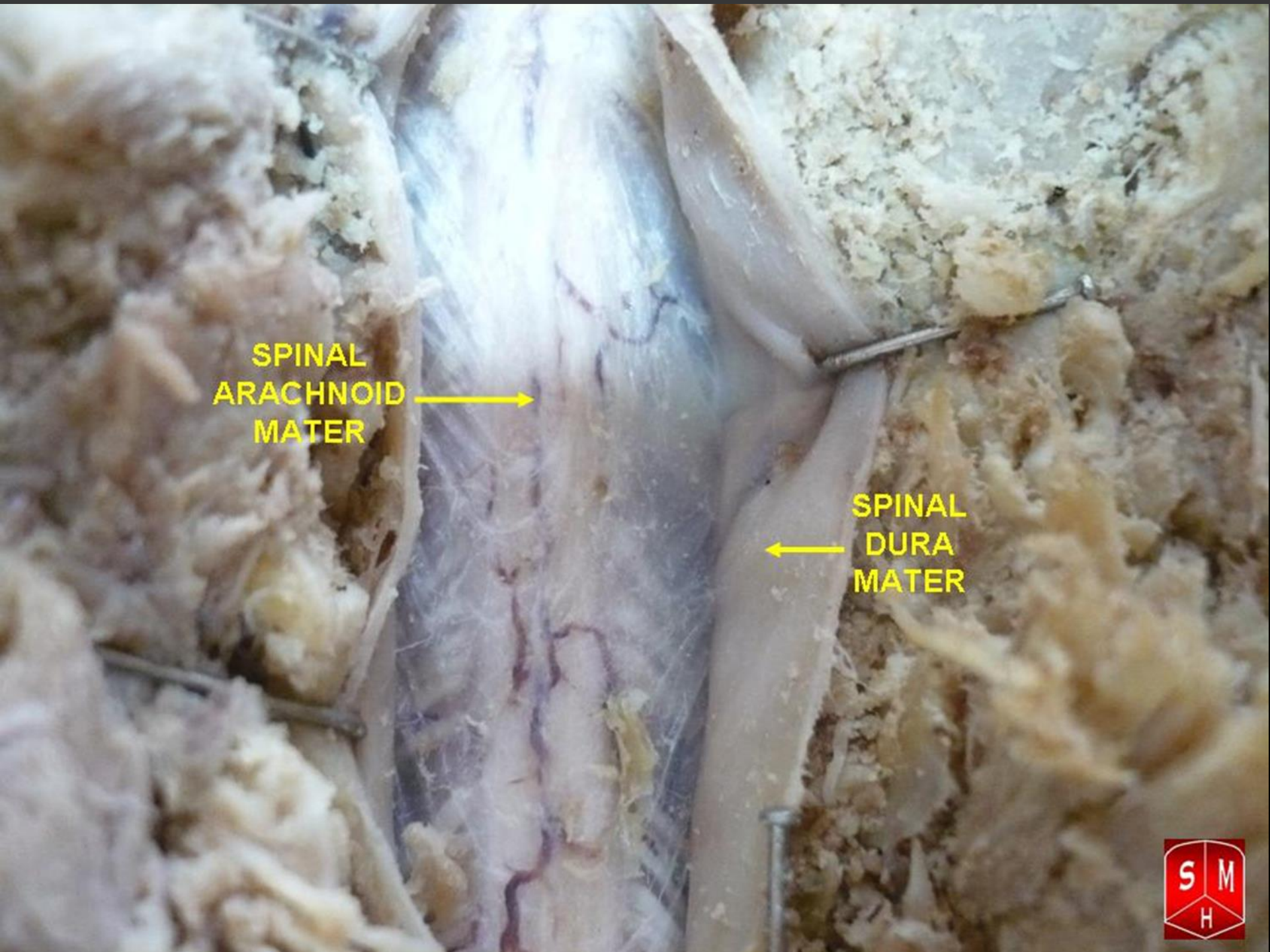
SPINAL
ARACHNOID
MATER
SPINAL
DURA
MATER
S
M
H

It is the thick external layer consisting of dense, fibroelastic connective tissue continuous with the periosteum of the skull.

Around the spinal cord the dura mater is separated from the periosteum of the vertebrae by the **epidural space**, which contains a plexus of thin-walled veins and areolar connective tissue.

It is always separated from the arachnoid by the thin **subdural space**.

The internal surface of all dura mater, as well as its external surface in the spinal cord, is covered by simple squamous epithelium.

Arachnoid 1/3

The arachnoid has two components:

- (1) a sheet of connective tissue in contact with the dura mater and
- (2) a system of loosely arranged trabeculae containing fibroblasts and collagen.
  - This trabecular system is continuous with the deeper pia mater.
  - Surrounding the trabeculae is a large, sponge-like cavity, the **subarachnoid space,** filled with CSF. This space forms a hydraulic cushion that protects the CNS from trauma.
  - The subarachnoid space communicates with the ventricles of the brain.

Arachnoid 2/3

The connective tissue of the arachnoid is said to be avascular because it lacks nutritive capillaries, but larger blood vessels run through it.

The arachnoid has fewer trabeculae in the spinal cord, and it can be more clearly distinguished from the pia mater in that area.

The arachnoid and the pia mater are intimately associated and are often considered a single membrane called the **pia-arachnoid.**

Arachnoid 3/3

In some areas, the arachnoid perforates the dura mater and protrudes into blood-filled venous sinuses within the dura mater.

These CSF-filled protrusions, which are covered by vascular endothelial cells, are called **arachnoid villi.**

- They transport CSF from the subarachnoid space into venous sinuses.

Pia mater 1/2

The innermost pia mater is lined internally by flattened, mesenchymally derived cells closely applied to the entire surface of the CNS tissue, but this layer does not directly contact nerve cells or fibers.

Between the pia mater and the neural elements is a thin limiting layer of astrocytic processes, which adheres firmly to the pia mater.

Together the pia mater and glial layer form a physical barrier at the CNS periphery. This barrier separates the CNS tissue from the CSF in the subarachnoid space.

Pia mater 2/2

Blood vessels penetrate the CNS through tunnels covered by pia mater: the **perivascular spaces.**

The pia mater disappears when the blood vessels branch to the smallest capillaries, instead, capillaries remain completely covered by expanded perivascular processes of astrocytes.

Neuronal Plasticity and Regeneration..1/3

Despite its general stability, the nervous system exhibits plasticity even in adults.

Plasticity is very high during embryonic development, when an excess of nerve cells is formed, and the cells that do not establish correct synapses with other neurons are eliminated by apoptosis.

In adult mammals after an injury, the neuronal circuits may be reorganized by the growth of neuronal processes, forming new synapses to replace the ones lost by injury

N**eural plasticity** and reformation of processes are controlled by several growth factors produced by both neurons and glial cells in a family of growth factors called **neurotrophins.**

Neuronal Plasticity and Regeneration..2/3

Neuronal stem cells are present in adult CNS, located in part among the cells of the ependyma, which can supply new neurons, astrocytes and oligodendrocytes.

Neurons cannot divide to replace those lost by injury or disease,

the potential of neural stem cells to allow regeneration of CNS components is a subject of intense investigation.

Neuronal Plasticity and Regeneration..3/3

Injured fibers in peripheral nerves have a capacity for regeneration and return of function.

In a wounded nerve fiber, it is important to distinguish changes occurring proximal to the injury from those in the distal segment.

The proximal segment maintains its continuity with the trophic center in the perikaryon and can regenerate, while the distal segment, separated from the nerve cell body, degenerates.

The onset of regeneration is accompanied by:

- C**hromatolysis** or dissolution of the RER and a consequent decrease in cytoplasmic basophilia;
- Swelling of the perikaryon;
- Migration of the nucleus to a peripheral position in the perikaryon.
- The proximal segment of the axon degenerates close to the wound for a short distance, but growth starts as soon as debris is removed by macrophages.
- Macrophages produce cytokines which stimulate Schwann cells to secrete neurotrophins.

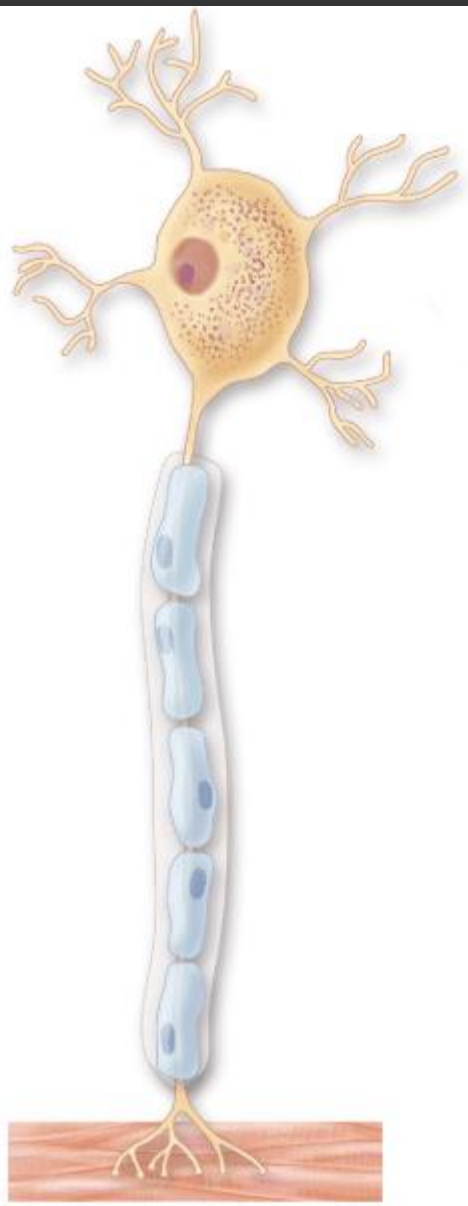

a

Source: Mescher AL: *Junqueira's Basic Histology: Text and Atlas, 12th Edition:* http://www.accessmedicine.com

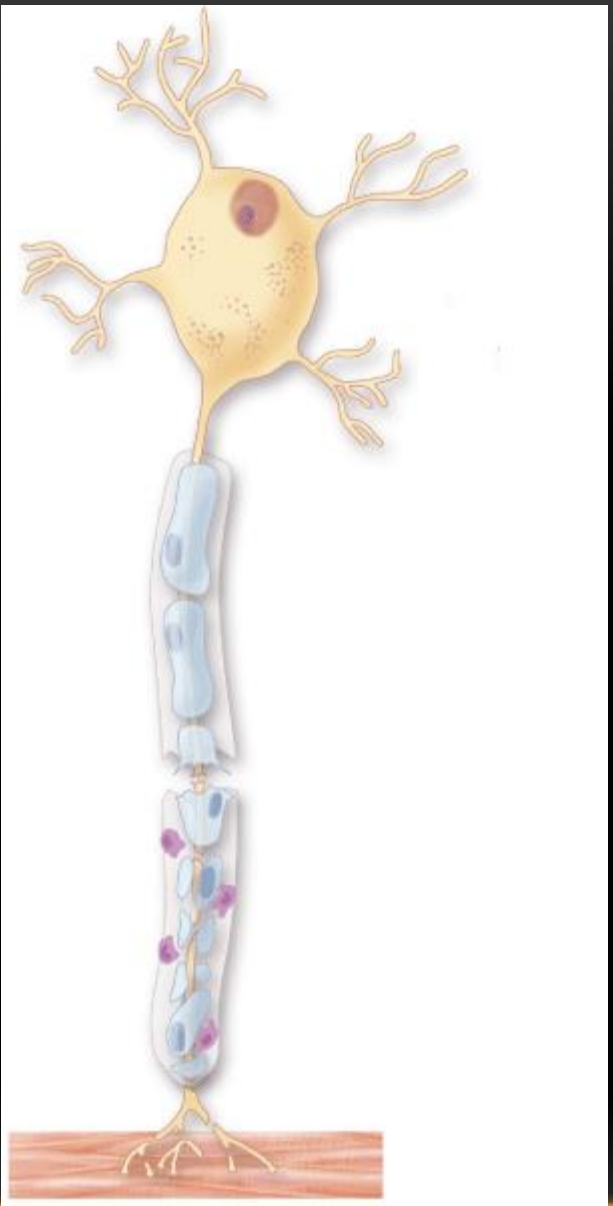

b 2 weeks

Source: Mescher AL: *Junqueira's Basic Histology: Text and Atlas, 12th Edition:* http://www.accessmedicine.com

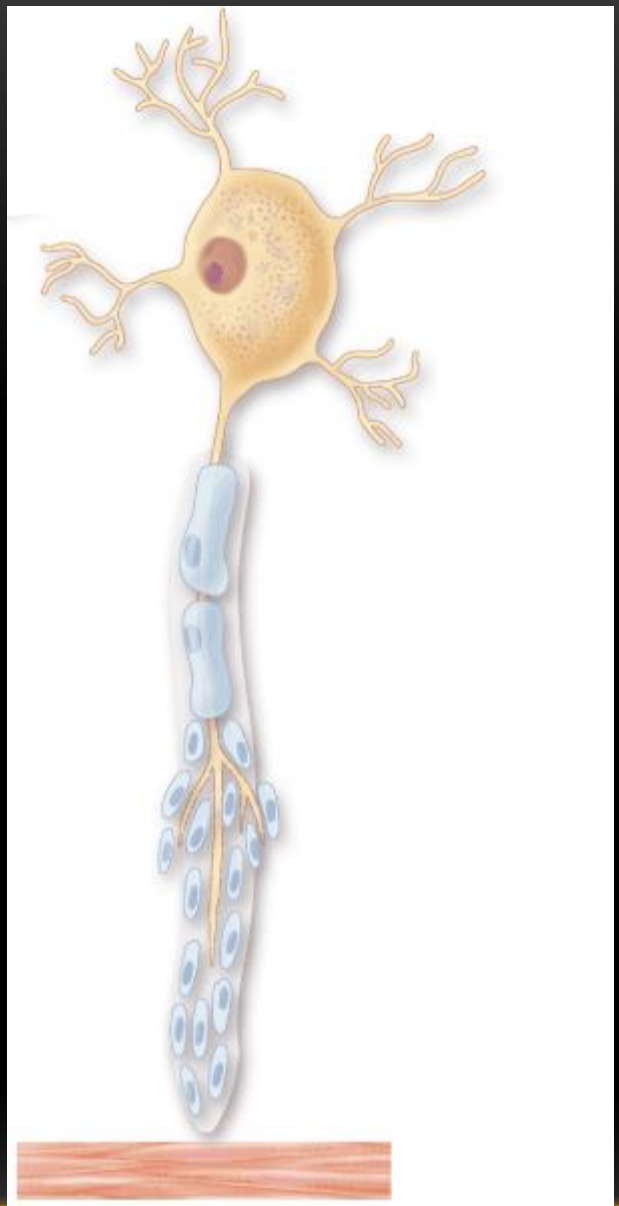

c 3 weeks

Source: Mescher AL: *Junqueira's Basic Histology: Text and Atlas, 12th Edition:* http://www.accessmedicine.com

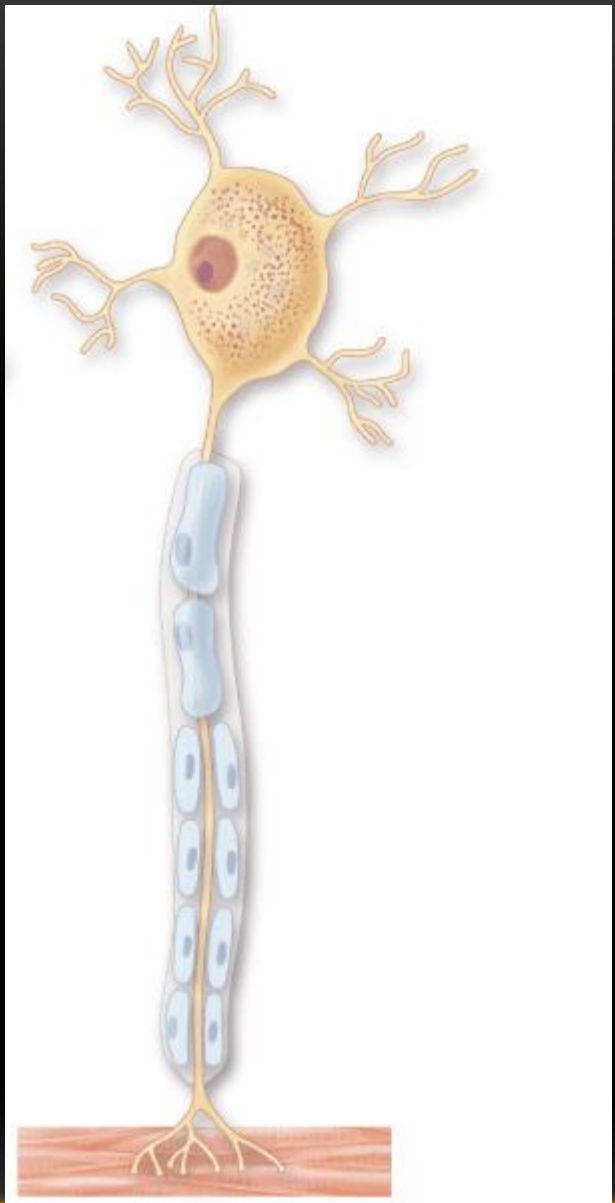

d 3 months

Source: Mescher AL: *Junqueira's Basic Histology: Text and Atlas, 12th Edition:* http://www.accessmedicine.com

Types of Glial Cells

Type	Location	Functions
Oligodendrocytes	CNS	Form myelin in brain and spinal cord
Astrocytes	CNS	Cover brain surface and nonsynaptic regions of neurons; stimulate formation of blood-brain barrier; remove neurotransmitters and K^+ from extracellular fluid (ECF) of brain and spinal cord; help to regulate composition of ECF; form supportive framework in CNS; form scar tissue to replace damaged nervous tissue
Ependymal cells	CNS	Line cavities of brain and spinal cord; secrete and circulate cerebrospinal fluid
Microglia	CNS	Phagocytize and destroy microorganisms, foreign matter, and dead nervous tissue
Schwann cells	PNS	Form neurilemma around all PNS nerve fibers and myelin around most of them; aid in regeneration of damaged nerve fibers
Satellite cells	PNS	Surround somas of neurons in the ganglia; function uncertain