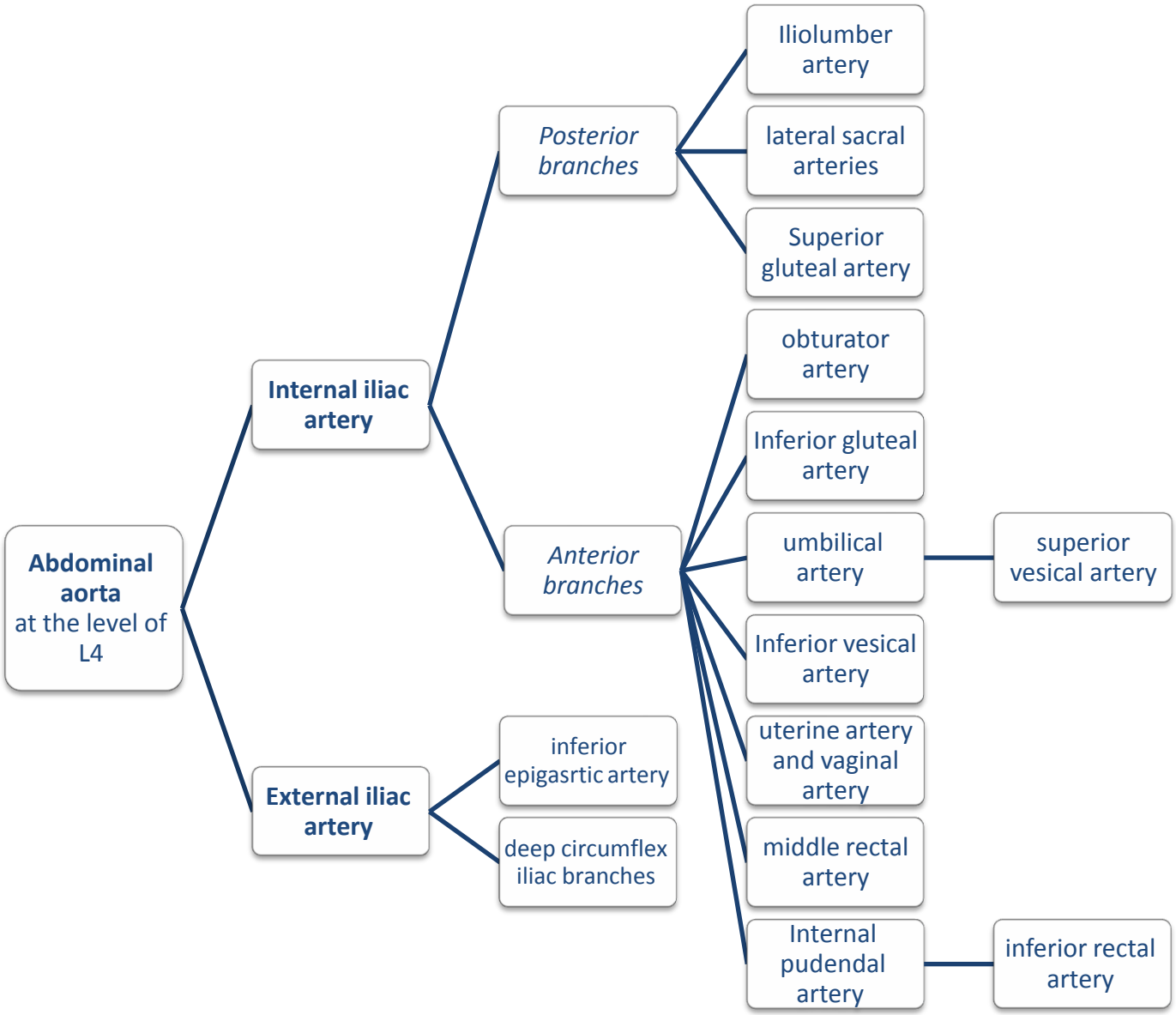
Abdominal aorta
at the level of L4
Internal iliac artery
External iliac artery
Posterior branches
Anterior branches
Iliolumber artery
lateral sacral arteries
Superior gluteal artery
obturator artery
Inferior gluteal artery
umbilical artery
superior vesical artery
Inferior vesical artery
uterine artery and vaginal artery
middle rectal artery
Internal pudendal artery
inferior rectal artery
inferior epigasrtic artery
deep circumflex iliac branches

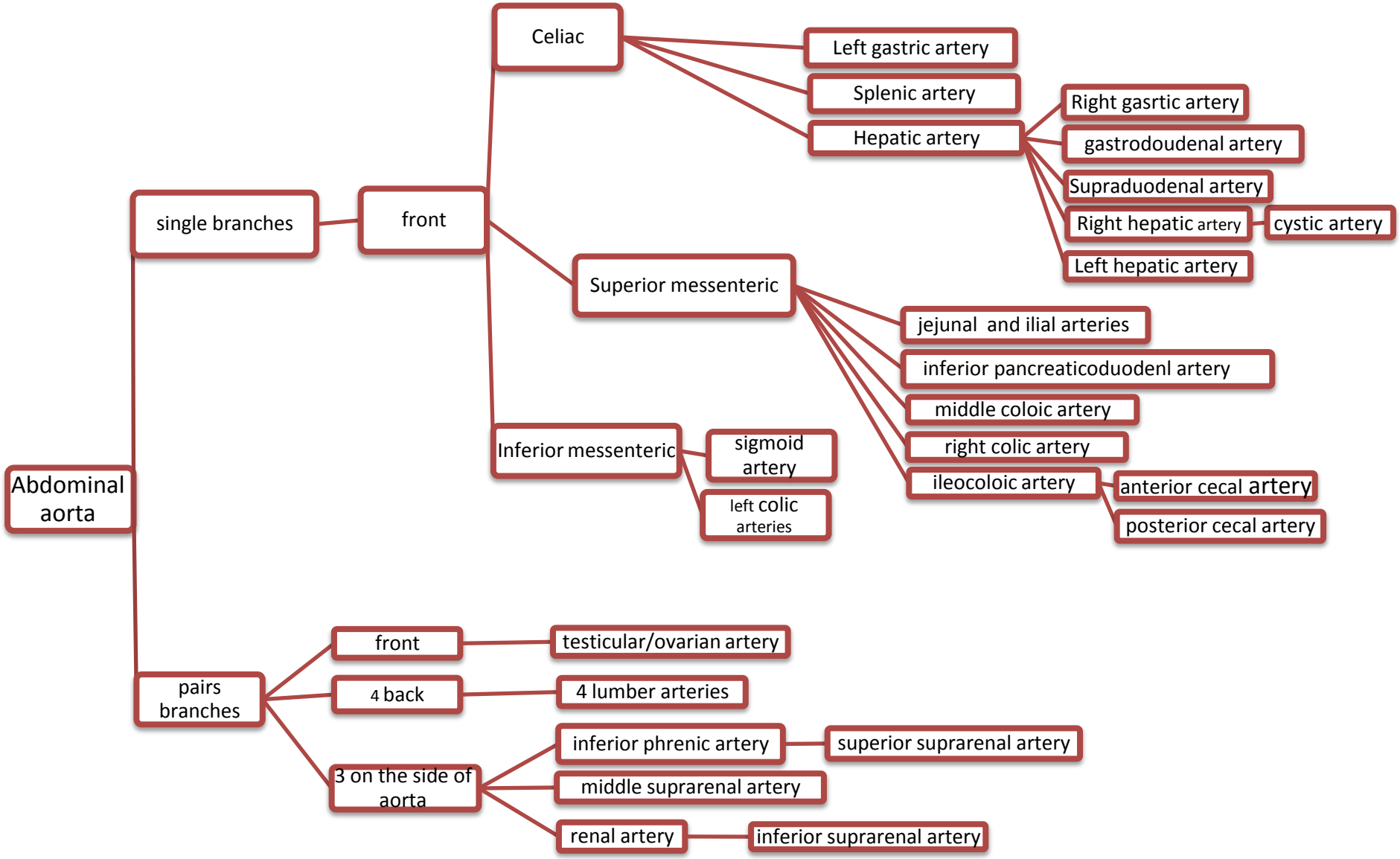
Abdominal aorta
single branches
front
Celiac
Left gastric artery
Splenic artery
Hepatic artery
Right gasrtic artery
gastrodoudenal artery
Supraduodenal artery
Right hepatic artery
cystic artery
Left hepatic artery
Superior messenteric
jejunal and ilial arteries
inferior pancreaticoduodenl artery
middle coloic artery
right colic artery
ileocoloic artery
anterior cecal artery
posterior cecal artery
Inferior messenteric
sigmoid artery
left colic arteries
pairs branches
front
testicular/ovarian artery
4 back
4 lumber arteries
3 on the side of aorta
inferior phrenic artery
superior suprarenal artery
middle suprarenal artery
renal artery
inferior suprarenal artery