Corticonuclear Projections and Innervation of the Oral Cavity

Face Area of Somatomotor Cortex and Frontal Eye Field

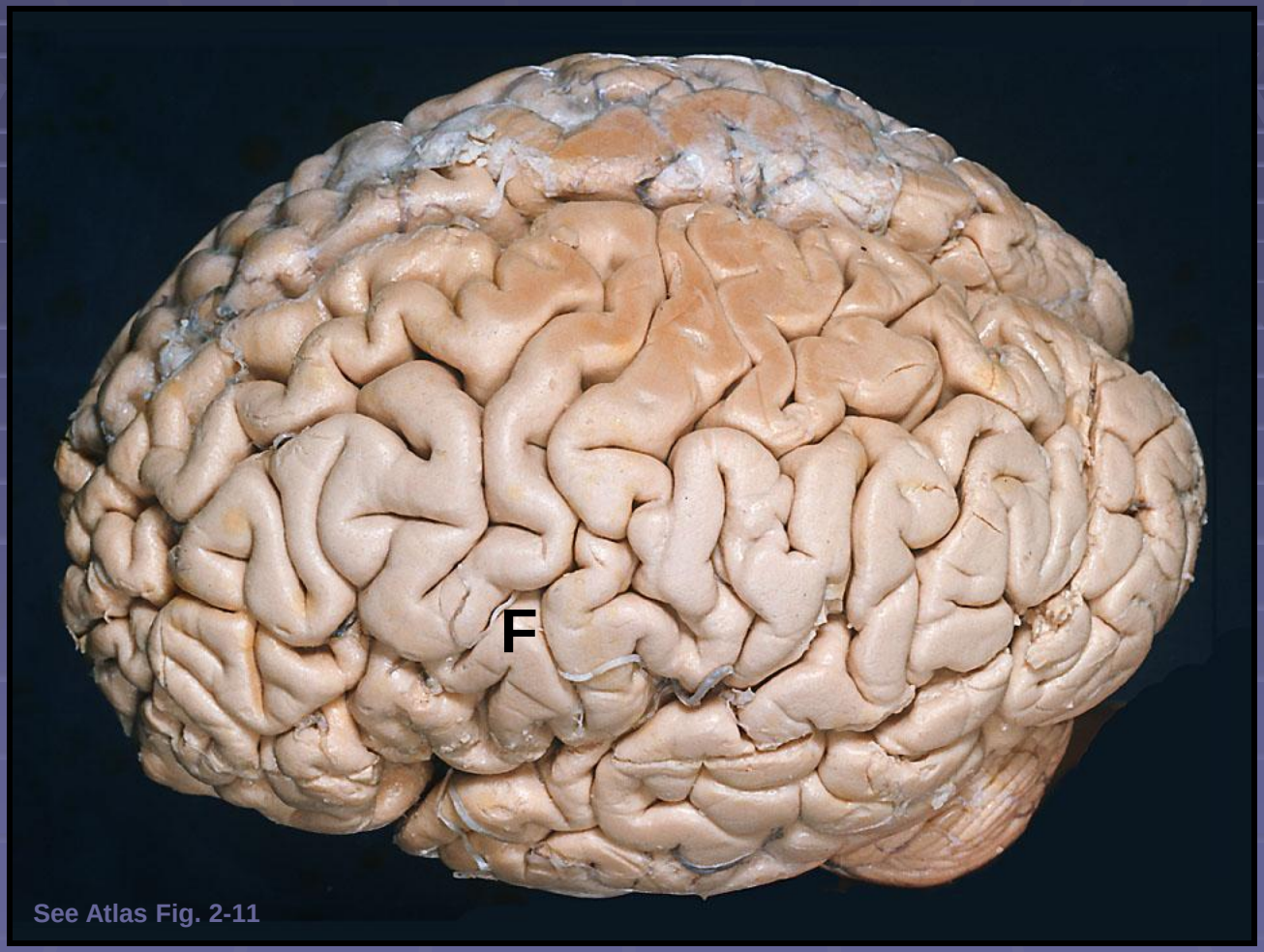

Corticonuclear Fibers

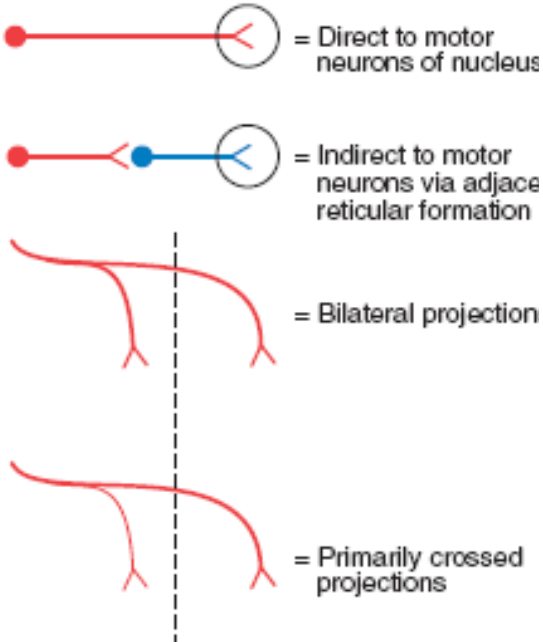

Motor cortex, precentral gyrus

Frontal eye field

Genu of IC

riMLF

OcNu

TroNu

Bilateral for upper face

TriMoNu *

PPRF

AbdNu

FacNu *

Crossed for lower face

NuAm *

Crossed for uvula (soft palate) *

Crossed for genioglossus muscle *

HyNu

AccNu *

Internal Capsule in MRI

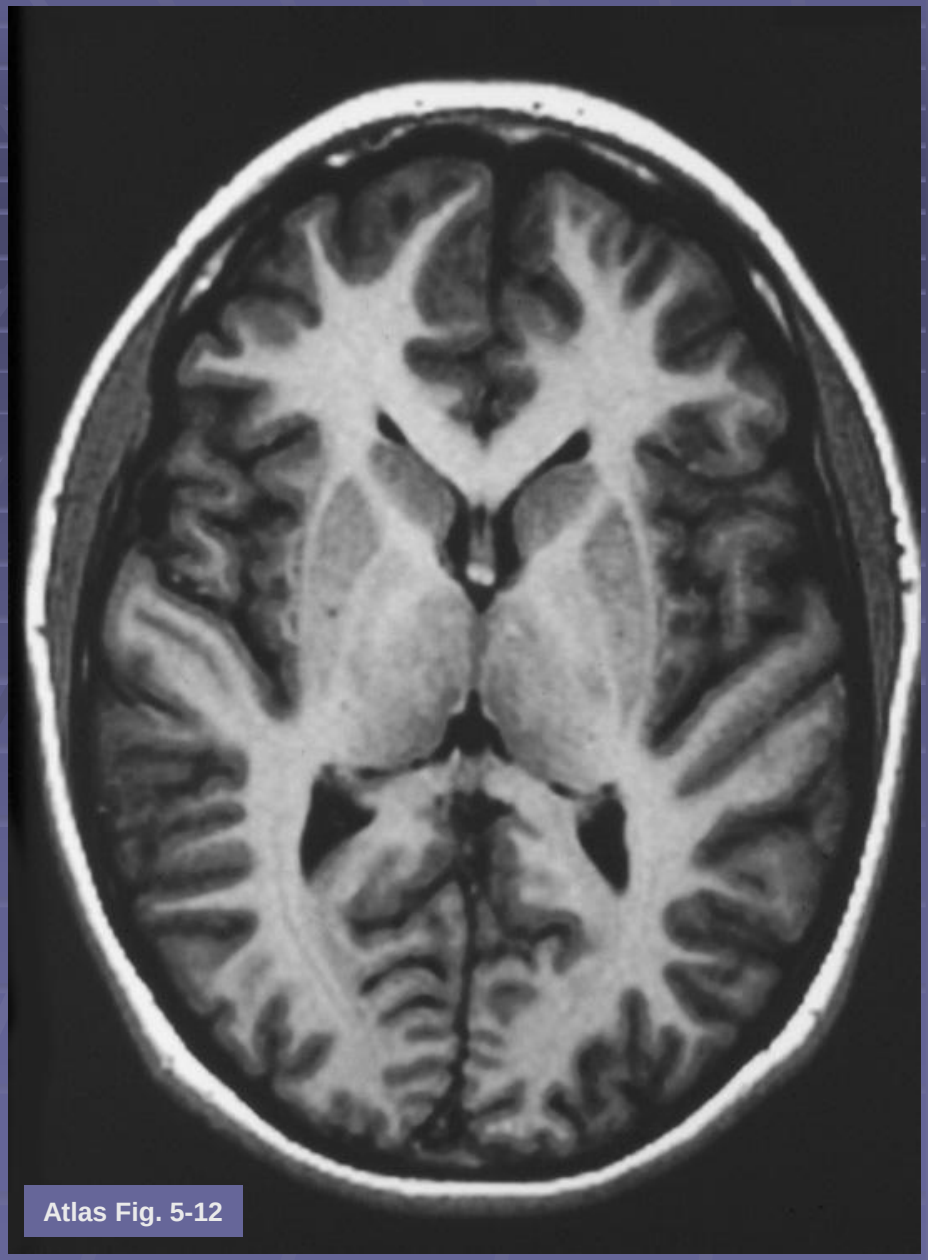

Atlas Fig. 5-12

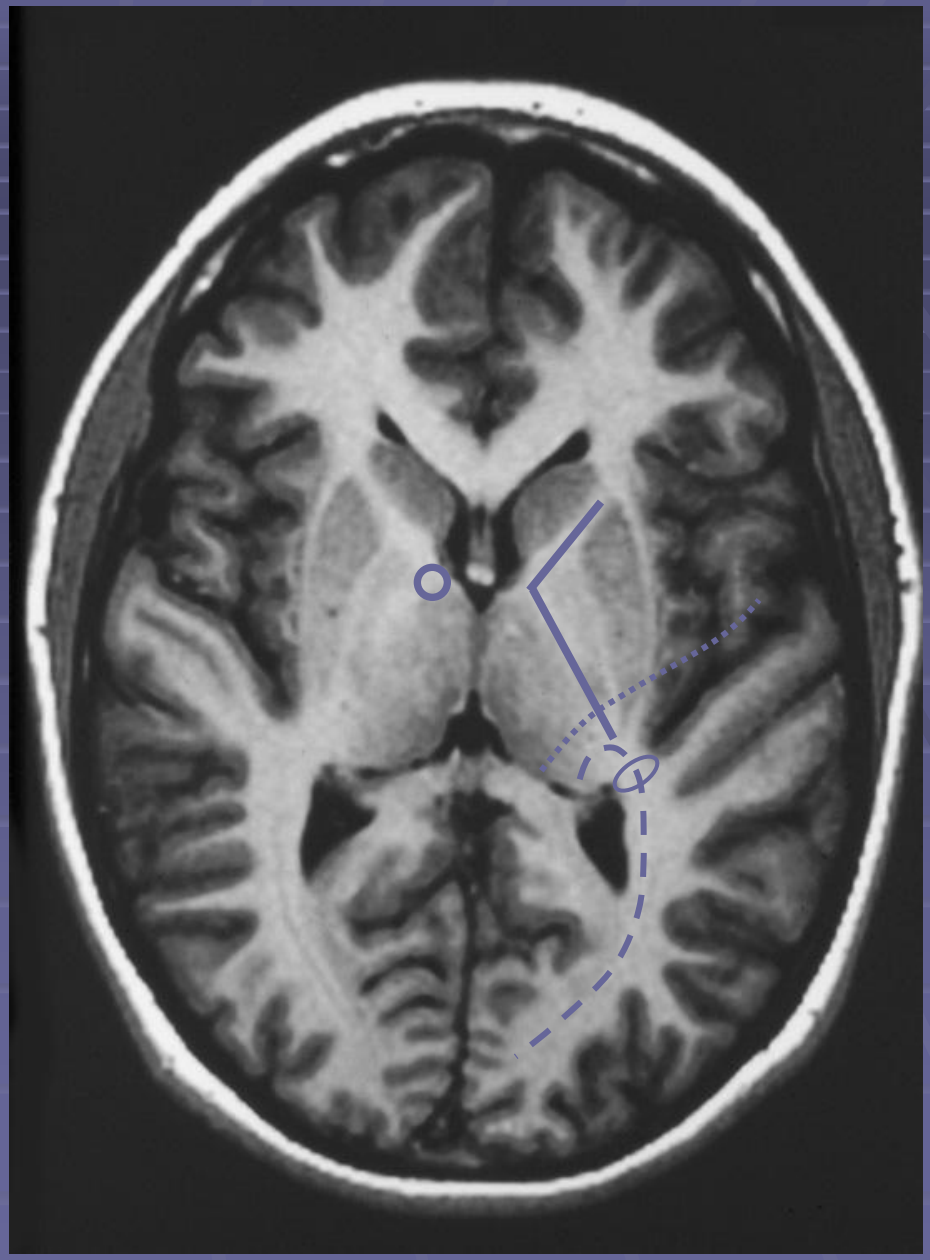

Corticonuclear Fibers

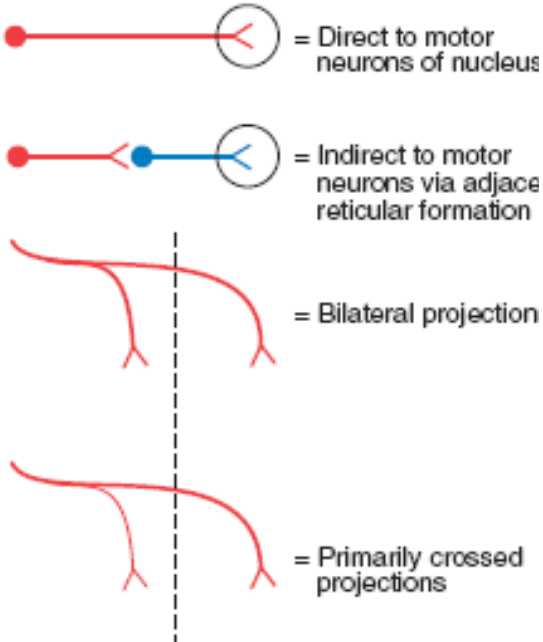

Motor cortex, precentral gyrus

Frontal eye field

Genu of IC

riMLF

OcNu

TroNu

Bilateral for upper face

TriMoNu *

PPRF

AbdNu

FacNu *

Crossed for lower face

NuAm *

Crossed for uvula (soft palate) *

Crossed for genioglossus muscle *

HyNu

AccNu *

Corticonuclear Fibers in the Crus Cerebri

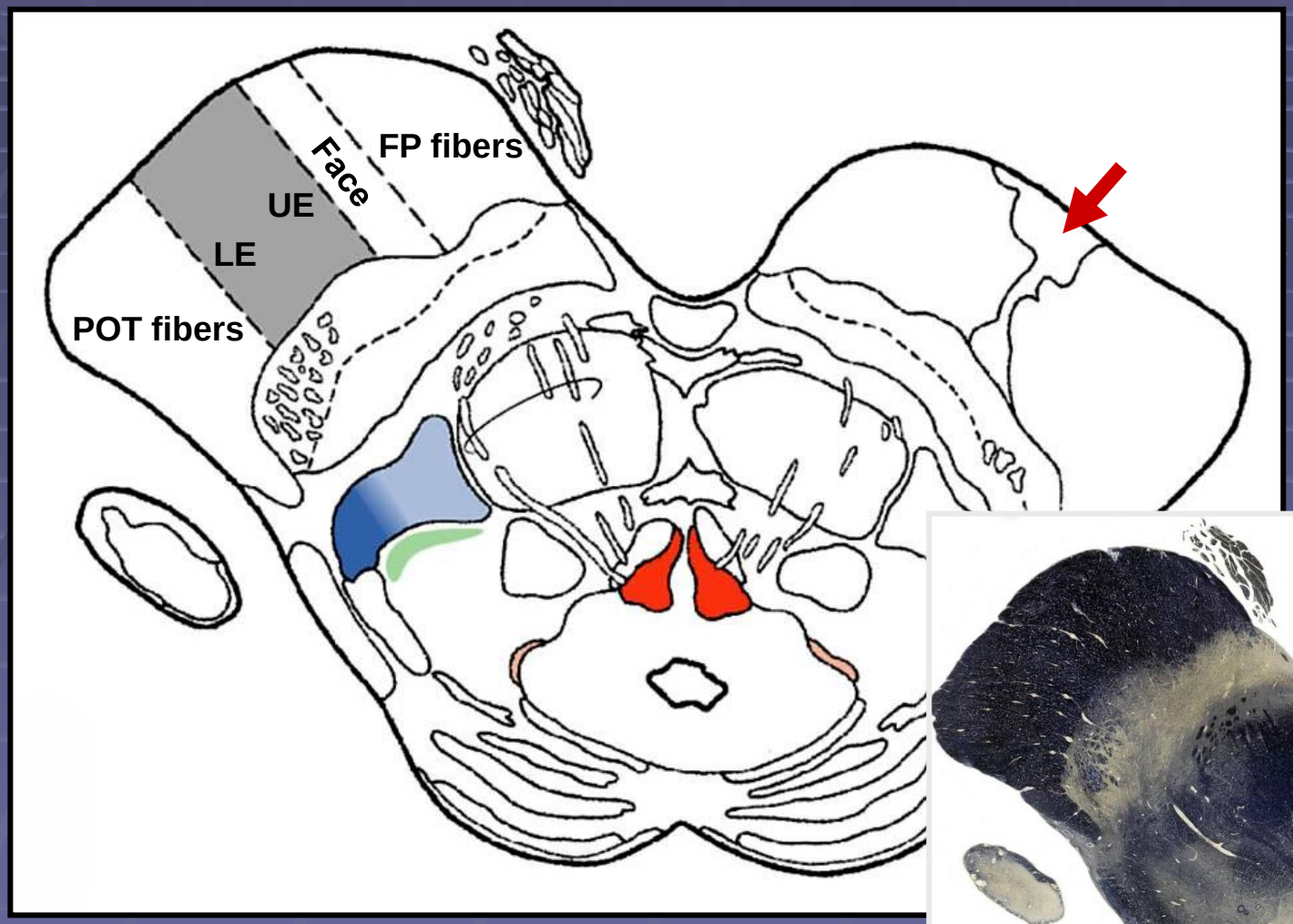

Trigeminal Pathways

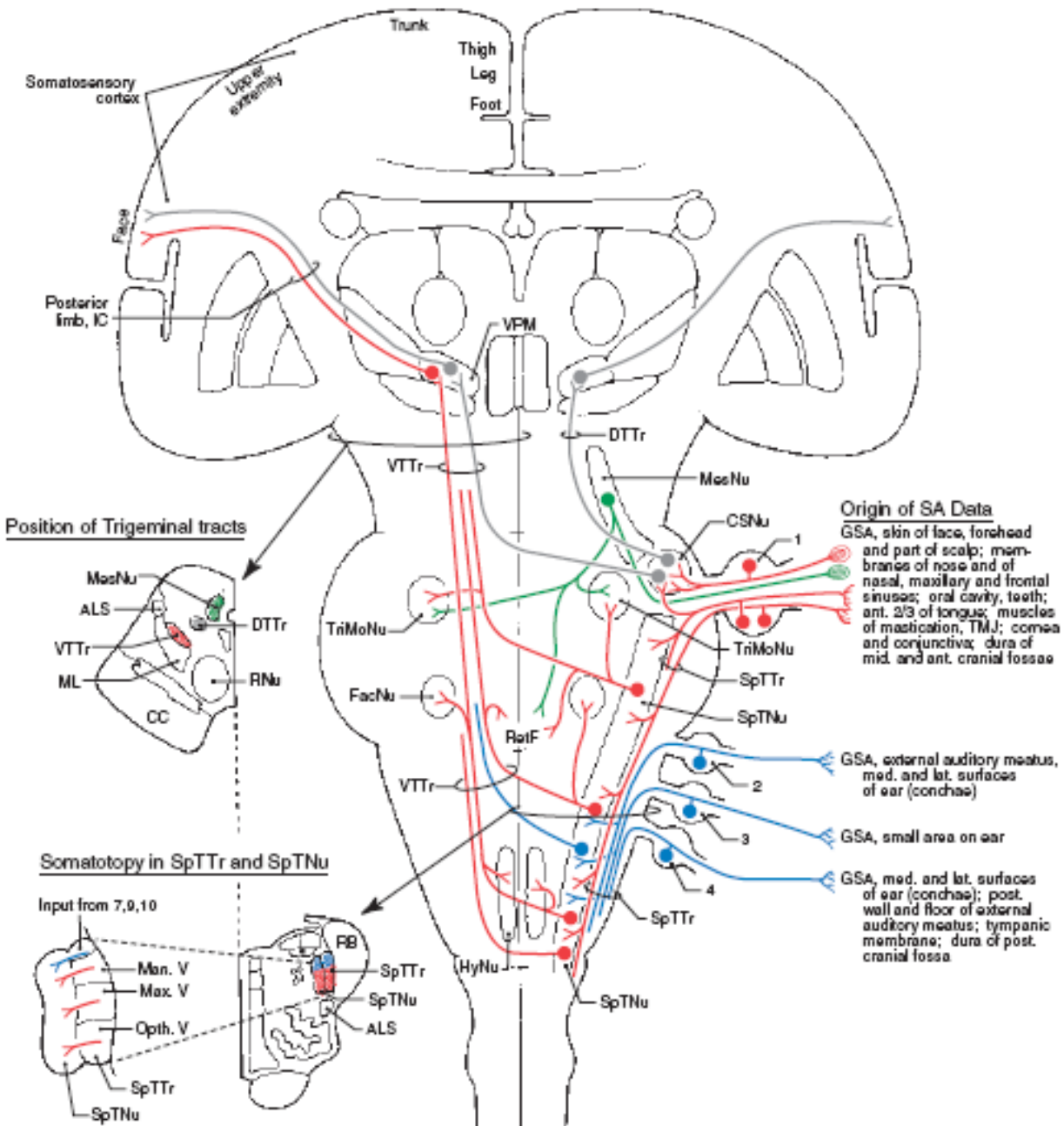

Trigeminal Nerve: CN V

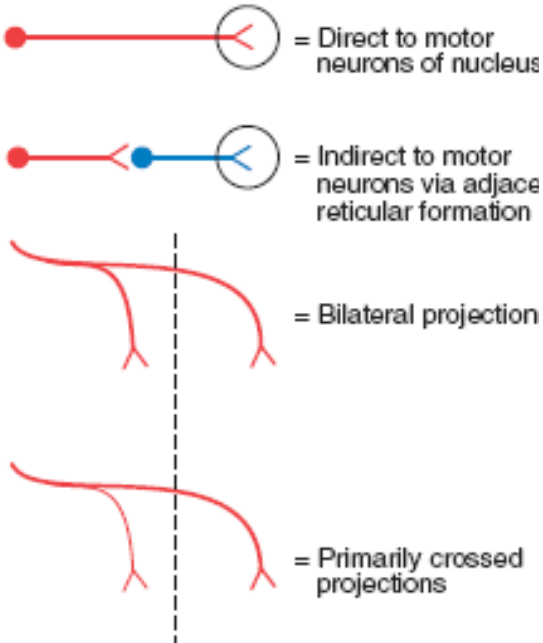

Motor cortex, precentral gyrus

Frontal eye field

Genu of IC

riMLF

OcNu

TroNu

Bilateral for upper face

TriMoNu *

PPRF

AbdNu

FacNu *

Crossed for lower face

NuAm *

Crossed for uvula (soft palate) *

Crossed for genioglossus muscle *

HyNu

AccNu *

Facial Nerve: CN VII

Facial Nerve: CN VII

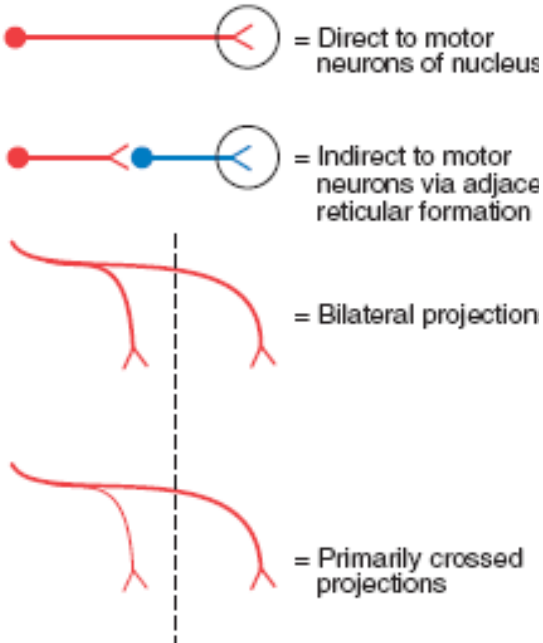

Motor cortex, precentral gyrus

Frontal eye field

Genu of IC

Bilateral for upper face

riMLF

OcNu

TroNu

TriMoNu *

PPRF

AbdNu

FacNu *

Crossed for lower face

NuAm *

Crossed for uvula (soft palate) *

Crossed for genioglossus muscle *

HyNu

AccNu *

The Facial Nerve

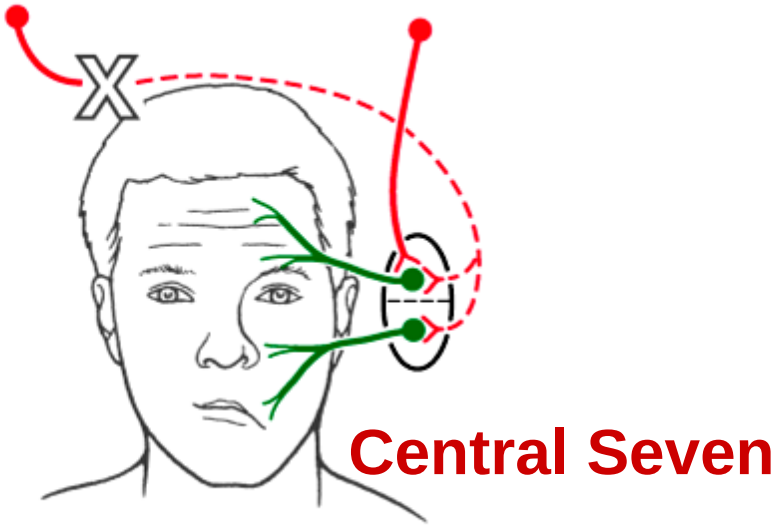

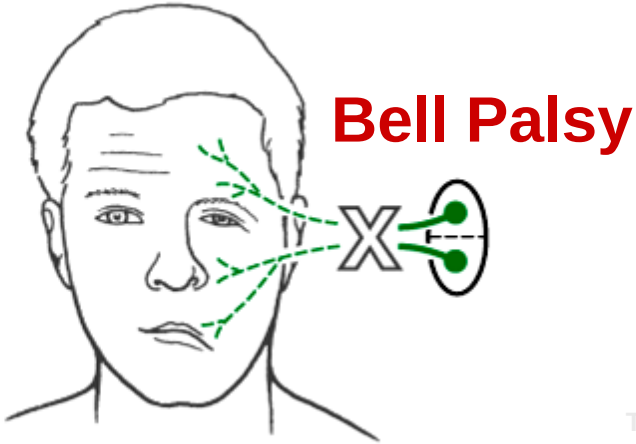

Text Fig. 25-14

Smile

Which smile is for real?

Pan Am Smile

Duchenne smile

Pan Am Smile

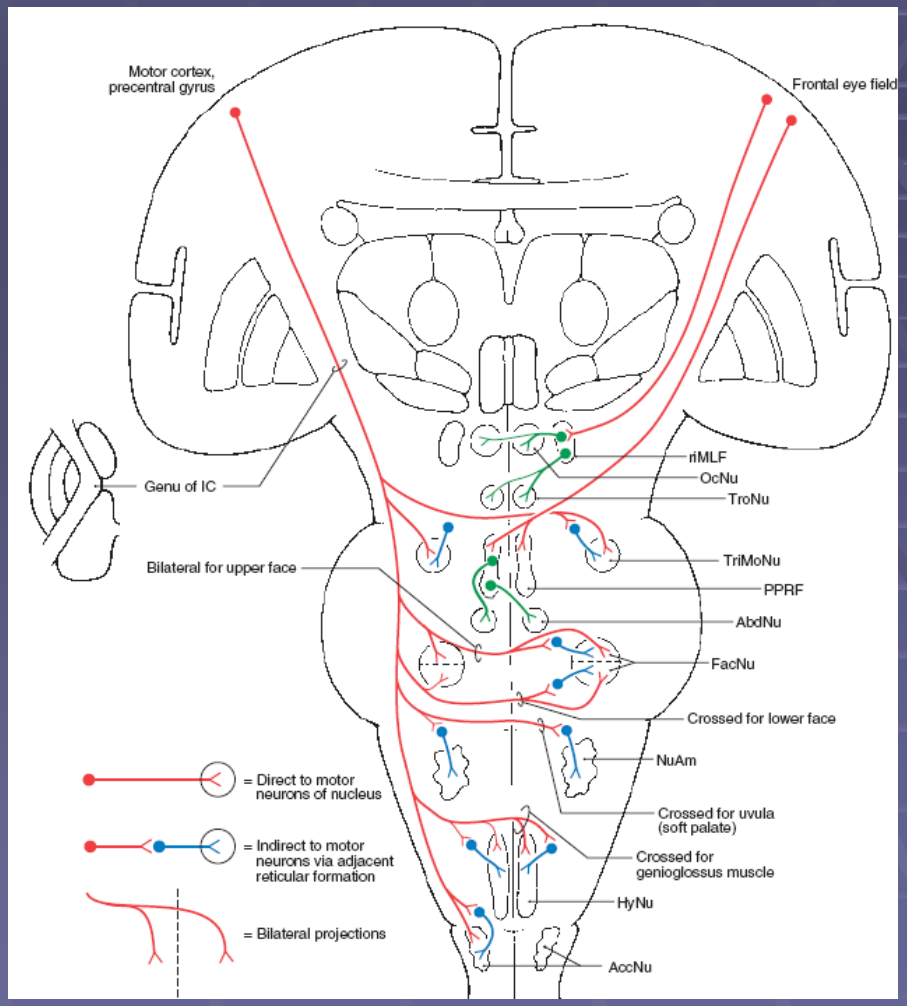
Motor cortex, precentral gyrus
Frontal eye field
Genu of IC
riMLF
OcNu
TroNu
Bilateral for upper face
TriMoNu
PPRF
AbdNu
FacNu
Crossed for lower face
NuAm
Crossed for uvula (soft palate)
Crossed for genioglossus muscle
HyNu
AccNu
= Direct to motor neurons of nucleus
= Indirect to motor neurons via adjacent reticular formation
= Bilateral projections

Duchenne smile

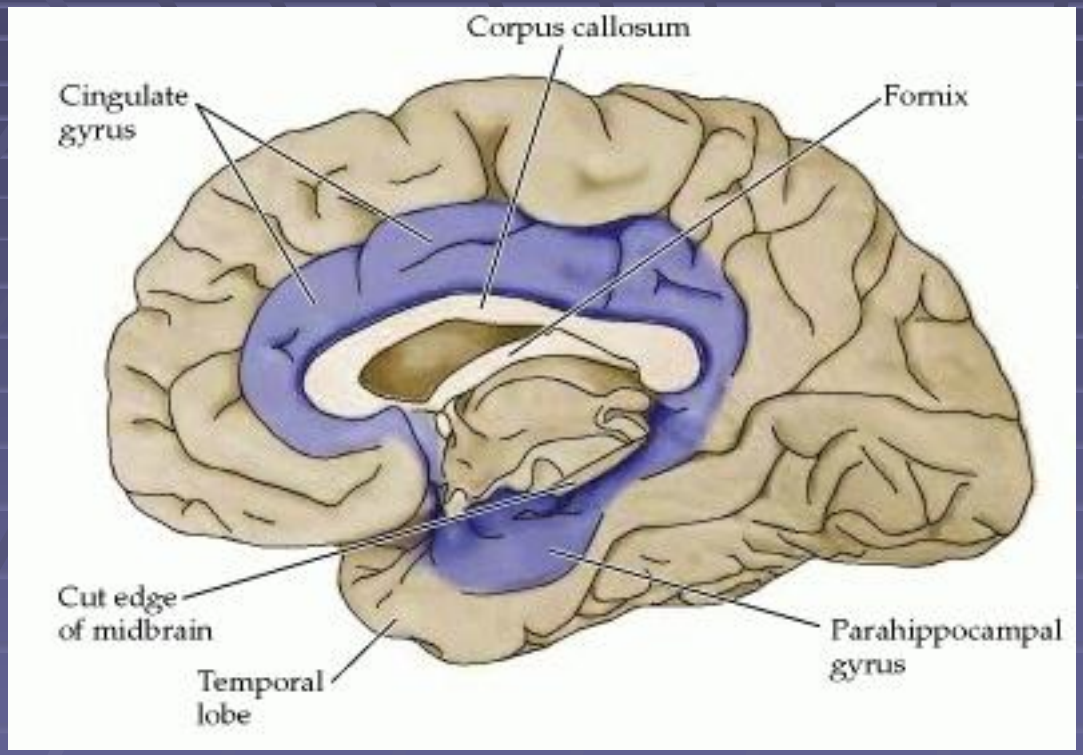

Corticonuclear Fibers

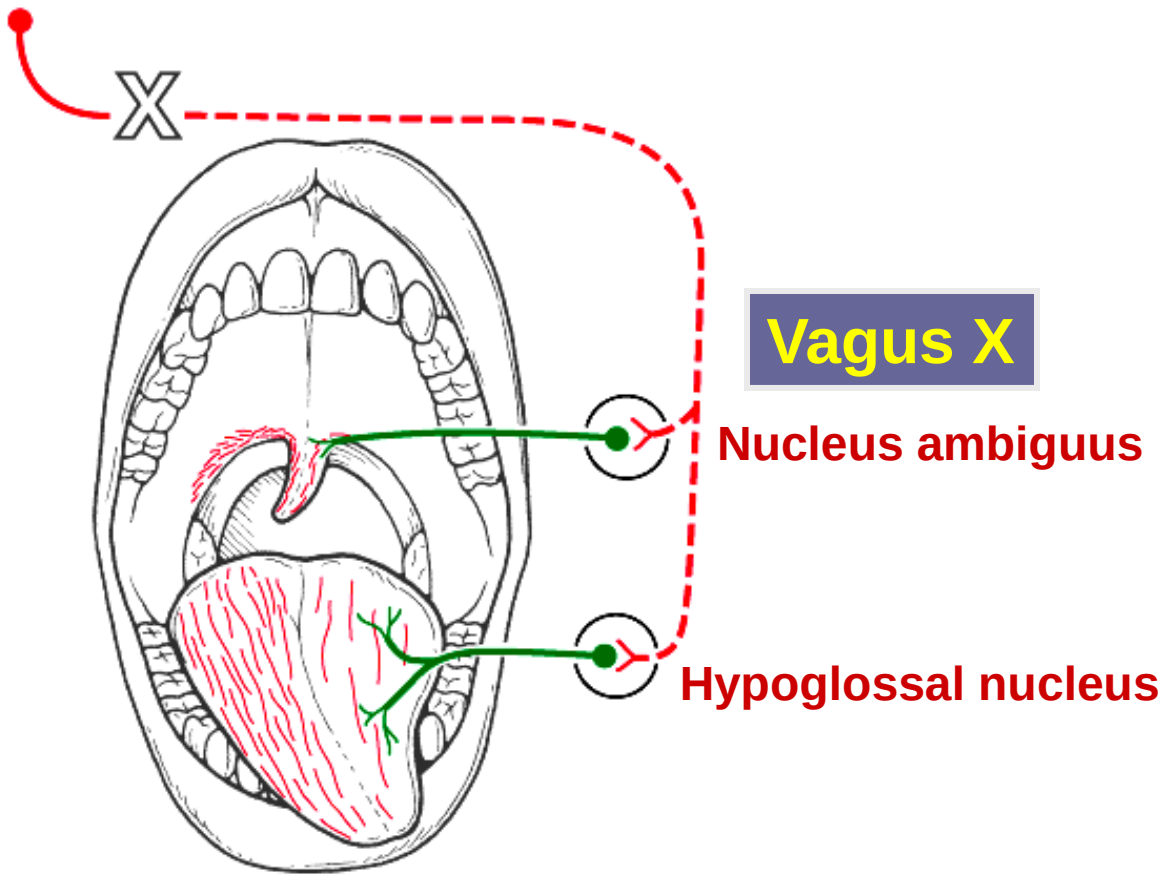

Text Fig. 25-15

Corticonuclear Fibers

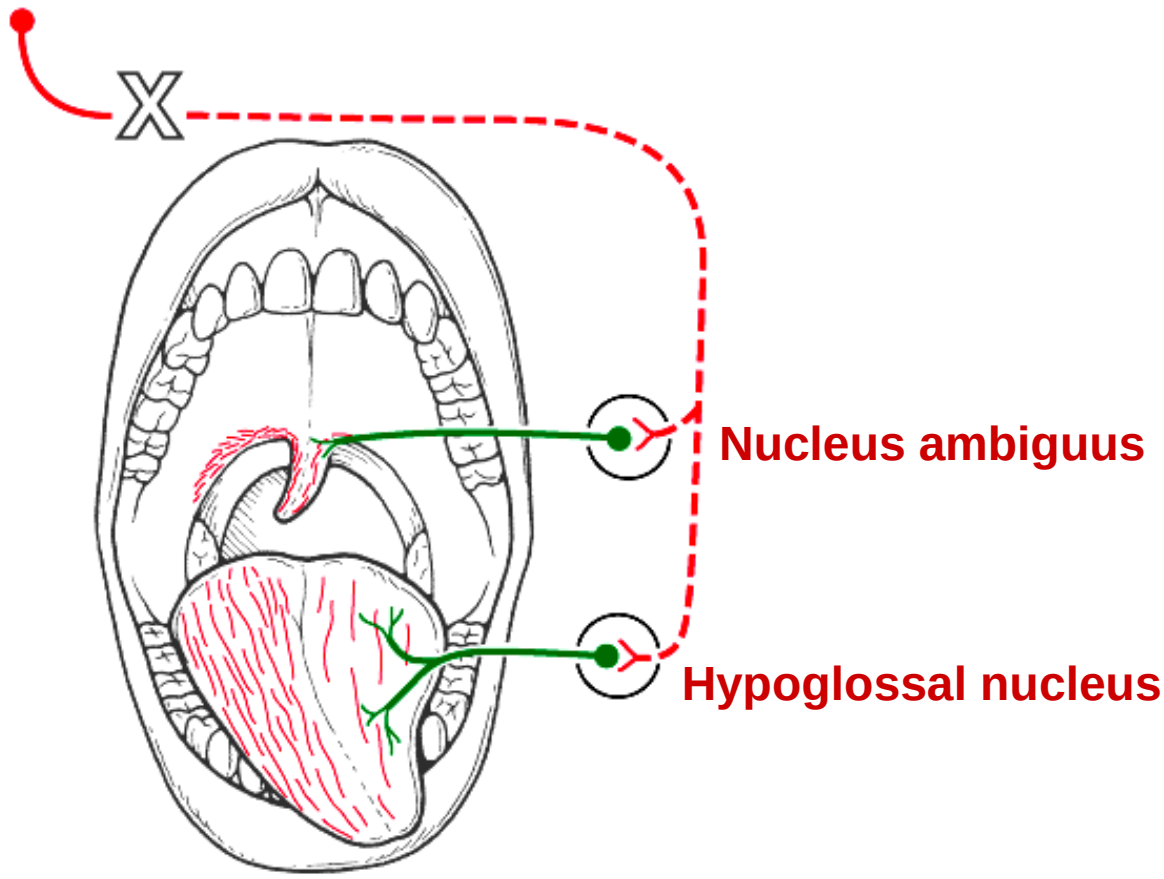

Text Fig. 25-15

Lesion of the Hypoglossal Nerve

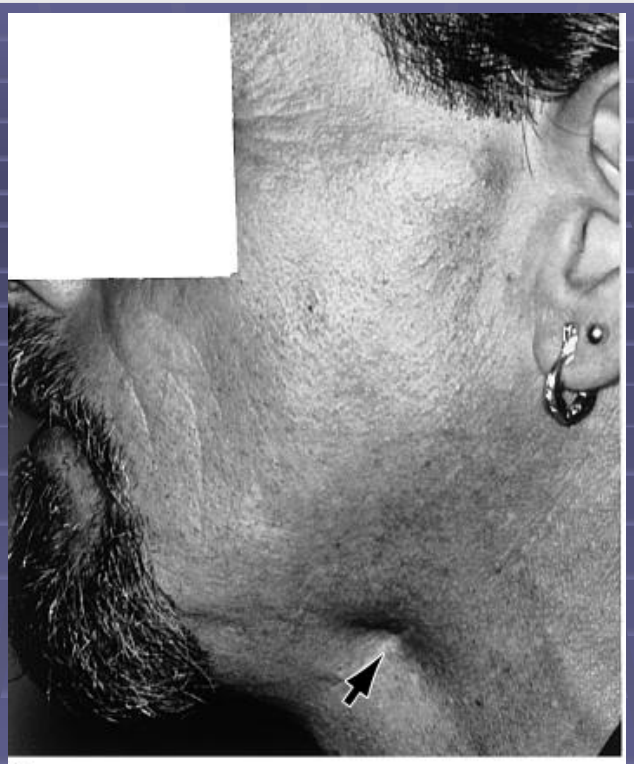

A

B

Text Fig. 25-16

Accessory Nerve CN XI

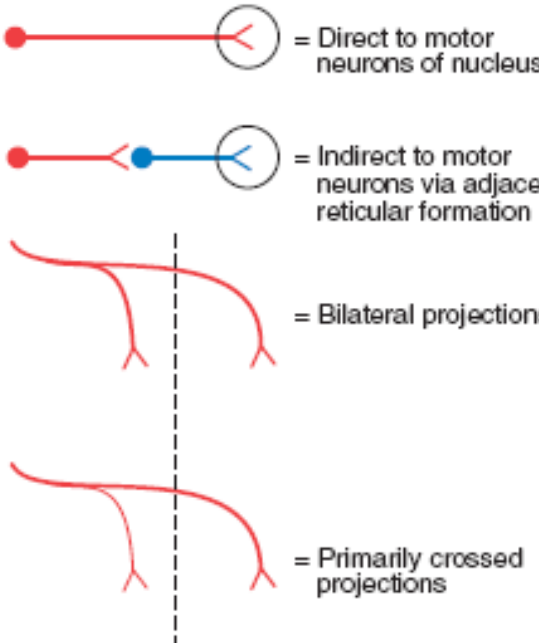

Motor cortex, precentral gyrus

Frontal eye field

Genu of IC

riMLF

OcNu

TroNu

Bilateral for upper face

TriMoNu *

PPRF

AbdNu

FacNu *

Crossed for lower face

NuAm *

Crossed for uvula (soft palate) *

Crossed for genioglossus muscle *

HyNu

AccNu *

Accessory Nerve CN XI

Motor neurons in the cervical spinal cord → Trapezius & sternocleidomastoid muscles

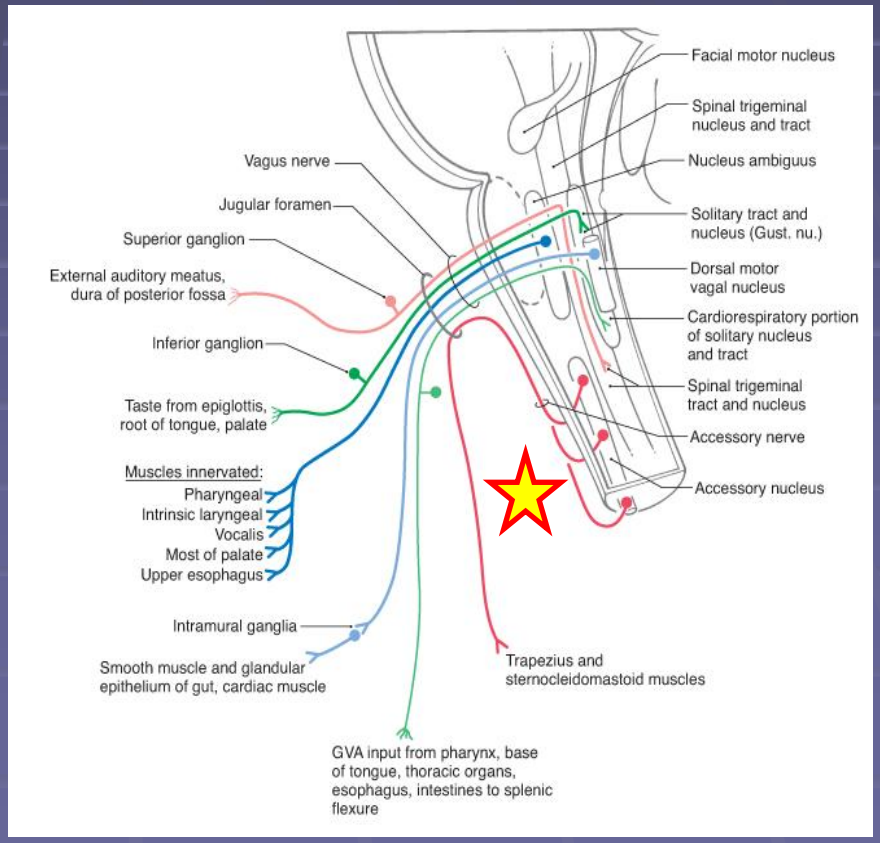

Sternocleidomastoid

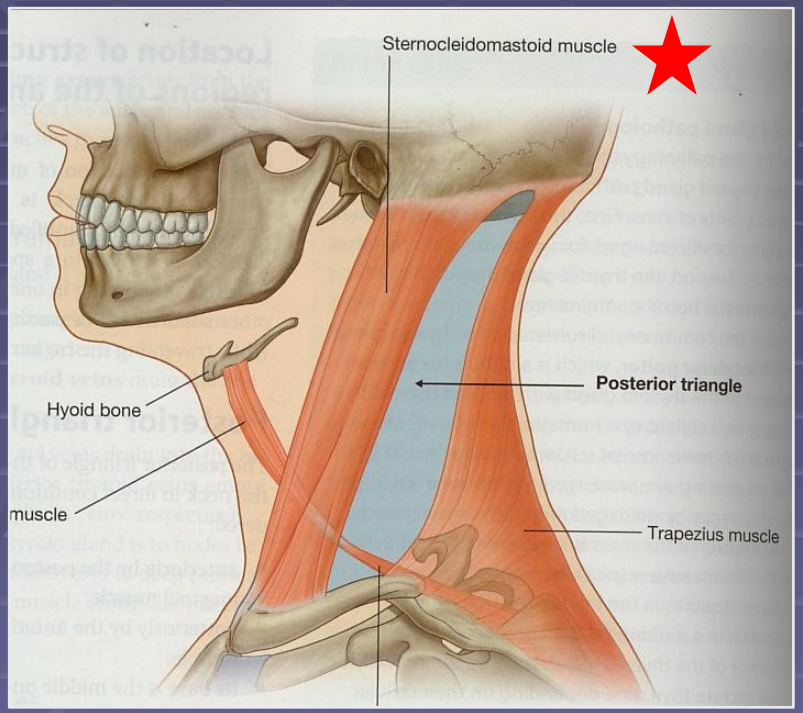

Trapezius

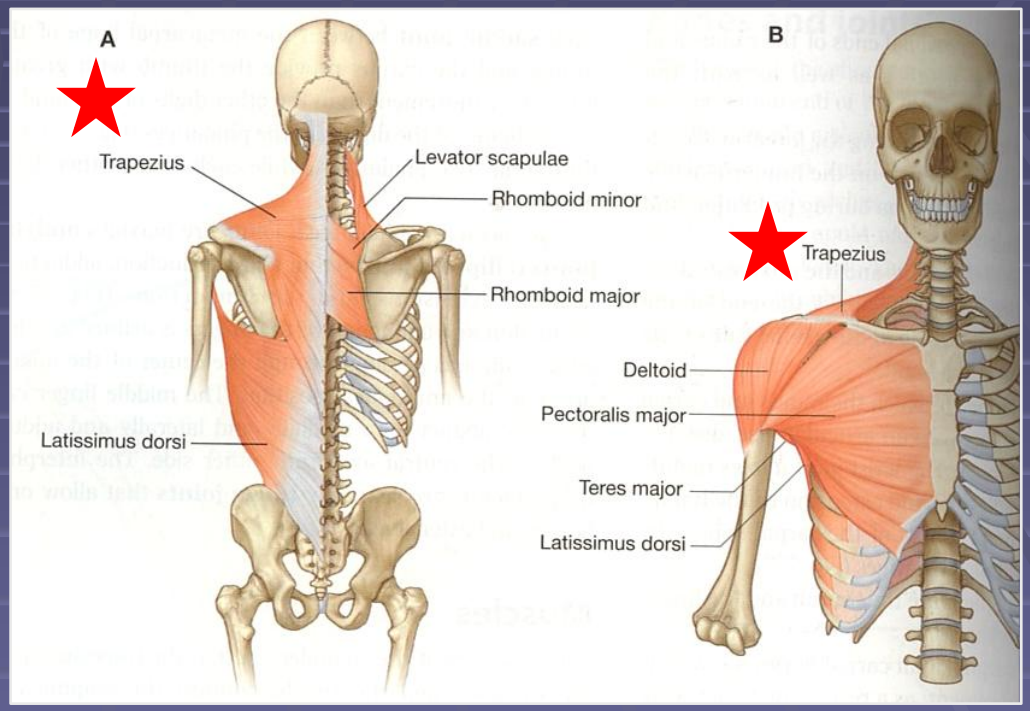

Gray's Anatomy for students: Figs. 8.171 page 920, 7.9 page 614

The sternocleidomastoid will tilt the head towards the shoulder on the same side, Thereby, rotating the head to turn the face to the opposite direction

Case Study

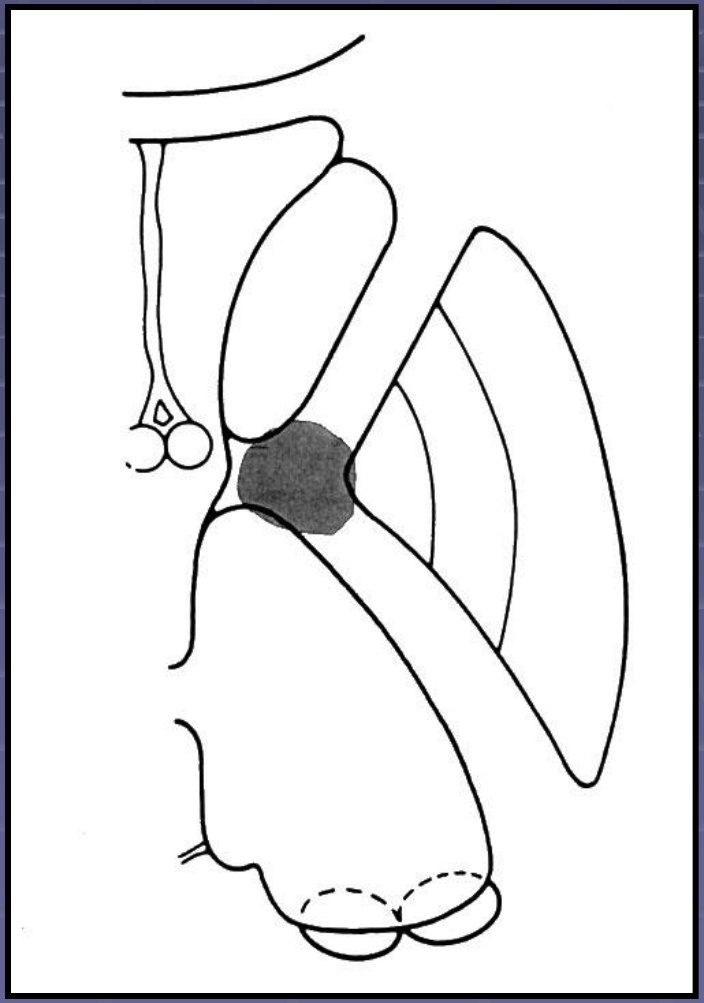

Case Study

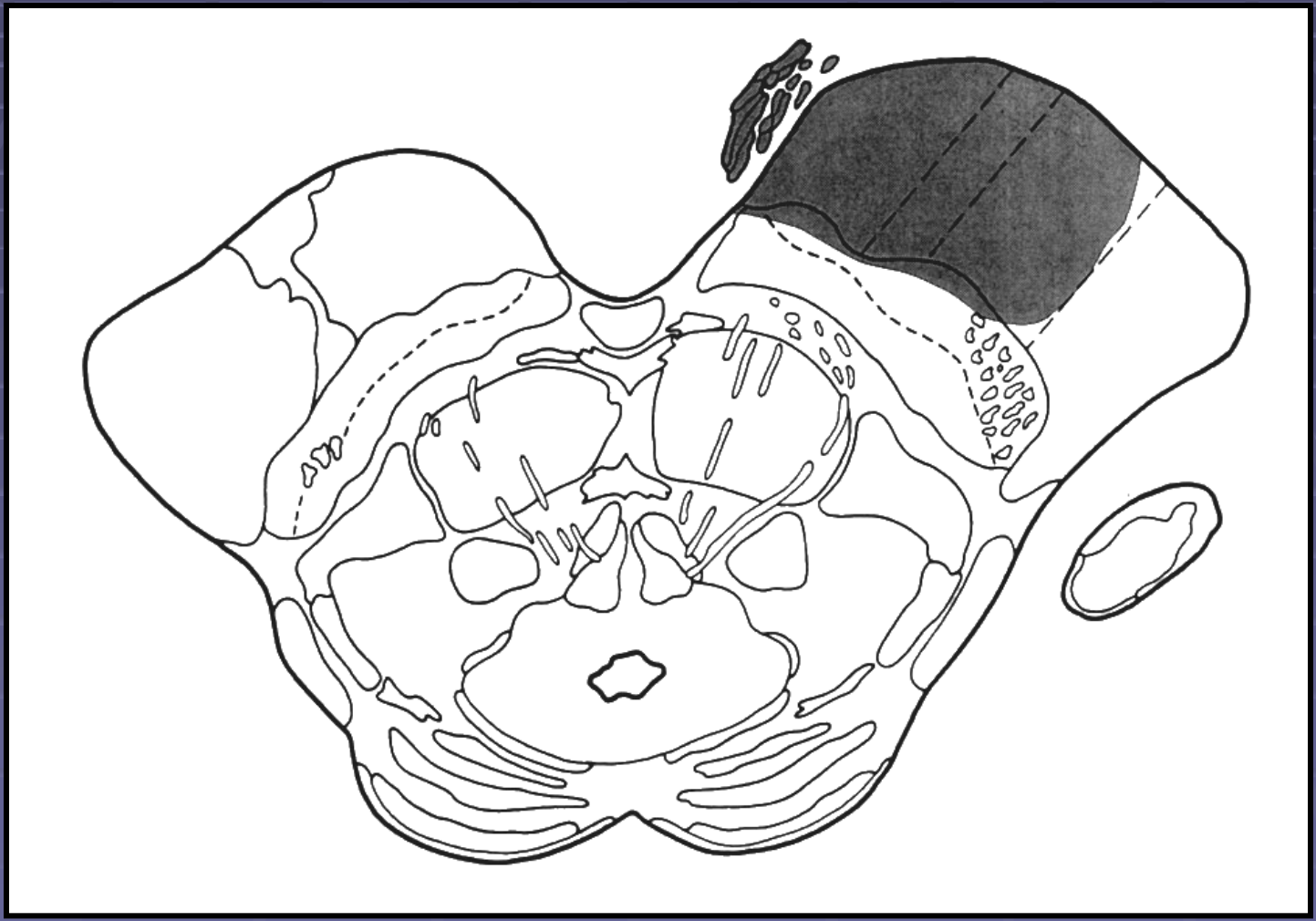

Brainstem Syndromes Involving Corticospinal Fibers and Cranial Nerves

SYNDROME	STRUCTURES INVOLVED	CORRESPONDING DEFICIT
Benedikt syndrome (Weber and Claude)	Corticospinal fibers in crus	Contralateral hemiplegia
	Oculomotor nerve fibers	Ipsilateral oculomotor palsy, dilated pupil, diplopia
	Red nucleus	Contralateral tremor, hyperkinesias
	Cerebellothalamic fibers	Contralateral ataxia
	(Medial lemniscus)	(Contralateral loss of vibratory sense, position sense, discriminative touch)
Claude syndrome†	Oculomotor nerve fibers	Ipsilateral oculomotor palsy, dilated pupil, diplopia
	Red nucleus	Contralateral tremor, hyperkinesias
	Cerebellothalamic fibers	Contralateral ataxia
	(Trochlear nucleus)	(Weakness of contralateral superior oblique muscle)
Dejerine syndrome (medial medullary)	Corticospinal fibers in pyramid	Contralateral hemiplegia
	Hypoglossal nerve fibers or nucleus	Ipsilateral deviation of tongue on protrusion
	Medial lemniscus	Contralateral loss of vibratory sense, position sense, discriminative touch
Foville syndrome‡	Corticospinal fibers in basilar pons	Contralateral hemiplegia
	Abducens nerve fibers	Ipsilateral abducens (lateral rectus) palsy, diplopia
	Middle cerebellar peduncle	Ataxia
Gubler or Millard-Gubler syndrome§	Corticospinal fibers in basilar pons	Contralateral hemiplegia
	Facial nerve fibers or nucleus	Ipsilateral weakness of facial muscles
	(Anterolateral system)	(Impaired pain and thermal sense on contralateral side of body)
	(Trigeminal nerve fibers)	(Impaired pain and thermal sense on ipsilateral side of face)
Midpontine base syndrome	Corticospinal fibers in basilar pons	Contralateral hemiplegia
	Trigeminal nerve fibers	Ipsilateral paralysis of masticatory muscles; ipsilateral loss of pain and thermal sensations on face
	Middle cerebellar peduncle	Ataxia
Raymond syndrome	Corticospinal fibers in basilar pons	Contralateral hemiplegia
	Abducens fibers in basilar pons	Ipsilateral abducens (lateral rectus) palsy, diplopia
Wallenberg syndrome (lateral medullary, posterior inferior cerebellar artery)	Spinal trigeminal tract	Ipsilateral loss of pain and thermal sense on face
	Anterolateral system	Contralateral loss of pain and thermal sense on the body
	Vestibular nuclei	Vertigo, nystagmus, nausea, vomiting
	Nucleus ambiguus	Hoarseness, dysphagia, deviation of the uvula to opposite side on phonation
	Restiform body	Ataxia
Weber syndrome	Corticospinal fibers in crus	Contralateral hemiplegia
	Oculomotor nerve fibers	Ipsilateral oculomotor palsy, dilated pupil, diplopia
	Corticonuclear fibers in crus	Contralateral weakness of facial muscles on lower half of face; deviation of the tongue to contralateral side on protrusion; ipsilateral weakness of trapezius and sternocleidomastoid muscles
	Substantia nigra	Contralateral Parkinson-like tremor, akinesia

Table 25-1

The Uncus and Uncal Herniation

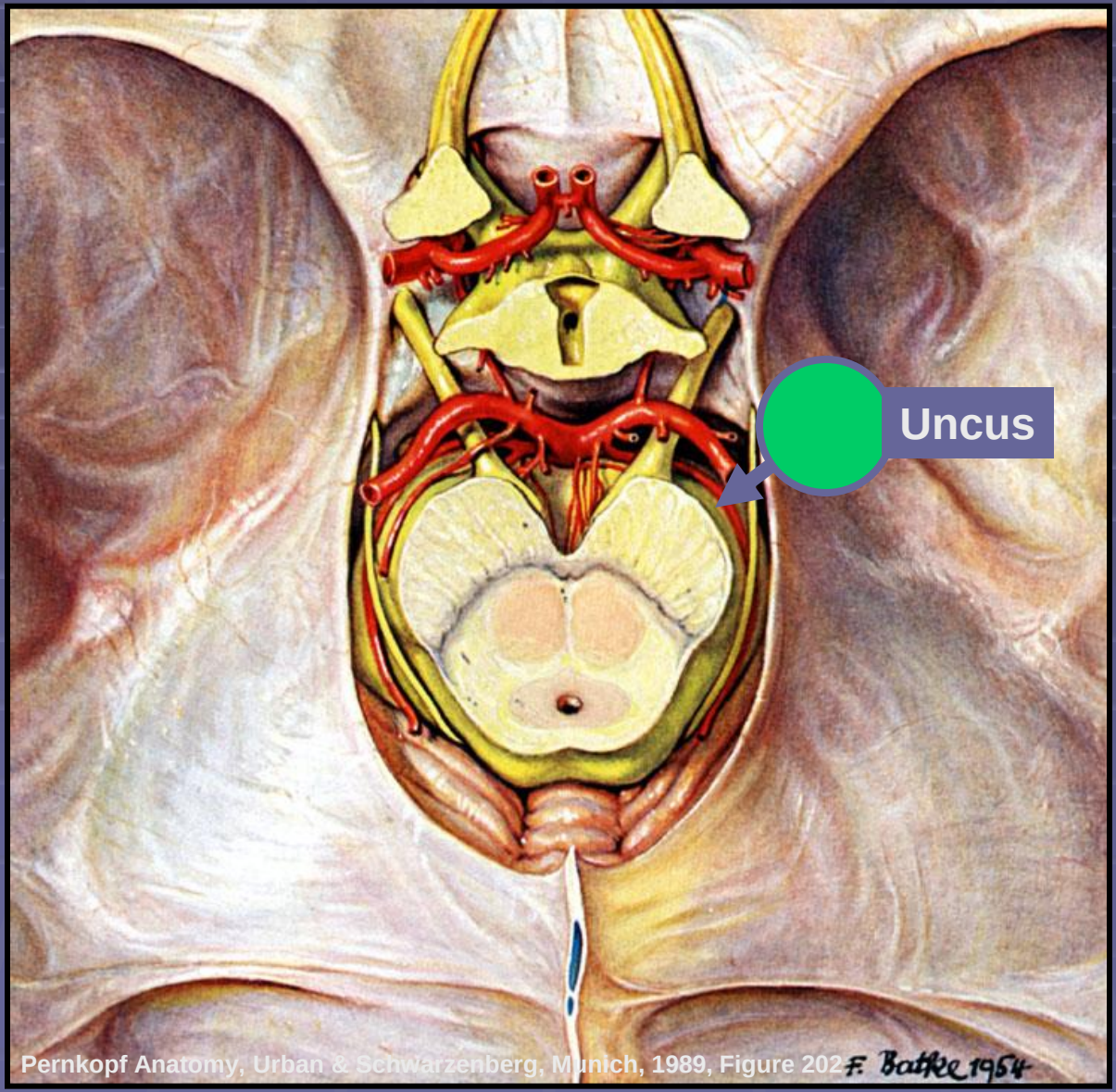

Pernkopf Anatomy, Urban & Schwarzenberg, Munich, 1989, Figure 202

The Uncus and Uncal Herniation

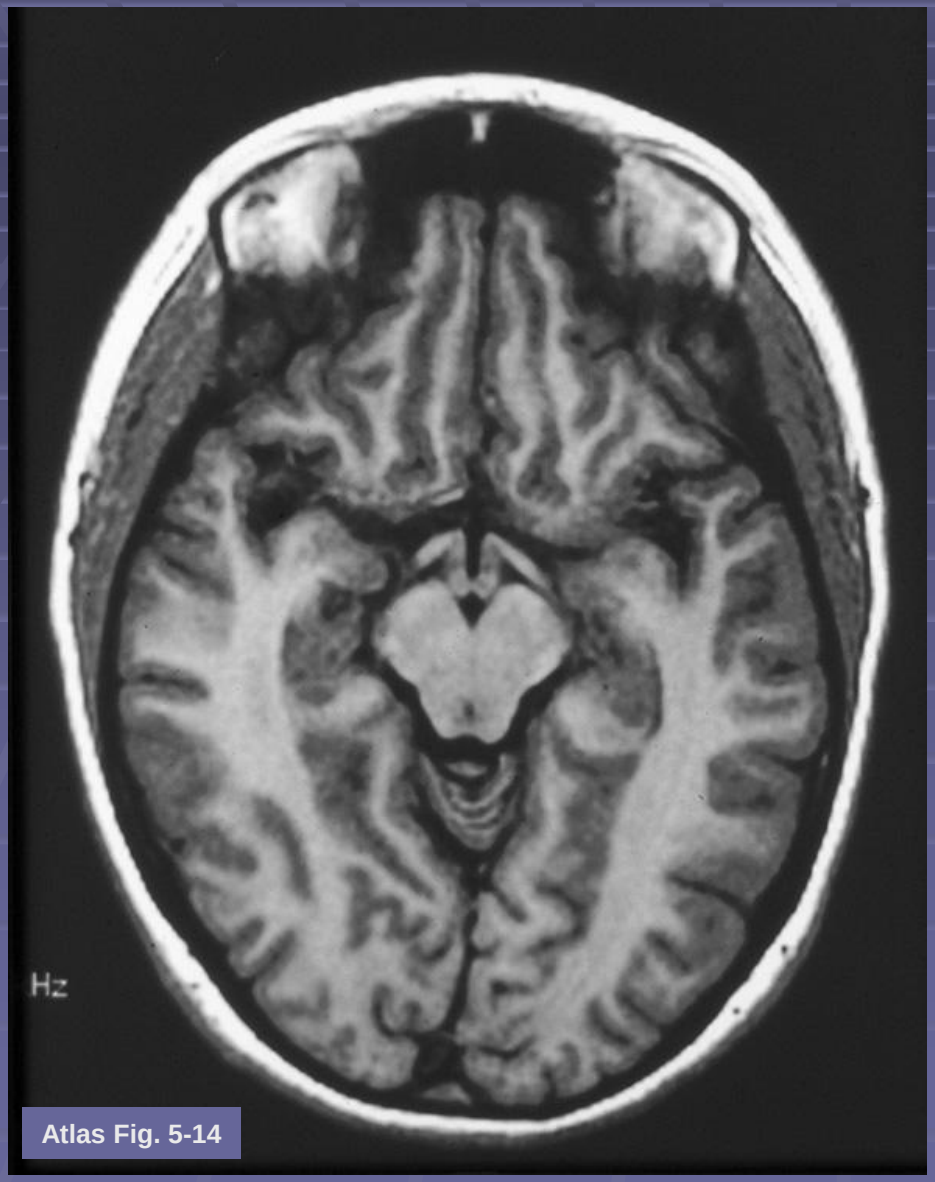

Atlas Fig. 5-14



Text Fig. 25-17

Third Nerve Palsy

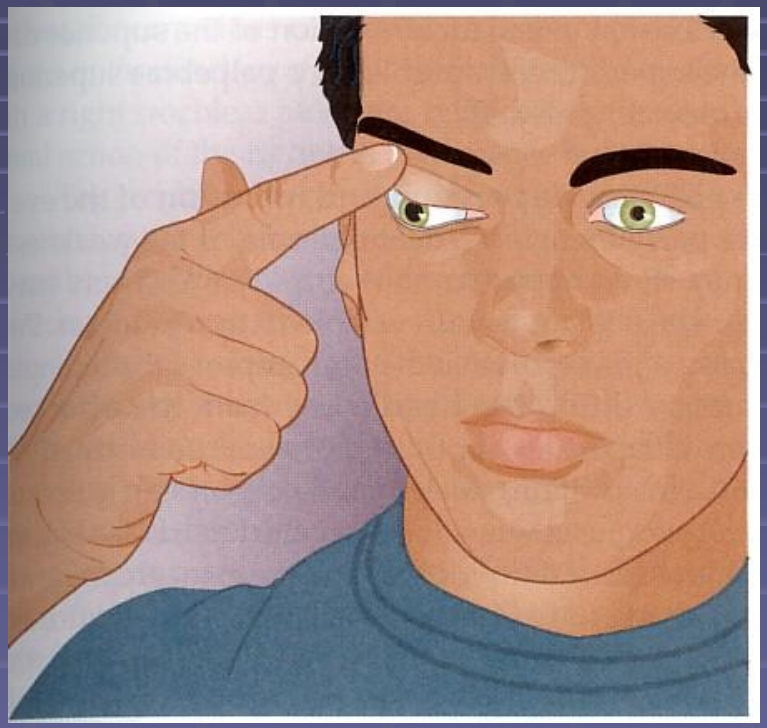

Eye “down and out”

Corticonuclear Fibers in the Crus Cerebri

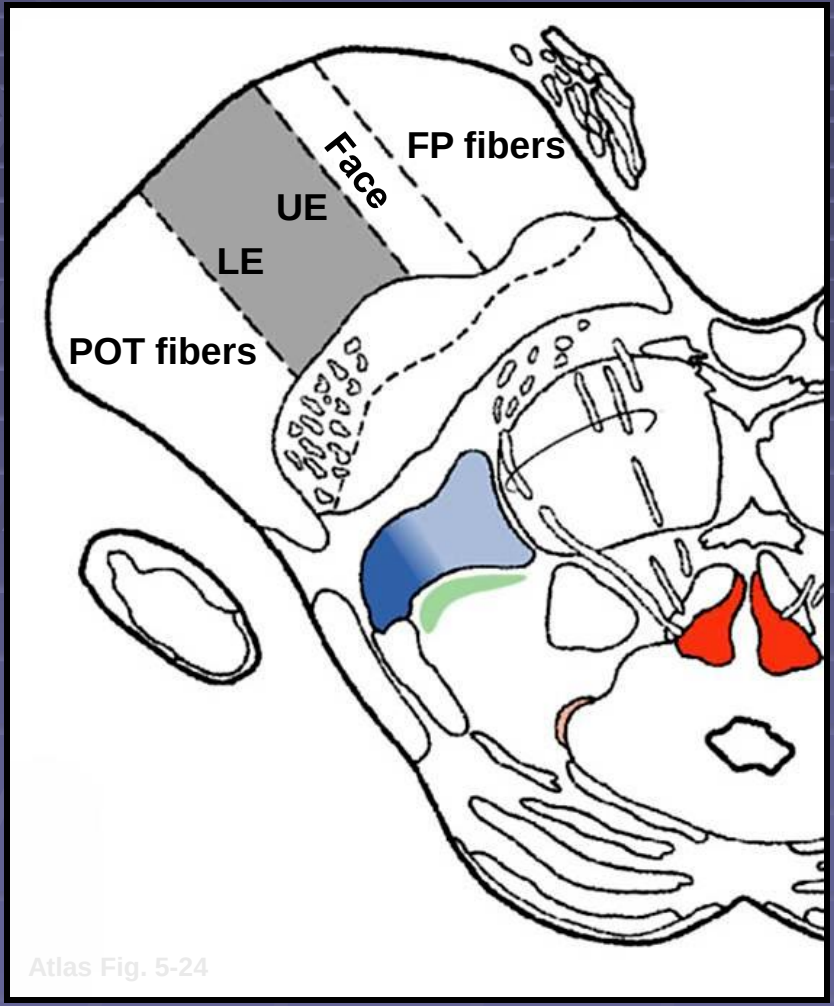

The Kernohan Syndrome

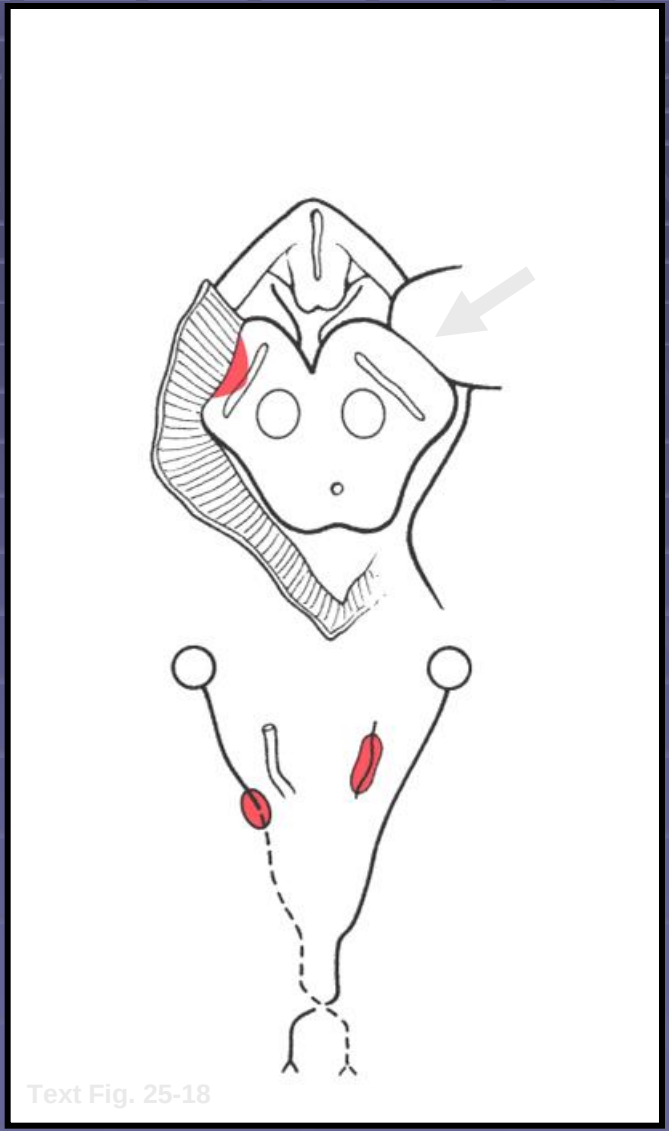

Thank you