The Arm

REVIEW

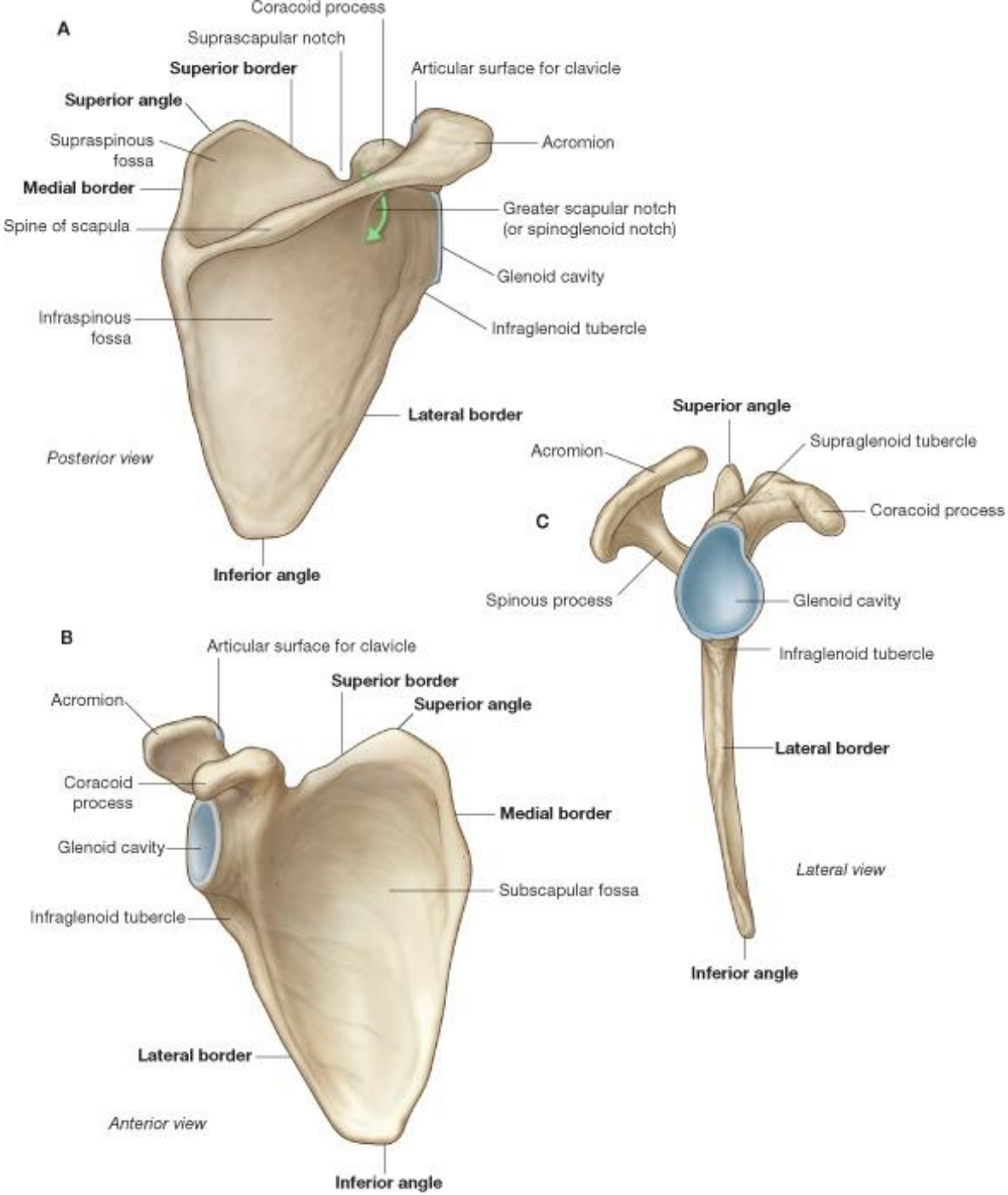

REVIEW

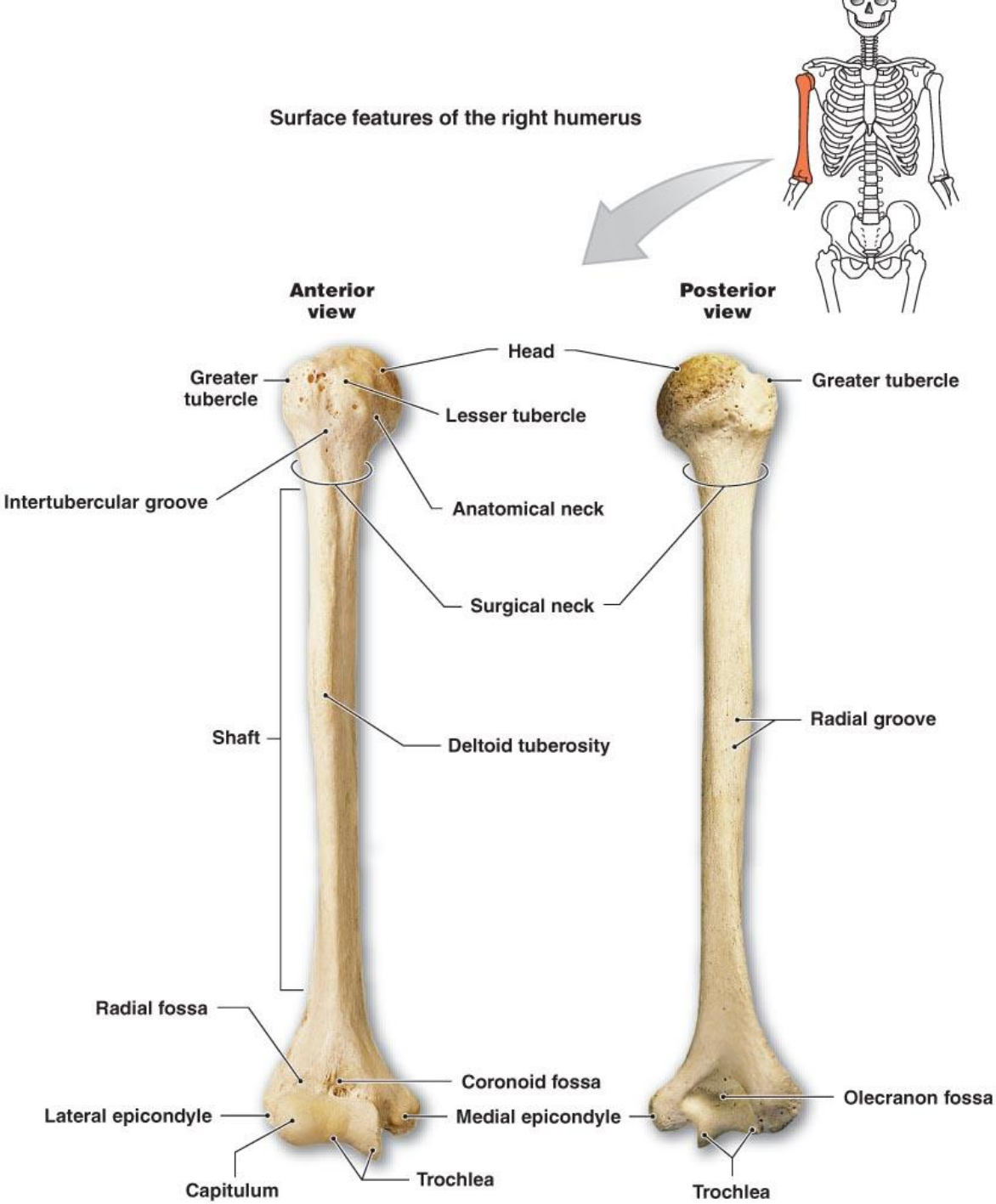

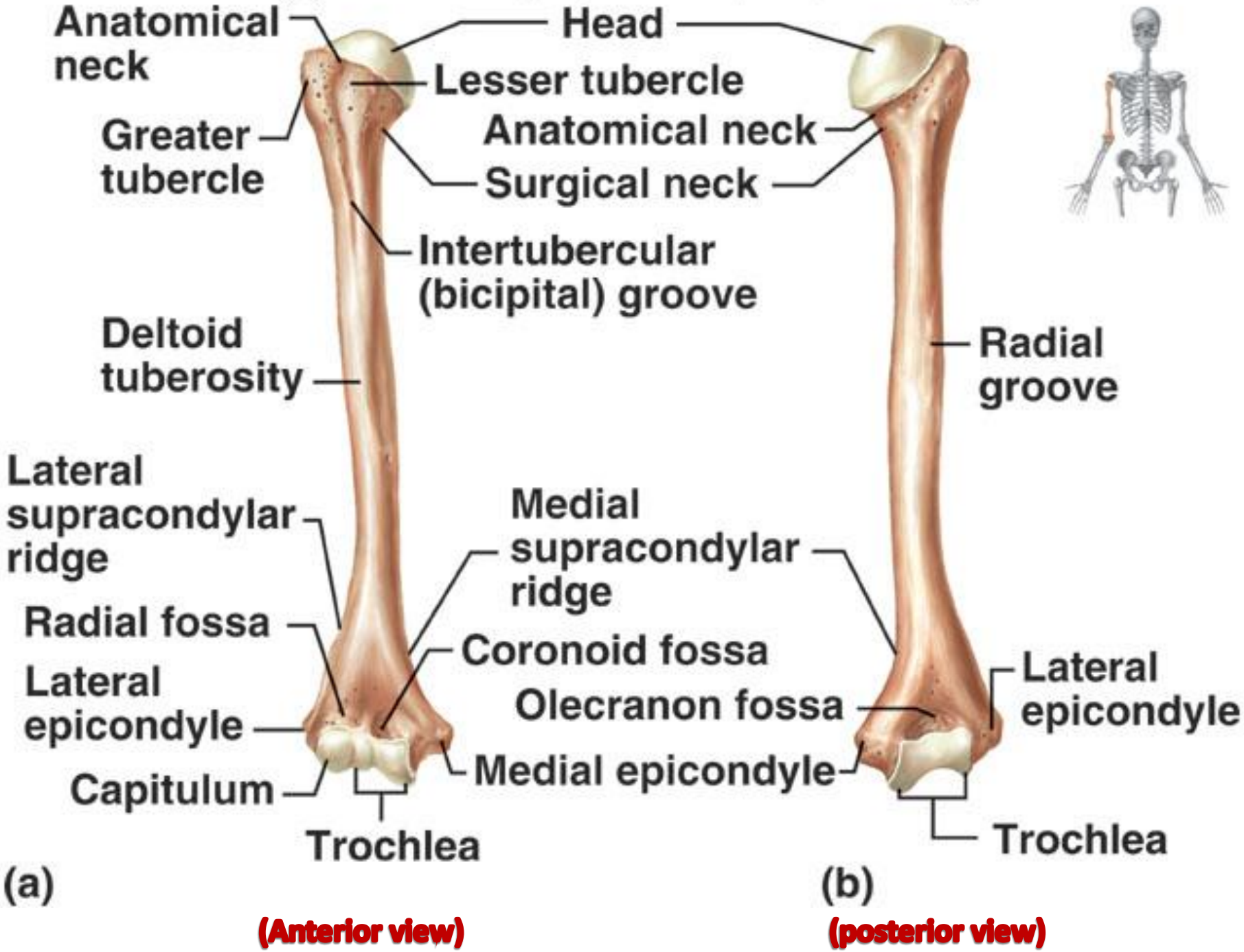

REVIEW

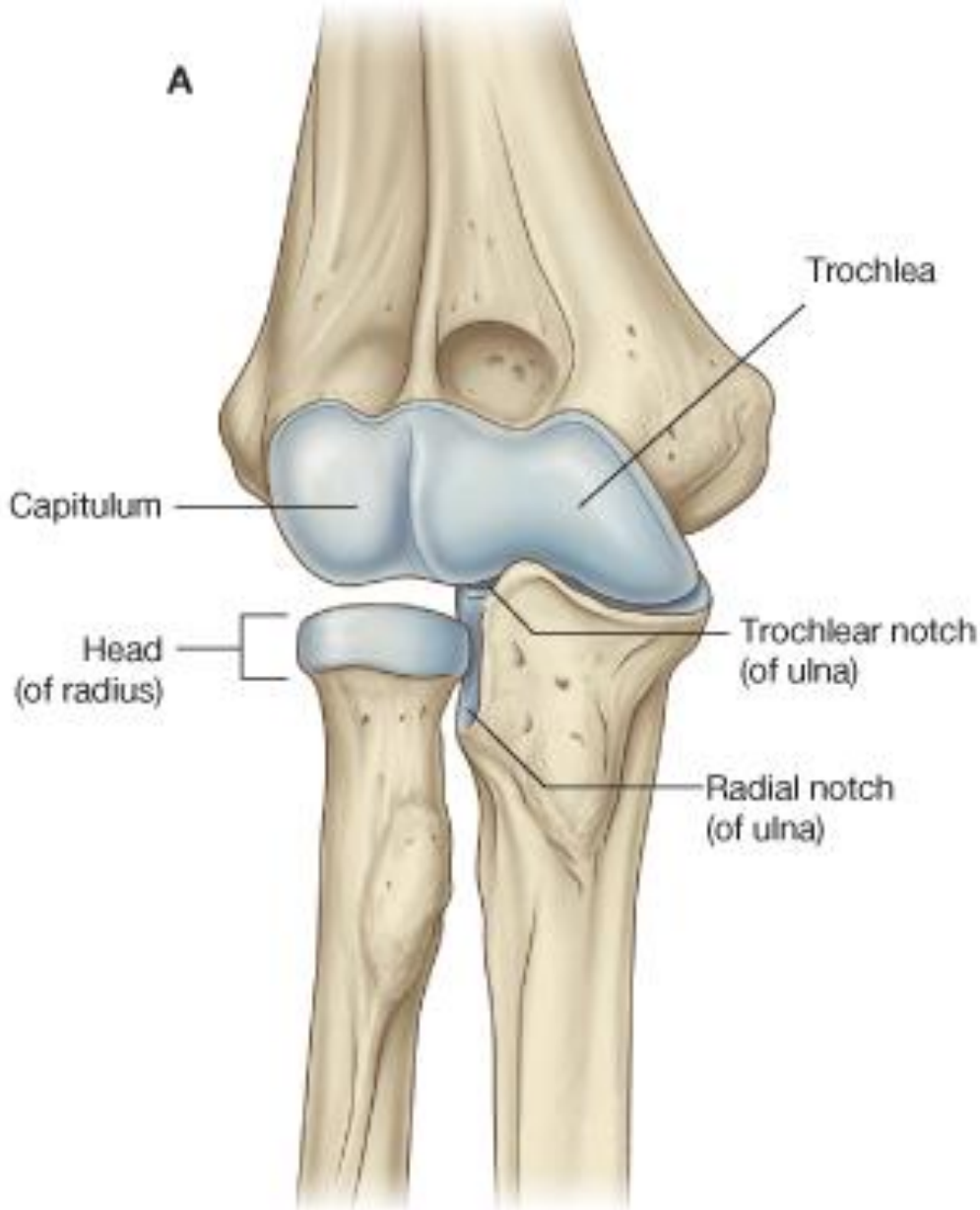

Compartments of the arm

Has the following layers:
1. Skin
2. Superficial fascia
3. Deep fascia, sends two internuscular septums to humerus which divides the arm into two compartments, each has:
   1. Its muscles
   2. Its nerve supply
   3. Its arterial supply
   4. its main action

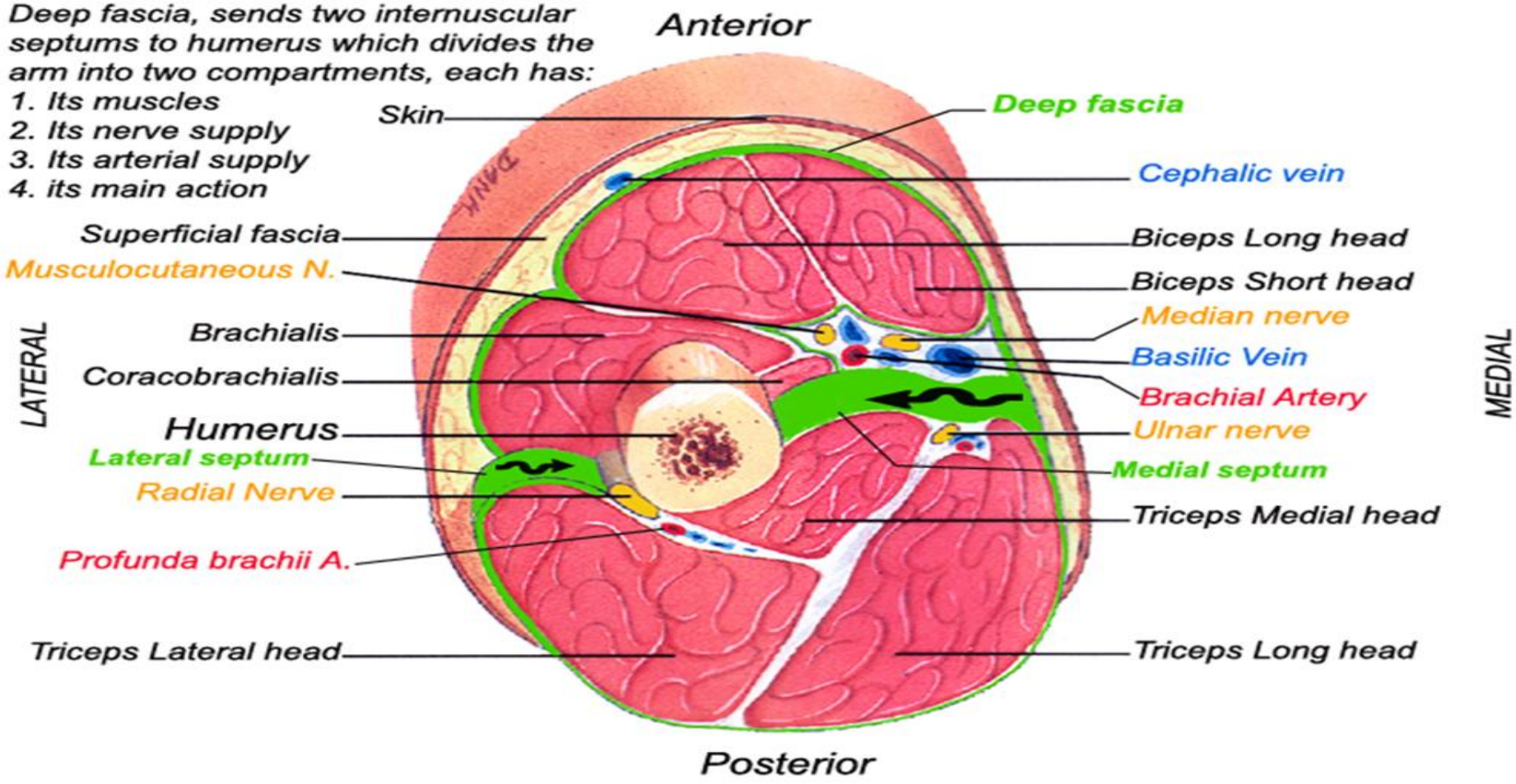

The Anterior compartment

I.Muscles :

- Biceps brachii
- Coracobrachialis
- Brachialis

II.Nerve supply :

- Musculocutaneous nerve

III.Arterial supply :

- Brachial artery

IV.Main action:

- Flexion

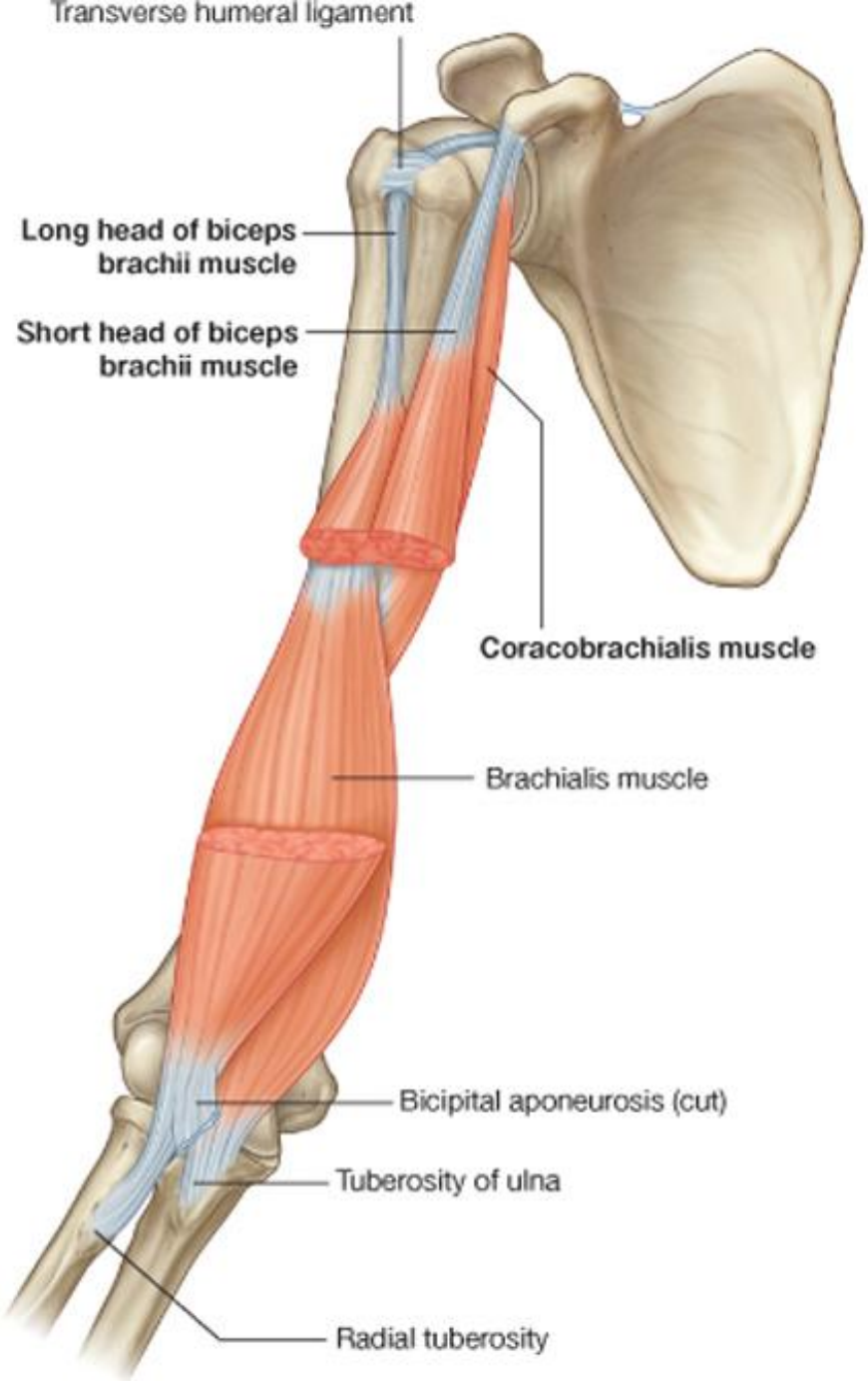

Biceps

Two heads

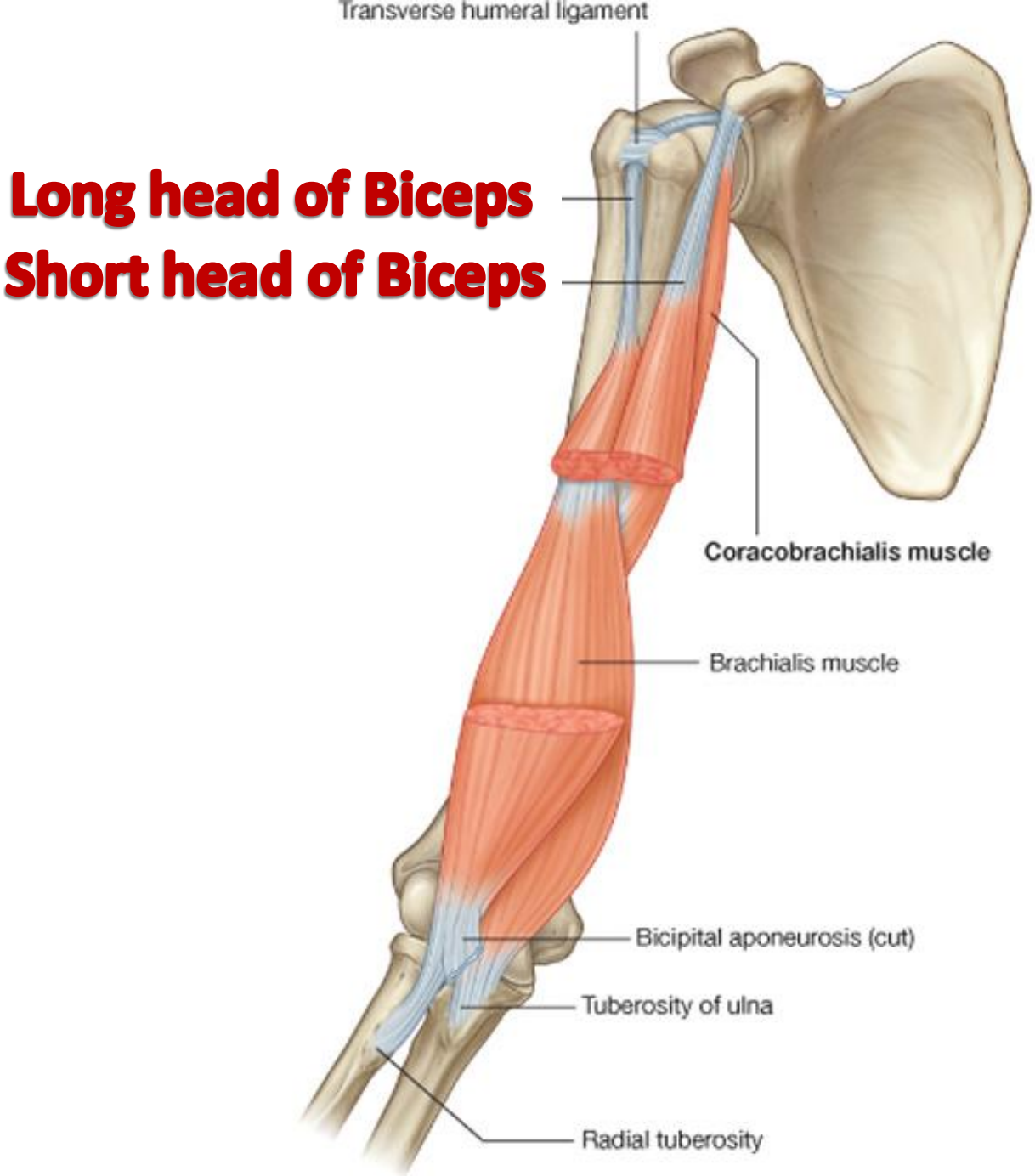

Biceps

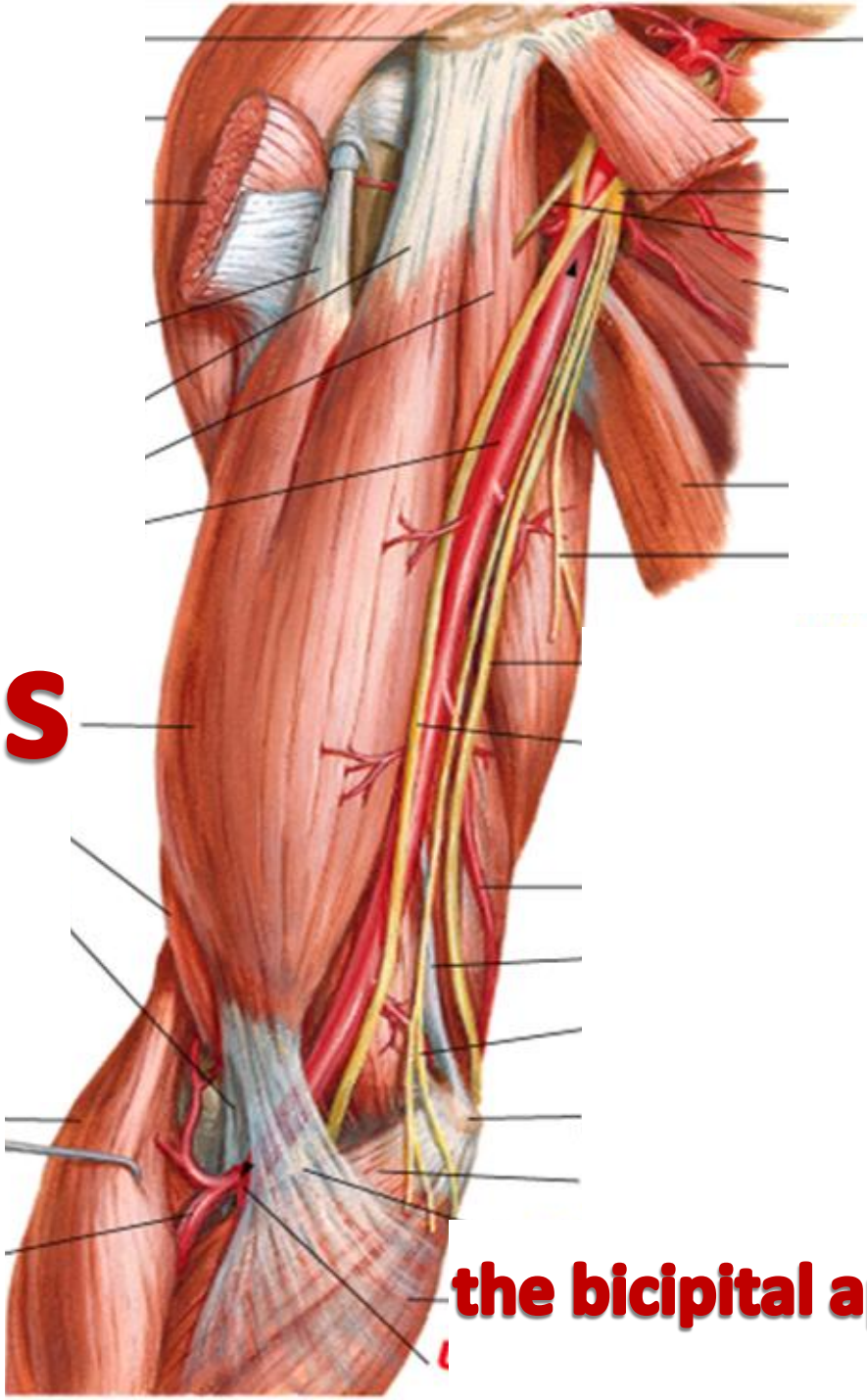

the bicipital aponeurosis

Biceps brachii

I.Origin:

-Long head : Supraglenoid tubercle of scapula

-Short head: Coracoid process of scapula

II.Insertion :

Tuberosity of radius and bicipital aponeurosis

III. Innervation :

Musculocutaneous nerve

IV. Action :

Supinator, Powerful flexor of elbow joint , weak flexor of shoulder joint

Coracobrachialis

Coracoid

Origin

Brachium (Humerus)

Insertion

Coracobrachialis

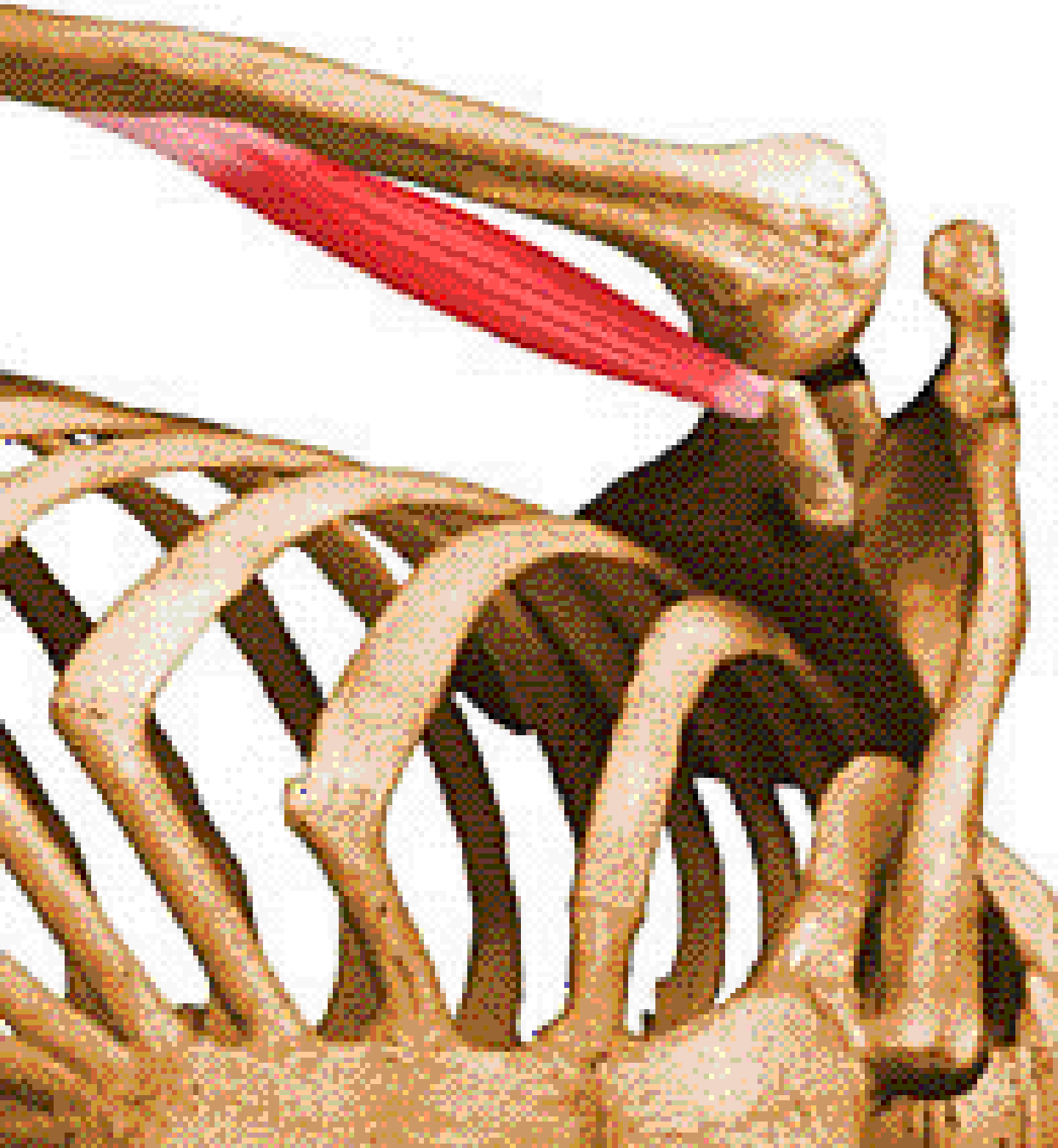

Coracobrachialis

I.Origin:
Coracoid process of scapula

II.Insertion:
Medial aspect of shaft of humerus

III.Innervation:
Musculocutaneous nerve

IV.Action:
Flexor of the arm ,weak adductor.

Brachialis

Brachium (Humerus)

Origin

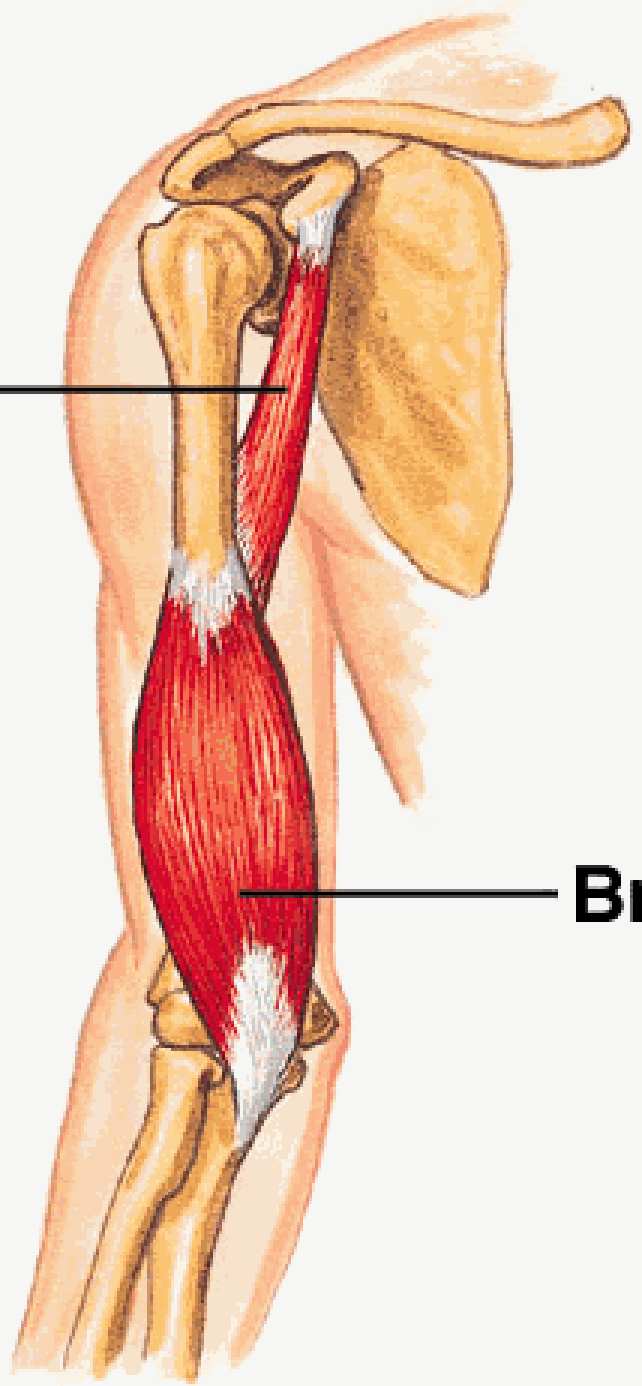

Brachialis

I.Origin:

Front of lower half of humerus

II.Insertion:

Coronoid process of ulna

III.Innervation:

Musculocutaneous nerve ,Radial Nerve.

IV.Action:

Flexor of elbow joint

Brachial Artery

- a continuation of the axillary artery
- provides the main arterial supply to the arm
- begins at the lower border of the teres major muscle
- terminates opposite the neck of the radius

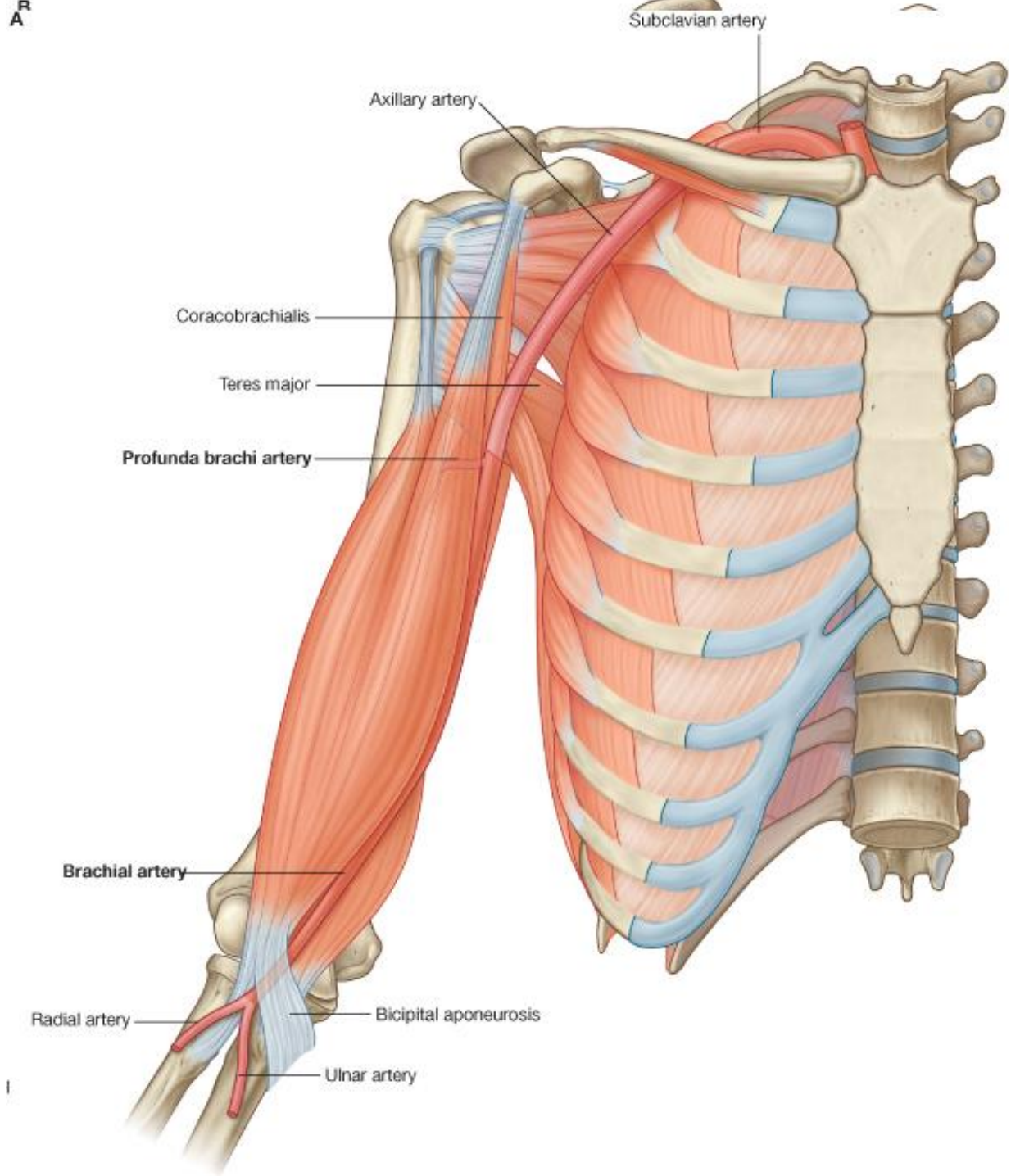
R
A
Subclavian artery
Axillary artery
Coracobrachialis
Teres major
Profunda brachi artery
Brachial artery
Radial artery
Bicipital aponeurosis
Ulnar artery

Subcalvian artery > Axillary artery > brachial artery

lateral border of the first rib

lower border of the teres major muscle

Branches of the brachial artery :

- **Profunda brachii artery**
- Superior ulnar collateral artery
- Inferior ulnar collateral artery
- Radial artery (a terminal branch)
- Ulnar artery (a terminal branch)
- Nutrient branches to the humerus

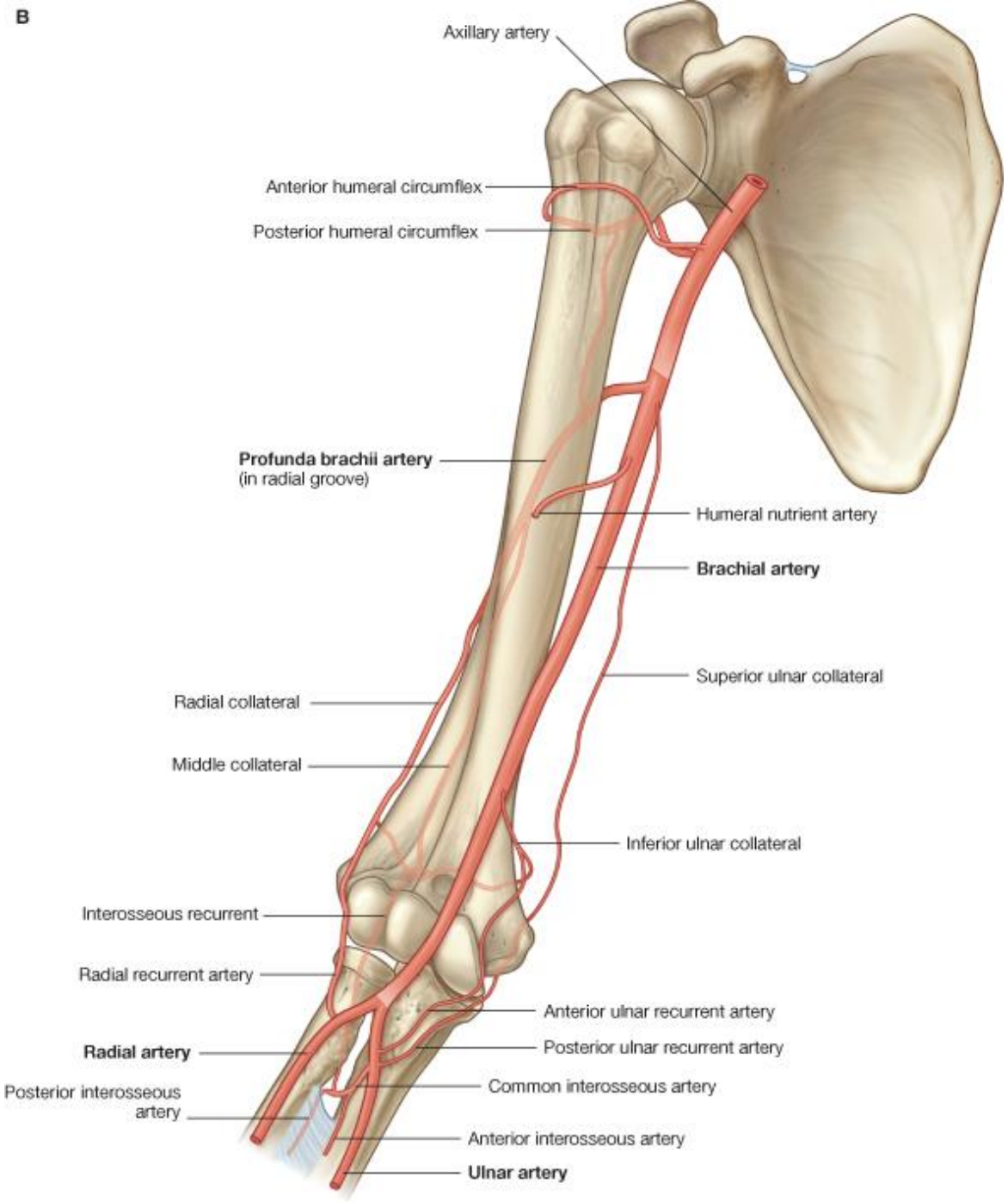

**Relation between median nerve and brachial artery:

LAM

Lateral,Anterior,Medial

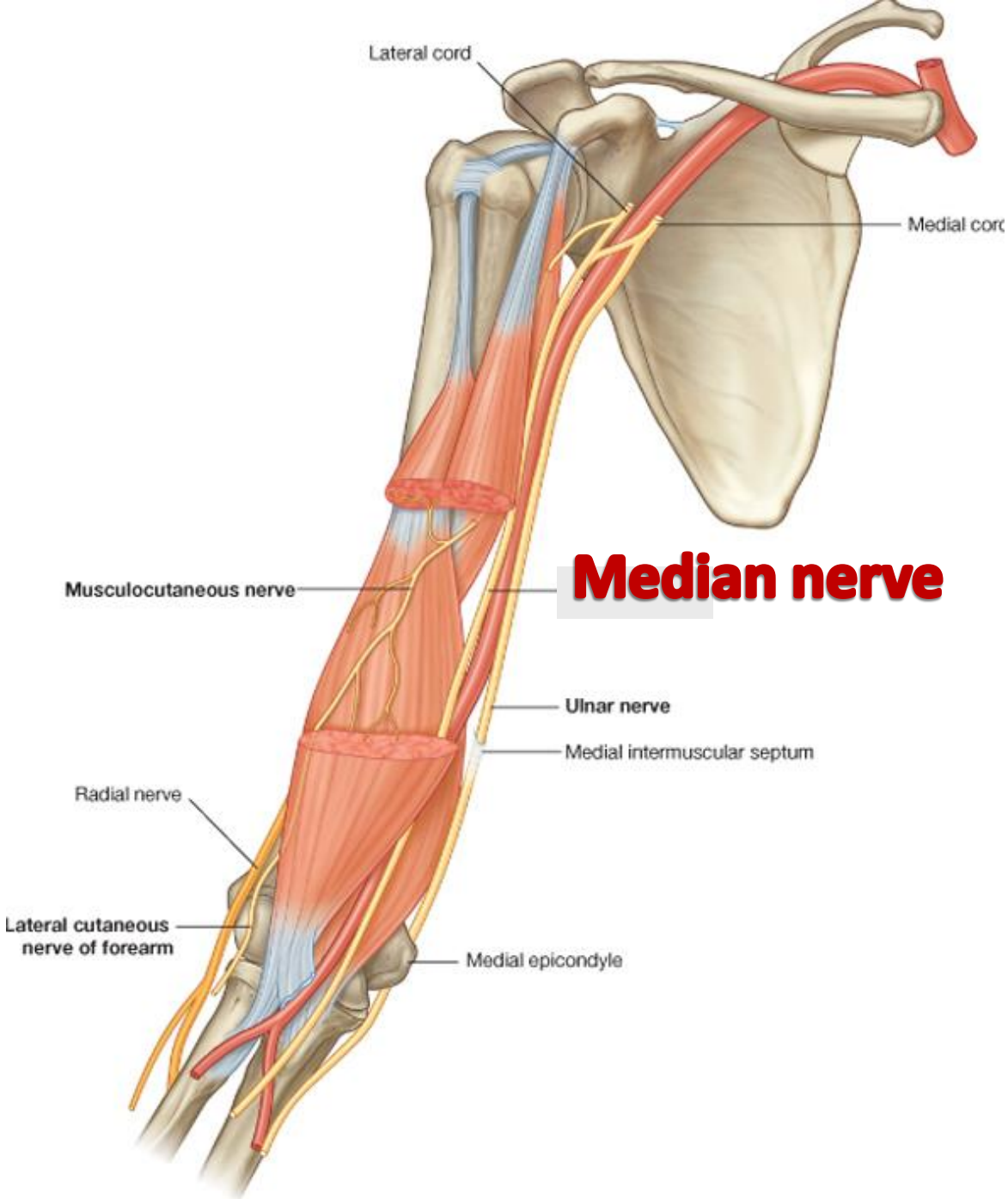

Musculocutaneous Nerve

Pierces the coracobrachialis muscle then passes downward between the biceps and brachialis muscles.

Musculocutaneous Nerve

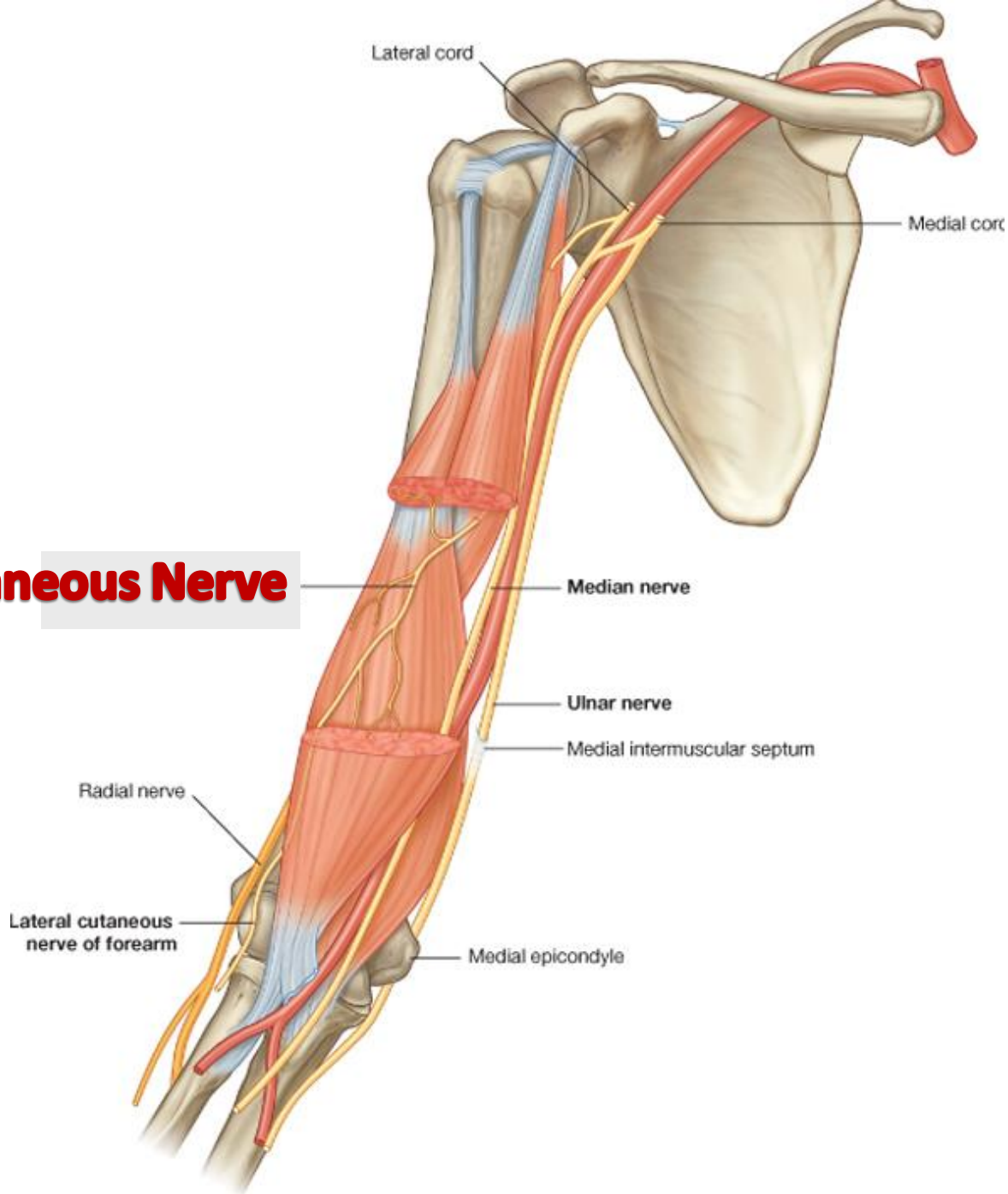

Posterior compartment of Arm

I. **Muscles**: 1 muscle with 3 heads.

II. **Nerve supply** : Radial nerve.

III. **Arterial supply** :profunda brachii artery.

IV. **Main action** : Extends elbow.

REVIEW

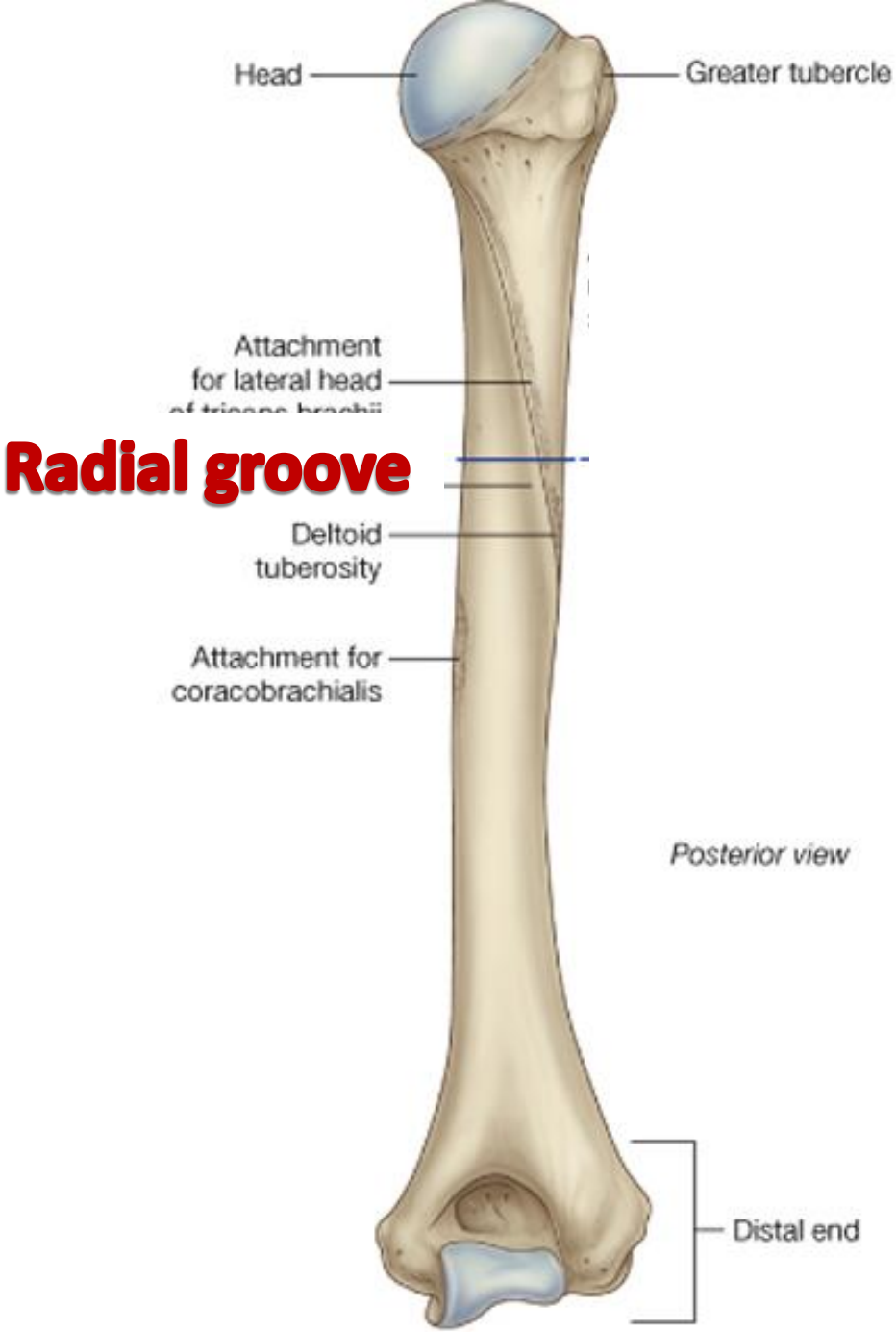

Both Radial nerve and profunda artery passes through the RADIAL GROOVE

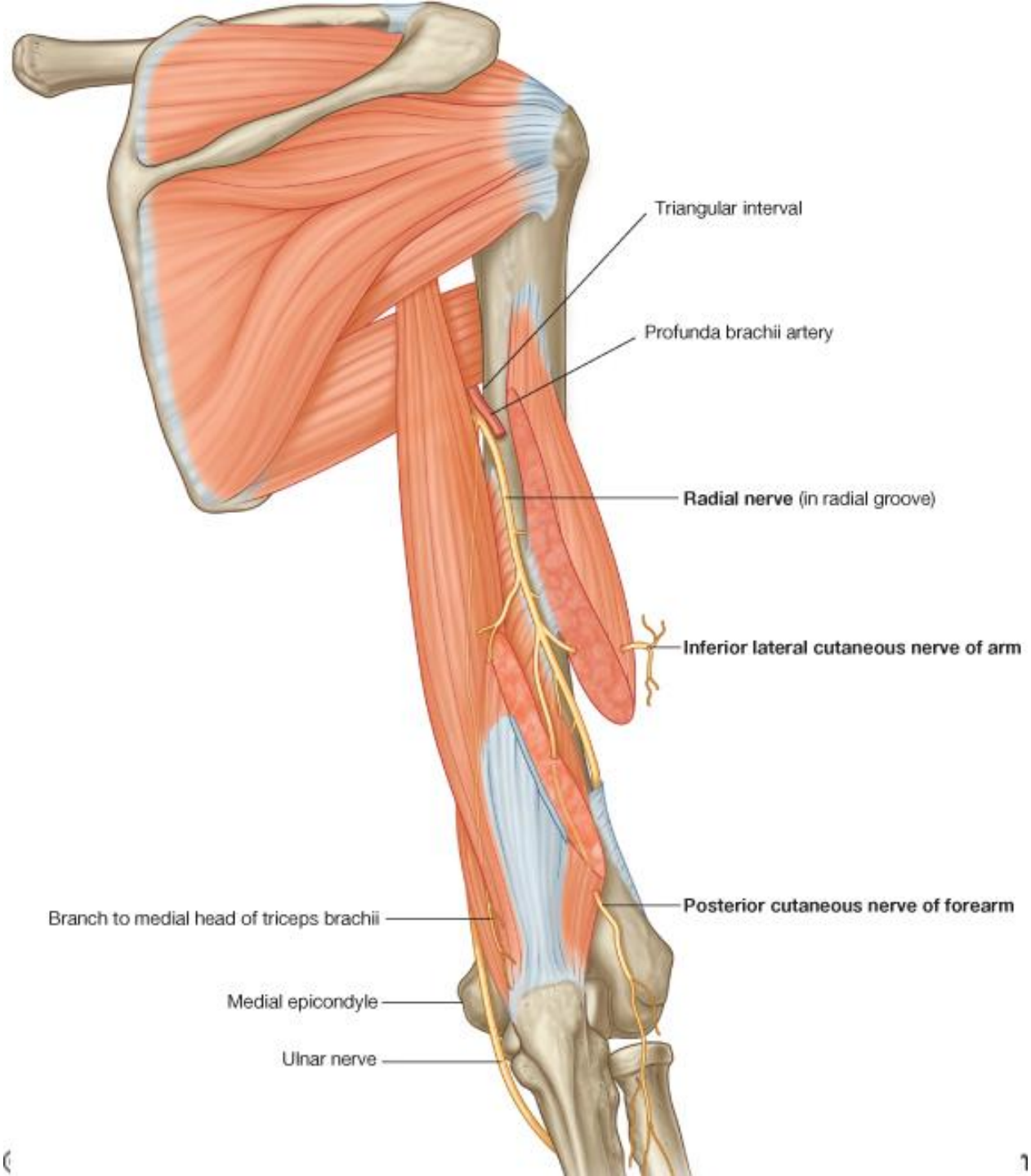
Triangular interval
Profunda brachii artery
Radial nerve (in radial groove)
Inferior lateral cutaneous nerve of arm
Posterior cutaneous nerve of forearm
Branch to medial head of triceps brachii
Medial epicondyle
Ulnar nerve

Triceps

Three heads

Triceps

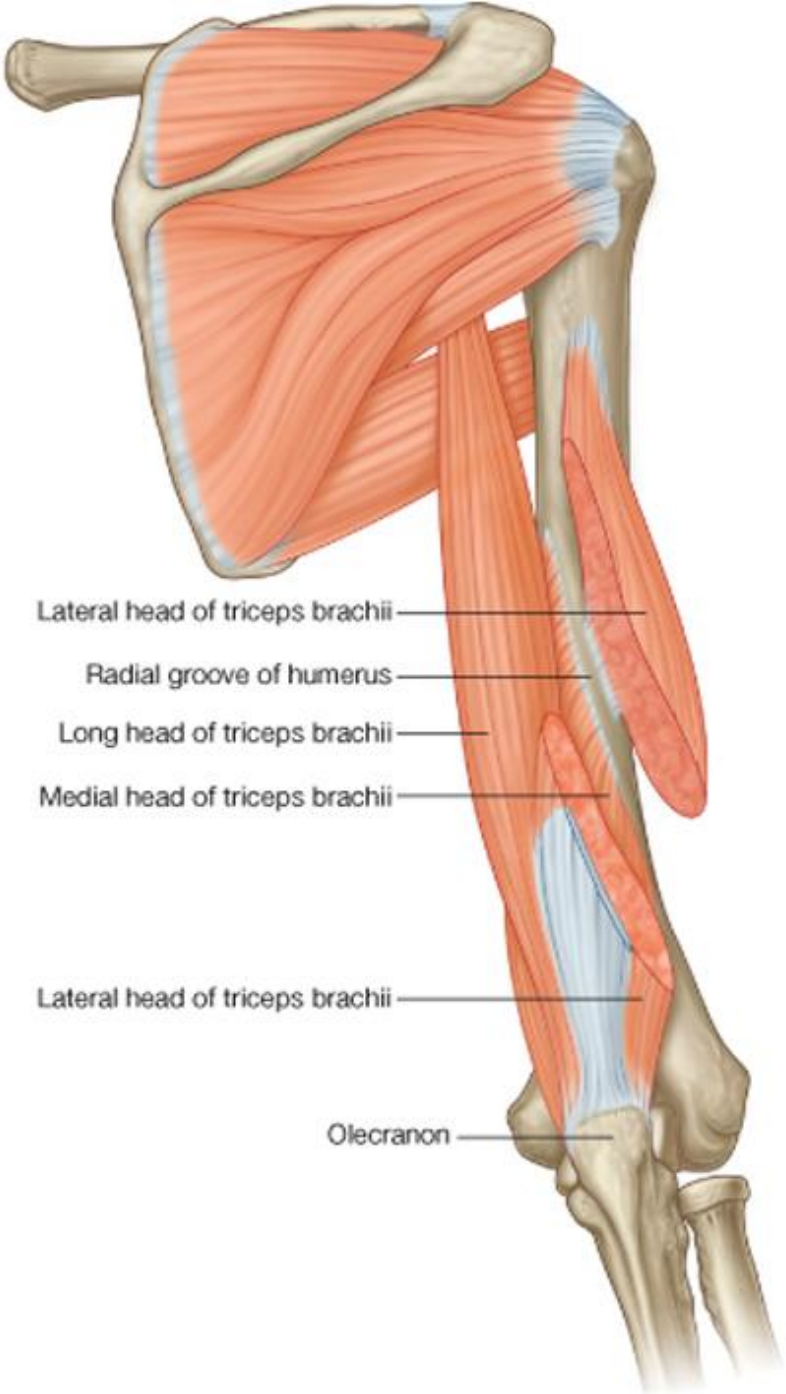

Origin :

Long head : Infraglenoid tubercle of scapula.

Lateral head : Upper half of posterior surface of shaft of humerus

Medial head : Lower half of posterior surface of shaft of humerus

Insertion:

Olecranon process of ulna

Anastomosis

connections between blood vessels

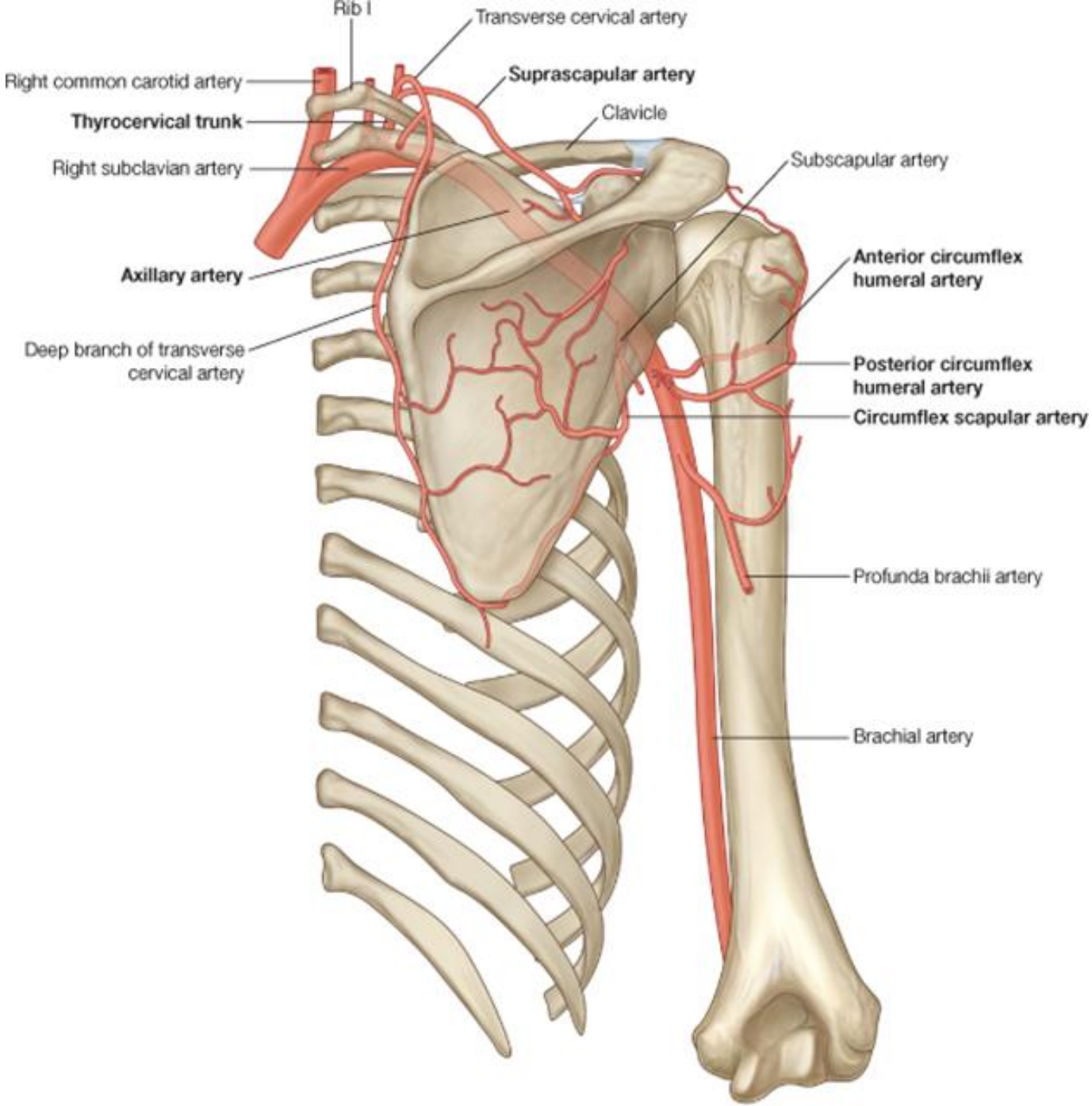

Veins of the upper limb

(I).Superficial Veins: lie in the superficial fascia. used for intravenous injections in clinical settings. :

- Cephalic vein
- Basilic vein
- Median cubital vein

(II).Deep veins : USUALLY accompany arteries.

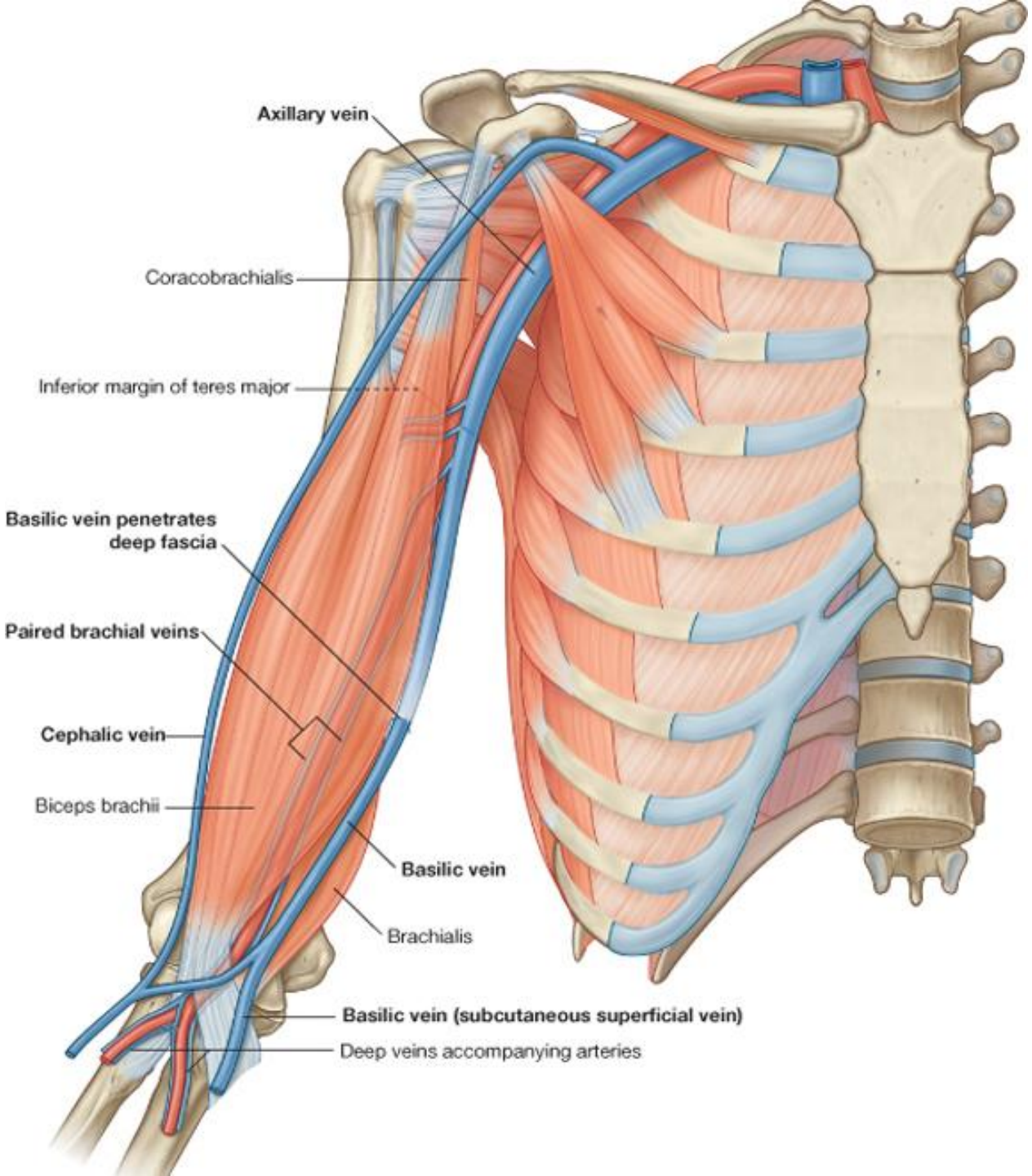
Axillary vein
Coracobrachialis
Inferior margin of teres major
Basilic vein penetrates deep fascia
Paired brachial veins
Cephalic vein
Biceps brachii
Basilic vein
Brachialis
Basilic vein (subcutaneous superficial vein)
Deep veins accompanying arteries

often used for venipuncture

median cubital vein

Cephalic

Basilic +veins of brachial artery >>> Axillary vein

@ lower border of the teres major muscle

The Cubital Fossa

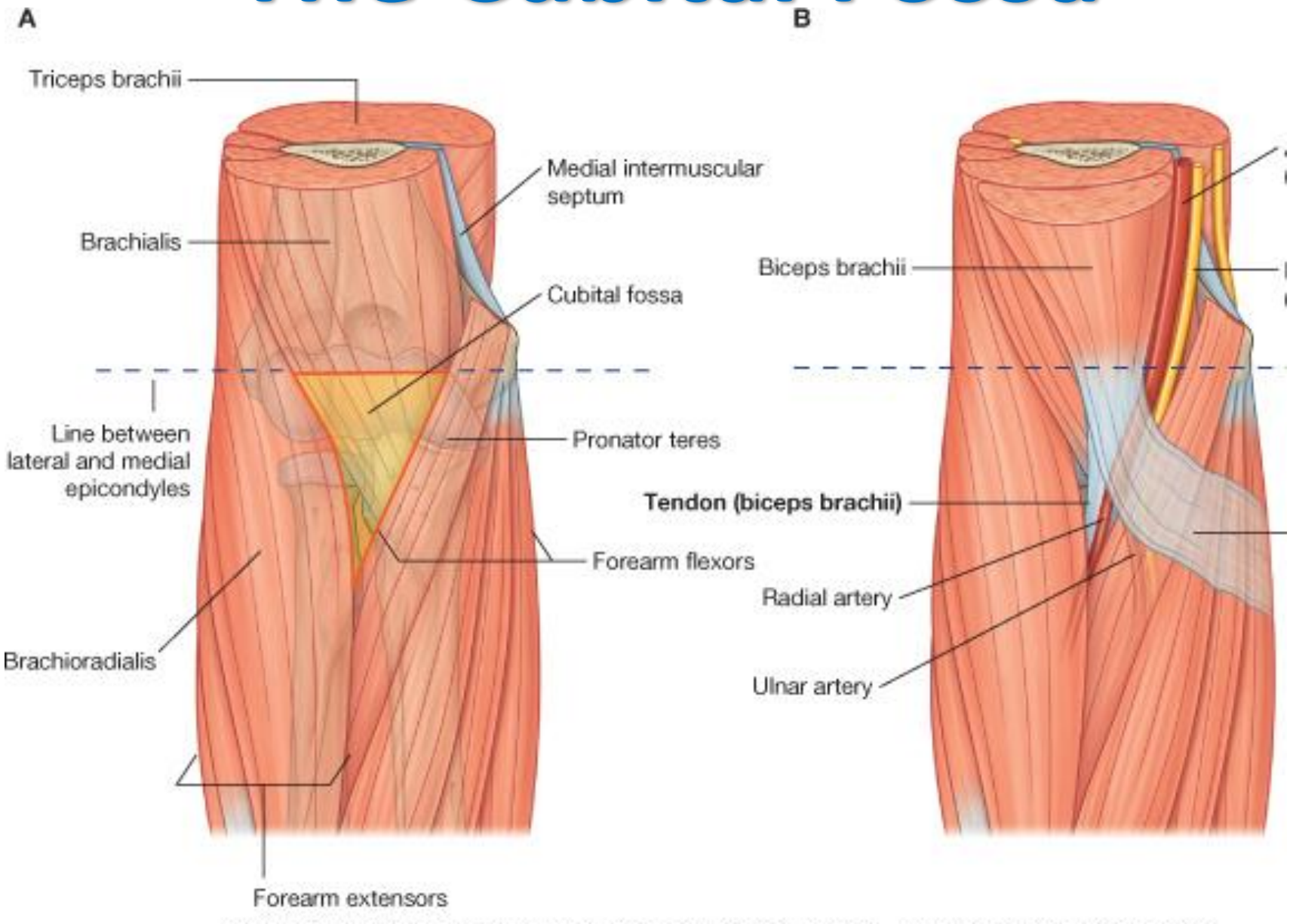

- **triangular depression that lies in front of the elbow**

- **Boundaries**

Laterally: The brachioradialis muscle
Medially: The pronator teres muscle

The base of the triangle is formed by an imaginary line drawn between the two epicondyles of the humerus

The floor of the fossa is formed by the supinator muscle laterally and the brachialis muscle medially

The roof is formed by skin and fascia and is reinforced by the bicipital aponeurosis.

Contents:

"Really Need Booze To Be At My Nicest"

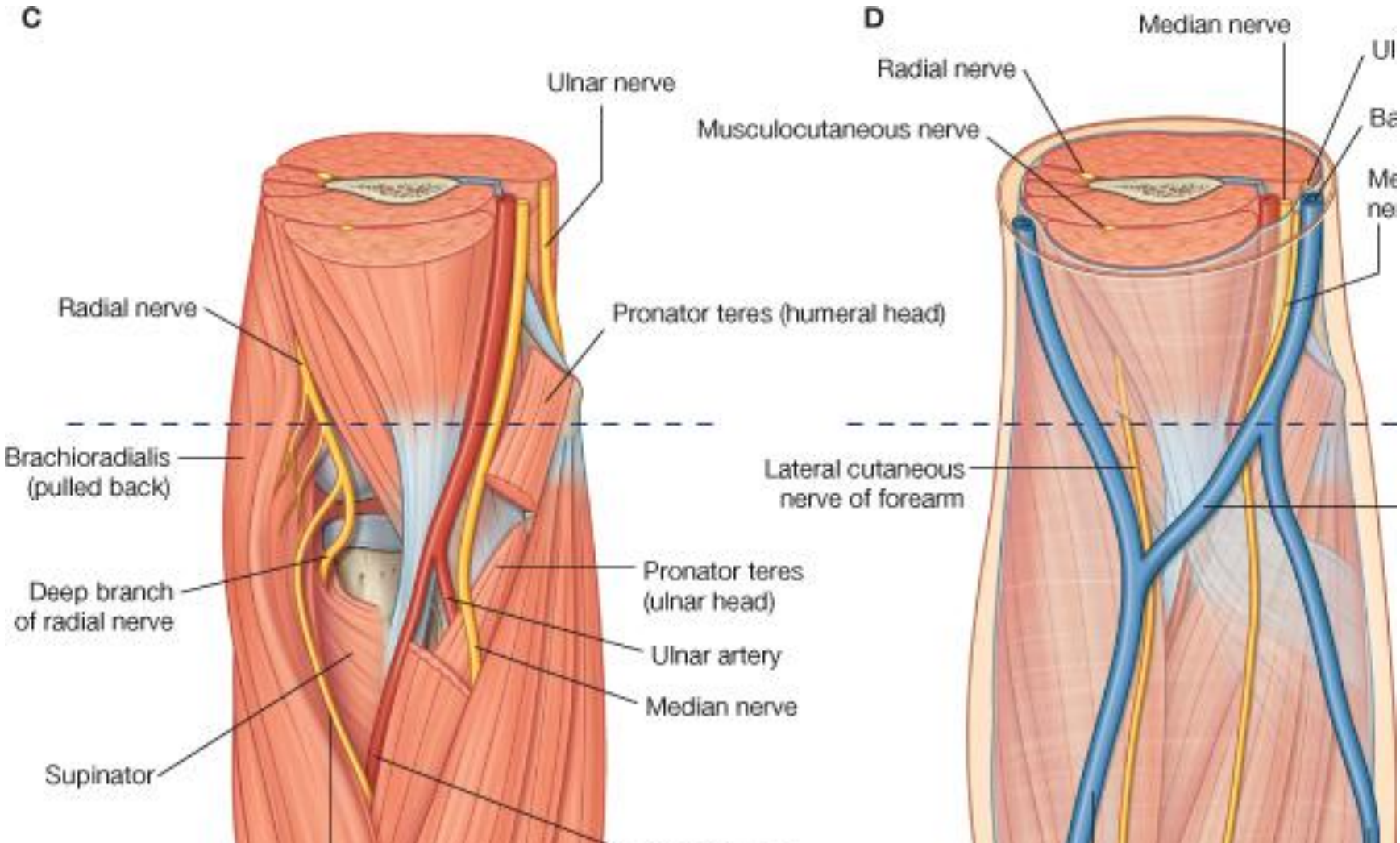

Thank you :’D

Have a break ..