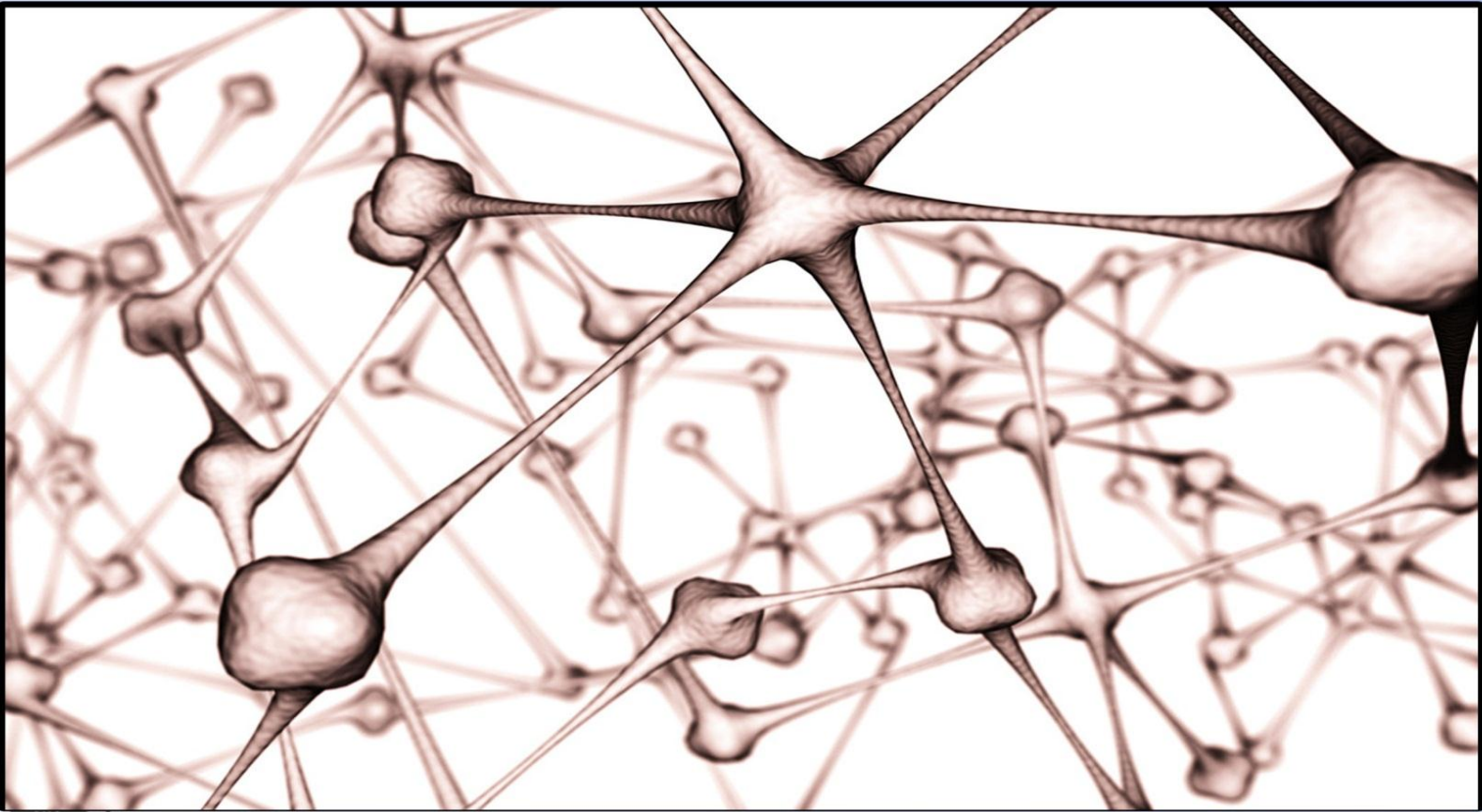


Anatomy Past Papers

لجان الدفقات - كلية الطب - ٢٠١١م



Lajneh Medcom



www.JUDoctors.com



078- 77 25 861

+1 Add Friend

★+ Bookmark

👤+ Add Contact



Scan me!

1. All of the following muscles have double innervations except:

- a- Brachialis
- b- Flexor digitorum profundus
- c- Trapezius
- d- Pectoralis major
- e- Subscapularis

2. You can't put your hand over your head to touch the tip of the other shoulder when an injury happens to which nerve of the following:

- a- Thoracodorsal
- b- Long thoracic
- c- Suprascapular
- d- Subscapular
- e- Pectoral

3. You can't touch the tip of the other shoulder when an injury happens to which nerve of the following:

- a- Thoracodorsal
- b- Long thoracic
- c- Suprascapular
- d- Subscapular
- e- Pectoral

4. Which of the following structure doesn't pierce the clavipectoral fascia:

- a- Cephalic vein
- b- Lymphatic vessels
- c- Lateral thoracic art.
- d- Thoracoacromial art.

e- Lateral pectoral nerve

5. All of the following muscles are pierced by nerves except:

- a- Flexor carpi ulnaris
- b- Pronator teres
- c- Supinator
- d- Coracobrachialis
- e- Brachialis

6. All of the following are related to the bicipital sulcus except:

- a- Lower subscapular nerve
- b- Long head of biceps
- c- Musculocutaneous nerve
- d- Upper subscapular nerve
- e- Thoracodorsal nerve

7. Which of the following doesn't happen at the level of insertion of coracobrachialis:

- a- Ulnar nerve pierces the medial intermuscular septum
- b- Basilic vein pierces the deep fascia
- c- Deltoid inserts into the deltoid tuberosity
- d- Median nerve crosses the brachial art.
- e- Radial nerve pierces the lateral intermuscular septum

8. You can't make an "O" shape with your thumb if an injury happens to:

- a- Ulnar nerve

- b- Median nerve
- c- Radial nerve
- d- Musculocutaneous nerve
- e- Axillary nerve

9. The skin of the index finger is innervated by:

- a- Median nerve
- b- Radial nerve
- c- Ulnar nerve
- d- median & radial nerves

10. Which muscle /muscles abduct the shoulder up to 90°:

- a- Deltoid and supraspinatus
- b- Deltoid
- c- Trapezius
- d- Deltoid and infraspinatus

11. All the following are from the posterior wall of Axilla
Except:

- a- Scapula
- b- subscapularis
- c- Teres major
- d- Latissimus dorsi
- e- Teres minor

12. Which of the following means above stomach:

- a- Hypogastric
- b- Antigastric
- c- Epigastric
- d- Gastritis
- e- Gastectomy

13. Which of the following is wrong about ulnar nerve:

- a- Originates from medial cord
- b- Doesn't supply the anterior compartment of the upper arm
- c- Passes anteriorly to the medial epicondyle of humerus
- d- Supplies one and half muscles of the forearm
- e- Passes lateral to pisiform

14. The plane that divide the body into anterior and posterior parts is :

- a- Midsagittal
- b- Sagittal
- c- Horizontal
- d- Coronal

15. Which one wrong about bones' shape :

- a- Scapula-flat bone
- b- Femur – long bone
- c- Vertebra – sesamoid bone
- d- Wrist – short bone

16. If you want to say near the trunk you say :

- a- Anterior
- b- Proximal
- c- Posterior
- d- Superior

17. Which of the following wrong about median nerve :

- a- Supplies all the anterior compartment of forearm except one & half muscles
- b- It is above Palmaris longus
- c- It supplies thenar muscles and half the lumbrical muscles
- d- Supplies nothing in the brachium

18. A common site of Implantation :

- a- anterior wall of uterine cavity
- b- Fundus of uterus
- c- Posterior wall of uterine cavity
- d- Ovary
- e- Uterine tube

19. A common site of fertilization :

- a- Cervical canal
- b- Ampulla
- c- Isthmus
- d- Uterine cavity

20. Which of the following secretes fructose-rich fluid :

- a- Prostate
- b- Vas deferens
- c- Epididymis
- d- Seminal vesicle
- e- Testis

21. Which of the following is wrong about oogenesis :

- a- Oogonia is formed by the end of the 5th week
- b- Oogonia reach the maximum number by the 7th M
- c- Near birth 1ry oocytes enter diplotene stage and remain until menopause

22. The step in Meiosis that gives the genetically different cells :

- a- Duplication of chromosomes
- b- In Metaphase II chromosomes aligned at equator
- c- Reshuffling and crossing over the chromosomes

23. Which of the following is wrong:

- a. Utrine tube about 4 inch long
- b. External Os. is transverse in a nullipara woman
- c. The normal position of the uterus is enteverted

24. Which of the following is wrong about prostate:

- a- It is below urinary bladder
- b- Pyramidal in shape
- c- It secretes acidic fluid to neutralize vaginal secretion
- d- Formed of lobes

25. Which is wrong about spinal cord:

- a- It is divided into 31 segments
- b- White matter is full of axons
- c- Ventral root is motor
- d- Spinal nerve is formed of motor fibers

26. Which of the following is wrong about the spinal cord:

- a- Located inside the vertebral column
- b- Extending from the base of the skull
- c- It ends at L3/L4 vertebral desk
- d- It has 2 enlargements

27. Which statement is wrong about hand:

- a- Lumbr muscles for writing position
- b Superficial palmar arch is mainly contributed by ulnar artery
- c- Deep palmar arch is mainly contributed by ulnar artery
- d- Medial nerve and ulnar nerve supply it

28. Which of the following is mismatched :

- a. Medial cubital vein – rarely used to obtain blood
- b. Brachial artery – starts at lower border of teres major
- c- Axillary nerve – supplies deltoid and teres minor muscles

ANSWERS:

QUE	ANS	QUE	ANS
1	c	15	c
2	b	16	b
3	e	17	b
4	c	18	c
5	e	19	b
6	d	20	d
7	e	21	c
8	b	22	c
9	d	23	b
10	a	24	c
11	e	25	d
12	c	26	c
13	c	27	c
14	d	28	a

True or False?

1. The eye is medial to the ear.
2. The elbow is proximal to the shoulder.
3. If the spine of the scapula is followed laterally, it becomes the coracoid process.
4. The scapula lies at the posterolateral aspect of the chest wall between 2nd & 7th ribs.
5. The serratus anterior is inserted into the medial border of the scapula?
6. Pectoralis major, latissimus dorsi, and teres major are supplied by branches of posterior cord.
7. Pectoralis major supplied by the medial and lateral pectoral nerves (from medial and lateral cords).
8. All the following muscles are supplied by Suprascapular nerve (from upper trunk C5,C6) : Supraspinatus , Infraspinatus , Teres minor.
9. The Axillary nerve supplies Deltoid muscle, Teres minor muscle, the skin area down ½ of deltoid, and shoulder joint.
10. The articular transverse ligament is outside the capsule of the shoulder joint.

11. The long head of biceps is intracapsular but extrasynovial.
12. The radial nerve pierces the lateral intermuscular septum and appears between brachialis and brachioradialis muscles then it supplies important muscle called extensor carpi radialis longus.
13. At the insertion of coracobrachialis, the radial nerve pierces the lateral intermuscular septum.
14. At the level of the insertion of coracobrachialis, the basilic vein pierces the deep fascia.
15. The ulnar nerve runs inside the carpal tunnel.
16. In carpal tunnel syndrome the patient is expected to suffer from paresthesia (abnormal sensation e.g. pins and needles, burn in the skin of the lateral 3 ½ fingers as well as in the skin over the Thenar eminence).
17. Injury to the median nerve near the elbow has more effects than injury to the ulnar nerve.
18. The Adductor pollicis longus is supplied by ulnar nerve.
19. Both Flexor pollicis longus & Flexor pollicis brevis are supplied by median nerve.
20. All palmar & dorsal interossei are supplied by ulnar nerve.

21. Lumbrical muscles have the same nerve supply as flexor digitorum profundus.

22. Winged scapula results from injury to the thoracodorsal nerve.

23. The axilla communicates with the neck through a canal which passes posterior To the clavicle.

24. The lower limit if the axilla is the lower border of teres major.

25. The musculocutaneous nerve (C5, 6, 7) supplied 3 muscles and ends at the medial cutaneous nerve of forearm.

26. The muscle of climbing is the latissimus dorsi.

27. The medial half of flexor digitorum superficialis (which acts on the ring and little fingers) is supplied by the ulnar nerve.

28. The tendons of the flexor digitorum profundus pierce those of the flexor digitorum superficialis and insert into the distal phalanges of the medial four fingers.

29. Following the interruption (cutting) of median nerve, the patient was unable to flex the index and middle fingers.

30. The pulse of brachial artery is felt immediately medial to the tendon of biceps muscle.

31. The median cubital vein is separated from brachial artery by the bicipital apponeurosis.

32. The median nerve is outside the cubital fossa behind the medial epicondyle.

33. The most common dislocation of shoulder joint is posterior.

34. The most important factor in stabilizing the shoulder joint is the bony factor.

35. Muscles that adduct and medially rotate the shoulder joint are attached to the bicipital groove.

36. All the following 3 muscles are supplied by branches of posterior cord: Pectoralis Major, Latissimus Dorsi, Teres major.

37. Spermatation is related to Spermatogenesis.

38. In Oogenesis, the Oogonia reach a max number of 7 million cells at the 5th month.

39. 2nd meiotic division occurs after fertilization.

40. The genetic sex is determined after fertilization.

ANSWERS:

Q	A	Q	A	Q	A	Q	A
1	T	11	T	21	T	31	T
2	F	12	T	22	T	32	F
3	F	13	F	23	T	33	F
4	T	14	T	24	T	34	F
5	T	15	F	25	F	35	T
6	F	16	T	26	T	36	F
7	T	17	T	27	T	37	F
8	F	18	F	28	T	38	F
9	T	19	T	29	T	39	T
10	F	20	T	30	T	40	T

Fill in the Blanks

1. The lateral end of the clavicle articulates with ... to form

2. 3 muscles are inserted into the bicipital groove of the Humerus: ... , ... , &

3. 3 muscles are inserted into the greater tuberosity of Humerus: ... , ... , &

4. In the spiral groove the radial nerve gives two muscular branches: ... & It also gives 2 cutaneous branches: ... &

5. Injury (cutting) to the median nerve near the wrist will result in the following effects: ... &

6. In order to rise the arm above the head, i.e. to do abduction beyond 90 degrees, you need the synergism between 2 muscles which are: ... &

7. In the flexor compartment of the forearm there are two pronator muscles: ... &

8. The previous muscles are supplied by ... Nerve.

9. Muscles responsible for Supination are innervated by ... & ... Nerves.

10. Muscles responsible for Pronation are innervated by... nerve.

11. The three thenar muscles are: ... , ... ,& They are innervated by ... Nerve.

12. Two structures inside the shoulder joint: ... &

ANSWERS:

1. Acromion process, acromioclavicular joint.
2. Pectoralis Major, Latissimus Dorsi, Teres Major.
3. Supraspinatus, Infraspinatus, Teres minor.
4. Medial & lateral heads of triceps / Inferior lateral cutaneous nerve of arm & posterior cutaneous nerve of forearm.
5. Paresthesia of the lateral 3 ½ fingers as well as in the skin over the thenar eminence.
6. Trapezius & Serratus anterior.
7. Pronator teres & pronator quadratus.
8. Median.
9. Musculocutaneous & Median
10. Radial.
11. Opponens metacarpal pollicis & Abductor pollicis brevis & Flexor pollicis brevis / Median.
12. Long head of biceps & Lateral ligament (special type of ligament).

If you can
DREAM IT
you can do it

Pairs: Suitable or Unsuitable?

1. The origin of deltoid: the insertion of trapezius.
2. Quadrangular space: axillary nerve.
3. Long head of triceps: quadrangular space.
4. Teres major: subscapularis.
5. Deltoid: Shoulder joint.
6. Acromioclavicular joint: Coracoclavicular ligament.
7. Profunda brachii artery: Radial nerve.
8. Interosseous membrane: Deep branches of radial and median nerve.
9. Inferior ulnar collateral artery: ulnar nerve.

ANSWERS:

Q	A	Q	A	Q	A
1	Suit.	4	Suit.	7	Suit.
2	Suit.	5	Suit.	8	Suit.
3	Suit.	6	Unsuit.	9	Suit.

ملحوظات

- موعد الامتحان: يوم السبت 4/7 في مجمع القاعات الطبية، الساعة التاسعة والنصف صباحا في مجمع القاعات الطبية .
- المادة : من بداية المادة إلى نهاية محاضرة يوم الخميس 3/29 (تشریح وعلم أجنة).
- الامتحان يتكون من 45 سؤالاً بنمط الاختيار من متعدد؛ 30 سؤالاً على مادة التشریح، و15 سؤالاً على مادة الأجنة تقريباً، موحدة لجميع الشعب.
- ودمتم بود.

