3rd year

University of Jordan
Faculty of Medicine

Medical Committee
The University of Jordan

Handout

3

- [ ] Slides
- [ ] Sheet
- [x] Handout

Title: _____

Professor: Dr.Faraj Bustami

Date: _____

Sheet written by:

_____

Anatomy

Price: 40

9/3/2015

Design:
Waseem Kamal

Unilateral lesion of the glossopharyngeal nerve manifested by the following signs:

(1) Loss of pharyngeal (gag) reflex
(2) Loss of carotid sinus reflex
(3) loss of taste in posterior third of tongue (vallate papillae)

⇓

Gag Reflex → Touching the posterior wall of the pharynx by a spatula is followed by contraction of the pharyngeal constrictors and elevation of the pharynx ⇒ The afferent fibres for this reflex are sensory fibres of the glossopharyngeal nerve ⇒ After entering the solitary tract, synaptic connections are made with the nucleus ambiguus which sends ⇒ efferent fibres to the striated muscles of the pharynx (through cranial part of accessory N. which joins the vagus nerve.

⇓

Stimulation of touch Receptors in the posterior wall of the oropharynx → impulses run along the glossopharyngeal nerve (9) → Solitary tract in medulla oblongata

* Remember that the Gag reflex is absent in comatosed patient → epiglottis does not close the inlet of larynx → vomitus enters Respiratory passages

↓

nucleus ambiguus in medulla → glossopharyngeal N. / cranial accessory along vagus N. → Contraction of pharyngeal muscles

* Carotid sinus reflex → refer to CVS physiology

* Carotid sinus Synchrome ?? Hypersensitive carotid sinus ------> attacks of syncope brought on by light external pressure over the sinus

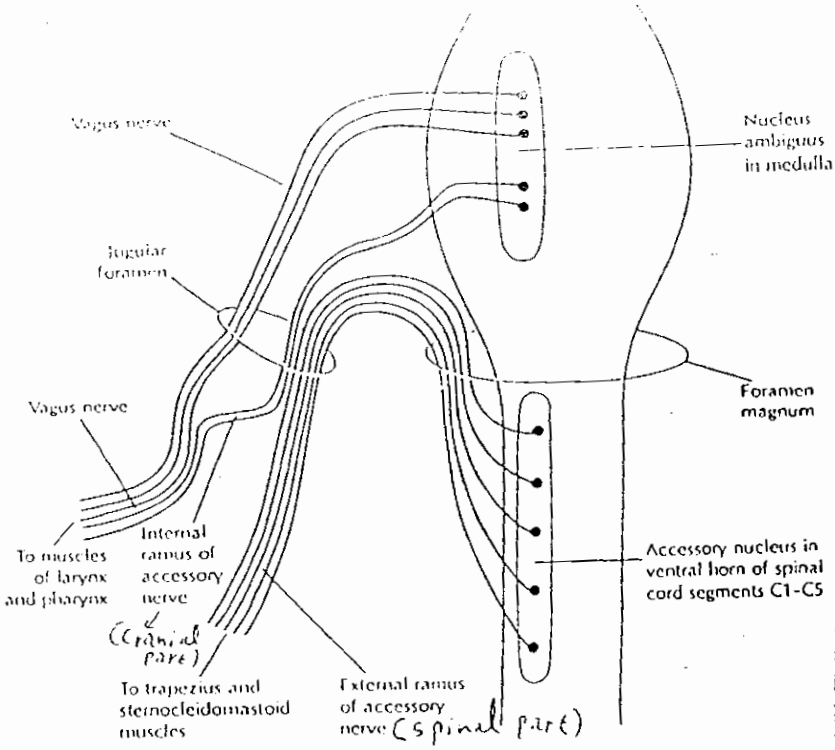

Figure 8-13. Spinal and cranial roots of the accessory nerve.

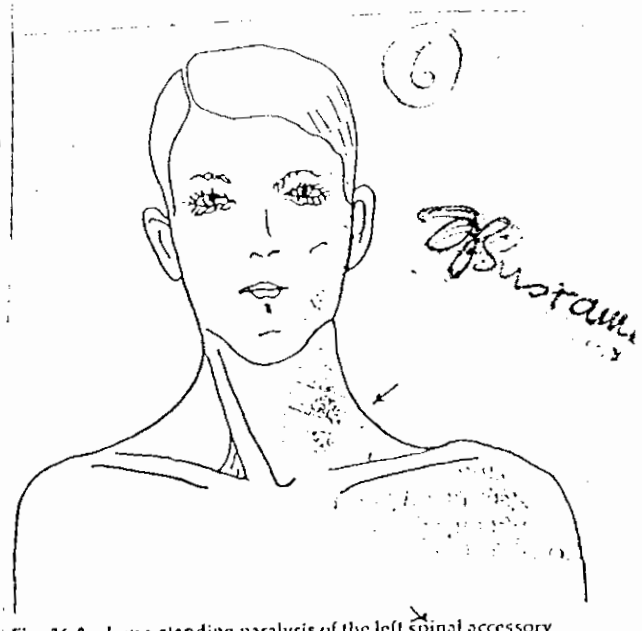

Fig. 36-8 Long-standing paralysis of the left spinal accessory nerve. The trapezius (arrow) and sternomastoid have wasted and the clavicle is lower on the affected side. (The trapezius normally helps to support the weight of the limb.)

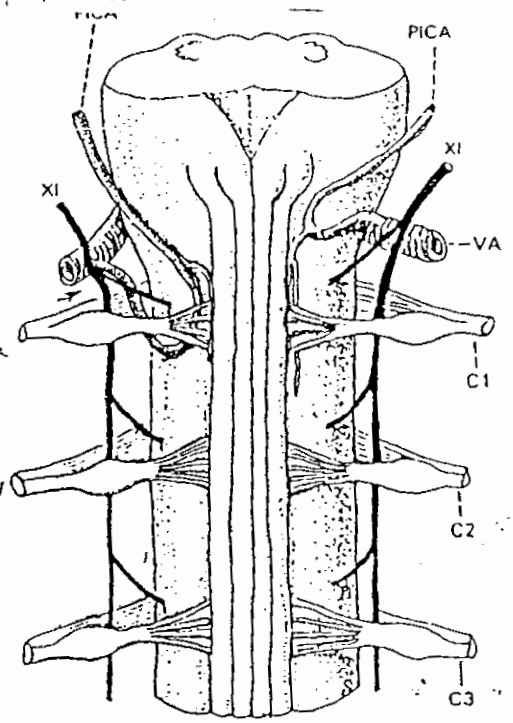

Fig. 36-9 Posterior view of medulla and spinal cord. A low-lying posterior inferior cerebellar artery (PICA) is stretching the left spinal accessory nerve (arrow). VA, vertebral artery. (Adapted from Hagenah et al., 1983).

* The Accessory nerve has two roots : a spinal and a cranial

* The spinal root arises from the accessory nucleus which is a ribbon of α and γ motor neurons extending through the upper 5 segments of the spinal cord in the base of the anterior horn. From their cells of origin, the rootlets course dorsolaterally and exit from the lateral part of the spinal cord between the dorsal and ventral roots → Enters the cranial cavity through the foramen magnum and → leaves it through the jugular foramen. It supplies the sternocleidomastoid and trapezius muscles.

The cranial root arises from the caudal ain of the nucleus ambiguus in the medulla oblongata. Its rootlets are those of the vagus nerve. Thus the cranial root of the accessory nerve is in essence a part of the vagus nerve, and distributed through its pharyngeal and laryngeal branches ????.

Applied anatomy : Isolated paralysis of the spinal accessory nerve may result from a stab wound in the neck (Post Δ) or from surgical injury during removal of cancerous lymph nodes. If the lesion is proximal to the sternocleidomastoid ⟹ atrophy and paralysis of this muscle ⟹ weakness on turning the head to the side opposite the lesion. Atrophy of trapezius → characteristic scalloping of the contour of the neck.

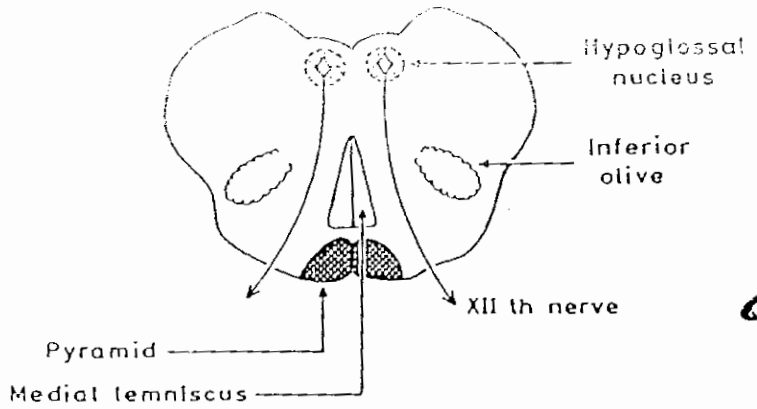

Figure 6.21. Schematic diagram of the origin and intramedullary course of filaments of the hypoglossal nerve.

7 A

Ofsuotami

Hypoglossal Nerve

* Contains Primarily Somatic motor nerve fibres (GSE) that innervate the intrinsic and extrinsic muscles of the tongue (Except Palatoglossus). These muscles are derived from the occipital myotomes. It also contains afferent proprioceptive fibres from the muscle spindles of the tongue muscles.
* The nucleus of the hypoglossal N. ⟹ Extends throughout the medulla oblongata, except for its most rostral and caudal levels. It is divided into cells groups corresponding to the tongue muscles they supply. The root fibres of the nerve course in the medulla oblongata lateral to the medial lemniscus and emerge on the ventral surface of the medulla between the pyramid and the inferior olive.
* A nuclear or infranuclear lesion of the hypoglossal Nerve ⟹ lower motor neuron lesion of the tongue muscles homolateral (ipsilateral) to the lesion ⟹ manifested by the following:

1. Atrophy of the affected side of the tongue
2. Deviation of the protruding tongue to the atrophic side (Unopposed forward pull of the healthy genioglossus)
3. Fasciculation (spontaneous activity of muscle fibres at rest) is best seen when the tongue is only slightly protruded.

Medial Medullary Syndrome

This syndrome (Fig. 6.26) is caused by occlusion of the anterior spinal artery or the vertebral artery. The affected area usually includes the following.

1. Medial lemniscus
2. Pyramid & Surrounding reticular formation
3. Rootlets of the hypoglossal nerve within the medulla

Neurologic signs resulting from affection of these areas are the following.

1. Contralateral loss of kinesthesia and discriminative touch due to involvement of the medial lemniscus
2. Contralateral paralysis of the upper motor neuron type (weakness, hyperactive reflexes, Babinski sign, and spasticity) due to involvement of the pyramid & Reticulospinal tracts (extrapyramidal)

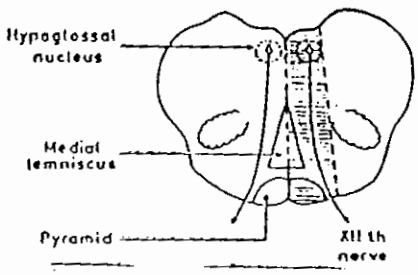

MEDIAL MEDULLARY SYNDROME

1. Paralysis of homolateral half of tongue
2. Contralateral paralysis
3. Contralateral loss of kinesthesia and discriminative touch

3. Lower motor neuron paralysis of the homolateral half of the tongue (weakness, atrophy, and fibrillation)

7 B

Upsurami

Fig. 8.40 Left hypoglossal nerve lesion.

Remember the presence of fasciculations which appear when the patient protrudes his tongue

This atrophy & fasciculation appear early in motor neuron disease, & may be accompanied difficulty in swallowing & nasal regurgitation → Why ???

(dysphagia) especially to fluids

Lateral Medullary Syndrome

This syndrome (Fig. 6.27) is caused by occlusion of the vertebral artery or the posterior inferior cerebellar artery. It is also known as the posterior inferior cerebellar artery (PICA) syndrome or Wallenberg's syndrome. The affected area usually includes the following.

1. Spinal nucleus of the trigeminal nerve and its tract
2. Adjacent spinothalamic tract
3. Nucleus ambiguus
4. Base of the inferior cerebellar peduncle
5. Vestibular nuclei
6. Descending sympathetic fibers from the hypothalamus

Neurologic signs and symptoms resulting from affection of these areas are the following.

1. Loss of pain and temperature sensations from the ipsilateral face due to involvement of the spinal nucleus of the trigeminal and its tract
2. Loss of pain and temperature sensations over the contralateral half of the body due to involvement of the spinothalamic tract
3. Loss of gag reflex, difficulty in swallowing (dysphagia), and difficulty in articulation due to paralysis of pharyngeal muscles supplied by the nucleus ambiguus
4. Loss of coordination (ataxia) due to involvement of the base of the inferior cerebellar peduncle
5. Hallucination of turning (vertigo) due to involvement of the vestibular nuclei
6. Horner's syndrome due to involvement of the descending sym-

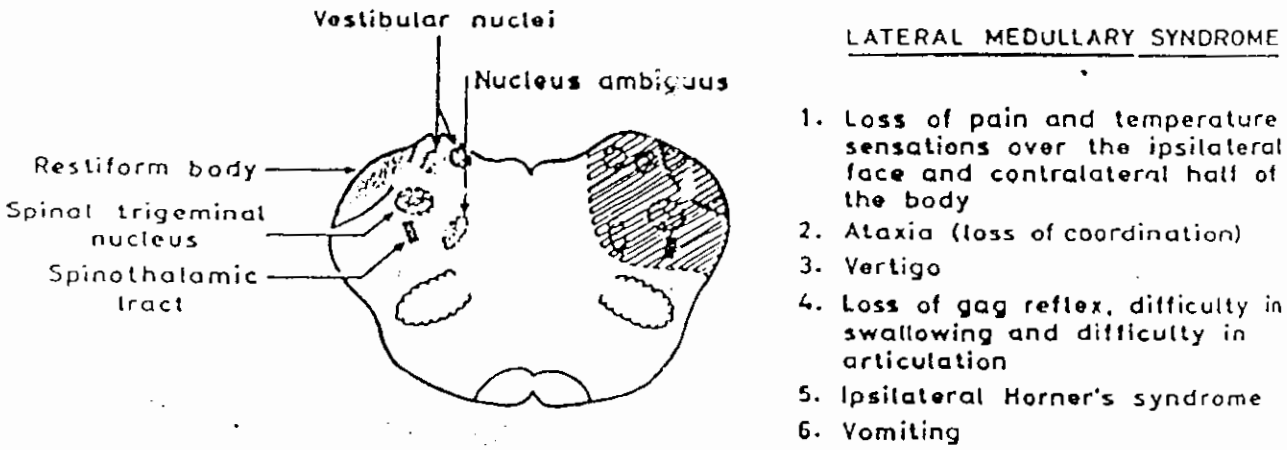

Figure 6.27. Schematic diagram of the medullary areas involved in the lateral medullary syndrome and the resulting clinical manifestations.

Section (I) of Medulla o. At Pyramidal (Motor) decussation

Cuneate nucleus

Gracile nucleus (B)

Gracil fasciculus (C)

Cuneate fasciculus (D)

Spinal tract of trigeminal nerve (E)

Nucleus of spinal tract of V N. (F)

Lateral corticospinal tract (M)

Dorsal spinocerebellar tract (G)

Rubrospinal tract (?)

Lateral and ventral spinothalamic tracts (?)

Ventral spinocerebellar tract (H)

Ventral horn of spinal cord (I)

Medial longitudinal fasciculus (MLF) (J)

* Pyramidal (Motor) decussation (L)

Anterior corticospinal tract (K)

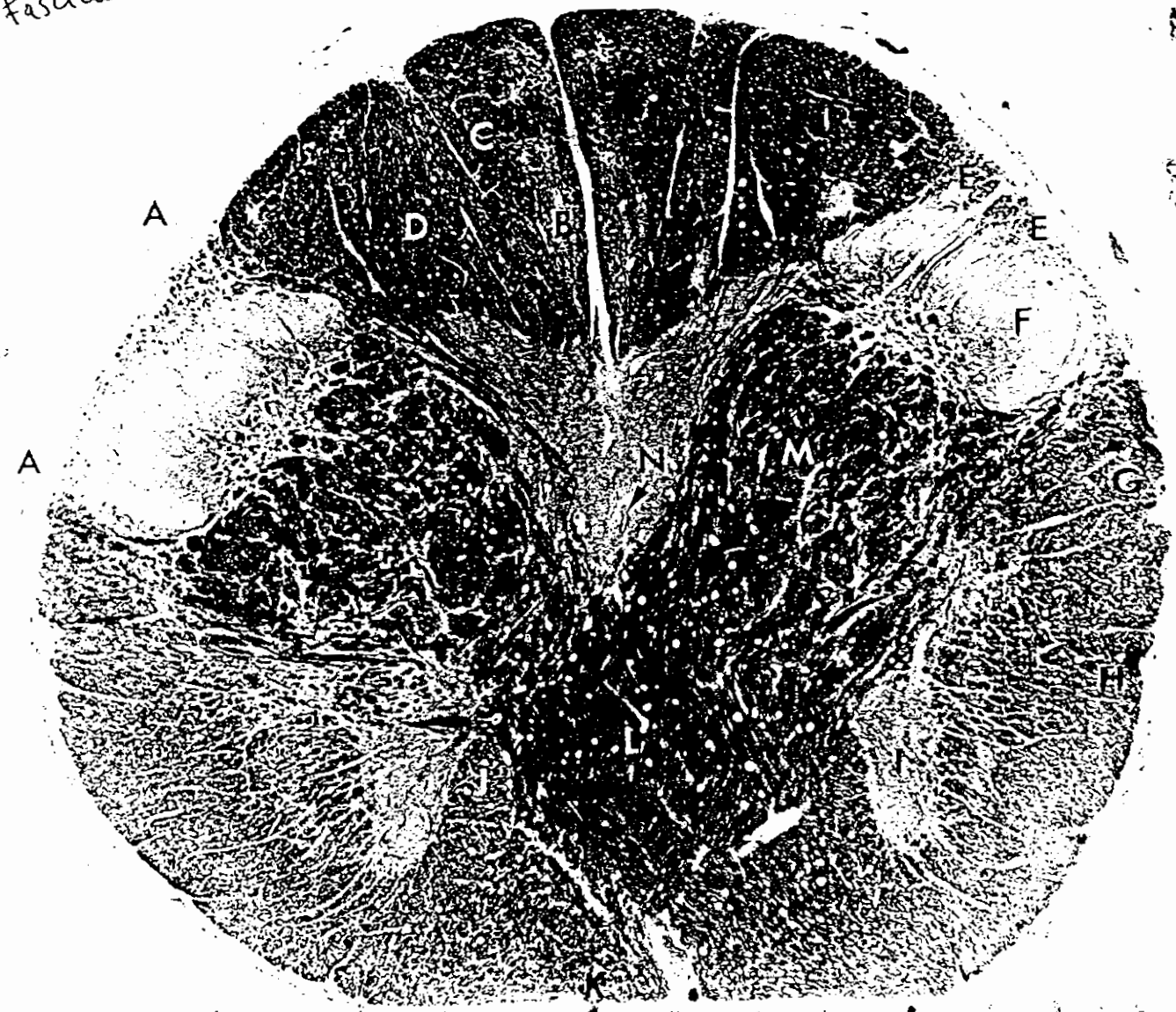

Fasciculus cuneatus (from upper ½ of body)

Fasciculus gracilis (from lower ½ of body)

Nucleus cuneatus

Nucleus gracilis

Spinal tract of trigeminal nerve

Nucleus of spinal tract of trig. n.

Dorsal spino-cerebellar tract

Ventral spino-cerebellar tract

Ventral and lateral spinothalamic tract

Pyramidal tract (Large at this level)

Section of medulla oblongata at the level of *sensory decussation II

O = solitary tract & nuclei
P = dorsal nuc. of vagus
Q = Hypoglossal nucleus

Internal arcuate fibres

Medial Lemniscus (Axons of gracile & cuneate nuclei of opposite side)

* S = Medial longitudinal fasciculus (MLF)

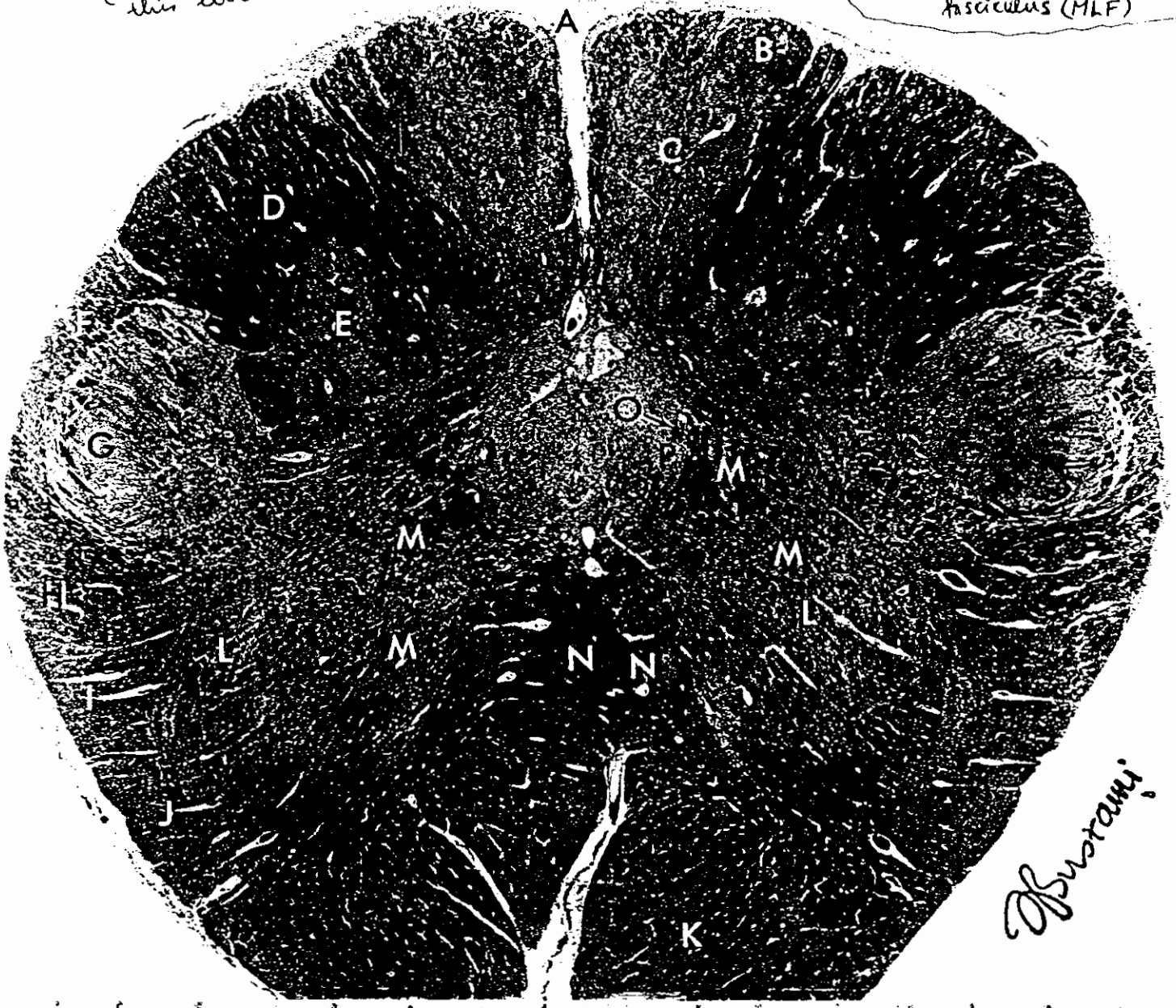

Dorsal (motor) nucleus of vagus nerve

Hypoglossal nucleus

Inferior cerebellar peduncle

Solitary tract and nucleus

Section of medulla oblongata at the level of inferior olive → Open medulla ← III

Bustrom 1991

{Spinal tract of trigeminal nerve

Nucleus of spinal tract of trigeminal nerve

4th ventricle

Medial vestibular nucleus

Inferior " "

(⊖ vestibulospinal tract)

Accessory cuneate nucleus

Medial longitudinal fasciculus (MLF)

Vagus nerve

Reticular formation

*Position of nucleus ambiguus

Cuneate part of medial lemniscus (from upper ½ of body)

Anterior (ventral) spinocerebellar tract (T)

anterior and lateral spinothalamic tract

Gracile part of medial lemniscus (from lower ½ of body)

* Inferior olivary nucleus

* Fibres of Hypoglossal nerve

K = Pyramidal tract (Pyramid)

Z = position of fibres in the pyramidal tract for the face (F), upper limb (U), trunk (T) and lower limb (L)

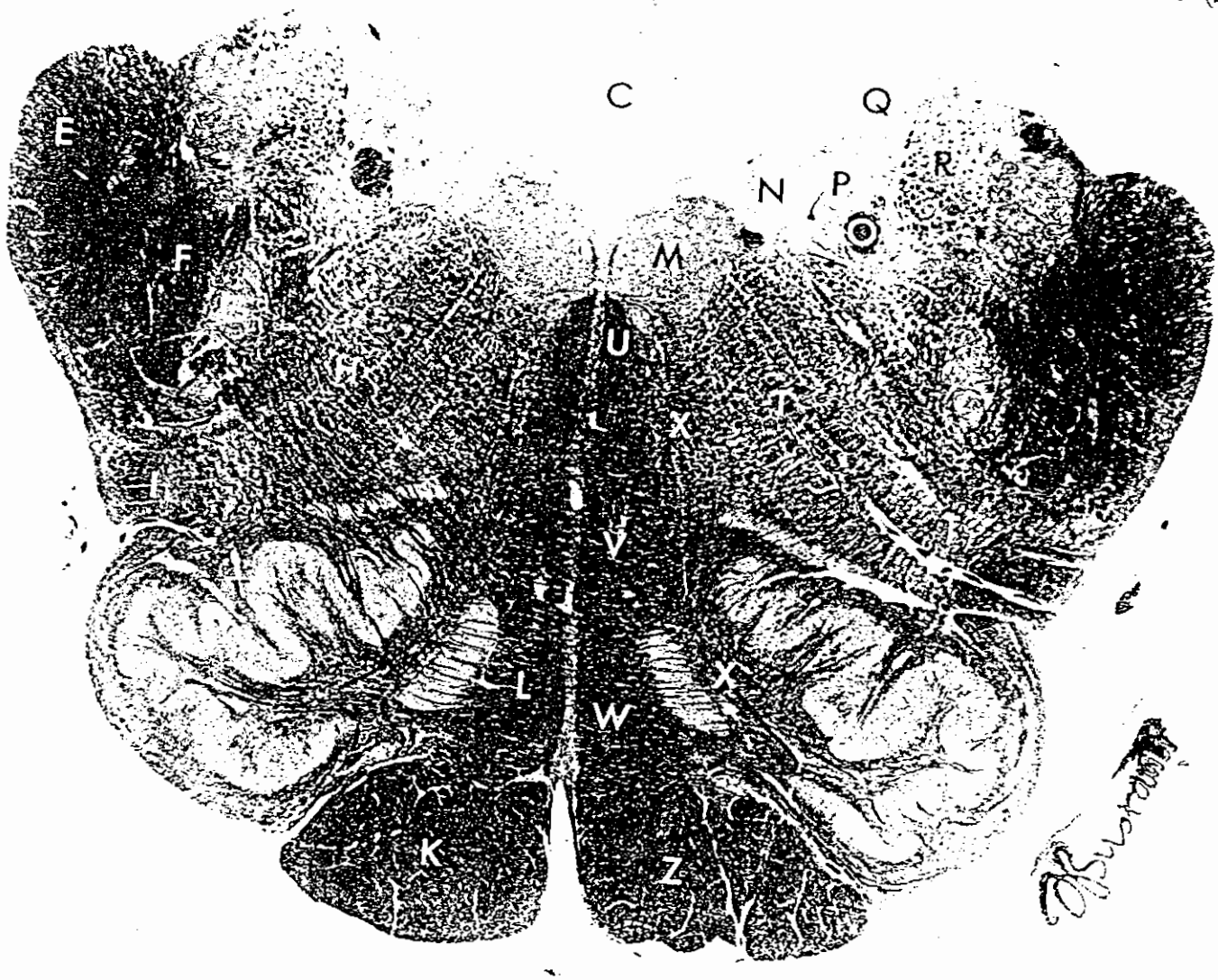

Bustrom

Trigeminal nerve (CN V)

- smaller Efferent part (?)
- larger Afferent »

- Afferent component → GSA → Proprioceptive fibres
  - exteroceptive »

Ebstram

- Exteroceptive fibres have their cell-bodies in the semilunar (trigeminal) ganglion
  - (a) peripheral processes → form → ophthalmic division, maxillary », mandibular » (sensory)
  - (b) Central processes → enter the lateral aspect of the pons & distribute themselves as follows:

Ebstram

→ Some of these fibres descend in the pons, medulla, and down to the level of 2nd or 3rd cervical spinal segment as the → Spinal trigeminal tract. They carry pain & temperature sensation → throughout their course they project upon the neurons of the adjacent spinal trigeminal nucleus

Dorsal trigemino-thalamic tract → TRIGEMINAL LEMNISCUS *

ventral trigeminothalamic tract

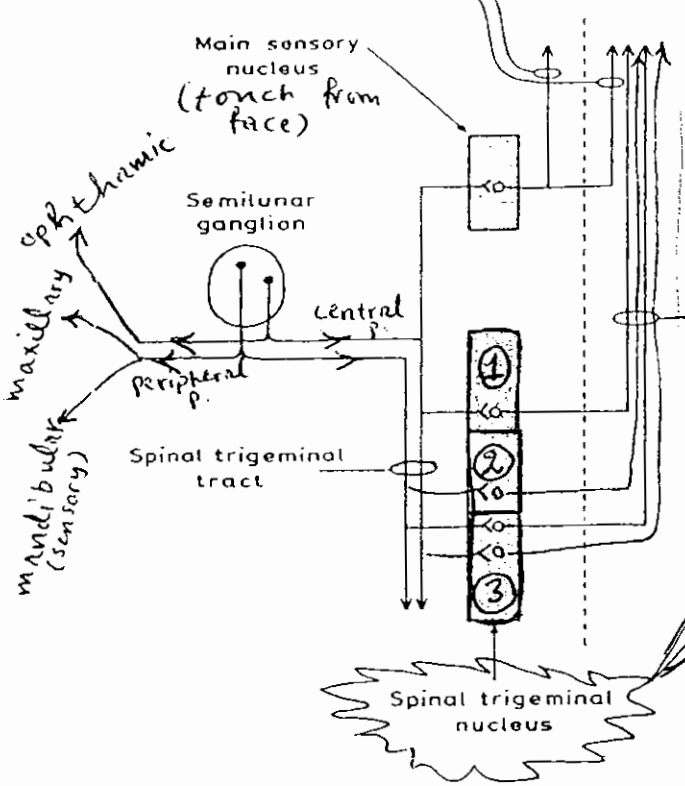

1. Pars oralis (touch from mouth)
2. pars interpolaris (Pain from teeth)
3. pars caudalis

⇓

Touch, pain, temperature

↓

from entire trigeminal area

→ Cornea (Remember < aff. 5, eff. 7 of corneal reflex

→ Face

→ nose

→ mouth

→ external acoustic meatus, middle ear, Eustachian tube

→ skin of neck (via dorsal rami of C_2, C_3)

→ from the dura mater
- above tentorium cerebelli supplied by ophthalmic nerve
- below » » C_2, C_3, Vagus

→ from pharynx & oesophagus

- Axons of neurons in the spinal trigeminal nucleus CROSS the midline & form the (ventral trigemino-thalamic tract → part of trigeminal lemniscus) which courses rostrally to terminate in the thalamus

(10)

Bustami

- Other incoming fibers of the trigeminal nerve bifurcate upon entry to the pons into ascending and descending branches. These fibers convey touch sensation. The descending branches join the spinal tract of the trigeminal nerve and follow the course outlined above. The shorter ascending branches project upon the main sensory nucleus of the trigeminal. From the main sensory nucleus, second order fibers ascend ipsilaterally and contralaterally as the (dorsal trigemino-thalamic tract → another part of trigeminal lemniscus) - - - - - - - - - - rostrally to the thalamus

→ which nucleus of thalamus → VPM (Ventral Postero-medial nucleus → Part of Ventrobasal complex).

→ For the relief of intractable pain → sometimes the spinal tract of the trigeminal nerve is cut surgically,

→ the patient will lose which sensations ← pain? temp.? touch ???

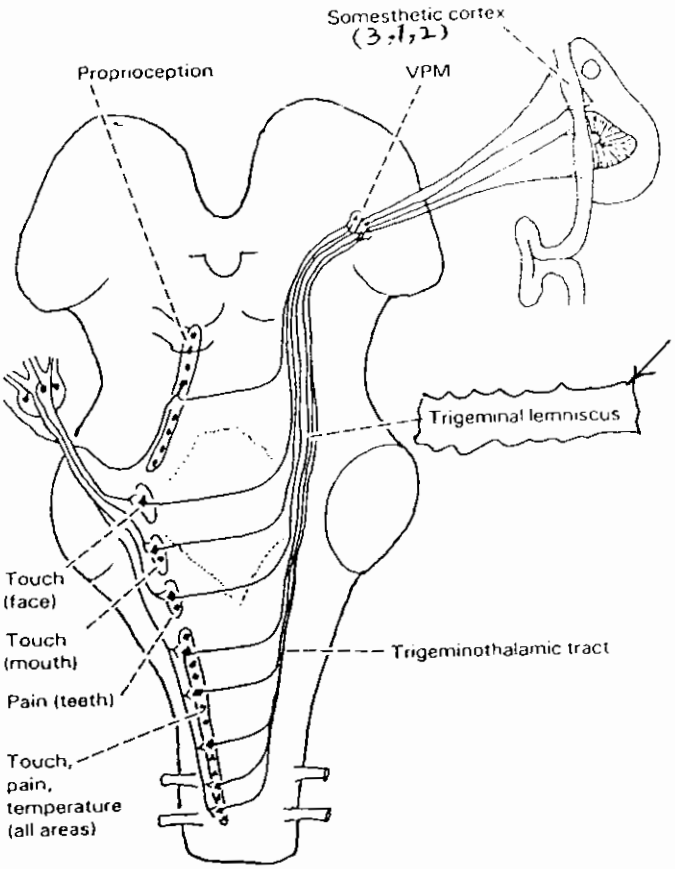

Fig. 34-5 Trigeminal sensory pathways. VPM, ventral posteromedial nucleus of thalamus.

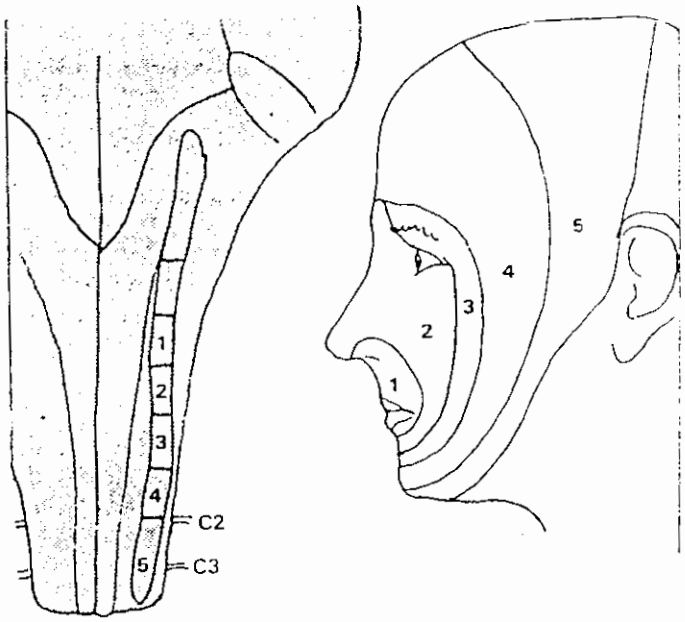

Fig. 34-4 Representation of the face in the pars caudalis of the spinal nucleus of trigeminal nerve. (C1 often has no posterior nerve root.) (Adapted from Sears and Franklin, 1980.)

The principal sensory territories of the pars caudalis are the epithelia of the entire trigeminal area: corneal, facial (epidermis), nasal and oral. The modalities served are pain, temperature, and touch (the tactile fibers are collaterals of those entering the pontine nucleus). Topographical representation in the nucleus is onion-like (Fig. 34-4).

Fig. 34-6 The five lines required to make a trigeminal sensory map.

(11)

D Bustami

Trigeminal neuralgia is a rare but important condition, characterized by attacks of excruciating pain in the territory of one or more divisions of the trigeminal nerve. The patients are able to map out the affected division(s) accurately. Since the condition has to be distinguished from many other causes of facial pain, the clinician must be able to draw the trigeminal sensory map (Fig. 34-6).

APPLIED ANATOMY

The motor nucleus and motor root are rarely affected by disease, but the root will be included if the mandibular nerve is divided in treating trigeminal neuralgia. Motor paralysis is revealed by deviation of the jaw toward the weak side on opening the mouth. The deviation is caused by the unopposed action of the healthy lateral pterygoid.

The *jaw-jerk* reflex (elicited by tapping the chin with a downward stroke) is routinely tested when the cranial nerves are being examined. Exaggeration of the jaw-jerk reflex signifies bilateral supranuclear lesions.

If the supranuclear supply to the motor nucleus is mainly contralateral, the jaw of a hemiplegic patient will deviate to the affected side when the mouth is opened.

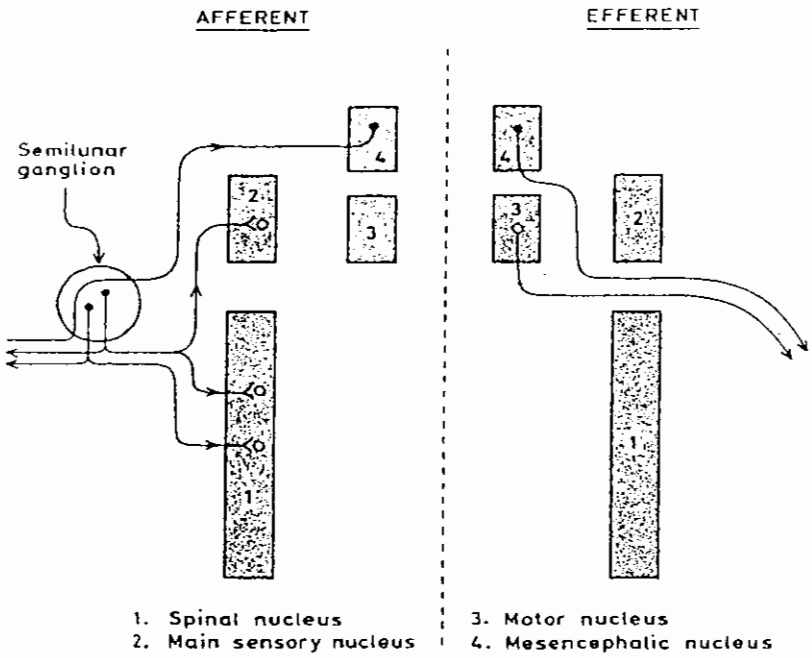

Figure 7.23. Composite schematic diagram of the afferent and efferent roots of the trigeminal (CN V) nerve and their nuclei.

Efferent root of Trig. N.
- arises from the motor nucleus of trig. nerve located in the tegmentum of the pons → it supplies the muscles of mastication
  - Temporalis
  - masseter
  - medial pterygoid
  - lat. "
- (+) tensor tympani
- " palati
- mylohyoid
- ant. belly of digastric

Mesencephalic nucleus (4 in the diagram)

The midbrain nucleus is a ribbon of unipolar cells lying beside the aqueduct of the midbrain and rostral end of the fourth ventricle, the *only* group of unipolar neurons within the CNS. Their peripheral processes supply sensory fibers to muscle spindles over a wide area: the extrinsic ocular muscles (rich in spindles), the facial muscles (poor), and the masticatory muscles (rich).

- The central processes end in thalamus & cerebellum

Fig. 8.31 Eliciting the jaw jerk.

Facial Nerve

(12)

The facial nerve is the most frequently paralyzed of all the peripheral nerves.

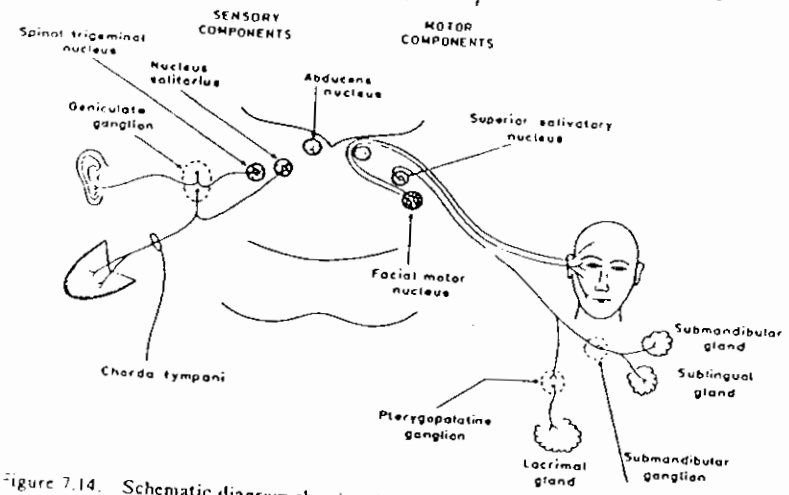

Figure 7.14. Schematic diagram showing the nuclei of origin, course, and areas of supply of the facial (CN VII) nerve.

Facial Nerve Components

Type of fibres	ganglion	nucleus	distribution
1. SVE (motor for special muscles)	×	Principle motor nuc. at Pons	Mimetic muscles ie muscles of facial expression
2. GVE (Parasympath.)	×	Superior salivatory	lacrimal g. / Submand. / Subling. salivary g. / Glands of nose & palate
3. SVA (taste)	geniculate ganglion	Solitary nuc.	ant. 2/3 of tongue
4. GSA	geniculate g.	spinal of V	skin of outer ear

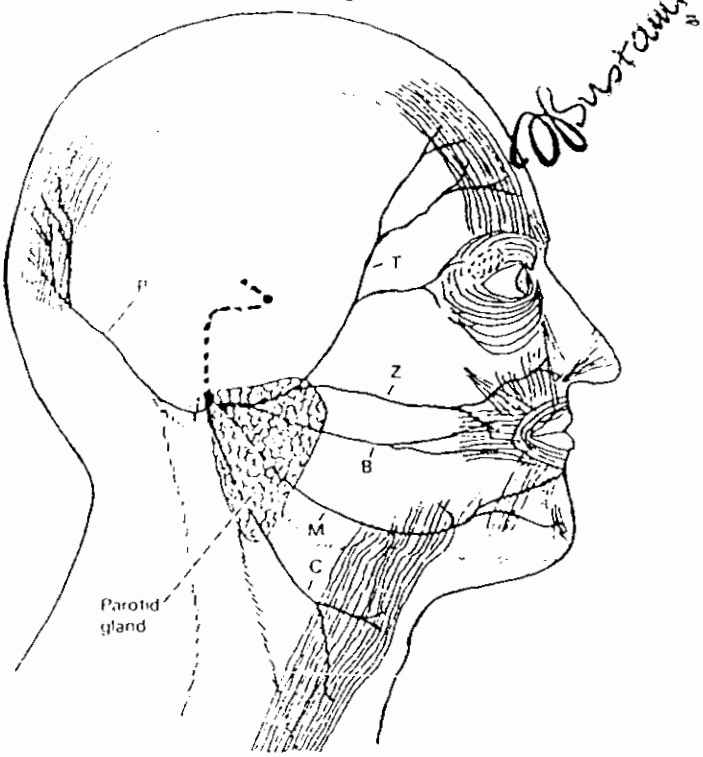

Fig. 35-2 Distribution of facial nerve. Branches to mimetic muscles: B, buccal; C, cervical; M, mandibular; P, posterior auricular; T, temporal; Z, zygomatic.

Course and distribution

The main facial nerve leaves the pons at its lower border and crosses the subarachnoid space to enter the temporal bone. It passes above the vestibule of the labyrinth, bends backward at the genu (L., knee) and descends to the stylomastoid foramen in the interval between the middle ear and the mastoid process. Before emerging from the skull it supplies the stapedius muscle. When it emerges it gives branches to the occipitalis, digastric (posterior belly), and stylohyoid muscles. Finally, it divides within the parotid gland into six branches to the mimetic muscles (muscles of facial expression) (Fig. 35-2).

BRANCHIAL EFFERENT ROOT (SVE)

The branchial efferent root (main facial nerve) supplies the muscles derived from the second branchial arch. They include all of the muscles inserting into the skin of the face, together with the stapedius and stylohyoid muscles and the posterior belly of the digastric muscle.

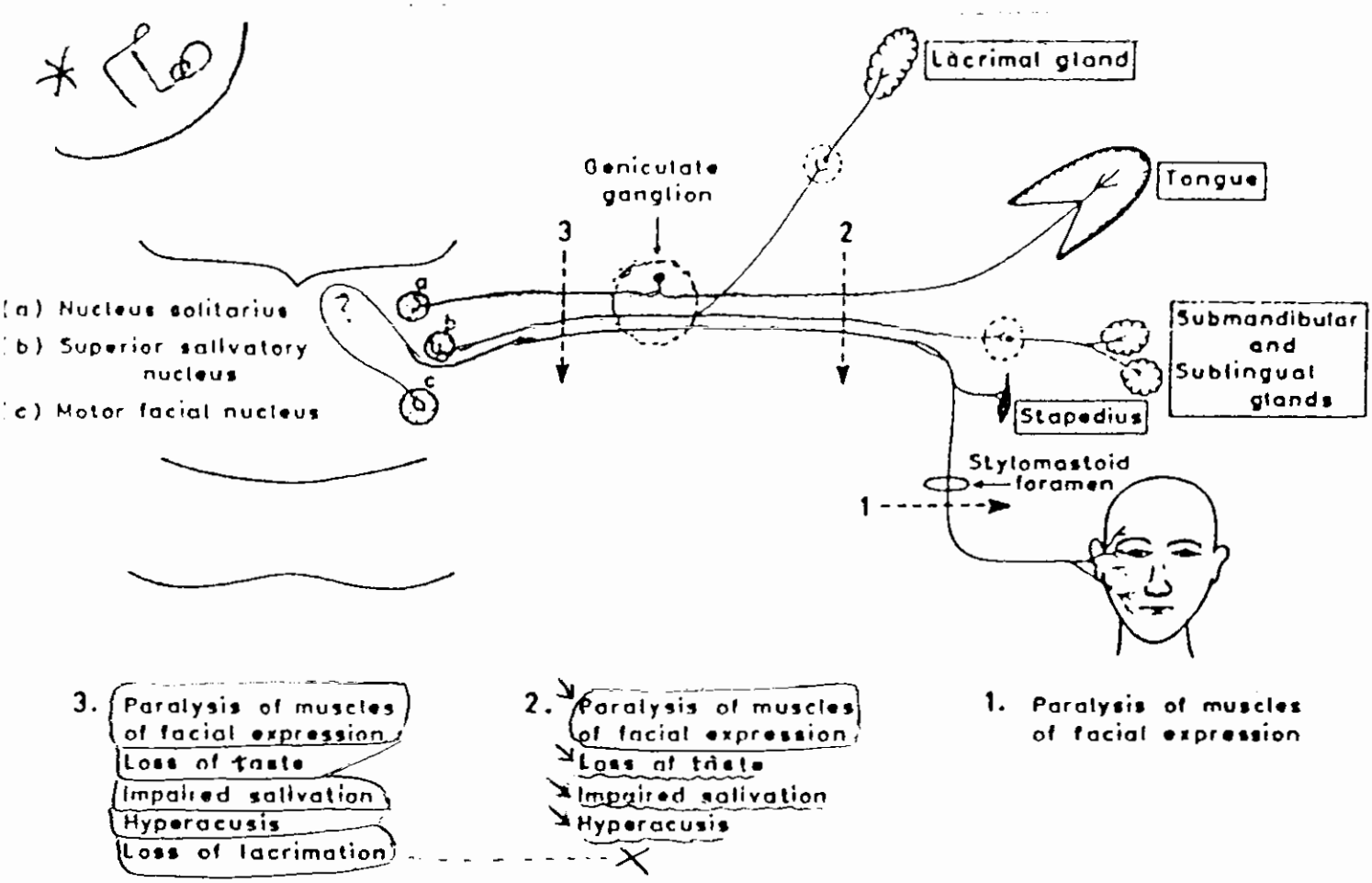

Figure 7.16. Schematic diagram showing lesions in the facial nerve at different sites and the resulting clinical manifestations of each.

PARASYMPATHETIC AND SPECIAL SENSE ROOTS (Fig. 35-6)

The nervus intermedius (NI) intervenes between the main facial nerve and the vestibulocochlear nerve in the internal acoustic meatus. It joins the facial nerve proximal to the genu.

The *parasympathetic root* of the NI arises in the superior salivatory nucleus. It contributes to the greater petrosal and chorda tympani nerves. The greater petrosal fibers synapse in the pterygopalatine ganglion, whose postganglionic fibers supply the lacrimal and nasal glands (Fig. 35-7). The chorda tympani fibers synapse in the submandibular ganglion, whose postganglionic fibers supply the submandibular, sublingual, and intralingual glands.

The *special sense root* of NI has its unipolar cell bodies in the geniculate ganglion of the facial nerve. The peripheral processes of the ganglion enter the greater petrosal nerve to supply the palatal taste buds and enter the chorda tympani to supply the taste buds of the anterior two-thirds of the tongue, being carried there by the lingual nerve.

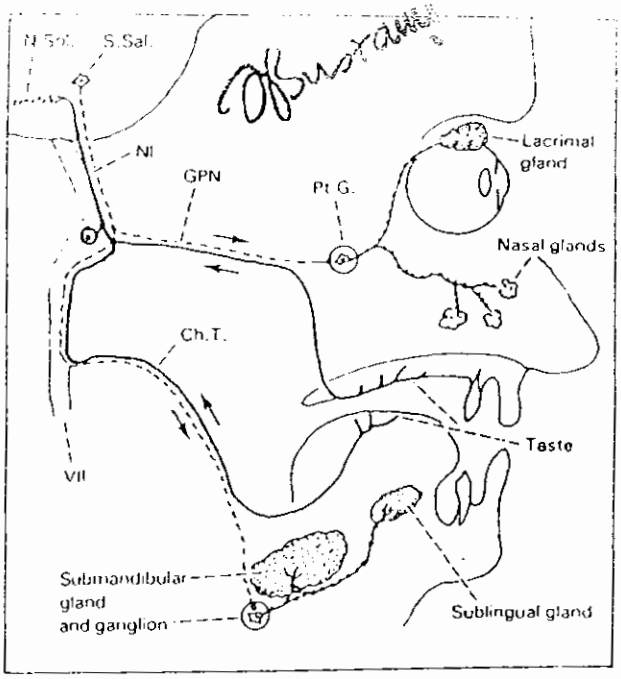

Fig. 35-6 The nervus intermedius. Ch.T., chorda tympani; GPN, greater petrosal nerve; Pt.G., pterygopalatine ganglion; NI, nervus intermedius; N.Sol., nucleus solitarius; S.Sal., superior salivatory nucleus.

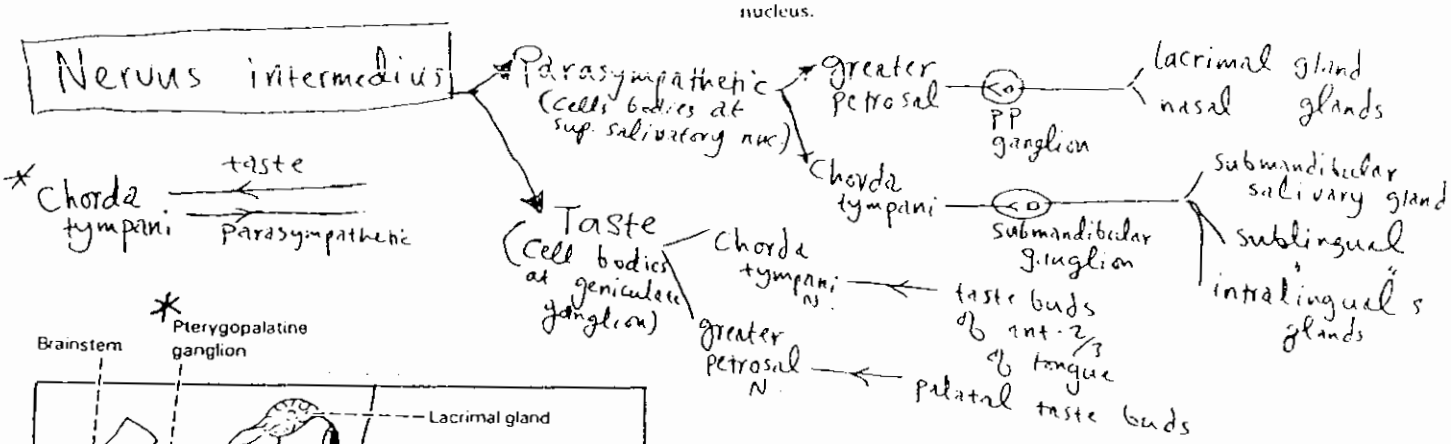

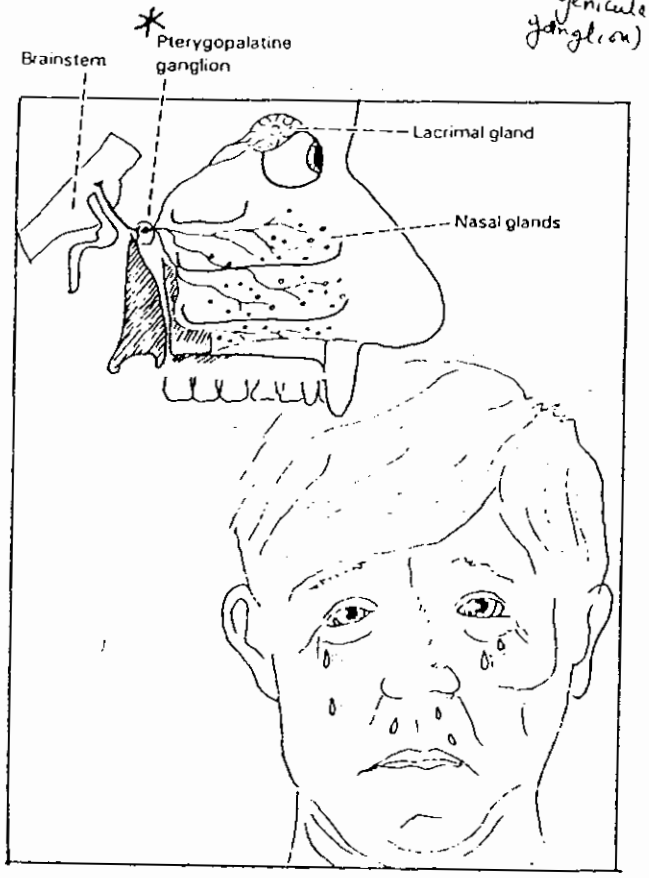

Fig. 35-7 Pterygopalatine ganglion ('ganglion of hay fever').

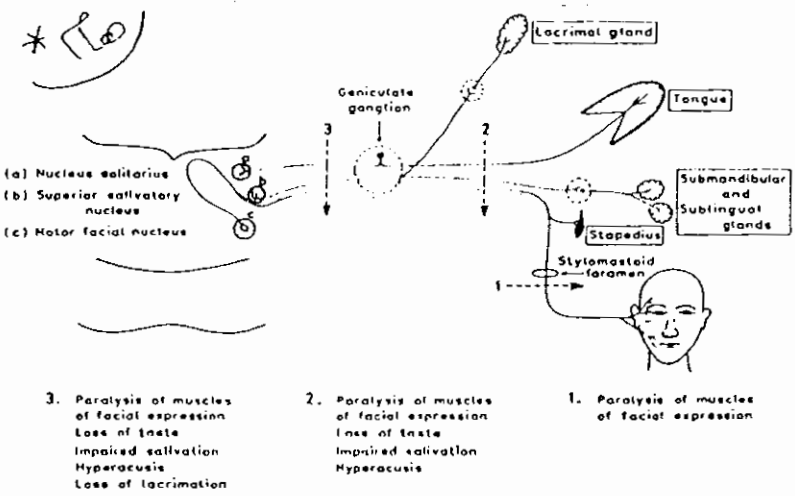

Figure 7.16. Schematic diagram showing lesions in the facial nerve at different sites and the resulting clinical manifestations of each.

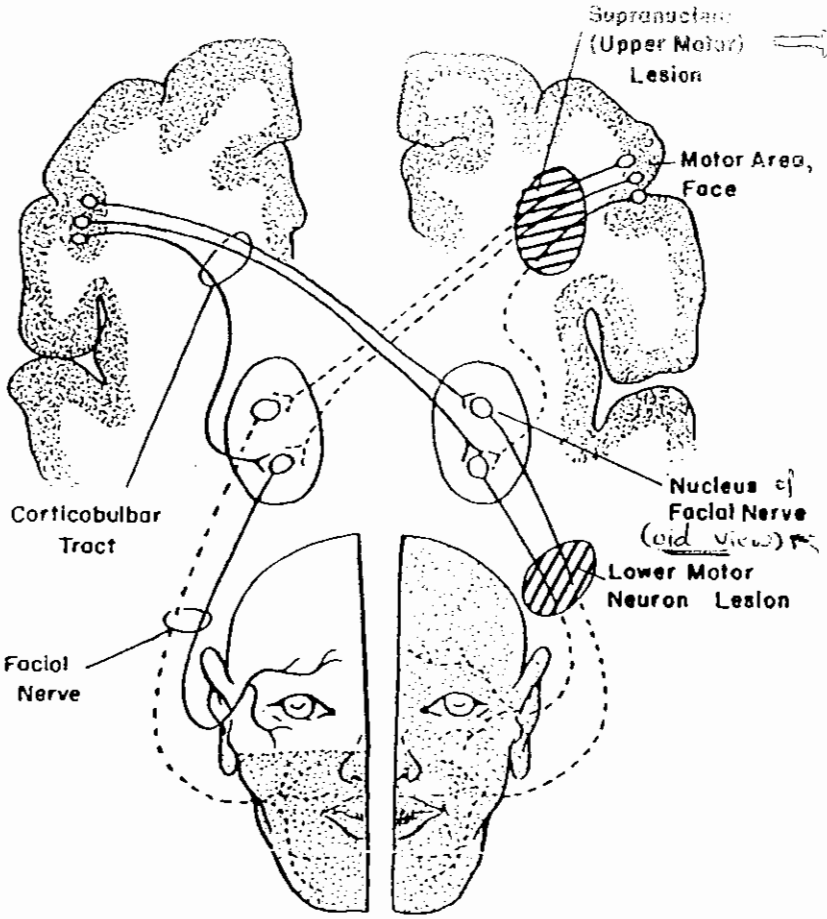

⇒ Supranuclear lesions of the facial nerve (i.e U.M.N.L) are caused by damage to the Contralateral pyramidal tract ⇒ Weakness of the lower face is a classical feature of a stroke (thrombosis or hemorrhage in the internal capsule)

⇓ i.e

In cases of **Hemiplegia**

→ weakness of Hemiface

⇓

(lower ½)

15

FIGURE 28. The shaded areas of the face show the distribution of facial muscles paralyzed after a supranuclear lesion of the corticobulbar tract, and after a lower motor neuron lesion of the facial nerve.

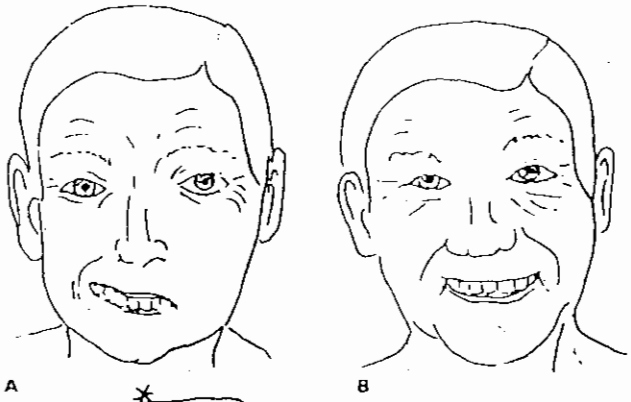

Fig. 35-4 A, supranuclear lesion of the left facial nerve. B, the patient can smile spontaneously.

Limbic connections

A hemiplegic patient may use the paralyzed lower face during a spontaneous smile (Fig. 35-4). The 'emotional' supranuclear fibers presumably travel from the limbic cortex. Their course is uncertain but it may include the basal ganglia; this is suggested by the absence of emotional expression in patients with Parkinson's disease.

Absence of transverse creases due to paralysis of ??

Bell's palsy (شلل بيل)

Unable to close the eye on the affected side ⇓ paralysis of ???

Absence of naso-labial fold ??? (Mask face)

Deviation of the angle of the mouth to the healthy side

Fig. 35-8 Bell's palsy, left side. Response to the request, 'Close your eyes and show your teeth'. (إصابة العصب الوجهي)

Bustami

Input (Afferent) connections of the motor nucleus of facial nerve

Bhuvana (10)

1. Bilateral corticobulbar fibres → to that part of the nucleus which supplies the upper facial muscles and only contralateral to that part of the nucleus that innervates Lower face (Perioral muscles) ⟹ In lesions affecting one hemisphere → only the lower facial muscles contralateral to the lesion are affected

2. Basal ganglia → this explains the movement of paretic facial muscles in response to emotional stimulation i.e Patients with supranuclear facial paralysis (usually hemiplegic patients) who are unable to move the lower facial muscles voluntarily may be able to do so reflexely in response to emotional stimulation

3. Superior olive → explains the grimacing of facial muscles that occurs in response to loud noise

4. Trigeminal system → Underlies the blinking of eyelids in response to corneal stimulation.

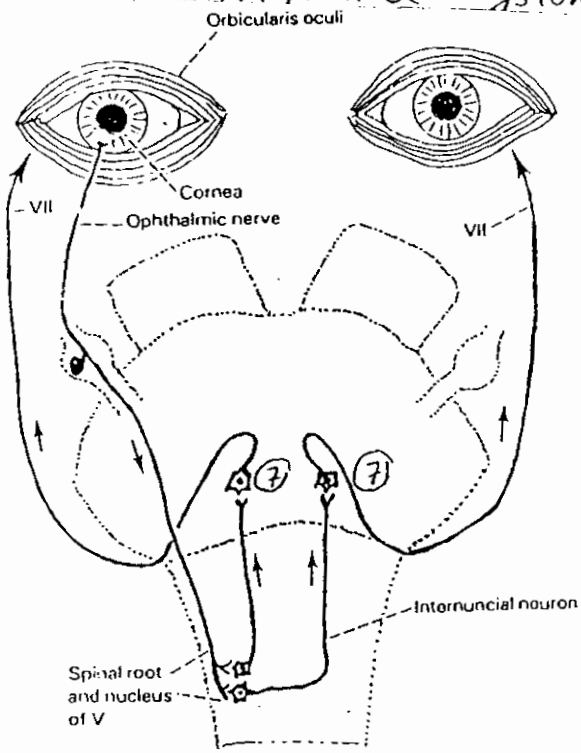

Corneal reflex (Fig. 35-5)

Touching the cornea with a cotton wisp elicits a bilateral blink response. The afferent limb is the ophthalmic nerve (its nasociliary branch supplies the cornea); the efferent limb is the facial, to the palpebral (eyelid) fibers of the orbicularis oculi muscle.

Basic Structure of the Pons

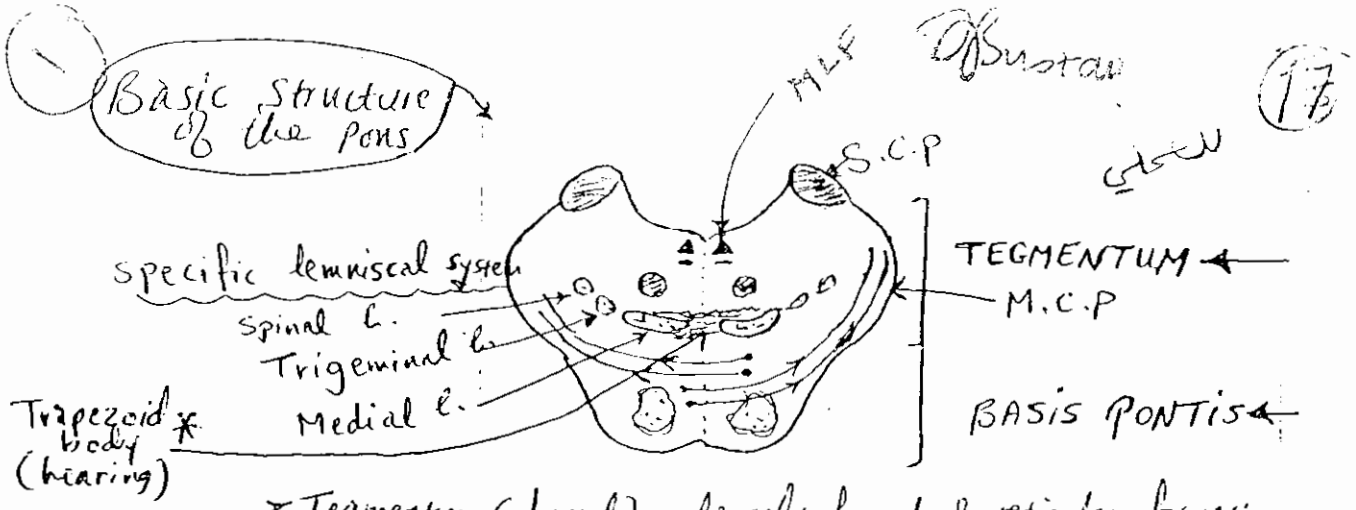

PONS
- Tegmentum (dorsal) → largely formed of reticular formation
  - Abducent nucleus in the floor of 4th ventricle
  - Facial nucleus → migrated to the inside
  - Trig. nuclei → " " "
- Lemniscal system
- Basis pontis (Ventral)
  - → corticospinal fibres ↓
  - → corticobulbar " ↓
  - → Cortico-ponto-cerebellar



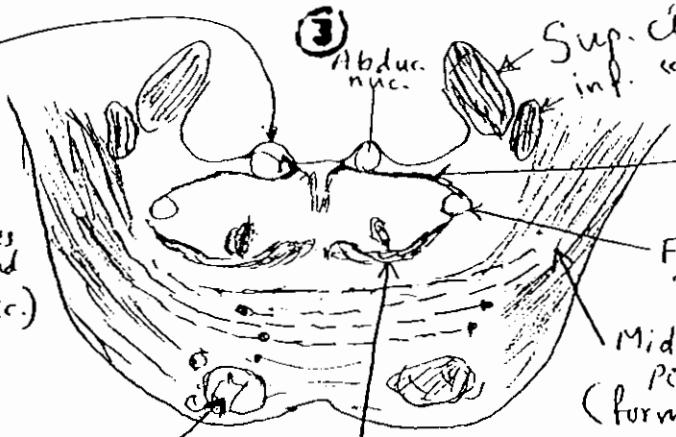

Pyramidal tract (MOTOR)
- corticospinal
- corticobulbar

4 lemnisci (sensory)
- * Medial L.: dorsal column syst.
- * Spinal L.: Spinothalamic tract (Anterolateral syst.) → pain, temp. crude touch from contralateral ½ of body
- * trigeminal L.: trigemino-thalamic tracts
- * lateral L.: part of auditory pathway

PONS: level of cranial nerve nuclei 6, 7

PONS → Level of (motor) & (main Sensory) nuclei of Trigem. Nerve

(6) Offustra.

(1) S C P Superior Cerebellar Peduncle
↓
mainly axons of Dentate nucleus & Red nucleus
↓
Remember Dentato-rubro-thalamic tract

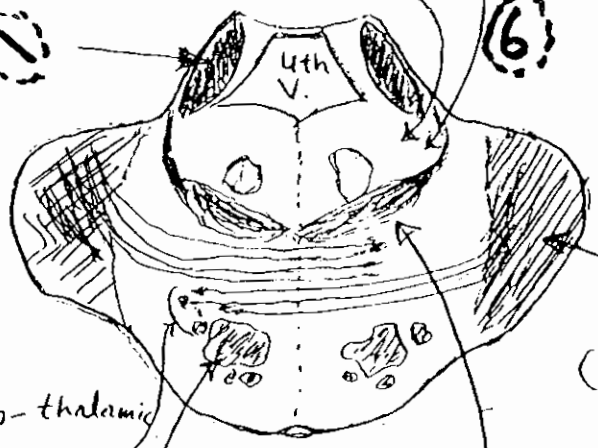

(2) M C P Middle Cerebellar Peduncle
↓
(axons of nuclei Pontis of opposite side)

(3) (4) Lemnisci (Sensory)

* Medial L. : dorsal column syst. (Position, Kinesthesia Stereognosis ..... etc
* Spinal L. : pain, temp. crude touch i.e (spinothalamic tract)
* trigeminal : trigeminothalamic tracts (from trig. nuclei to thalamus
* Lateral : part of auditory Pathway

(4) Pyramidal tract (MOTOR)

Corticospinal corticobulbar

(5) pontine nuclei

Other cranial nerve nuclei at this level ??

Offustrami

(18)

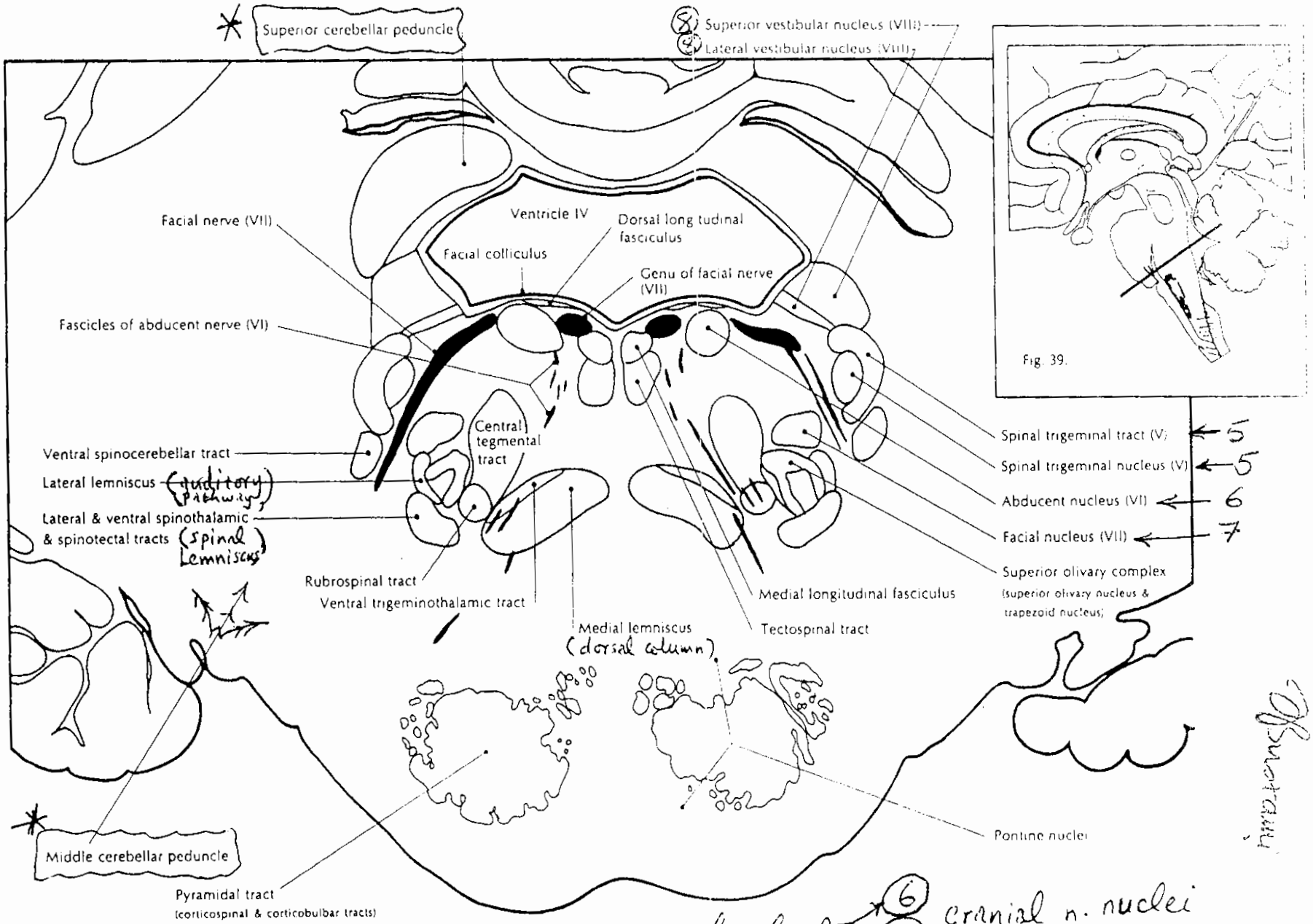

PONS → level of 6 7 cranial n. nuclei
" " < superior cerebellar peduncle
middle " "
" " Medial lemniscus
spinal "
lateral lemniscus
trigeminal

Figure 39. Pons: Level of cranial nerve nuclei VI and VII—Weil, 6.5X

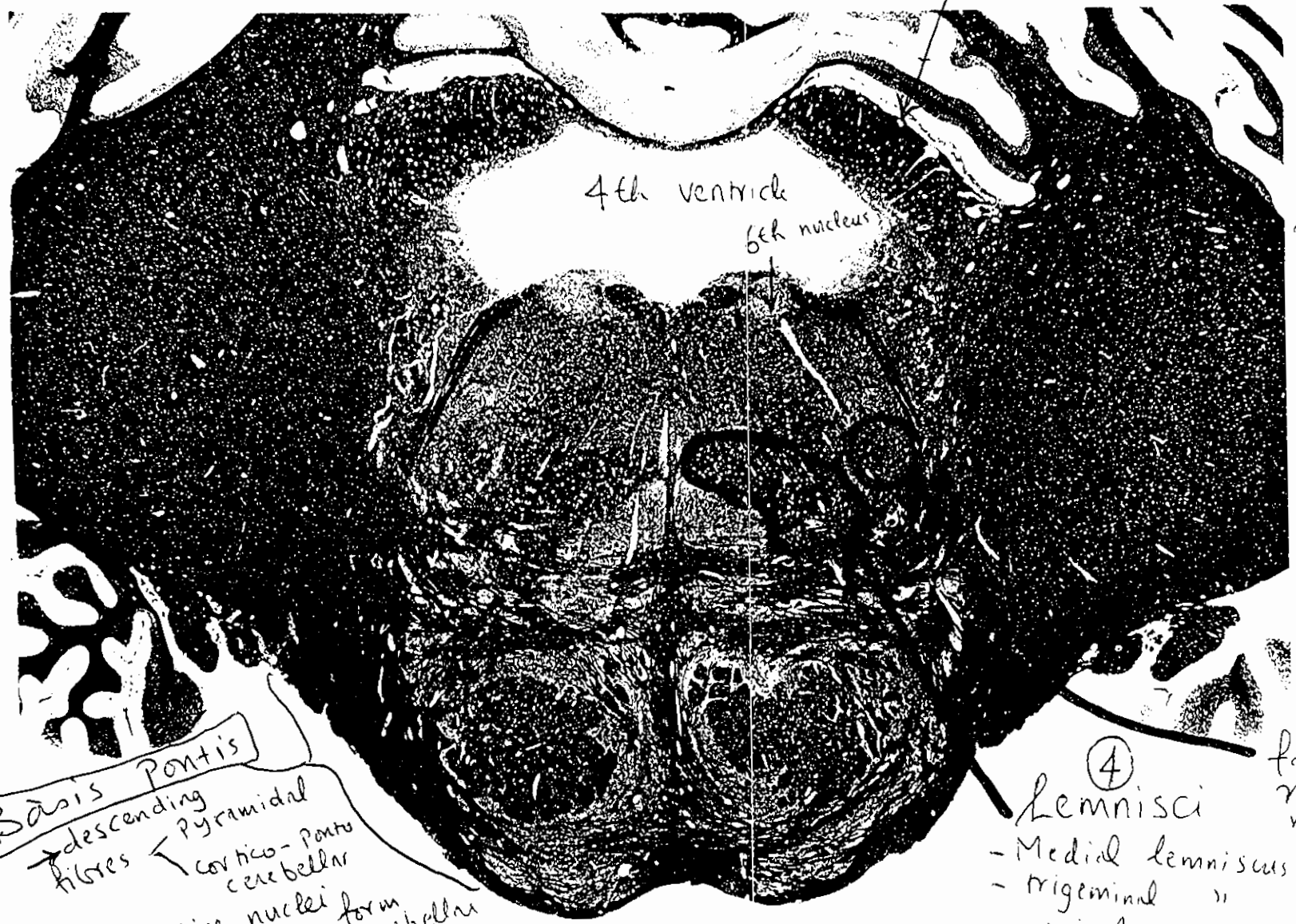
Superior Cerebellar Peduncle
-beginning?
- termination?
- function?
4th ventricle
6th nucleus
Middle Cerebellar Peduncle
-beg ?
- termination
- function?
facial motor nucleus
Basis Pontis
descending fibres
Pyramidal
cortico-ponto cerebellar
Pontine nuclei (their axons form the middle cerebellar peduncle)
4
Lemnisci
- Medial lemniscus
- trigeminal "
- spinal "
- lateral "

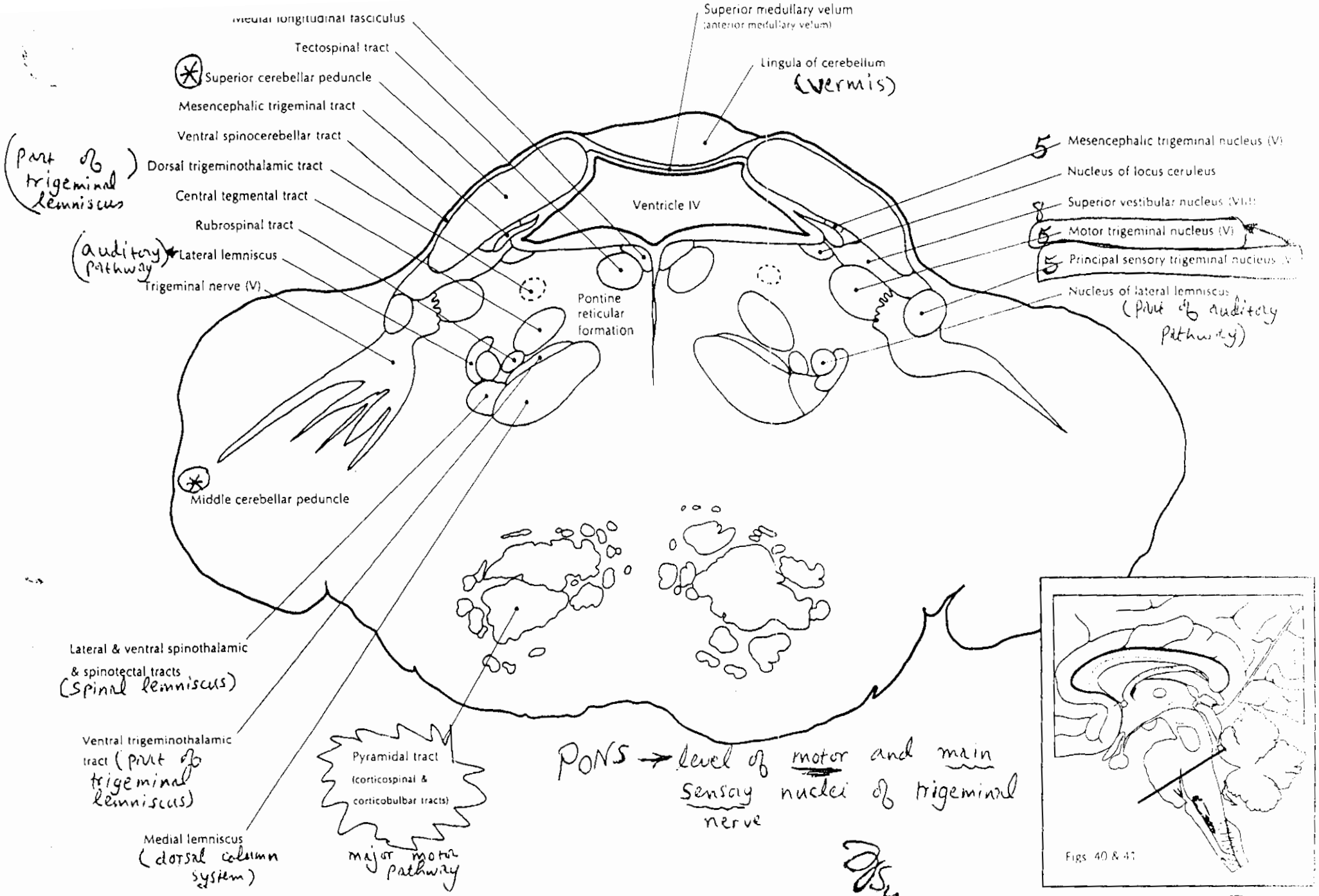

Figure 40. Pons: Level of motor and principal sensory nuclei of cranial nerve V—Weil, 6.5X

{Section of PONS at the level of motor & main sensory nucleus of trigeminal nerve}

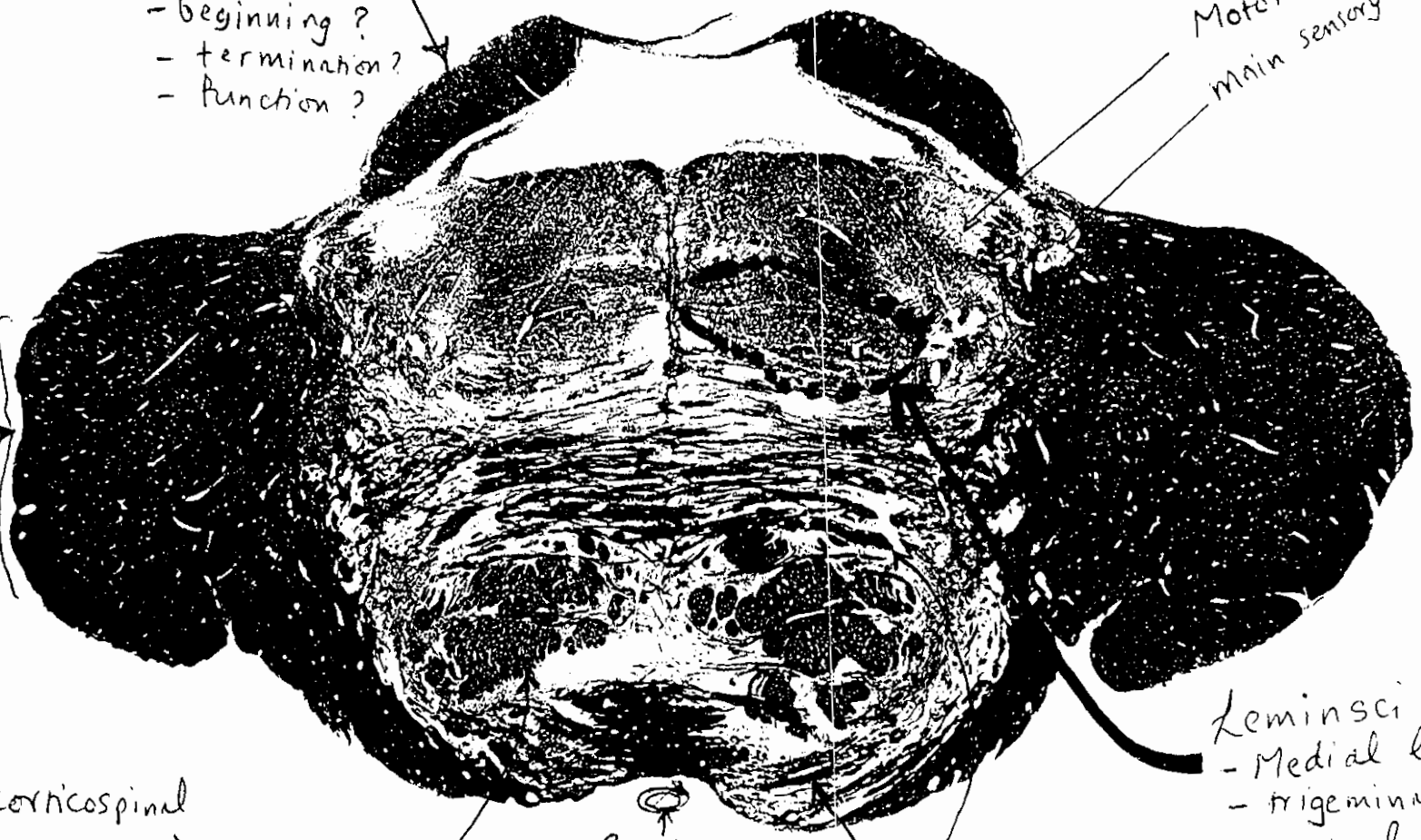

* Tr. Section of the MIDBRAIN passing through the inferior colliculus

CEREBRAL AQUEDUCT

Inferior colliculus

Central gray substance (containing mesencephalic nucleus of V)

Trochlear nucleus

Medial longitudinal fasciculus (MLF)

Central tegmental tract ⊕ dorsal trigeminothalamic tract

⊛ Decussation of superior cerebellar peduncles

Crus cerebri

Brachium of inf. colliculus (connecting inf. colliculus to medial geniculate body of thalamus)

Lateral lemniscus (part of auditory pathway)

Temporo-parieto-occipito-pontine tract

corticospinal fibres to lower limb

corticospinal fibres to trunk

corticospinal fibres to upper limb

corticobulbar fibres (eventual supplying muscles of face, pharynx, larynx, tongue, ... etc.

frontopontine fibres

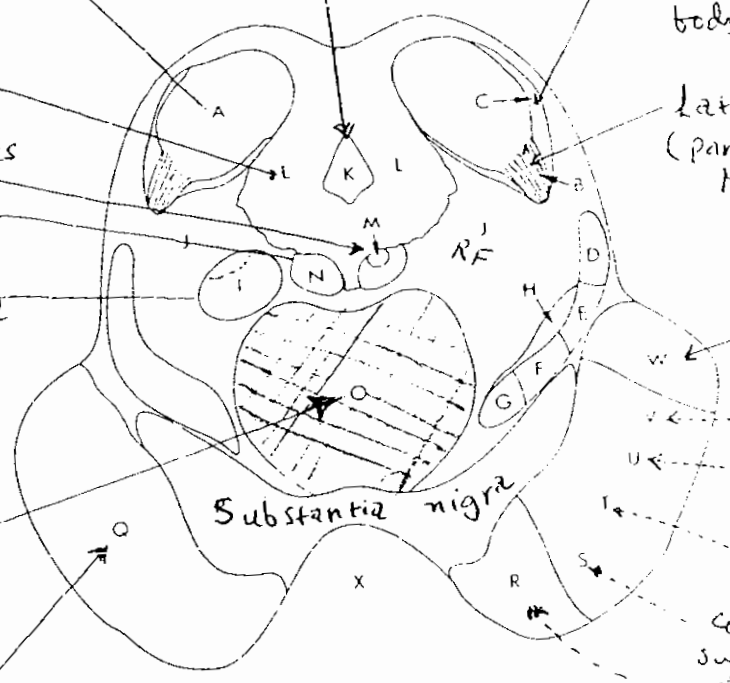

H = Ventral trigeminothalamic tract
D = Anterolateral system (spinothalamic tracts)
E = Gracile part of medial lemniscus
F = Cuneate part of >> >>
G = secondary ascending taste fibres

DBustami

DBustami 1991

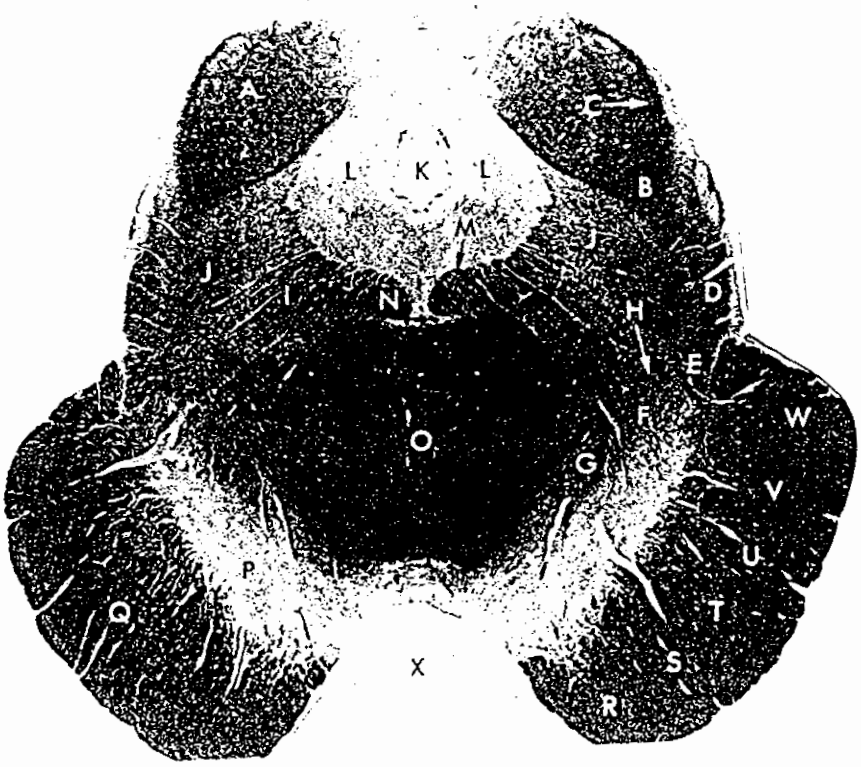

* Tr. Section of the Midbrain passing through the superior colliculus

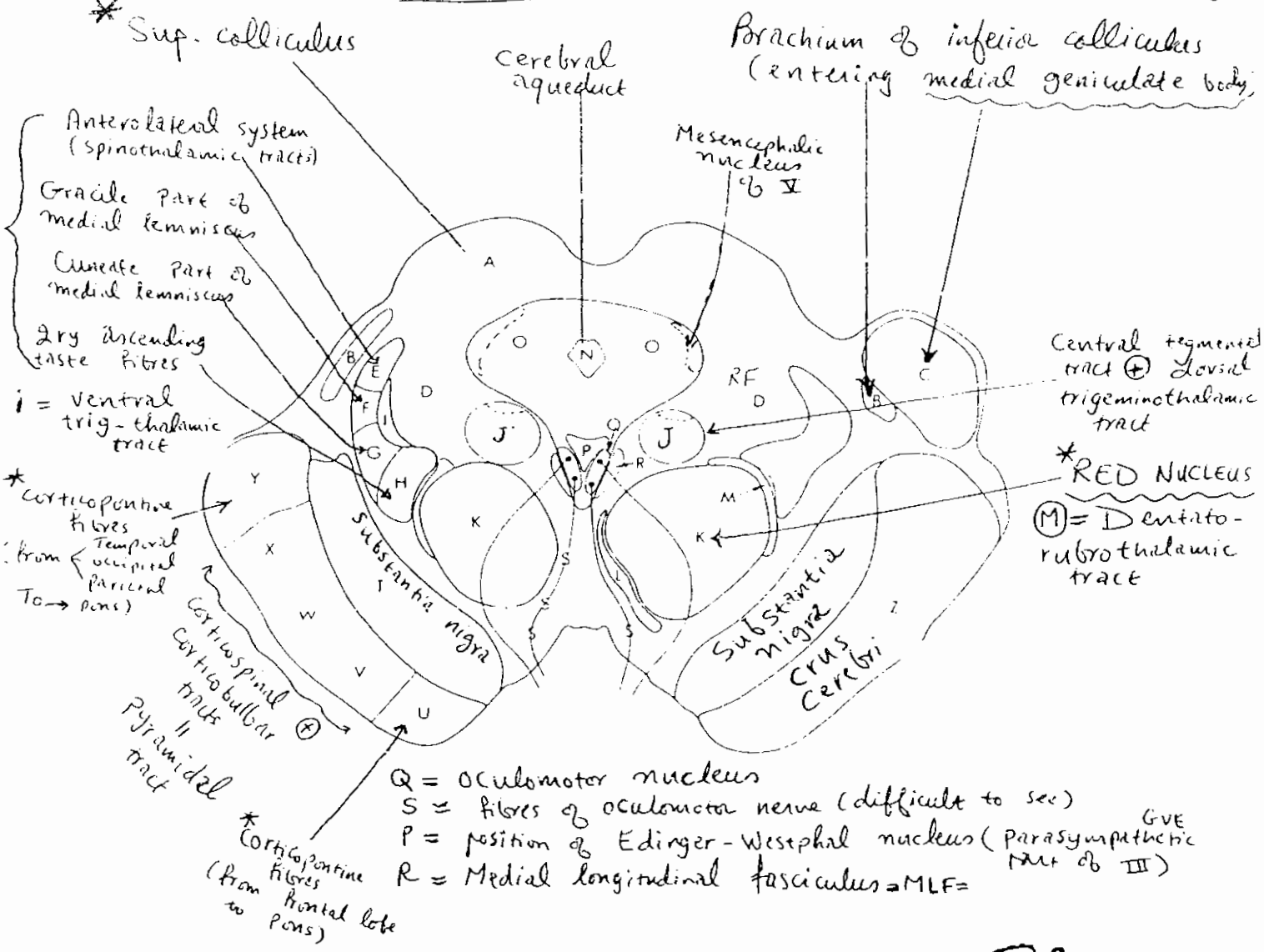

Bustami
Bustami 1991

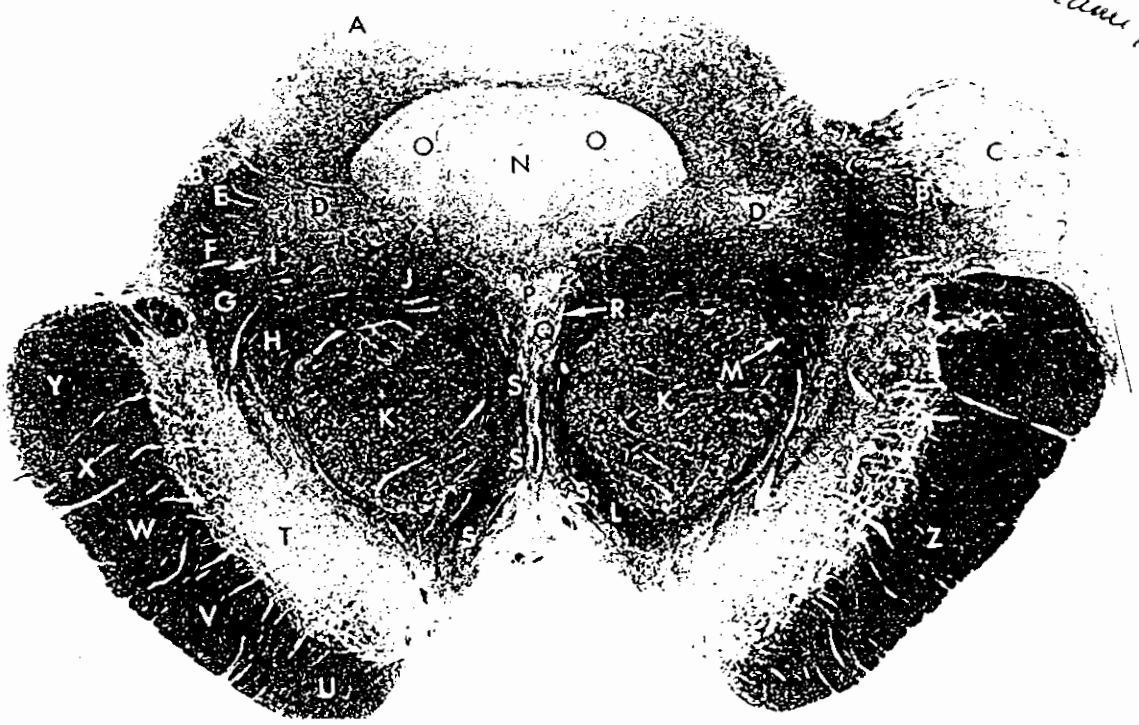

General organization of Midbrain → Tectum, Tegmentum, Crus cerebri (cerebral peduncles & substantia nigra)

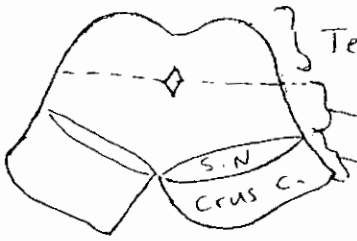

Tectum → a mixture of gray and white matter dorsal to the central gray and cerebral aqueduct. It includes the superior and inferior colliculi

Tegmentum → the main portion of the midbrain → contains ascending & descending tracts ⊕ reticular formation ⊕ certain nuclei

Substantia nigra & Crus cerebri → massive bundle of corticofugal fibres

formed of: Corticospinal fibres, corticobulbar fibres, corticopontine fibres → from: Occipital, frontal, parietal, temporal lobes

PONS ← TO

Midbrain at inferior colliculus level: The most characteristic feature of this level is → decussation of the superior cerebellar peduncles (brachia conjunctivae). The superior cerebellar peduncle is a massive bundle of fibres arising in the deep cerebellar nuclei. These fibres decussate in the tegmentum of midbrain at this level; some proceed rostrally to terminate upon the red nucleus and others form the capsule of the red nucleus and continue rostrally to terminate upon the VL (ventrolateral) nucleus of thalamus.

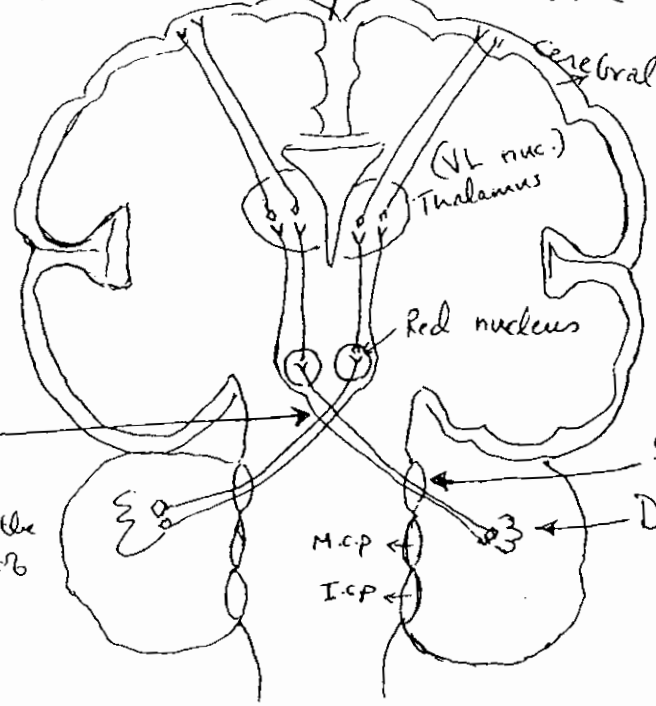

Decussation of Superior cerebellar peduncles → At the level of the inferior colliculus of midbrain

Sup. cerebellar peduncle (S.C.P)

Dentate nucleus of cerebellum

* Notice that the presence of 2 decussations:
  1. decussation of superior cerebellar peduncles
  2. decussation of pyramidal (corticospinal) tracts

  is Responsible for the fact that each half of cerebellum (each cerebellar hemisphere) CONTROLS the muscles of the IPSILATERAL HALF (i.e same side) of the body.

* The tegmentum of the midbrain at the level of the inferior colliculus contains the following:

(4) Lemnisci
- Medial lemniscus → composed of gracile and cuneate parts and represents upward continuation of Posterior Column system
- Trigeminal lemniscus → composed of ventral trigemino-thalamic tract and travels close to medial lemniscus
- Spinal lemniscus → represent upward continuation of the spinothalamic tracts i.e Anterolateral System. It is located lateral to the medial lemniscus & conveys pain and temperature sensations from the contralateral half of body
- lateral lemniscus → conveys auditory fibres

Bustami

* Medial Longitudinal fasciculus (MLF) → maintains its position dorsally in the tegmentum in a Paramedian position. It is present at all levels of brainstem. It connects the vestibular nuclei with the nuclei of III, IV & VI nerves (i.e nerves of extraocular muscles) as well as with the alpha and gamma motor neurons of the cervical region of spinal cord.
  ⇒ Through these connections the eyes can move in response to movements of the head (i.e vestibulo-ocular reflexes)
* The MLF also establishes internuclear connections between the nuclei of III, IV & VI nerves → Responsible for conjugate movements of the eyes (i.e the two eyes can move in harmony)

* Cerebral Peduncle (Crus cerebri) → is the massive fibre bundle occupying the most ventral part of midbrain.
* It is continuous Rostrally with the internal capsule and caudally with the basis pontis.
* It contains 2 types of Corticofugal fibres
  - Pyramidal
    - corticospinal
    - cortico-bulbar
  - corticopontine
* Corticopontine fibres — originate from wide areas of cerebral cortex → Synapse on pontine nuclei → enter the Contralateral cerebellar hemisphere via the middle cerebellar peduncle (brachium pontis).

Dr Sustrami

Midbrain at Superior colliculus level

* Tectum → The nucleus of the superior colliculus occupies the tectum at this level → Aff. / Eff. ???
* Remember that Rostral to the superior colliculus at the junction of the midbrain and diencephalon is the Pretectal area (Pretectal nucleus). This area is important for light reflex.
* Tegmentum: at the level of the superior colliculus contains all the tracts encountered at the inferior colliculus level EXCEPT the → LATERAL LEMNISCUS ← which terminates upon inferior colliculus neurons and is NOT seen at superior colliculus level.
* Nuclear groups
  - Red nucleus
  - oculomotor nucleus
  - accessory oculomotor nuclei

Red nucleus
- → Afferent connections from
  - Deep cerebellar nuclei
    - Dentate
    - globose
    - Emboliform
  - cerebral cortex (Cortico-rubro-spinal tract)
- → Efferent connections TO
  a. Spinal cord (Rubrospinal cord)
  b. cerebellum
  c. Reticular formation → cerebellum
  d. Inferior olive → cerebellum